Downloaded from http://jnnp.bmj.com/ on May 6, 2016 - Published by group.bmj.com

double-stranded DNA antibodies[9] prompted speculation[10] as to whether such antibodies, or other autoantibodies described in scleroderma, might be found in patients with "idiopathic" HFA.

It has been suggested that lesions to the ipsilateral cervical sympathetic innervation, whether peripheral or central, may cause HFA. Moss and Crikelair reported a rat model of progressive HFA following cervical sympathectomy.[11] However, autonomic function testing in patients with HFA has produced conflicting results: although some patients have clear evidence of concomitant autonomic dysfunction (for example, ipsilateral Horner's syndrome) others give entirely normal responses to standard tests of autonomic function.[12] Nonetheless, Archambault and Fromm[12] came to the conclusion that the sympathetic theory alone could explain most cases of HFA, even those without overt evidence of autonomic dysfunction, a position which seems less tenable today. Only indefinite pathological changes have been found in the cervical sympathetic ganglia in the few patients examined thoroughly at post mortem.[12] No evidence of autonomic dysfunction was found in our patient.

Facial trauma is a recognised antecedent of HFA (in up to a third of cases[12]) but the mechanism(s) whereby it might produce the condition remain to be clarified. Much remains to be learned of the aetiology of this condition, which probably should not be regarded as a uniform syndrome. Its clinical heterogeneity probably reflects an underlying aetiological heterogeneity.[6 10] Some cases probably reflect a developmental abnormality, possibly with a genetic basis; other cases may form part of the clinical spectrum of scleroderma, and others still may result from involvement of the cervical sympathetic chain. The suggestion has also been made that cases with prominent neurological complications may result from a slow viral infection.[13]

We thank Dr R C Hughes for permission to report his patient.

A J LARNER
D P BENNISON
Midland Centre for Neurosurgery and Neurology, Holly Lane, Smethwick, Warley, West Midlands B67 7JX, UK

Correspondence to: Dr Larner, Department of Anatomy, Downing Street, Cambridge CB2 3DY, UK.

1 Parry CH. Collections from the unpublished medical writings of the late Caleb Hillier Parry. London: Underwoods, 1825:478.
2 Romberg HM. *Trophoneurosen Klinische Ergebnisse*. Berlin: A Forstner, 1846:75–81.
3 Jeffreys AJ, Wilson V, Thein SL. Individual-specific "fingerprints" of human DNA. *Nature* 1985;**316**:76–9.
4 Johnson RH, Spalding JMK. *Disorders of the autonomic nervous system*. Oxford: Blackwell, 1974.
5 McKusick VA. *Mendelian Inheritance in Man*, 5th ed. Baltimore: The Johns Hopkins University Press, 1978.
6 Lewkonia RM, Lowry RB. Progressive hemifacial atrophy (Parry-Romberg syndrome). Report with review of genetics and nosology. *Am J Med Genet* 1983;**14**:385–90.
7 Wartenberg R. Progressive facial hemiatrophy. *Arch Neurol Psychiatry* 1945;**54**:75–96.
8 Lakhani PK, David TJ. Progressive hemifacial atrophy with scleroderma and ipsilateral limb wasting (Parry-Romberg syndrome). *J R Soc Med* 1984;77:138–9.
9 Adebajo AO, Crisp AJ, Nicholls A, Hazleman BL. Localized scleroderma and hemiatrophy in association with antibodies to double-stranded DNA. *Postgrad Med J* 1992;**68**:216–8.
10 Larner AJ. Localized scleroderma and hemiatrophy in association with antibodies to double-stranded DNA. *Postgrad Med J* 1993;**69**:166.
11 Moss ML, Crikelair GF. Progressive facial hemiatrophy following cervical sympathectomy in the rat. *Arch Oral Biol* 1959–60;**1**:254–8.
12 Archambault L, Fromm NK. Progressive facial hemiatrophy: report of three cases. *Arch Neurol Psychiatry* 1932;**27**:529–84.
13 Wolf SM, Verity MA. Neurological complications of progressive facial hemiatrophy. *J Neurol Neurosurg Psychiatry* 1974;**37**:997–1004.

Subarachnoid haemorrhage associated with MDMA abuse

Over recent years the use of 'ecstasy' (3, 4-methylenedioxymethamphetamine, MDMA), a synthetic amphetamine derivative, has become increasingly popular. In the United Kingdom organised abuse of 'ecstasy' often takes place at 'rave parties'[1] involving several hundred participants in prolonged vigorous dancing.

MDMA is generally taken orally and in the only case that has been reported a peak plasma concentration of 0·106 mg/l was measured at two hours following a 50 mg oral dose (in a 74 kg adult male). The elimination half life in this case was estimated to be 7·6 hours with 65% of the dose excreted in the urine unchanged and 7% excreted as the metabolite methylenedioxyamphetamine (MDA) within three days.[2] Whilst the potential for misuse has been recognised and it has been banned under UK legislation as a class 'A' drug since 1971, serious morbidity and mortality associated with MDMA has only recently been noted. Deaths following MDMA abuse have occurred in the presence of underlying pathology such as ischaemic heart disease, asthma and cardiac conduction defects but no predisposing cause is necessary; death has been reported due to ventricular fibrillation.[3 4] In addition, significant morbidity has been noted including hyperthermia, disseminated intravascular coagulation and acute renal failure.[5] Despite widespread abuse acute neurological complications from MDMA seem to be rare.[6] Cocaine and amphetamine abuse are both well recognised causes of subarachnoid haemorrhage[7–10] but we are unaware of any similar reports of subarachnoid haemorrhage associated with MDMA.

A 25 year old female presented in the accident and emergency department at 11.20 am with a severe occipital headache of sudden onset at 6 am that morning. The headache was described as the "worst headache she had ever had" and was associated with vomiting. Between 00.30 and 05.00 she had taken 2 1/2 'ecstasy' tablets, while sitting at home with friends. Although she was a 'regular user' and this amount was 'usual' for her, she denied the use of 'ecstasy' for the previous two months. There was no history of any other drug abuse and she had not consumed alcohol. Past medical history was unremarkable and there was no prescribed medication.

On clinical examination she was apyrexial, alert, orientated, and responding appropriately to verbal commands. Motor responses and eye opening were normal; she had meningism with a positive Kernig's sign on the right. Pupils were symmetrical and not dilated with normal direct and consensual responses. Fundoscopy and examination of the cranial nerves was normal. Reflexes were symmetrically brisk with normal tone and power and flexor plantar responses. Blood pressure on arrival 5 1/2 hours after the onset of symptoms was 120/60 mmHg with a regular heart rate of 80/minute. The remainder of the physical examination was clinically normal as was routine haematology and biochemistry. The MDMA plasma concentration measured at the National Poisons Unit, Guy's Hospital, was 0·21 mg/l 13–18 hours after ingestion and the analysis excluded the presence of other stimulant drugs.

She received 60 mg of dihydrocodeine orally as analgesia. A CT head scan was performed showing subarachnoid haemorrhage with blood in the sulci (fig 1a, b). Treatment was started with regular oral nimodipine 60 mg 4 hourly, before transfer to the regional neurosurgical centre. Carotid angiography revealed a left posterior communicating artery aneurysm (fig 2), which was subsequently clipped. Following surgery she made a complete recovery.

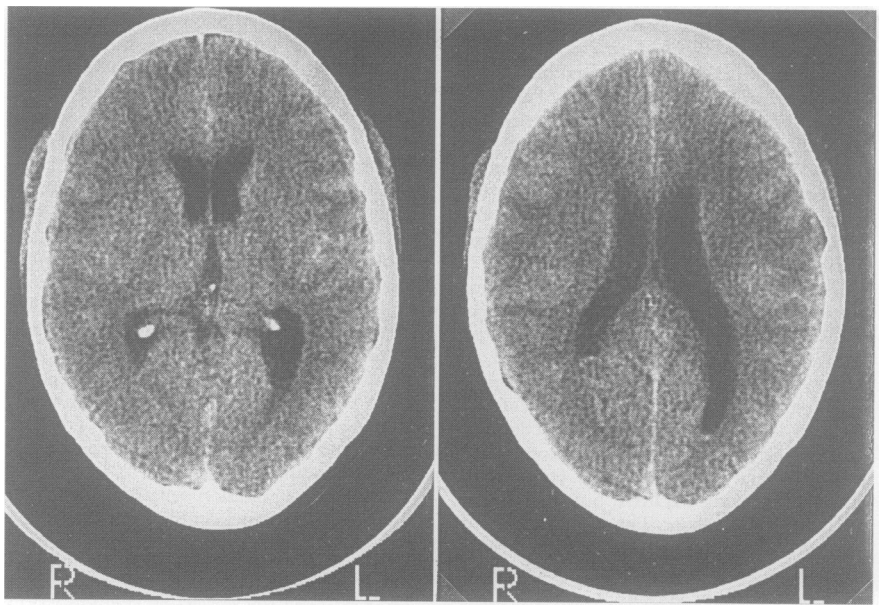

Figure 1 (A) (left) CT head without contrast showing blood in the cerebral sulci; (B) (right) CT head without contrast showing expansion of right lateral ventricle posteriorly.

Downloaded from http://jnnp.bmj.com/ on May 6, 2016 - Published by group.bmj.com

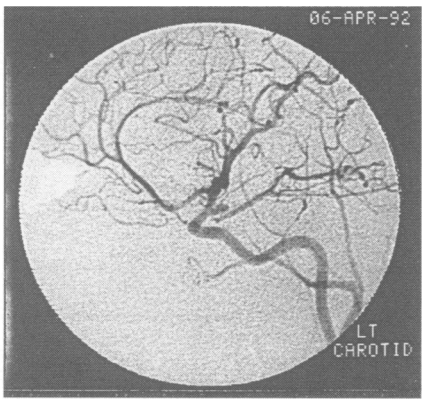

Figure 2 Digital subtraction carotid angiogram illustrating the left posterior communicating artery aneurysm.

It is evident that this patient had a pre-existing 'berry' aneurysm. After ingestion of MDMA, however, it is possible that there was an acute sympathetically mediated surge in blood pressure which caused the aneurysm to rupture. It is also possible that due to repeated use of the drug recurrent surges in blood pressure led to progressive weakening of the vessel wall resulting in aneurysm instability. As noted previously this patient had been a regular user of MDMA over a two to three year period before presentation. Such a mechanism has previously been suggested in cocaine abuse which has a recognised association with subarachnoid haemorrhage.[10] Although current usage of MDMA is generally associated with the 'rave scene' it is of note that in the patient we describe, no strenuous physical activity or sexual intercourse was associated with the onset of symptoms.

This case emphasises the importance of taking a full drug history including the possible abuse of illicit drugs in patients presenting with subarachnoid haemorrhage. Subarachnoid haemorrhage may therefore be yet another serious adverse effect of the abuse of MDMA and adds to the increasing number of reports of serious morbidity and mortality associated with this drug.[11]

J A GLEDHILL*
D F MOORE
D BELL*
J A HENRY
National Poisons Unit, Guy's Hospital, London, and Department of Thoracic Medicine, Central Middlesex Hospital, London, UK*

Correspondence to: Dr Moore, National Poisons Unit, Avonley Road, London SE14 5ER, UK.

We thank Dr Sheila Dawling, National Poisons Unit, for her expertise in performing the MDMA assay.

1 Henry JA. Ecstasy and the dance of death. *BMJ* 1992;**305**:4–5.
2 Baselt RC, Cravey RH. *Methylenedioxymethamphetamine in disposition of toxic drugs and chemicals in man.* Chicago and London: Year Book Medical Publishers, 1989:554–5.
3 Dowling GP, McDonough ET, Bost RO. 'Eve' and 'Ecstasy': a Report of five deaths associated with the use of MDEA and MDMA. *JAMA* 1987;**257**:1615–17.
4 Suarez RV, Riemersma R. 'Ecstasy' and sudden cardiac death. *Am J Forensic Medicine and Pathology* 1988;**9(4)**:339–41.
5 Fahal IH, Sallomi DF, Yacoub M, Bell GM. Acute renal failure after 'Ecstasy'. *BMJ* 1992;**305**:29.
6 Peroutka SJ. Incidence of recreational use of 3,4-methylenedimethoxymethamphetamine (MDMA, 'Ecstasy') on an undergraduate campus. *N Eng J Med* 1987;**317**:1542–43.
7 Cregler LL, Mark H. Medical complications of cocaine abuse. *N Eng J Med* 1986; 315:1495–500.
8 Gawin FH, Ellinwood EH. Cocaine and other stimulants: actions; abuse, and treatment. *N Eng J Med* 1988;**318**:1173–82.
9 Wojak JC, Flamm ES. Intracranial haemorrhage and cocaine use. *Stroke* 1987;**18**: 712–5.
10 Lichtenfeld PJ, Rubin DB, Feldman RS. Subarachnoid haemorrhage precipitated by cocaine snorting. *Arch Neurol* 1984;**41**: 223–4.
11 Henry JA, Jeffreys KJ, Dawling S. Toxicity and deaths from 3,4-methylenedioxymethamphetamine ("Ecstasy"). *Lancet* 1992;**340**:384–7.

Opsoclonus showing only during eye closure in hereditary cerebellar ataxia

Opsoclonus is an abnormal eye movement characterised by a burst of saccades in all directions without an intersaccadic interval. Opsoclonus only during eye closure, and opsoclonus in hereditary cerebellar ataxia, as in our case, have not been previously described.

A 34 year old man complained of gait disturbance and difficulty with fine finger movements. At the age of 28 he gradually noted a deterioration in his baseball playing skills. At the age of 30 he began to have difficulty in walking down stairs, and has since had to use a hand rail. He also experienced difficulty with handwriting and manipulating small objects, and when watching baseball he frequently lost sight of the ball. He had no history of alcohol abuse. On admission on 12 March 1990, physical examination revealed a scaphoid skull, high arched palate and small auricles. Neurological examination showed that he was mentally alert and cooperative. The pupils were equal, round and reacted to light. He had no limitation of eye movement, but there was a horizontal fine ocular oscillation during fixation. When he closed his eyes abnormal ocular movements were noted together with an upward deviation of the eyes (Bell's phenomenon). The eyes showed frequent irregular rapid conjugate oscillations in all directions. He had saccadic pursuit eye movement and ocular dysmetria. He had moderate to severe limb and gait ataxia, and ataxic dysarthria. There was no muscle atrophy or weakness. Tendon reflexes were normal and the plantar response was flexor. There were no involuntary movements, and no sensory nor autonomic disturbances.

Routine laboratory examinations for blood and urine were normal as were thyroid function and lysosomal enzyme assays. Peripheral nerve conduction studies and needle electromyography of limb muscles were also normal. Brain CT and MRI showed atrophy of the cerebellar vermis and upper hemisphere. EEG showed frontal dominant θ waves during hyperventilation. Electro-oculographic findings were as follows: square-wave jerks were noted during visual fixation, and its amplitude and frequency were increased in darkness. On closing the eyes irregular sharp waves without an intersaccadic interval appeared horizontally as well as vertically (fig). These spontaneous abnormal eye movements persisted during the voluntary eye closure, decreased in drowsy state, and disappeared during sleep. Smooth eye tracking test revealed saccadic pursuit which overlapped the square wave jerks. Saccadic latencies and speed were normal. Optokinetic pattern test showed poor increase of slow phase of nystagmus in both directions. Caloric test with cold water showed normal response with normal visual suppression.

A 29 year old man, a brother of the patient we have described, had no subjective complaints and no history of alcohol abuse. He was mentally alert, and the pupils were equally round and reacted to light. There was no limitation of eye movement and convergence was normal. Although there was no nystagmus, horizontal fine ocular oscillation was noted during fixation. On closing the eyes, abnormal irregular rapid conjugate oscillations in all directions were seen as in his brother. He had saccadic pursuit eye movement and ocular dysmetria. His speech was slightly dysarthric and

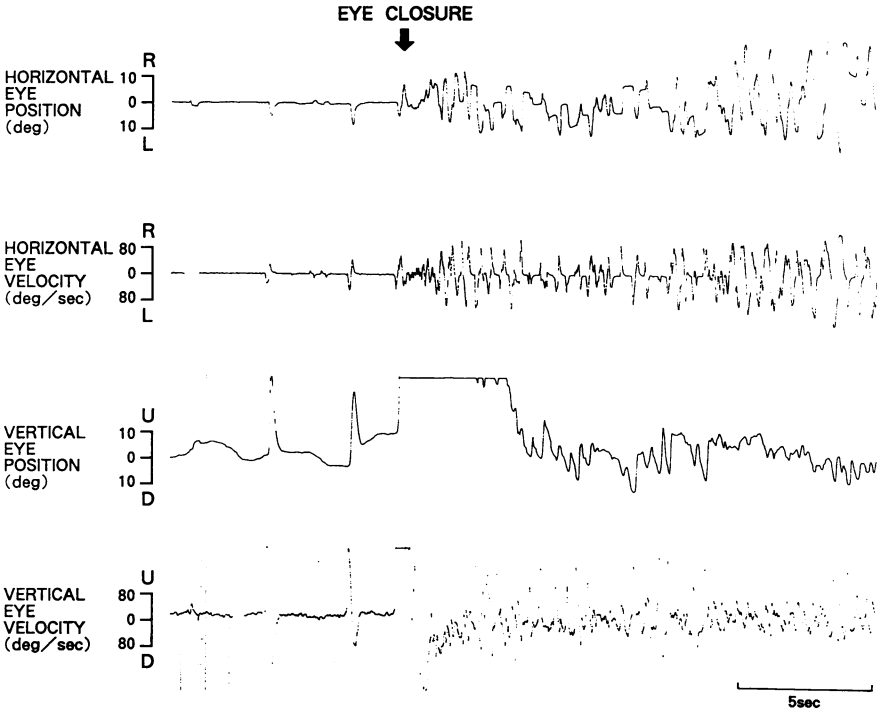

Figure Electro-oculography of the first case: showing opsoclonus only after eye closure.

Downloaded from http://jnnp.bmj.com/ on May 6, 2016 - Published by group.bmj.com

Subarachnoid haemorrhage associated with MDMA abuse.

J A Gledhill, D F Moore, D Bell and J A Henry

J Neurol Neurosurg Psychiatry 1993 56: 1036-1037
doi: 10.1136/jnnp.56.9.1036

Updated information and services can be found at:
http://jnnp.bmj.com/content/56/9/1036.citation

These include:

Email alerting service

Receive free email alerts when new articles cite this article. Sign up in the box at the top right corner of the online article.

Notes

To request permissions go to:
http://group.bmj.com/group/rights-licensing/permissions

To order reprints go to:
http://journals.bmj.com/cgi/reprintform

To subscribe to BMJ go to:
http://group.bmj.com/subscribe/