Downloaded from http://jnnp.bmj.com/ on May 6, 2016 - Published by group.bmj.com

Journal of Neurology, Neurosurgery, and Psychiatry 1995;**59**:448–454

LETTERS TO THE EDITOR

Improvement of Isaacs' syndrome after treatment with azathioprine

In Isaacs' syndrome, muscular cramps exacerbated by effort, stiffness, delay in muscle decontraction, myokymia, fasciculations, and excessive perspiration are associated with spontaneous repetitive electromyographic discharges. The peripheral origin of the neuromyotonic discharges has been accepted since Isaacs' first description,[1] but the exact aetiology remains obscure.

Sinha *et al* reported experimental arguments for an autoimmune process leading to quantitative reduction of the potassium channels on the axonal membrane.[2] Three patients have benefited from plasma exchange,[2 3] and three from azathioprine.[4] We report another favourable response to azathioprine.

A 36 year old patient was admitted in February 1991 with a five month history of progressive paraesthesia of all four limbs, diffuse painful cramps affecting distal muscles, and stiffness. He was regularly treated with insulin for diabetes diagnosed in 1983.

Examination showed delayed muscular relaxation of the masseter and limb muscles exaggerated by repetitive movements, without loss of strength or muscle hypertrophy. There were abolished tendon reflexes and palmar and plantar dysaesthesiae. Myokymia was seen in the interossei muscles of the hands. There was no sensory loss. Hyperhidrosis was noticed. The patient experienced episodes of transient diplopia. Ophthalmological examination disclosed a slight reduction of abduction of the left eye and horizontal nystagmus. Two days later, there was an impaired right eye elevation, but no longer any involvement of the left eye.

The following laboratory investigations were normal: serum electrolytes including calcium and magnesium, muscular enzymes, blood count, serum immunoglobulin concentrations, thyroid function tests, cortisol concentration AbA1c, tumour markers. Serum tests for HIV, CMV, EBV, hepatitis A, B, and C, *Borrelia burgdorferi*, echo, coxsackie, influenza, and parainfluenza were negative. IgG antibodies to HHV1, VZV, and measles were weakly positive. Tests for autoantibodies were negative including antinuclear, anti-DNA, antiskeletal muscle, antismooth muscle, antimitochondria, antithyroid, and antipancreatic islets. Analysis of CSF was normal, including cell count and immunoglobulin concentration. Sural nerve biopsy showed endoneurial oedema, a mild loss of myelinated fibres, narrowed myelin sheaths, and in some places, vacuolisation and partial unrolling of the myelin sheaths.

On 15 February an EMG examination, disclosed neuromyotonia predominantly in the distal muscles of the hands and the right extensorum digitorum brevis, with spontaneous activity arising at rest, in a pattern of brief bursts of repetitive motor unit discharges with high interspike frequencies. Stimulation of the nerves elicited these bursts, appearing after the M waves. Fibrillation and denervation activities were seen, particularly in the right extensorum digitorum brevis. Motor and sensory conduction velocities were normal; F responses were present with normal latencies but sometimes the abnormal discharges precluded their appearance.

Diagnosis of Isaacs' syndrome was made and treatment was begun with carbamazepine. An EMG on the next day showed reduction in number and duration of neuromyotonic bursts. In parallel, clinical improvement was notable with disappearance of paraesthesia and of the delayed muscle relaxation. Despite the beneficial effect of carbamazepine (600 mg/day), this drug had to be discontinued after a few days because of cutaneous allergic reaction. Phenytoin induced a similar allergic effect and was also discontinued. Azathioprine was begun in May 1991 (2·5 mg/kg). In September, painful stiffness of the hands and especially of the legs had clearly diminished. Hand paraesthesia and finger pulp hypaesthesia persisted, as well as some degree of neuromyotonia. An EMG in December 1991 showed improvement with persistence of neuromyotonic bursts only in the arms. An EMG in December 1992 showed almost complete disappearance of neuromyotonia. In April 1993, nearly two years after initiation of azathioprine treatment, there was a dramatic reduction of pains in the legs. Cramps persisted in the feet. Episodic diplopia had disappeared.

Since the initial two cases described by Isaacs,[1] some 40 cases have been reported[4] under various terms including neuromyotonia, pseudomyotonia, and continuous muscle fibre activity. This syndrome has been described in association with polyradiculoneuropathy, pulmonary small cell cencer, or thymoma, all affections associated with autoimmune processes.

Several mechanisms have been postulated to explain these spontaneous activities: ephaptic excitation, hyperexcitability of peripheral nerves or terminal motor axons, and neuromuscular junction disorders. The results of Sinha *et al* suggest that "an increase in neurotransmitter release might result from an antibody mediated reduction in the number of functional potassium channels that normally regulate nerve excitability."[2] Although carbamazepine (or phenytoin) remains the classic treatment for Isaacs' syndrome, a new therapeutic approach could be represented by immunomodulation plasma exchanges,[2-4] or immunosuppressors such as corticosteroids or azathioprine. Newsom-Davis *et al* used azathioprine in three cases,[4] but always in association both with corticoids or plasma exchange, and with carbamazepine or phenytoin. In one case, only plasma exchanges were of temporary efficacy; the two other patients improved at six and 18 months with prednisolone and azathioprine. Our patient also improved, albeit incompletely, with azathioprine as a sole treatment, and showed almost complete disappearance of EMG patterns of neuromyotonia. A peculiar feature of this syndrome is the possibility of full recovery in the absence of underlying neuropathy, but this should occur generally after several years of carbamazepine or phenytoin treatment. Moreover, the sural nerve biopsy in our patient showed pathological changes. Improvement could therefore probably be attributed to azathioprine.

Among their five patients, Newsom-Davis *et al* report the finding of antithyroid antibody in one, and a history of vasculitis in another.[4] In three patients, there was an IgG intrathecal synthesis with oligoclonal profile, as in the patient of Elalaoui-Faris *et al.*[5] We did not find any biological autoimmune abnormality in our patient and CSF analysis was normal. No CT of the thymus was undertaken. Nevertheless, the coincidence with insulin dependent diabetes could be a stigma of an autoimmune process.

G RICHE
P TROUILLAS
Service de neurologie B
B BADY
Service d'électromyographie, Hopital Neurologique, 59 Boulevard Pinel 69003, Lyon, France

Correspondence to: Professor P Trouillas, Service de Neurologie B, 59 Bd Pinel, 69003 Lyon, France.

1 Isaacs H. A syndrome of continuous muscle-fibre activity. *J Neurol Neurosurg Psychiatry* 1961;**24**:319–25.
2 Sinha S, Newsom-Davis J, Mills K, Byrne N, Lang B, Vincent A. Autoimmune aetiology for acquired neuromyotonia (Isaacs' syndrome) *Lancet* 1991;**338**:75–7.
3 Bady B, Chauplannaz G, Vial C, Savet JF. Autoimmune aetiology for acquired neuromyotonia. *Lancet* 1991;**338**:1130.
4 Newsom-Davis J, Mills KR. Immunological associations of acquired neuromyotonia (Isaacs' syndrome). Report of five cases and literature review. *Brain* 1993;**116**:453–69.
5 Elalaoui-Faris M, Ouahabi H, Slassi I *et al.* Syndrome d'Isaacs: rémission clinique après bolus de Méthylprednisolone. *Rev Neurol* 1993;**149**:426–7.

Hypomania after temporal lobectomy: a sequela to the increased excitability of the residual temporal lobe?

The occurrence of frank psychiatric illness after surgery has been a neglected topic until recently. It was not until the 1980s that a literature search showed scattered reports confirming the presence of overt psychoses, paranoid or schizophrenia-like in nature, arising for the first time after operation.[1] The description of postoperative hypomanic states was even more difficult to find. Until recently, workers agreed that hypomania was non-existent or exceptionally rare not only among new psychoses after temporal lobectomy but also among epileptic psychoses in general.[2] Here, I report a case of transient hypomania after temporal lobectomy for longstanding intractable complex partial seizures.

A 33 year old man with a history of rare generalised tonic-clonic seizures and intractable complex partial seizures since the age of 9 was admitted to our seizure monitoring unit for presurgical evaluation before temporal lobectomy. Brain MRI disclosed slight atrophy of the right hippocampus and interictal scalp EEG showed frequent right anterior temporal spikes. Because four ictal records of complex partial seizures with scalp EEG inclusive of sphenoidal electrodes had failed to provide definitive evidence of the side of origin of the seizures, depth electrodes, together with right sided subdural electrodes, were inserted. During the depth EEG study, four complex partial seizures and six simple partial seizures occurring as epigastric sensations were recorded. They were typical of the patient's habitual attacks. All of the 10

Downloaded from http://jnnp.bmj.com/ on May 6, 2016 - Published by group.bmj.com

ictal events confirmed the right hippocampal origin of the seizures.

Subsequently, temporal lobectomy was performed on 12 October and the right hippocampus was removed from the tip to 1·5 cm posteriorly. Ammon's horn sclerosis was confirmed in the excised tissue. Several days after the operation, however, he became increasingly euphoric and elevated in mood. His speech was raced. He incessantly interrupted conversations around him. He became a constant joker. At the 20th day after the lobectomy, this mood change culminated in sexual disinhibition and sporadic explosive behaviour, which necessitated a two week stay in a psychiatric hospital. Throughout this episode, which lasted about two months, he was alert and fully oriented and the EEG recordings showed frequent right temporal spikes. Four consecutive EEG documentations registered within three months after the lobectomy showed this elevated excitability in the right mid-temporal region. These spikes had disappeared completely by the next February when his mood was stabilised to the level of the presurgical period. No spikes were found in three further EEG recordings registered in the subsequent 12 months. No change in medication was made after the operation. His epilepsy was relieved after the operation. There was no history of psychiatric illness before the operation.

Depression has been one of the well known psychiatric manifestations after temporal lobectomy. Hill *et al*[3] noted in the late 1950s that aggressive acting out, one of the well recognised personality trends in a group of patients with temporal lobe epilepsy, was often switched to depressive seclusion after operation. They designated this replacement of preoperative aggressive hostility with postoperative depressive withdrawal as a "turning in" of aggression. By contrast with this longstanding recognition of postoperative depression, hypomanic states arising after temporal lobectomy do not seem to have been mentioned in the medical literature. Indeed, Mace *et al*[1] pointed out in a discussion on de novo psychoses that affective symptoms were most evident in those cases when they appeared early after surgery. Although this was also true of the affective psychosis in the current case because it appeared within a few days of the lobectomy, it should be noted that the affective symptoms in all the cases noted by Mace *et al*[1] were dominated not by elevated but by depressed moods. Reports of five cases with postictal hypomania by Barczak *et al*[4] and by Byrne[5] challenged the prevailing view that hypomania was not (or only scarcely) found in close relation to epilepsy. This case report of a hypomanic state as a de novo psychosis after operation is another example supporting the link between the hypomania and epilepsy.

An increased temporal spike activity concomitant with psychiatric symptoms was found in the current case. The clinical course of the hypomanic mood swing corresponded well with the fluctuation in the EEG findings. As long as the hypomania dominated the clinical setting, clusters of right mid-temporal spikes were recorded in the repeated EEG. This suggested that an increased excitability in the residual tissue immediately after the lobectomy may play some part in the genesis of postoperative psychoses. The short interval between the operation and the psychiatric manifestation also supported this view.

K KANEMOTO
Kansai Regional Epilepsy Centre, Utano National Hospital, Kyoto, Japan

Correspondence to: Dr Kousuke Kanemoto, Utano National Hospital, Ukyoku, Narutaki, Ondoyama-cho 8, Kyoto-fu, Kyoto-shi, Japan.

1 Mace CJ, Trimble MR. Psychoses following temporal lobe surgery: a report of six cases. *J Neurol Neurosurg Psychiatry* 1991;54: 639–44.
2 Wolf P. Manic episodes in epilepsy. In: Akimoto H, Kazamatsuri M, Seino M, eds. *The XIIIth epilepsy international symposium.* New York: Raven Press, 1982.
3 Hill D, Pond DW, Mitchell W, Falconer MA. Personality changes following temporal lobectomy for epilepsy. *J Ment Sci* 1957; 103:18–27.
4 Barczak P, Edmunds E, Betts T. Hypomania following complex partial seizures. *Br J Psychiatry* 1988;152:137–9.
5 Byrne A. Hypomania following increased epileptic activity. *Br J Psychiatry* 1988;153: 573–4.

Machado-Joseph disease mutations as the genetic basis of most spinocerebellar ataxias in Germany

Machado-Joseph disease is an autosomal dominant inherited neurodegenerative disorder pathologically characterised by neuronal loss and gliosis in the cerebellum (especially the dentate nucleus), the spinal cord (spinocerebellar tracts, anterior horn cells, posterior columns, and Clarke's columns) and to varying degrees in the substantia nigra, the subthalamic nuclei, cranial motor nuclei, and peripheral nerves. Clinically Machado-Joseph disease presents with a broad range of symptoms including variable combinations of cerebellar ataxia, pyramidal and extrapyramidal features, peripheral neuropathy, progressive external ophthalmoplegia, and faciolingual fasciculation.[1] Machado-Joseph disease was originally described in Portuguese-Azorean descendants and has rarely been encountered in ethnic groups other than Portuguese.[1] Up to now, no patients with the clinical diagnosis of Machado-Joseph disease have been reported in Germany. Recently, the Machado-Joseph disease gene locus has been mapped to chromosome 14q and the disease causing mutation has been identified as an unstable and expanded $(CAG)_n$ trinucleotide repeat.[2]

We investigated the Machado-Joseph disease mutation in 38 families with dominant cerebellar ataxias and in 21 patients with sporadic forms of ataxia of German ancestry. In 19 of 38 families an expanded trinucleotide repeat in the Machado-Joseph disease gene has been identified. Analysis of the $(CAG)_n$ repeat length and the age of onset disclosed an inverse correlation, with the longest repeats in patients with juvenile onset (figure). None of the sporadic patients carried the Machado-Joseph disease mutation indicating that new mutations occur rarely.

Prominent clinical features of the German patients with ataxia and bearing the Machado-Joseph disease mutation (table) included cerebellar symptoms such as ataxia of limbs, gait, and stance, dysarthria and cerebellar oculomotor disturbances, and a varying combination of dysphagia, spasticity, and peripheral neuropathy with amyotrophy and sensory loss. Characteristic signs of Machado-Joseph disease as described in patients of Portuguese or Japanese descent, such as dystonia, extrapyramidal rigidity, faciolin-

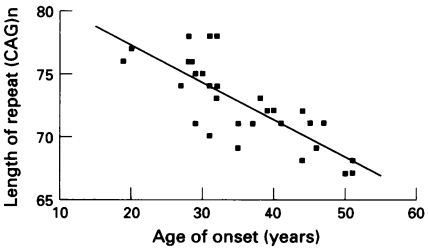

Correlation between the expanded (CAG)n repeat length in the Machado-Joseph disease gene and the age of onset in patients with spinocerebellar ataxia type 3/Machado-Joseph disease. The regression curve derives from the formula: trinucleotide size = 83·3 − 0·3 × age of onset (r = − 0·79, P = 0·00000025).

Clinical characteristics of patients with (SCA3), (MJD), and (SCA1)

	SCA3/MJD Germany†	MJD USA[4]	MJD Japan[5,6]	SCA3 France[3]	SCA1 Germany‡
No of families	19	?	1	2	4
No of patients	30	25	12	18	8
Age of onset (mean (SD)) (y)	37 (7)	36 (17)	31 (10)	33 (7)	37 (4)
(range) (y)	(19–51)	(10–64)	(20–44)	(20–47)	(32–47)
Disease duration (mean (SD)) (y)	12 (5)	12 (7)	11 (5)	10 (6)	8 (4)
Clinical signs (%):					
Cerebellar: gait ataxia	100	100	?	?	100
Limb ataxia and dysmetria	97	92	?	?	100
Dysarthria	90	96	?	?	100
Cerebellar oculomotor signs	93	96	?	?	88
Pyramidal: spasticity	57	52	?	?	50
Increased tendon reflexes	40b**	64f*	92h**	33	13
Extensor plantar responses	40	64f*	58	50	13
Extrapyramidal: rigidity	13	40	25	11	0
Dystonia	3a***,b***	36c*	67g**,h*	6	0
Amyotrophy	23	32	42g*	11	38
Decreased vibration sense	70a***,b***	36f**	8h***	44i*	100
Ophthalmoplegia	37	?	58	39	38
Faciolingual fasciculation	10a***,b***	56d*,e***	100g***,h*	0	25
Dysphagia	63	?	?	?	63
Dementia	10c*	?	8		25

*P < 0·05; **P < 0·01; ***P < 0·001 comparison of percentages with a corrected χ^2 test.
a: comparison between SCA3/MJD Germany and MJD USA; b: SCA3/MJD Germany and MJD Japan; c: SCA3/MJD Germany and SCA1 Germany; d: MJD USA and MJD Japan; e: MJD USA and SCA3 France; f: MJD USA and SCA1 Germany; g: MJD Japan and SCA3 France; h: MJD Japan and SCA1 Germany; i: SCA3 France and SCA1 Germany. †Data presented in this paper. ‡Schöls *et al*, unpublished data.

Downloaded from http://jnnp.bmj.com/ on May 6, 2016 - Published by group.bmj.com

Hypomania after temporal lobectomy: a sequela to the increased excitability of the residual temporal lobe?

K Kanemoto

J Neurol Neurosurg Psychiatry 1995 59: 448-449
doi: 10.1136/jnnp.59.4.448-a

Updated information and services can be found at:
http://jnnp.bmj.com/content/59/4/448.2.citation

These include:

Email alerting service

Receive free email alerts when new articles cite this article. Sign up in the box at the top right corner of the online article.

Notes

To request permissions go to:
http://group.bmj.com/group/rights-licensing/permissions

To order reprints go to:
http://journals.bmj.com/cgi/reprintform

To subscribe to BMJ go to:
http://group.bmj.com/subscribe/