Downloaded from http://jnnp.bmj.com/ on May 5, 2016 - Published by group.bmj.com

followed by administration of prednisolone (50 mg/day) and melphalan (6 mg for 10 days) each month with monthly intravenous injections of cyclophosphamide (300 mg). Thereafter, the patient showed gradual improvement in motor, respiratory, and renal functions (figure C; table). Four months after treatment, the tissue pressure of the quadriceps femoris in the supine position fell to 47 mm Hg. Serum IgA concentrations were consistently less than 200 mg/dl. There were no serious side effects of DMSO and an unpleasant breath odour was the patient's main concern. Nine months after treatment, we noted a levelling off or a slight decline in some variables. Sixteen months after treatment, the patient aspirated his secretions and died.

AL-amyloidosis results from conversion by proteolysis of monoclonal light chains into twisted β-pleated sheet fibrils,[4] which can be recognised by Congo red staining. Light chain deposition disease is another pathological state associated with plasma cell dyscrasia.[5] In our patient with IgA λ plasma cell dyscrasia and skeletal muscle pseudohypertrophy, simultaneous deposition of AL-amyloid and λ light chains[5] were shown by amyloid staining, immunohistochemistry, and electron microscopy.

Precise mechanisms for physical disability in amyloid associated muscle pseudohypertrophy remain unclear. Most attention to date has been directed toward the weakness.[1] A possible factor causing motor impairment in our patient was a decreased range of motion, predominantly affecting proximal joints. Involvement of shoulder joints showing "shoulder pad sign" is pathognomonic of amyloidosis.[4] Another factor hampering mobility is increased muscle tissue pressure reflected as wooden firmness. Increased muscle pressure is not produced by amyloid infiltration alone[1] but may be related to deposition of chondroitin-4-sulphuric acid and silicon in muscles,[2] tense muscle fascia secondary to amyloid deposition, or impaired tissue perfusion by amyloid angiopathy. The pressure is further increased by muscle activity to the point that it interferes with muscle blood flow.

The goal of treatment in amyloidosis is to prevent further deposition of amyloid and to promote its resorption. In our patient, plasmapheresis and DMSO treatment resulted in an appreciable level of improvement in motor, respiratory, and renal functions. The ability of DMSO to make amyloid fibrils soluble for digestion has been demonstrated.[4] Amyloid/light chain-derived materials dislodged from various organs are likely to impair renal function. Therefore, to remove these breakdown products and the precursor monoclonal immunoglobulins, plasmapheresis was combined with DMSO. Because of the grave prognosis and disabling symptoms of amyloid associated muscle pseudohypertrophy, a trial of plasmapheresis and DMSO may be warranted even though the improvement may be moderate and of limited duration.

A KOMIYAMA
Department of Neurology, Yokohama City University School of Medicine, Yokohama, Japan,
M KIJIMA
M TAKAHASHI
Department of Neurology, Chiba Rousai Hospital, Ichihara, Japan
S ISHIDA
Y ONO
Department of Rehabilitation Medicine, Chiba Rousai Hospital, Ichihara, Japan

Correspondence to: Dr Atsushi Komiyama, Department of Neurology, Yokohama City University School of Medicine, 3–9 Fukuura, Kanazawa-ku, Yokohama, Japan.

1 Whitaker JN, Hashimoto K, Quinones M. Skeletal muscle pseudohypertrophy in primary amyloidosis. *Neurology* 1977;**27**:47–54.
2 Miyasaki K, Murao S, Tsunetoshi S, *et al.* Primary systemic amyloidosis. A case permitting pathological and biochemical investigations. *Acta Pathol Jpn* 1979;**29**:157–69.
3 Whitesides TE Jr, Haney TC, Harada H, Holms HE, Morimoto K. A simple method for tissue pressure determination. *Arch Surg* 1975;**110**:1311–3.
4 Glenner GG. Amyloid deposits and amyloidosis. The β-fibrilloses. *N Engl J Med* 1980; **302**:1283–92;1333–43.
5 Jaquot C, Saint-Andre JP, Touchard G,*et al.* Association of systemic light-chain deposition disease and amyloidosis: a report of three patients with renal involvement. *Clin Nephrol* 1985;**24**:93–8.

Opsoclonus, a rare complication of cocaine misuse

Opsoclonus is a rare eye movement disorder, mostly seen in postviral encephalopathy or occult neuroblastoma in children, or as a paraneoplastic phenomenon in adults. It rarely occurs after giving drugs or toxins. A single report of the opsoclonus-myoclonus syndrome in association with cocaine use has been described in this *Journal*.[1] We present a patient with opsoclonus, myoclonus, and ataxia after taking cocaine.

A 29 year old man was admitted to hospital with vertigo, nausea, and vomiting. He was unable to stand and walk, because his legs were shaking. The first symptoms had occurred 18 days earlier, after taking cocaine, with paroxysmal vertigo which became continuous the next day, then progressive shaking of the legs, and finally of the whole body. The patient did not complain of headache. There was no weight loss, fever, or recent infectious disease. There was a medical history of migraine and hyperventilation. He admitted heroin misuse until eight years ago and incidental cocaine misuse in recent years. The patient took 10 mg diazepam daily because of nervousness but no other drugs. Since the appearance of nausea he used 6·5 mg thiethylperazine a day.

General examination showed no abnormalities. Neurological examination showed normal consciousness and there was no evidence of nuchal rigidity. The optic fundi could not be examined because of intermittent involuntary eye movements. The pupil reactions were normal, as were the visual fields. There were continuously intermittent conjugated nystagmoid beats in all directions, often finishing with a circumduction movement. The abnormal eye movements increased under the influence of stress. The patient had a trembling voice and slight myoclonic jerks of his head and neck. He was unable to stand and walk because of vertigo and ataxia. When sitting he showed a disequilibrium. There was no other neurological deficit.

Blood and CSF examination were normal except for a slightly raised CSF protein (0·72 g/l). Viral serologies were negative. Electrocardiography, chest radiography, brain CT and MRI, EEG, and brainstem auditory evoked potentials were normal. Electro-oculography at fixation in different directions showed crescentiform eye movements with a short rotation at the end of the movement. With the eyes closed there were coarse eye movements in all directions with a frequency of 8 Hz. The abnormal eye movements were seen in superposition of normal eye movements.

During his stay in hospital the disequilibrium gradually improved. The opsoclonus changed to flutter-like oscillations. After a few weeks oculomotor examination showed only sporadic horizontal ocular myoclonus in vertical movements. Follow up four months after his admission to the hospital yielded no oculomotor abnormalities or ataxia and the patient stated that he felt perfectly well.

In our patient opsoclonus was very likely associated with taking cocaine. After extensive diagnostic evaluation no other cause could be found. The disorder appeared after incidental misuse of cocaine and was self limiting. One other such patient was described by Scharf.[1]

Various neurological complications of cocaine are known. Neurovascular disorders, either haemorrhagic or ischaemic, can occur after taking the drug.[2] Seizures and migraine are other neurological complications. Interestingly, increases in brain serotonin by inhibition of its uptake is an effect of cocaine. Maybe our patient, who had migraine, was more sensitive to this effect of cocaine, as serotonergic dysfunction has been reported in patients with migraine. The lack of any anatomical substrate supports this. On the other hand, a direct toxic effect of cocaine or one of its accompanying substances cannot be ruled out.

YAL ELKARDOUDI-PIJNENBURG
AGM VAN VLIET
Academical Hospital VU, Department of Neurology, PO Box 7057, 1007 MB Amsterdam, The Netherlands

1 Scharf D. Opsoclonus-myoclonus following the intranasal usage of cocaine. *J Neurol Neurosurg Psychiatry* 1989;**52**:1447–8.
2 Levine SR, Washington JM, Moen M, Kieran SN, Junger S, Welch KM. "Crack" cocaine-associated stroke. *Neurology* 1987;**37**: 1092–3.

Further evidence of increased risk of mortality from Parkinson's disease

It is often considered that since the introduction of levodopa treatment, there has been little difference in mortality from Parkinson's disease compared with the general population.[1] However, to date, only three studies have investigated the mortality in a group of patients with Parkinson's disease compared with a matched control group. Rajput *et al*, in their review of case notes, found a mortality for patients with Parkinson's disease 1·6 times that of controls,[2] and the community based prospective case-control survey of Ebmeier *et al* in Aberdeen found a 2·35-fold higher death rate.[3] In a recent issue of this *Journal*, Ben-Shlomo and Marmot published the results of a long term community based prospective survey showing a 2·6-fold increased risk of mortality for Parkinson's disease.[4] We report the results of a prospective population based survey of subjects aged 65 and over that provides further evidence of increased mortality due to Parkinson's disease.

The population studied was a representative, randomly selected sample of 2792 subjects, aged 65 and over, living at home in Gironde, France (PAQUID study), composed of 1122 men (40·2%) and 1670

Downloaded from http://jnnp.bmj.com/ on May 5, 2016 - Published by group.bmj.com

women (59·8%), mean age 74·9 (range 65–101) years.[5] Prevalent cases of Parkinson's disease were ascertained in this population during 1988 (time 0) with a two phase design (home interview then neurological evaluation), as described elsewhere.[6] The diagnosis of Parkinson's disease was reached on the basis of the presence of at least two cardinal signs—typical history and drug response—and exclusion of other conditions such as drug induced parkinsonism, parkinsonism associated with cerebrovascular disease, and parkinsonism associated with other neurodegenerative diseases.[6] The population was then studied again, five years later during 1993 (time 5), with the same procedure. The proportion of prevalent cases of Parkinson's disease deceased at time 5 was compared with that of subjects without Parkinson's disease (χ^2 test).

To take into account the different age structure between the Parkinson's disease group and the group without the disease, we calculated the standardised mortality ratio (SMR). The SMR compares the observed number of deaths in the Parkinson's disease cohort with an expected number obtained by applying the age specific SMRs to the Parkinson's disease cohort age structure. In addition, we calculated the annual mortality for age groups 65–74, 75–84, and 85 and over, in prevalent cases of Parkinson's disease and subjects without Parkinson's disease, by dividing the number of deaths by the number of person-years in each age group.

The number of prevalent cases of Parkinson's disease at time 0 was 24 (2768 for the subjects without the disease).[6] The mean age of cases of prevalent Parkinson's disease was 78·54 years (SD 6·73) and 74·92 (SD 6·98) for the non-Parkinson's disease population. At time 5, 16 cases of Parkinson's disease (67%) and 605 subjects without the disease (22%) were deceased. The mean age at death of patients with Parkinson's disease was 82·1 years (SD 7·63) and 82·3 (SD 7·44) for the population without the disease. The difference in number of deaths was highly significant (χ^2 = 27, P < 0·0001) and the SMR was 3·43 (95% confidence interval (95% CI) 1·96–5·58). An excess of deaths in cases of Parkinson's disease occurred in each age group (table).

These results provide further evidence of increased mortality due to Parkinson's disease compared with the general population by studying an unselected population based cohort. The risk of mortality due to Parkinson's disease was about three times that of the population without the disease and was not explained by an effect of age. Our results are similar to those of Ebmeier *et al*[3] and Ben Shlomo and Marmot,[4] and provide further evidence of a greater than twofold increased risk of mortality for patients with Parkinson's disease. However, our results concern subjects aged 65 and over and living at home, thus omitting younger subjects and those living in institutions. A follow up study of subjects living in institutions is being undertaken.

Annual mortality (%) calculated for each age group for prevalent cases of Parkinson's disease and other subjects of the cohort without Parkinson's disease (controls)

	Age group (y)		
	65–74	75–84	> 85
Parkinson's disease (n = 24)	25	12·5	29·4
Controls (n = 2768)	2·5	3·6	10·7

F TISON
Département de Neurologie, Hôpital Pellegrin
L LETENNEUR
F DJOSSOU
JF DARTIGUES
Unité Inserm 330, Université de Bordeaux II, Bordeaux, France

Correspondence to : Dr F Tison, Département de Neurologie, Hôpital Pellegrin, Place Amélie Raba-Léon, 33076 Bordeaux Cedex, France.

1 Hoehn MMM. Parkinson's disease: progression and mortality. In Yahr MD, Bergmann KJ, eds. *Advances in neurology*, New York: Raven Press, 1986:457–61.
2 Rajput AH, Offord KP, Beard CM, Kurland LT. Epidemiology of parkinsonism: incidence, classification and mortality. *Ann Neurol* 1984;**16**:278–82.
3 Ebmeier K, Calder SA, Crawford JR, Stewart L, Besson JAO, Mutch WJ. Parkinson's disease in Aberdeen: survival after 3·5 years. *Acta Neurol Scand* 1990;**81**:294–99.
4 Ben-Shlomo Y, Marmot MG. Survival and cause of death in a cohort of patients with parkinsonism: possible clues to aetiology? *J Neurol Neurosurg Psychiatry* 1995;**58**:293–99.
5 Dartigues JF, Gagnon M, Barberger-Gateau P, *et al*. The PAQUID epidemiological program on brain ageing. *Neuroepidemiology* 1992;**11** (suppl 1):14–18.
6 Tison F, Dartigues JF, Dubes L, Zuber M, Alpérovitch A, Henry P. Prevalence of Parkinson's disease in the elderly: a population based study in Gironde, France. *Acta Neurol Scand* 1994;**90**:111–15.

Severe tick borne encephalomyelitis after tick bite and passive immunisation

Tick borne encephalitis is a flavivirus infection which is transmitted by ticks and only rarely results in severe neurological deficits in patients in central or northern Europe.[1] The necessity of passive immunisation after a single tick bite remains controversial as a protective effect can only be achieved in 60% of patients.[2] We report a 32 year old patient who developed serious tick borne encephalitis after a single tick bite, despite passive immunisation.

A previously healthy 32 year old man was bitten by a tick during a vacation trip in southern Germany. He was passively immunised with 9 ml (0·9–1·53 g) of tick borne encephalitis immunoglobulin given intramuscularly 24 hours later. Twelve days later, he complained of high fever and severe headache. On admission to hospital, he presented moderate meningeal rigidity and moderate flaccid paresis of both arms. One week later he became comatose for six weeks. Complete flaccid tetraparesis with diminished tendon reflexes and a slight facial palsy were noted. In addition, he had severe facial myoclonic fits with pronounced hypersalivation. During a 15 month follow up period the initial locked in-like state ameliorated moderately. Finally, he was able to speak single words. Comprehension seemed to be only slightly affected. Tetraplegia persisted but there were minimal movements in the left arm. Pronounced generalised atrophy developed, and later on, spasticity on the right side. The sensory pathway seemed to be undamaged.

Examination of the CSF initially disclosed a pleocytosis of 380 lymphocytes, which became normal within eight weeks. Later on, several oligoclonal bands and a temporary increase in protein to a maximum of 8 g/l were seen. The diagnosis of tick borne encephalitis was verified with titre ratios of tick borne encephalitis specific IgM/IgG in serum and CSF. Infections with *Borrelia burgdorferi* were excluded. An EEG showed severe and generalised slowing, which recovered over time. Electromyography showed severe generalised spontaneous activity.

Magnetic resonance imaging disclosed bilateral hyperintense signals with accentuation in the thalamic area on T2 and proton weighted analysis 10 days after onset of the illness (figure). Further disseminated lesions were present in the left striatum, insular cortex, tegmental mesencephalic area, raphe nuclei of the pons, and left inferior olive. Slight haemorrhagic infarction of the thalamus and striatum and discrete gadolinium enhancement were seen on MRI after 12 weeks. Three months later, MRI showed clear regression of the lesions, and a pronounced cerebellar and moderate cerebral atrophy, especially in the frontotemporal lobes.

Tick borne encephalitis is a rare disease which comes about after flaviviruses are transmitted via tick bites. Around 60–70% of tick borne encephalitis infections go unnoticed. Influenza-like symptoms appear in 20–30% of patients after a latency phase of several days. Only 10% of patients have neurological symptoms. Residual deficits are found in up to 10% of the victims and about 1% die. In a few necropsy reports on fatal tick borne encephalitis, polioencephalomyelitis with a prominent thalamic involvement has been recorded.[3 4] Other affected sites have been found in the brain stem (especially the tegmentum, red nucleus, substantia nigra, and inferior olive), the cerebellum, the basal ganglia, and the anterior horns of the cervical and thoracic spinal cord. The polioencephalitic lesions, detected on MRI in our patient, corresponded well with the known pathological accounts. Similar MRI abnormaliites have been seen in the flavivirus induced Japanese encephalitis,[5] but have not been reported in tick borne encephalitis as far as we know. The mostly flaccid tetraparesis seems to result from anterior horn affliction, as was suggested by electrophysiological examination.

There is no known specific treatment. For prophylactic purposes an inactivated vaccine can be used for active immunisation, which provides adequate protection in 97% of patients. Adverse side effects, such as myeloencephalitis and focal neuritis, have been described after active immunisation.[6] Passive immunisation with a tick borne

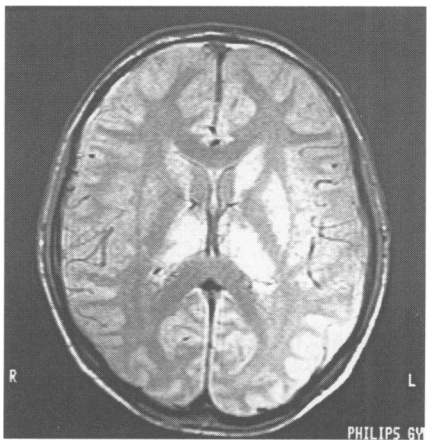

Proton weighted MRI with hyperintense signals in both thalami and in the striatum five weeks after the onset of the disease.

Downloaded from http://jnnp.bmj.com/ on May 5, 2016 - Published by group.bmj.com

Further evidence of increased risk of mortality of Parkinson's disease.

F Tison, L Letenneur, F Djossou and J F Dartigues

J Neurol Neurosurg Psychiatry 1996 60: 592-593
doi: 10.1136/jnnp.60.5.592-a

Updated information and services can be found at:
http://jnnp.bmj.com/content/60/5/592.2.citation

These include:

Email alerting service

Receive free email alerts when new articles cite this article. Sign up in the box at the top right corner of the online article.

Notes

To request permissions go to:
http://group.bmj.com/group/rights-licensing/permissions

To order reprints go to:
http://journals.bmj.com/cgi/reprintform

To subscribe to BMJ go to:
http://group.bmj.com/subscribe/