

Evidence for case-to-case transmission of Creutzfeldt-Jakob disease

RG WILL, WB MATTHEWS

From the University Department of Clinical Neurology, The Radcliffe Infirmary, Oxford

SUMMARY Three cases of probable iatrogenic transmission of Creutzfeldt-Jakob disease by neurosurgery are detailed together with a cluster of three cases in Eastern England possibly connected by dental procedures, and the development of Creutzfeldt-Jakob disease in a patient who had been in social contact with a familial case.

Creutzfeldt-Jakob disease (CJD) is transmissible in the laboratory to a range of mammalian hosts by a variety of inoculation routes¹ and can be transmitted to primates by the ingestion of infected tissue.² Kuru, another transmissible spongiform encephalopathy, was almost certainly spread by the custom of ritual cannibalism.³ It is therefore important to consider the possibility of natural transmission of Creutzfeldt-Jakob disease. In the course of a study of the epidemiology of the disease in mainland UK, a number of instances of possible case-to-case transmission have been encountered.

IATROGENIC TRANSMISSION

The high incidence of previous neurosurgical procedures in the series of patients with Creutzfeldt-Jakob disease described by Nevin *et al*⁴ has been noted previously.⁵ Examination of the case notes of the patients suggests that iatrogenic transmission occurred on three occasions. Two patients (cases 5 and 7 in Nevin *et al*'s⁴ report) were diagnosed in the same hospital and died in 1956 and 1957 respectively. The operating list for 3 February 1956 shows that case 5 was first on the list, having burrholes for ventriculography. This patient died the next day of pathologically confirmed Creutzfeldt-Jakob disease. Case 7 was third on the list and had a cortical undercut for longstanding obsessional neurosis. The operation was a success and the patient remained well until September 1957 when she was readmitted with a six-week history of progressive dementia. Brain biopsy was carried out and Creutzfeldt-Jakob disease was confirmed histologically. The patient died on 13 September 1957.

Address for reprint requests: Dr RG Will, Department of Clinical Neurology, The Radcliffe Infirmary, Oxford OX2 6HE, UK.

Received 25 September 1981. Accepted 8 October 1981

In January 1952 two patients (cases 1 and 2 in Jones and Nevin's report of 1954⁶) were admitted to another hospital for investigation of rapidly progressive dementia and died on 12 January 1952 and 19 January 1952 respectively of pathologically proven Creutzfeldt-Jakob disease. Case 1 had burrholes for ventriculography on 31 December 1951 and insertion of depth electrodes on 10 January 1952. Within two weeks two other patients in the second series (cases 1 and 2 in Nevin *et al*'s report of 1960⁴) had neurosurgical procedures in the same theatre, almost certainly using common instruments. Case 1 had burrholes for ventriculography on 23 January 1952 and craniotomy for excision of a meningioma on 30 January 1952. Case 2 had craniotomy for excision of abscess on 16 January 1952. Case 1 was readmitted 19 months later with a 4 week history of progressive dementia and died in October 1953 of pathologically proven Creutzfeldt-Jakob disease. Case 2 was readmitted on 17 November 1953 with a twelve week history of progressive dementia and died on 25 November 1953 of pathologically proven Creutzfeldt-Jakob disease.

Two other cases with a previous history of neurosurgical procedures and subsequent development of Creutzfeldt-Jakob disease have been discovered, but in neither case was a link with other patients found. The first patient had burrholes for ventriculography in August 1952 in the course of investigation of a suspected cerebrovascular accident, and remained well until October 1954 when she was readmitted with rapidly progressive dementia. She died on 15 November 1954 of pathologically confirmed Creutzfeldt-Jakob disease. The second patient had posterior fossa decompression in 1969, syringostomy in 1976 and became progressively demented shortly after further syringostomy in July 1978. She became mute and developed myoclonus, and EEGs were typical of Creutzfeldt-Jakob disease. She died on

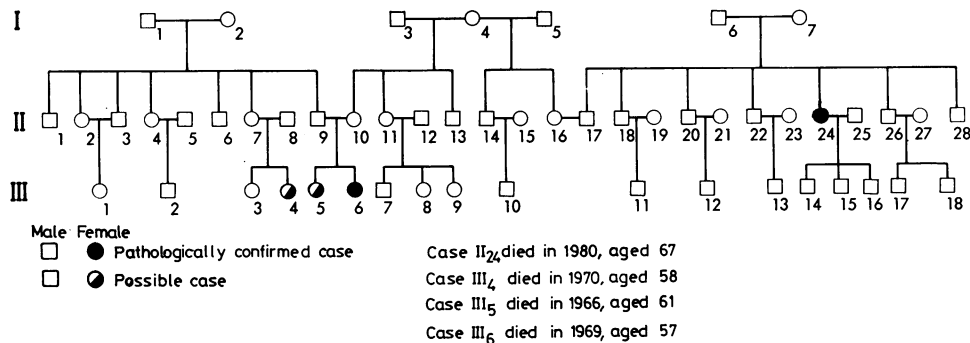


Figure Pedigree of the family described. A solid circle indicates a pathologically confirmed case and a hatched circle a clinically possible case of Creutzfeldt-Jakob disease. Case II₂₄ died in 1980 aged 67, Case III₄ died in 1970 aged 58, Case III₅ died in 1966 aged 61 and case III₆ died in 1969 aged 57.

3 January 1979, but postmortem examination was not carried out.

SPATIO-TEMPORAL CLUSTER

In 1965 a patient died of Creutzfeldt-Jakob disease, confirmed at necropsy. In 1968 a patient who lived within 250 m also died of the disease. These two patients shared the same general practitioner but unfortunately it has been impossible to examine the medical records which have been destroyed. In 1980 a patient who lived midway between the two previous patients and within sight of both houses died of pathologically proven Creutzfeldt-Jakob disease. This last patient worked as a dentist from 1950-1977 and used his house as a surgery. The dental records have been examined but are incomplete and do not include either of the two previous patients. It has been impossible to obtain details of dental history by other means, and the possibility that the patients were treated by the dentist cannot be further explored.

CONTACT WITH FAMILIAL CASES

A patient who died in 1980 of pathologically confirmed Creutzfeldt-Jakob disease had previous social contact with a group of three cases representing a familial cluster. Clinical details of two of the familial cases are scanty, and in all three cases the duration of the illness is more prolonged than usual in this disease, but in the third case pathological confirmation of the diagnosis was obtained (see figure).

Case III.4 The patient presented in January 1969 with a four week history of forgetfulness and bizarre behaviour. She was found to be demented but neurological examination was not carried out. Investigation revealed no abnormality although EEG was not obtained. The patient became progressively mentally impaired and by

December 1969 was mute and incontinent. She remained inaccessible with "tremulous movements of the limbs" until she died of hypostatic pneumonia on 15 August 1970. Necropsy was not performed.

Case III.5 The patient presented in 1965 with a three month history of drowsiness, forgetfulness and frontal headache. On examination she was demented and pneumoencephalography showed mild cortical atrophy. In July 1966 the patient was admitted for permanent care. She was severely demented, inaccessible and incontinent with rigidity of the limbs. She deteriorated and died in December 1966 of bronchopneumonia. Necropsy was not performed.

Case III.6 The patient presented in 1966 with intellectual deterioration and progressive dysphasia. By July 1968 she was incontinent and unable to dress or feed herself. By August she was unable to respond to simple commands and there was generalised hypertonia and hyper-reflexia, an extensor left plantar response and bilateral grasp reflexes. She deteriorated and died on 9 February 1969 of pneumonia. Necropsy was carried out at the Maudsley Hospital. Histology showed cortical atrophy with loss of nerve cells, spongy change and some astrocytic proliferation, extensive in the frontal lobe and patchy in the temporal lobe. Spongy change and gliosis were also present in the caudate lobe and medial part of the thalamus, and gliosis in the putamen. There was pallor and wasting of the white matter in the anterior parts of the hemispheres. The medial parts of the basis pedunculi showed wasting and gliosis as did the cortico-spinal tracts in the pons and the pyramids. A diagnosis of Creutzfeldt-Jakob disease was made.

Case II.24 The patient was admitted on 7 February 1980 with a two month history of progressive confusion and forgetfulness. On examination she was demented, dysphasic and unco-operative. On 13 February 1980 she developed myoclonus and rigidity of the limbs. Her condition rapidly deteriorated with the development of akinetic mutism and decorticate posturing. EEG was suggestive of Creutzfeldt-Jakob disease. The patient died

of pneumonia on 29 April 1980. Postmortem examination revealed generalised spongiform change and gliosis typical of Creutzfeldt-Jakob disease.

The figure shows the relationship between the patients. Cases III.5 and III.6 were sisters and case III.4 their first cousin. The sisters lived in the same house until their early twenties and case III.6 had close social contact with her cousin III.4 in her teens and early twenties, meeting regularly, holidaying together and working in the same factory. III.6 visited her cousin regularly during her last illness. Case II.24, who was related by marriage but with no consanguinity, knew III.6 socially for 20 years, meeting about twice a year for afternoon tea and at family gatherings. They continued to meet during III.6's final illness, and II.24 visited her during her final admission, the last occasion in August 1968, five months prior to death.

Discussion

The possible iatrogenic transmission of Creutzfeldt-Jakob disease by neurosurgery, corneal transplantation and stereotactic electrodes has been suggested in the past.^{5 7 8} This paper describes the close temporal relationship of neurosurgical procedures on two affected patients and three patients, unaffected at the time but who subsequently developed the disease. It provides strong circumstantial evidence of iatrogenic transmission by neurosurgery. Although sterilisation procedures have improved since the cases described, the unusual resistance of the agent¹ and the recent description of probable neurosurgical transmission in France⁹ suggest that there is a continued risk of accidental transmission. However, brain biopsy to confirm the diagnosis of Creutzfeldt-Jakob disease is now an unusual event and computed tomography has obviated the necessity for ventriculography.

In the close geographical group of three cases possible modes of transmission can be suggested, either iatrogenic or through dental procedures, but these must remain conjectural. It is known, however, that the similar scrapie agent can be transmitted from the gums in animals.¹⁰ Such close spatial clustering of cases is extremely unusual, being previously reported by Matthews,¹¹ but not detected even in the study of the epidemiology of Creutzfeldt-Jakob disease in urban Paris, where the incidence was found to be relatively high.¹²

The occurrence of the disease in a patient who had contact with cases of familial Creutzfeldt-Jakob disease but was not genetically related has been described in Chile and France.^{13 14} In Chile the patient was related by marriage but with no consanguinity and had social contact with subsequently affected family members for 13 years before developing the disease. The contact case in France (Brown, personal communication) also married into a family

in which Creutzfeldt-Jakob disease was prevalent and had close contact with an affected member. In neither instance did the spouse of the non-familial case have the disease. The case described in this report was similarly related to affected family members and social contact had occurred for 20 years prior to developing Creutzfeldt-Jakob disease. If contact transmission had occurred, the minimum incubation period would be 11 years. Contact between sporadic cases has not been described and it is remarkable that possible "contact" transmissions have all been with familial cases.

The pedigrees of families with Creutzfeldt-Jakob disease immediately suggest dominant inheritance but it has not been possible to distinguish with certainty between genetic and contact transmission.¹⁵ It is possible to calculate, however, that if case-to-case transmission occurs in these families, the incubation period must extend to 40 years.¹⁵ No method of transmission by casual social contact has been suggested. The occurrence of contact cases raises the possibility that transmission in families may be effected by an unusually virulent strain of agent.

Known examples of iatrogenic transmission of Creutzfeldt-Jakob disease have all involved actual or presumed implantation of tissue into brain or eye. In most cases of the disease no such opportunities of infection are found, but it remains unknown whether minor medical or dental procedures, or even simple contact, could also effect transmission. If so, a prolonged incubation period, perhaps extending over decades as in kuru,³ would render the detection of the means of transmission in individual patients inordinately difficult.

We acknowledge the co-operation of Dr R Hierons, Dr AH Roberts, Mr JR Bartlett, Dr R Doshi, Dr I Janota, Dr KWG Heathfield, Dr RA Henson and Professor V Logue.

References

- Gajdusek DC, Gibbs CJ. Unconventional viruses causing the spongiform encephalopathies: a fruitless search for the coat and core. In: Kurstak E, Maramorosch K, eds. *Viruses and Environment*. New York: Academic Press, 1978:79-98.
- Gibbs CJ, Amyx HL, Bacote A, Masters CL, Gajdusek DC. Oral transmission of Kuru, Creutzfeldt-Jakob disease and Scrapie to non-human primates. *J Infect Dis* 1980;**142**:205-8.
- Alpers MP. Epidemiology and Ecology of Kuru. In: Prusiner SB, Hadlow WJ, eds. *Slow Transmissible Diseases of the Nervous System*. New York: Academic Press, 1979;1:67-90.

- ⁴ Nevin S, McMenemy WH, Behrman S, Jones DP. Subacute spongiform encephalopathy—a subacute form of encephalopathy attributable to vascular dysfunction (spongiform cerebral atrophy). *Brain* 1960;**83**:519-64.
- ⁵ Masters CL, Harris JO, Gajdusek DC, Gibbs CJ, Bernouilli C, Aster DM. Creutzfeldt-Jakob disease: Patterns of worldwide occurrence and the significance of familial and sporadic clustering. *Ann Neurol* 1979;**5**:177-88.
- ⁶ Jones DP, Nevin S. Rapidly progressive cerebral degeneration (subacute vascular encephalopathy) with mental disorder, focal disturbances and myoclonic epilepsy. *J Neurol Neurosurg Psychiatry* 1954;**17**:148-59.
- ⁷ Duffy P, Wolf J, Collins G, Devoe A, Streeten B, Cowen D. Possible person-to-person transmission of Creutzfeldt-Jakob disease. *New Engl J Med* 1974;**290**:692-3.
- ⁸ Bernouilli C, Siegfried J, Baumgartner G *et al*. Danger of accidental person-to-person transmission of Creutzfeldt-Jakob disease by surgery. *Lancet* 1977;**1**:478-9.
- ⁹ Foncin JF, Gaches J, Cathala F, El Sherif E, Le Beau J. Transmission iatrogène interhumaine possible de maladie de Creutzfeldt-Jakob avec atteinte des grains du cervelet. *Rev Neurol (Paris)* 1980;**136**(3): 280.
- ¹⁰ Adams DH, Edgar WM. Transmission of agent of Creutzfeldt-Jakob disease. *Br Med J* 1978;**1**:987.
- ¹¹ Matthews WB. Epidemiology of Creutzfeldt-Jakob disease in England and Wales. *J Neurol Neurosurg Psychiatry* 1975;**38**:210-13.
- ¹² Cathala F, Brown P, Buge A, Lhermitte F, Castaigne P, Gajdusek DC. Epidémiologie de la maladie de Creutzfeldt-Jakob dans la région Parisienne. *Rev Neurol (Paris)* 1978;**134**/12:741-50.
- ¹³ Galvez S, Masters C, Gajdusek DC. Descriptive epidemiology of Creutzfeldt-Jakob disease in Chile. *Arch Neurol* 1980;**37**:11-14.
- ¹⁴ Brown P, Cathala F, Gajdusek DC. Creutzfeldt-Jakob disease in France III: Epidemiological study of 170 patients dying during the decade 1968-1977. *Ann Neurol* 1979;**6**:438-46.
- ¹⁵ Masters CL, Gajdusek DC, Gibbs CJ, Bernouilli C, Asher DM. Familial Creutzfeldt-Jakob disease and other familial dementias: an inquiry into possible modes of transmission of virus-induced familial disease. In: Prusiner SB, Hadlow WJ, eds. *Slow Transmissible Diseases of the Nervous System*. New York: Academic Press, 1979;**1**:143-94.



Evidence for case-to-case transmission of Creutzfeldt-Jakob disease

RG Will and WB Matthews

J Neurol Neurosurg Psychiatry 1982 45: 235-238
doi: 10.1136/jnp.45.3.235

Updated information and services can be found at:
<http://jnp.bmj.com/content/45/3/235>

Email alerting service

These include:

Receive free email alerts when new articles cite this article. Sign up in the box at the top right corner of the online article.

Notes

To request permissions go to:
<http://group.bmj.com/group/rights-licensing/permissions>

To order reprints go to:
<http://journals.bmj.com/cgi/reprintform>

To subscribe to BMJ go to:
<http://group.bmj.com/subscribe/>