

THE CLINICAL ROLE OF EVOKED POTENTIALS

P Walsh, N Kane, S Butler

ii16

J Neurol Neurosurg Psychiatry 2005;76(Suppl II):ii16–ii22. doi: 10.1136/jnnp.2005.068130

Neuro-electric responses to sensory stimuli can be readily and non-invasively recorded using averaging techniques first employed by Dawson in 1947.¹ The evoked responses can be quantified by measuring peak amplitudes and latencies, in the millisecond (ms) domain, and they provide numerical data that are quantitative extensions of the neurological examination. The clinical utility of evoked potentials (EPs) is based on their ability to:

- ▶ demonstrate abnormal sensory system conduction, when the history and/or neurological examination is equivocal
- ▶ reveal subclinical involvement of a sensory system (“silent” lesions), particularly when demyelination is suggested by symptoms and/or signs in another area of the central nervous system
- ▶ help define the anatomic distribution and give some insight into pathophysiology of a disease process
- ▶ monitor changes in a patient’s neurological status.

In theory almost any sensory modality may be tested, although in routine clinical practice pattern reversal visual evoked potentials (VEPs), short latency somatosensory evoked potentials (SSEPs), and brainstem auditory evoked potentials (BSAEPs) are tested most frequently. Longer latency responses that are related to higher “cognitive” functions such as event related potentials (ERPs), contingent negative variant (CNV), and sensory potentials after stimulation with CO₂ lasers are not routinely used in clinical practice and are beyond the scope of this article.

EPs have the advantages of being objective, often more sensitive than detailed neurological examination, and they can be recorded in patients who are anaesthetised or comatose. The latter fact, along with improvements in recording equipment, has led to newer applications in the operating theatre and intensive care unit (ICU)—at a time when the role of EPs in the assessment of multiple sclerosis has largely been replaced by magnetic resonance imaging (MRI). A recent evidence based review recommended that VEPs are probably useful and SSEPs are possibly useful in identifying patients who are at increased risk for developing clinically definite MS, but that there was insufficient evidence to recommend BSAEPs.² Disadvantages of EPs in clinical practice are that they are rarely disease specific and can be confounded by end organ disease (for example, VEPs may be abnormal in ocular disease, SSEPs in patients with peripheral neuropathy, and BSAEPs in conductive and sensorineural deafness), are affected by age, and require a degree of patient cooperation to obtain artefact-free recordings.

VISUAL EVOKED POTENTIALS: WHAT ARE THEY?

VEPs provide a sensitive indication of abnormal conduction in the visual pathway. Increases in retino-striate conduction time caused by processes such as demyelination can be detected by measuring the latency of this cortical response. Abnormalities in the amplitude and waveform of the VEPs may also be caused by the loss of axons in the pathway. VEPs are therefore widely used in the investigation of demyelinating disease, optic neuritis, and other optic neuropathies.

The standard clinical test involves the recording of the pattern reversal VEPs. The visual stimulus is a high contrast black-and-white checkerboard spanning the central 20°–30° of the visual field whose black and white squares periodically exchange places. The VEP is the averaged response to this reversal. Normal responses to binocular and monocular “full field” stimulation are illustrated in the upper part of fig 1. The responses are recorded from three electrodes spanning the occipital region with a mid frontal electrode as the voltage reference. The signal at the midline occipital electrode normally contains a prominent positive component which occurs approximately 100 ms after the pattern reversal (called P100). It is usually preceded by a smaller negative component with a latency of about 75 ms (N75). The waveforms at the lateral electrodes are rather variable and so the latency of P100 at the midline electrode is taken as the measure of retino-striate conduction time. The cursors in fig 1 show the mean latency for this group of normal subjects ± 2.5 SDs, the range used in our laboratory to define the range of normal variation.

See end of article for authors' affiliations

Correspondence to:
Dr Nick Kane, The Grey
Walter Department of Clinical
Neurophysiology, Frenchay
Hospital, Bristol, BS16 1LE,
UK; nick.kane@nbt.nhs.uk

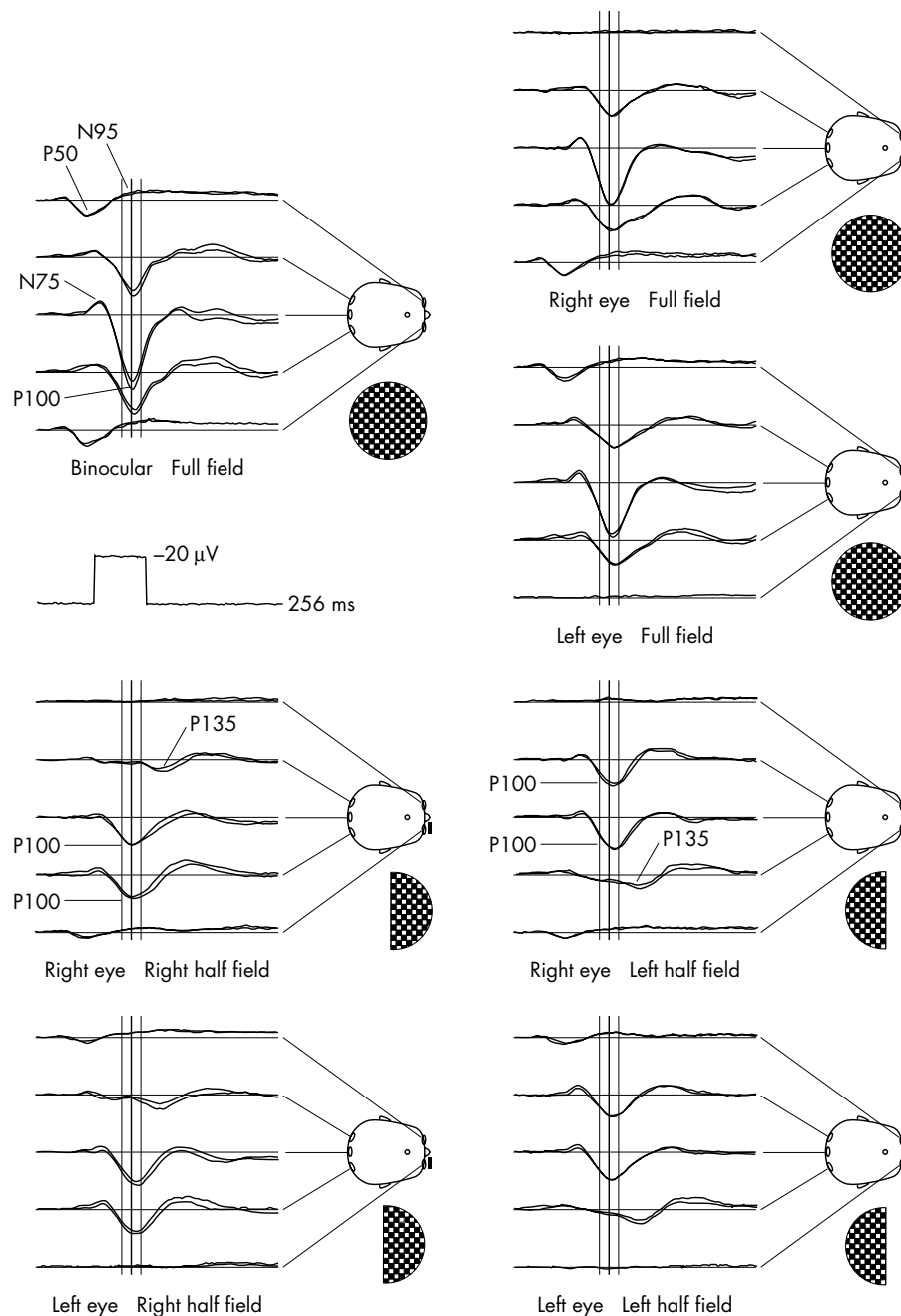


Figure 1 Pattern reversal visual evoked potentials (VEPs) and pattern electroretinograms (ERGs) evoked by full and half field stimulation averaged over a group of normal subjects. The vertical cursors show the mean latency and its 99.5% confidence limits (± 2.5 SDs).

The P100 is generated largely in the striate cortex as a response to the central region of the visual field. The lower part of fig 1 shows the VEPs to stimulation of the left and right halves of the visual field individually. Stimulation of one half of the visual field gives rise to excitation in the contralateral occipital lobe. P100 might therefore be expected to appear at the electrode contralateral to the half field stimulated. In practice P100 is usually seen over the lateral electrode ipsilateral to the half field stimulated. The paradoxical topography of the response is attributed to the oblique orientation of the cortex at the occipital pole, the area serving the central areas of the visual field. Stimulation of the peripheral field evokes a later positive VEP component, P135. The lateralisation of this component is orthodox and it can be seen in fig 1 at the electrode contralateral to the stimulated

half field. The half field responses therefore allow responses to central and peripheral stimuli to be distinguished.

The pattern electroretinograms (PERGs) recorded from electrodes on the lower eyelid are also shown in fig 1. These contain a P50 component generated by distal parts of the retina (receptors and the neural network) and an N95 component generated by the retinal ganglion cells. The PERG is abolished by defocusing and misfixation, and by retinal disorders which affect the macula. The N95 component is frequently absent or reduced in diseases of the optic nerve.

The standard clinical VEP is comprised of responses to monocular "full field" stimulation recorded from the three occipital electrodes. Inclusion of the PERG in the recording provides a biological check on compliance with fixation and focus and the assurance that any abnormalities in the VEPs

are not secondary to retinal disorder. Inclusion of the half field responses enables lesions affecting the retrochiasmal part of the pathway to be detected more reliably. The latency of P100 is affected by a number of factors including the brightness and contrast of the stimulus and the angle subtended by the squares in the checkerboard. It is therefore usual to base the values used to define the range of normal variation on data obtained from normal subjects using the local equipment. The checkerboard is normally composed of squares subtending a visual angle of 1° . Responses to smaller checks are more sensitive to disorders of the visual pathway but they are also more affected by defocusing and amblyopia. The use of the larger check size minimises these problems.

The latency of P100 appears to vary little with age from childhood through adult life. However, its latency begins to increase in the over 60s and allowance has to be made for this in assessing the normality of a recording.

VISUALLY EVOKED POTENTIALS: WHEN ARE THEY CLINICALLY USEFUL?

Abnormalities commonly encountered in patients referred for the investigation of demyelination and optic neuropathies are shown in fig 2. A delayed P100 in the full field VEPs of both eyes is frequently found in demyelination and in other disorders in which the reduction of conduction velocity is widely disseminated. Abnormalities restricted to one eye signify a problem affecting that eye or its optic nerve and are particularly common in optic neuritis. The abnormality may take the form of a delayed P100, a reduction in the amplitude of P100 or its complete absence, or a response with an abnormal waveform. The wave shape may be unusually prolonged (dispersed) or may have an abnormal number of inflections. These effects are attributed to the loss or impairment in conduction of axons within the visual pathway. An example of an abnormal waveform is shown in fig 2D. The "W" waveform abnormality (marked by $\uparrow \downarrow \uparrow$ arrows) is often the result of a loss of information from the central parts of the visual field. It may be the result of a maculopathy or damage to the pathway. In this case, the half field VEPs usually reveal that the second of the abnormal positive components is a P135, which appears at the midline electrode in the absence of P100.

Responses to half field stimulation may help to locate lesions posterior to the optic nerves. Figure 3 shows VEPs from a patient being investigated for demyelinating disease. The response to full field stimulation yielded a VEP of unexceptional waveform with a P100 of normal latency. However, the responses to stimulation of the left half field of each eye contain no positive component within the normal range for P100 and only vestigial positive deflections at longer latencies. Homonymous abnormalities in the latency, amplitude or waveform of the VEP, which appear only in response to stimulation of one half field, signify a retrochiasmal lesion in the hemisphere contralateral to the stimulated half field. Similarly, VEP abnormalities affecting the temporal or nasal half fields selectively indicate lesions (usually compressive) affecting the midline or lateral aspects of the optic chiasm, respectively.

SENSITIVITY AND SPECIFICITY

The sensitivity of VEPs to clinical disorders depends upon the technique used to evoke them. When the procedure was first introduced it was found to detect abnormality in 85–95% of individuals who would eventually receive a diagnosis of clinically definite multiple sclerosis.³ In a recent audit of 273 referrals to our practice, 92.5% of patients who eventually received a diagnosis of multiple sclerosis were found to have VEP abnormalities. However, these figures apply to VEPs evoked using stimulators which reverse the black and white pattern within a millisecond or so. Since the advent of inexpensive digitally generated graphic displays, VEPs have been recorded in many centres using computer monitors as stimulators. Although the pattern reversal on a computer monitor appears to be instantaneous, its raster scan takes up to 18 ms to draw the checkerboard. The result is that the pattern reversal is distributed in time. The P100 is more dispersed and its latency is more variable than is the case when the response is evoked with a fast optomechanical stimulator. The range of latencies defined as normal is a multiple of the standard deviation of the normal dataset and so the ability to detect abnormality is reduced. Some studies have suggested that the sensitivity of the technique may be as low as 25% when computer monitors are used as stimulators.⁴ This may be why some authorities no longer recommend VEPs for the routine investigation of multiple

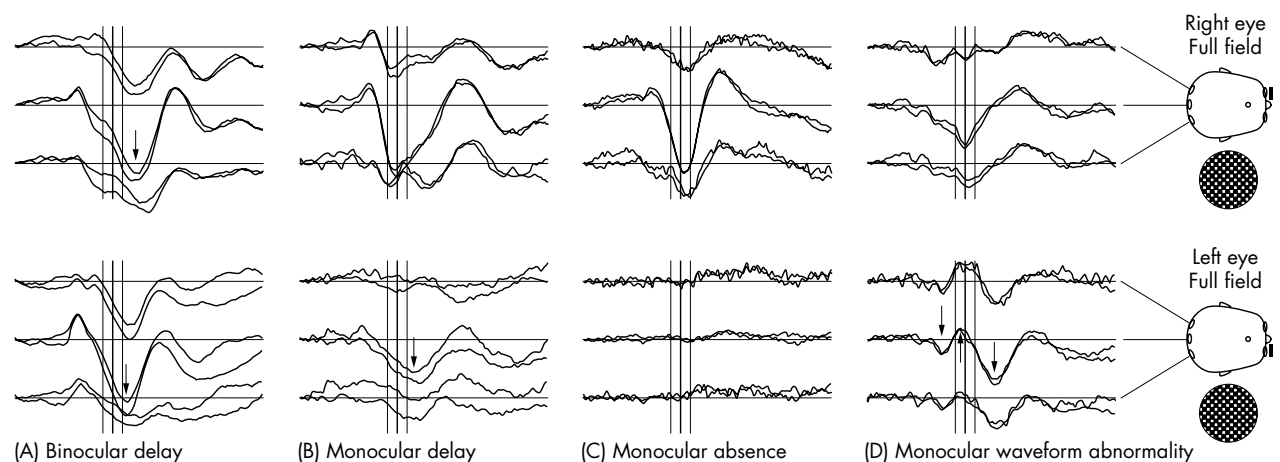


Figure 2 Full field monocular pattern reversal VEPs in four patients illustrating common forms of abnormality. The cursors show the mean latency for normal subjects and its 99.5% confidence limits from fig 1.

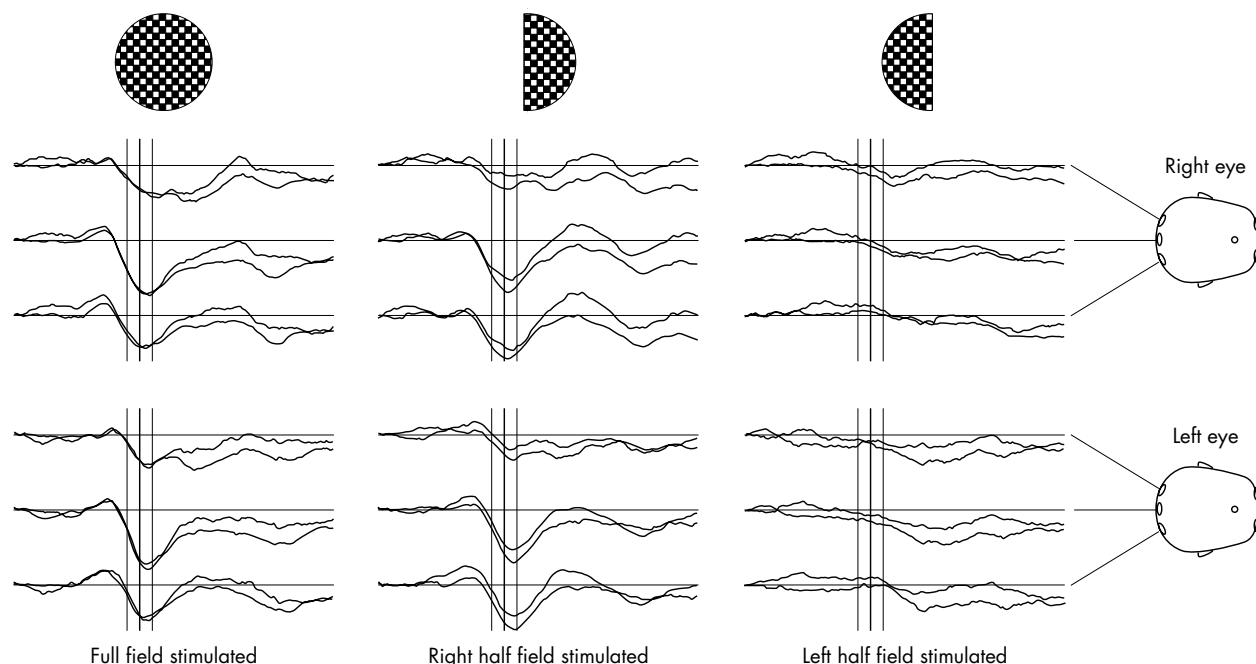


Figure 3 Full field and half field VEPs in a patient with multiple sclerosis. The pathway disorder is revealed only in the response to stimulation of the left half field.

sclerosis,⁵ but the problem can be overcome by using a stimulator which achieves rapid pattern reversal.

Anything which impairs conduction in the retino-striate pathway is likely to give rise to abnormalities in the latency, amplitude, or waveform of the VEPs. These are therefore associated with demyelination whether the disease is multiple sclerosis, familial ataxia (including Friedreich's ataxia), or adrenoleucodystrophy. VEPs are frequently delayed after traumatic brain injury, presumably as a result of diffuse axonal injury, and the magnitude of the delay is correlated with other measures of injury severity such as the extent of cognitive impairment. Toxic and nutritional causes of nerve conduction disorder, including B12 deficiency and alcohol-tobacco amblyopia, are associated with delayed VEPs. Other disorders in which the VEPs may be abnormal include the optic atrophies, compressive lesions affecting the visual pathway, and sarcoidosis.

FLASH AND PATTERN ONSET VISUAL EVOKED POTENTIALS

The pattern reversal VEP can be used to assess the visual system only with the cooperation of the patient because it requires both fixation and focus. It cannot be used in neonates or in adults who cannot focus because of opacity of the ocular media or who cannot understand or follow instructions. In these conditions the VEP may be recorded to a flash generated by a stroboscope, preferably in a "ganzfeld" which spans the whole visual field so that the direction of gaze is unimportant. Such recordings will at least provide rudimentary information about whether visual information is reaching the brain. But the variability of the flash VEP is high. It depends on pathways additional to the retino-striate projection and it is generated by other cortical regions, in addition to the striate area. Standard components can seldom be recognised in neonates and variability is high during the maturation of the cerebral cortex. As a result, the

flash VEP does not provide a reliable indication of retino-striate conduction time and inferences cannot be drawn from it about the quality or prognosis of visual perception.

In albinism the normal partial decussation of the visual pathway in the optic chiasm is often replaced by one in which there is a total or near total crossing of the axons to the contralateral hemisphere.⁶ This is often associated with significantly reduced visual acuity. The abnormal decussation can be detected by a characteristic reversal in the asymmetric topography of the VEPs over the occipital lobes in response to stimulation of left and right eyes. However, albinos often have nystagmus so that the pattern used to evoke the VEPs is not stationary on the retina. It is claimed that VEPs evoked by the appearance of the black-and-white checkerboard (the pattern onset VEPs) from a grey background provides a more reliable indication of the albino decussation than does pattern reversal.

SHORT LATENCY SOMATOSENSORY EVOKED POTENTIALS: WHAT ARE THEY?

SSEPs, elicited from the upper and lower limbs within 30 ms and 60 ms, respectively, of percutaneous electrical stimulation, are considered to be the result of action potentials and synaptic potentials from successive anatomic neural generators within the dorsal-lemniscus thalamo-cortical sensory system (fig 4).

After peripheral nerve stimulation both group Ia muscle afferents and group II cutaneous afferent fibres contribute to the resultant responses that can be recorded from electrodes placed over the peripheral nerves. In the upper limbs these compound nerve action potentials are routinely recorded from the brachial plexus at Erbs point and in the lower limbs in the popliteal fossa after stimulation of the posterior tibial nerve at the ankle. The postsynaptic electrical activity from the complex synaptic arrangements within the spinal grey matter gives rise to a stationary potential that is recorded over

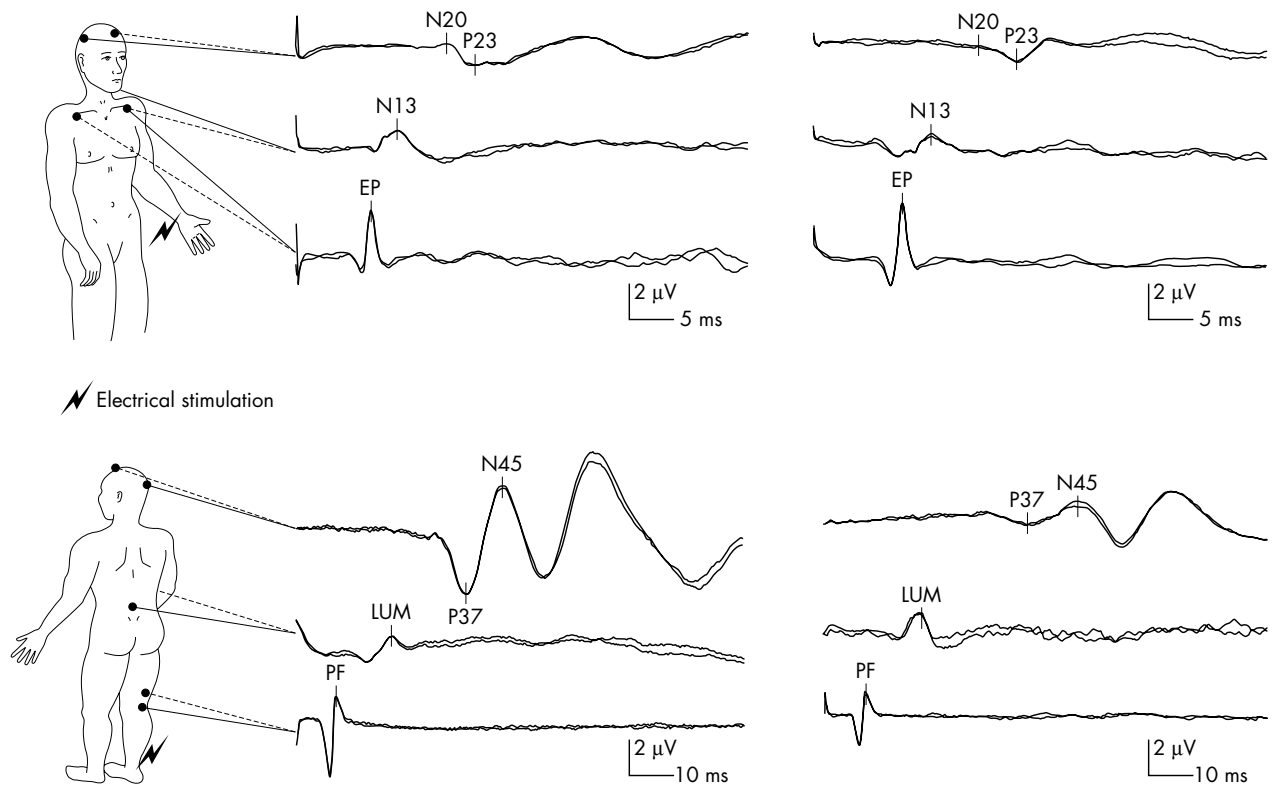


Figure 4 Left side: normal short latency somatosensory evoked potentials (SSEPs) after stimulation of the median nerve (top picture) and posterior tibial nerve (bottom picture). Right side: top picture shows normal median nerve SSEPs while the scalp potentials from the posterior tibial nerve (bottom picture) show a dispersed P37 potential with a prolonged latency.

the spinal segments of the nerve being stimulated. The upper limb cervical potential is seen with a negativity over the neck posteriorly at a latency of around 13 ms (and therefore called N13). The corresponding N22 reflects the activity coming from the spinal segments that receive the posterior tibial nerve.

The ascending axons continue rostrally to form the cuneate and gracilis funiculus and synapse with the second order neurones in the dorsal column nuclei of the medulla. The axons of these second order neurones cross the midline and ascend the brainstem on the contralateral side as the medial lemniscus. These lemniscal pathways terminate in the thalamus and synapse with third order neurones that project to their relative somatosensory cortices in the parietal lobe. On the scalp the cortical median N20 and tibial P37 responses are recorded from the contralateral hand area and the vertex, respectively, reflecting the cutaneous input to the primary somatosensory cortex (Brodmann area 3b).

SHORT LATENCY SOMATOSENSORY EVOKED POTENTIALS: WHEN ARE THEY CLINICALLY USEFUL?

In our clinical practice SSEPs are typically used to investigate patients with possible multiple sclerosis and myoclonus, intraoperatively to monitor integrity of the sensory pathways during surgical correction of spinal curvatures, and as a guide to prognosis in post-traumatic and anoxic-ischaemic coma in the ICU.

Multiple sclerosis

With the advent of magnetic resonance imaging (MRI) the clinical diagnosis and monitoring of multiple sclerosis

patients no longer requires EP studies.⁵ Nonetheless, they may be requested in patients with equivocal diagnostic evaluation such as a “negative” MRI (either abnormalities are too few or do not satisfy specific radiological criteria). When demyelination occurs within the central fibres of the dorsal column–medial lemniscal pathways this leads to a delay or even an absence of the SSEPs. Such findings are said to be present in about 80% of patients with multiple sclerosis who do not have sensory symptoms or signs.⁷ There is an increase in the diagnostic yield in those patients with sensory involvement, particularly from the SSEPs following stimulation of the lower limbs, which is probably due to the longer length of white matter that is being assessed (fig 4). When the responses from the lower limbs are normal, the upper limb responses will only show additional abnormalities in less than 10% of the patients studied. It is, however, worth stimulating all four limbs, as the abnormalities may only affect one side in a third of the patients studied. In our recent experience of 250 referrals, when a patient’s symptoms are restricted to the sensory system alone, usually a hemi-sensory disturbance, the yield of abnormality is low (less than 10%).

Unfortunately, abnormalities are not always pathognomonic of demyelination and as with all laboratory investigations must be analysed in the context of the clinical findings and other test results. SSEPs are often also abnormal in a variety of other conditions, and therefore sometimes used in their diagnosis, including neurogenic thoracic outlet syndrome, myeloradiculopathies, Friedreich’s ataxia, hereditary spastic paraplegia, and leucodystrophies, together with infarctions and tumours of the spinal cord, brainstem, and thalamus.⁷ In “MRI negative” nerve root lesions isolated cervical and

lumbar radiculopathies may be detected by a modified recording technique of the dermatomal SSEPs.

Myoclonus

Since Dawson found an exaggerated EEG response to electric shock in a patient with myoclonic epilepsy, the SSEPs have been widely used for supporting the diagnosis and therapeutic management of cortical myoclonus. In essence the later components of the cortical potential may be enlarged by more than 10 times reflecting cortical hyperexcitability. These “giant” potentials can be seen in a group of disorders known as the progressive myoclonic epilepsies, as well as juvenile myoclonic epilepsy, post-anoxic myoclonus (Lance-Adams syndrome), Alzheimer’s disease, advanced Creutzfeldt-Jacob disease, metabolic encephalopathies, olivopontocerebellar atrophy (OPCA), and Rett’s syndrome.⁸

Intraoperative monitoring

SSEPs can be recorded virtually continuously during surgical correction of spinal scoliosis and kyphosis in order to detect impaired neurological function, due to cord ischaemia, at a stage when corrective action may prevent postoperative neurological sequelae. A large multicentre survey has shown that monitoring contributes to a reduction in postoperative paraplegia by 50–60%.⁹ Somatosensory techniques have also been used to monitor during cross clamping of the internal carotid artery, cerebral aneurysm surgery, and excision of intrinsic spinal cord tumours—although their utility is less well established and may be limited by false negative results.

Guide to prognosis

Clinical assessment of the comatose ICU patient is limited to examination of the brainstem reflexes and motor responses. SSEPs can be used to enhance prognostic predictions in post-traumatic and anoxic-ischaemic coma. They are less susceptible to the effects of metabolic changes and sedating agents than clinical signs, such as motor responses and to a lesser extent the pupillary light reactions. Meta-analyses of the bilateral absence of cortical N20 responses, recorded after 72 hours, can predict death or the persistent vegetative state (that is, non-awakening) with a specificity of > 99% in anoxic-ischaemic and around 95% in traumatic coma.¹⁰

BRAINSTEM AUDITORY EVOKED POTENTIALS: WHAT ARE THEY?

After auditory stimulation with clicks a sequence of five peaks are usually recorded from an electrode placed over the vertex, and referenced to the ipsilateral mastoid. The compound action potential in the distal portion of the eighth nerve elicits wave I, while the proximal portion of the nerve, along with a contribution from the ipsilateral cochlear nucleus, generates wave II. Wave III is generated within the lower pons and probably represents multiple generators as the signal passes from the ipsilateral cochlear nucleus to the ipsilateral superior olivary complex and, via the trapezoid body, to the superior olives contralaterally. The fibre tracts and nuclei responsible for the IV/V complex include the lateral lemniscus and contralateral inferior colliculus in the lower midbrain. The ascending lower auditory pathways incorporate complex parallel processing, which makes the assumption that successive excitation of brainstem structures producing sequential potentials is probably an over simplification. More likely all but the most distally generated

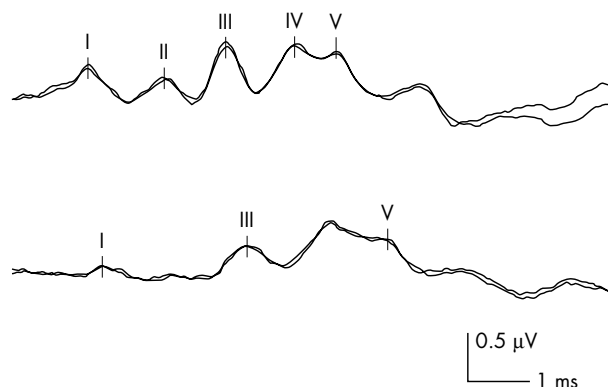


Figure 5 Upper trace: normal brainstem auditory evoked potentials (BSAEPs) following alternating click stimulation. Lower trace: abnormal BSAEPs in a patient with an acoustic neuroma showing poorly formed waveforms with prolonged I–III inter-peak latencies and subsequent I–V inter-peak latency.

waveforms arise as a composite of electrical activity from multiple adjoining structures (fig 5).

Interpretation of the BSAEPs usually involves measuring the absolute latency of the three most prominent vertex positive peaks I, III, and V, along with analysis of their relative inter-peak latencies (IPLs), which may provide some anatomical localisation of lesions. Conduction through the eighth nerve and the caudal brainstem is represented by the I–III IPL, while the III–V IPL probably represents transmission through the rostral brainstem and midbrain.

When the intensity of the auditory stimulus is gradually reduced the latency of each peak subsequently increases and the peak amplitude decreases, a technique called electric or evoked response audiometry. Eventually the threshold of each component, up to the point that the peak is last seen, can be determined and its latency–intensity curve can be plotted. Estimations of hearing threshold can be obtained by this systematic reduction in the stimulus intensity and the threshold of hearing can be determined at the point that wave V is barely discernible. The resultant latency–intensity curve can also help determine the type of hearing loss (conductive versus sensorineural).

BRAINSTEM AUDITORY EVOKED POTENTIALS: WHEN ARE THEY CLINICALLY USEFUL?

BSAEPs assess conduction through the lower brainstem auditory pathways which are not readily accessible to other testing procedures. In our clinical practice BSAEPs are used to investigate patients with possible multiple sclerosis, structural lesions of the brainstem and posterior fossa, intraoperatively to monitor integrity of the auditory pathways during neurosurgical excision of posterior fossa tumours, and as a guide to prognosis in post-traumatic and anoxic-ischaemic coma in the ICU. Occasionally hearing assessments are performed using electric response audiometry in patients who are unable to cooperate with formal audiometry.

Multiple sclerosis

The BSAEPs are more likely to be abnormal when demyelination affects the brainstem clinically, but they can also detect “silent” lesions in reportedly about 40% of patients who do not have symptoms or signs of brainstem involvement.¹¹ As with SSEPs the electrophysiological abnormalities

are not pathognomonic of multiple sclerosis, but the BSAEPs are less sensitive and specific than the SSEPs. In our recent experience of 60 symptomatic patients with suspected multiple sclerosis the yield of abnormality was only 15%.

BSAEP abnormalities have been described in OPCA, Friedreich's ataxia, hereditary cerebellar ataxia, central pontine myelinolysis, hydrocephalus, subarachnoid haemorrhage, and the leucodystrophies, together with neurodegenerative and neuropathic disorders.

Structural lesions

A prolonged I-III IPL is a reasonably sensitive and specific indicator of an acoustic neuroma in unilateral hearing loss (fig 5), but other patients may show rather non-specific abnormalities such as increased peak I and II latencies or absent responses. Rare cerebellopontine angle (CPA) tumours, including meningiomas, epidermoid cysts and neurofibromas, and intrinsic brainstem tumours also cause BSAEP abnormalities. MRI defines pathology and tumour size, which have implications for audiological prognosis. In our experience preoperative disruption of BSAEPs is a poor prognostic indicator for hearing preservation. Patients who have wave I, III, and V present are more likely (80%) to have preserved hearing function than those patients who have a wave I and/or V recordable (30%).

During neurosurgical excision of CPA tumours it is possible to record BSAEPs using a slightly modified stimulating technique, as the responses are relatively resistant to anaesthetic agents. Along with improvements in early diagnosis and surgical techniques intraoperative monitoring has contributed to the improved neurological outcome for patients with disorders of the posterior fossa.¹²

Guide to prognosis

The prognostic power of BSAEPs is limited by its relative resistance to ischaemia and anatomic specificity, which gives essentially no indication of the functional integrity of supratentorial structures. The presence of normal BSAEPs therefore correlates only weakly with neurological outcome. However, absence of waves III to V after both anoxic ischaemic cardiac arrest and traumatic brain injury is almost invariably associated with death or survival in a persistent vegetative state.¹⁰ In our practice it is more common to see abolition of the BSAEPs after devastating traumatic or anoxic-ischaemic insults; however, these must be interpreted with caution because of the selective sensitivity of the cochlear to ischaemia and the auditory nerve in head trauma, both of which can abolish wave I. In the diagnosis of

brainstem death the absence of wave I can warn the clinician of possible peripheral damage to the pathway, potentially invalidating the absence of doll's eye movement and the caloric test.¹¹

Authors' affiliations

P Walsh, N Kane, S Butler, The Grey Walter Department of Clinical Neurophysiology, Frenchay Hospital, Bristol, UK

REFERENCES

- 1 Dawson GD. Investigations on a patient subject to myoclonic seizures after sensory stimulation. *J Neurol Neurosurg Psychiatry* 1947;**10**:141–62.
- ▶ **Historical interest.**
- 2 Groseth GS, Ashman EJ. Practice parameter: the usefulness of evoked potentials in identifying clinically silent lesions in patients with suspected multiple sclerosis (an evidenced based review). *Neurology* 2000;**54**:1720–5.
- ▶ **Report of the Quality Standards Subcommittee of the American Academy of Neurology.**
- 3 Halliday AM. *Evoked potentials in clinical testing*, 2nd ed. Edinburgh: Churchill Livingstone, 1993.
- 4 Filippini G, Comi GC, Cosi V, et al. Sensitivities and predictive values of paraclinical tests for diagnosing multiple sclerosis. *J Neurol* 1994;**241**:132–7.
- 5 McDonald WI, Compston A, Egan G, et al. Recommended diagnostic criteria for multiple sclerosis: guidelines from the international panel on the diagnosis of multiple sclerosis. *Ann Neurol* 2001;**50**:121–7.
- ▶ **An updated and simplified outline of the diagnostic multiple sclerosis guidelines which plays down the clinical role of evoked potentials.**
- 6 Schmitz B, Käsmann-Kellner B, Schäfer T, et al. Monocular visual activation patterns in albinism as revealed by functional magnetic resonance imaging. *Human Brain Mapping* 2004;**23**:40–52.
- 7 Aminoff MJ, Eisen AA. Somatosensory evoked potentials. *Muscle Nerve* 1998;**21**:277–90.
- ▶ **American Academy of Electrodiagnostic Medicine (AAEM) minimonograph provides a good overview of SSEPs.**
- 8 Shibasaki H. Electrophysiological studies of myoclonus. *Muscle Nerve* 2000;**23**:321–35.
- ▶ **AAEM minimonograph.**
- 9 Nuwer MR, Dawson EG, Carlson LG, et al. Somatosensory evoked potential spinal cord monitoring reduces neurologic deficits after scoliosis surgery: results of a large multicenter survey. *Electroenceph Clin Neurophysiol* 1995;**96**:6–11.
- ▶ **Influential survey with methodological shortcomings but a sample size of nearly 100 000 operative cases.**
- 10 Young GB, Wang JT, Connolly JF. Prognostic determination in anoxic-ischemic and traumatic encephalopathies. *J Clin Neurophysiol* 2004;**21**:379–90.
- 11 Nuwer MR. Fundamentals of evoked potentials and common applications today. *Electroenceph Clin Neurophysiol* 1998;**106**:142–8.
- 12 Guerit J-M. Neuromonitoring in the operating room: why, when, and how to monitor? *Electroenceph Clin Neurophysiol* 1998;**106**:1–21.
- ▶ **Invited review: particularly useful for neurosurgeons.**
- 13 Binnie CD, Cooper R, Manguiere F, et al. *Clinical neurophysiology* vol. 1: EMG, nerve conduction and evoked potentials, Amsterdam: Elsevier, 2004.
- 14 Brignell MG. The visual evoked potential. In: Fishman GA, Birch DG, Holder GE, Brignell MG, eds. *Electrophysiological testing in disorders of the retina, optic nerve and visual pathway*. San Francisco: Foundation of the American Academy of Ophthalmology, 2001:237–9.
- 15 Caviness JN. Visual evoked potentials. In: Daube JR, ed. *Clinical neurophysiology*, 2nd ed. Oxford: Oxford University Press, 2003:227–36.
- 16 Chiappa K. *Evoked potentials in clinical medicine*, 3rd ed. Raven Press, 1997.