



OPEN ACCESS

SHORT REPORT

MRI-visible perivascular spaces: relationship to cognition and small vessel disease MRI markers in ischaemic stroke and TIA

Robert Hurford,¹ Andreas Charidimou,¹ Zoe Fox,² Lisa Cipolotti,³ Rolf Jager,^{4,5} David J Werring¹

► Additional material is published online only. To view please visit the journal online (<http://dx.doi.org/10.1136/jnnp-2013-305815>).

¹Stroke Research Group, Department of Brain Repair and Rehabilitation, UCL Institute of Neurology and The National Hospital for Neurology and Neurosurgery, London, UK

²UCL and the Education Unit, Biomedical Research Centre, UCL Institute of Neurology, London, UK

³Department of Neuropsychology, National Hospital for Neurology and Neurosurgery, London, UK

⁴Lysholm Department of Neuroradiology, UCL Institute of Neurology and National Hospital for Neurology and Neurosurgery, London, UK

⁵Department of Brain Repair and Rehabilitation, UCL Institute of Neurology, London, UK

Correspondence to

Dr David J Werring, National Hospital for Neurology and Neurosurgery, Box 6, Queen Square, London WC1N 3BG, UK; d.werring@ucl.ac.uk

Received 9 May 2013

Revised 13 October 2013

Accepted 20 October 2013

Published Online First

18 November 2013



Open Access
Scan to access more
free content

To cite: Hurford R, Charidimou A, Fox Z, et al. *J Neurol Neurosurg Psychiatry* 2014;**85**:522–525.

ABSTRACT

Background MRI-visible perivascular spaces (PVS) are potential neuroimaging markers of cerebral small vessel disease, but their functional significance and mechanisms remain uncertain. We investigated the association between PVS and cognitive impairment, and other MRI markers of small vessel disease, in a patient cohort of ischaemic stroke/transient ischaemic attack (TIA) referrals.

Methods Data were collected from a prospective observational database. Standardised detailed neuropsychological testing was performed. A validated visual rating scale on T₂-weighted MRI was used to categorise PVS severity; validated scales were used to assess white matter hyperintensities (WMH), cerebral microbleeds (CMB) and lacunes.

Results We included 246 patients (45.1% female, mean age 62 years). No significant association between PVS severity grade in any brain region and impairment in any cognitive domain was identified. In multivariable analysis, WMH and hypertension (but not age) were independently associated with basal ganglia PVS severity (OR: 1.27; $p < 0.0001$ and OR: 4.89; $p = 0.013$, respectively). Increasing PVS severity in the basal ganglia was associated with lacunar stroke subtype ($p < 0.0001$). Age and hypertension (but not WMH or lacunar stroke subtype) were independently associated with centrum semiovale PVS severity (OR: 1.19; $p = 0.013$ and OR: 3.71; $p = 0.007$, respectively).

Conclusions PVS do not have an independent association with cognitive impairment in patients with ischaemic stroke or TIA. The associations with clinical-radiological factors are consistent with the hypothesis that PVS reflect cerebral small vessel disease; the different associations for basal ganglia and centrum semiovale PVS might indicate different underlying small vessel arteriopathies according to PVS anatomical distribution, but this requires further study.

INTRODUCTION

Cerebral small vessel disease (SVD) is a highly prevalent cause of stroke and cognitive impairment,¹ but its pathophysiology is incompletely understood.² MRI-visible perivascular spaces (PVS) are emerging as promising new neuroimaging markers of SVD.³ PVS have been independently associated to incident dementia⁴ and cognitive function in a healthy elderly population.⁵ However, their relationship with cognition in patients with

cerebrovascular disease, in whom cognitive impairment is very common, is largely unknown.⁶

The pathophysiological mechanisms underlying PVS also remain unclear. The two commonest sporadic forms of SVD are: first, an intrinsic process affecting deep (basal ganglia, deep white matter and brainstem) small perforating arteries, and given a number of terms including arteriolosclerosis, lipohyalinosis or fibrinoid necrosis, but generally considered at least partly related to hypertension, so for simplicity, often termed hypertensive arteriopathy; and, second, cerebral amyloid angiopathy (CAA). The former has a predilection for the deep perforating arteries (basal ganglia and brainstem), while CAA typically affects cortical and leptomeningeal vessels.⁷ These processes may plausibly lead to different anatomical patterns of PVS.⁸

We hypothesised that: (A) since PVS reflect SVD, PVS severity is associated with worse cognitive function, particularly in speed-attention and frontal executive cognitive domains; and (B) PVS severity in basal ganglia and centrum semiovale is associated with clinical-radiological markers of SVD and stroke subtype, but associations may be different depending on PVS location. We therefore investigate associations between PVS and cognitive function in an ischaemic stroke/transient ischaemic attack (TIA) patient population. We also investigated associations of PVS with other clinical-radiological markers of SVD and ischaemic stroke subtype.

METHODS

Subjects

Patients admitted to the stroke unit, or attending the neurovascular clinic at the National Hospital for Neurology and Neurosurgery, Queen Square, London, who were referred for neuropsychological testing (2000–2007) were considered for inclusion. Provided there are no contraindications, all stroke service patients are referred for neuropsychological testing and MRI scanning in this service (figure 1).

The stroke, or TIA mechanism, was determined using the results of a detailed diagnostic assessment and were classified into aetiologies as per the Trial of Org 10172 in Acute Stroke (TOAST) guidelines.⁹

Neuropsychological assessment

A standardised neuropsychological battery examining seven cognitive domains (current intellectual

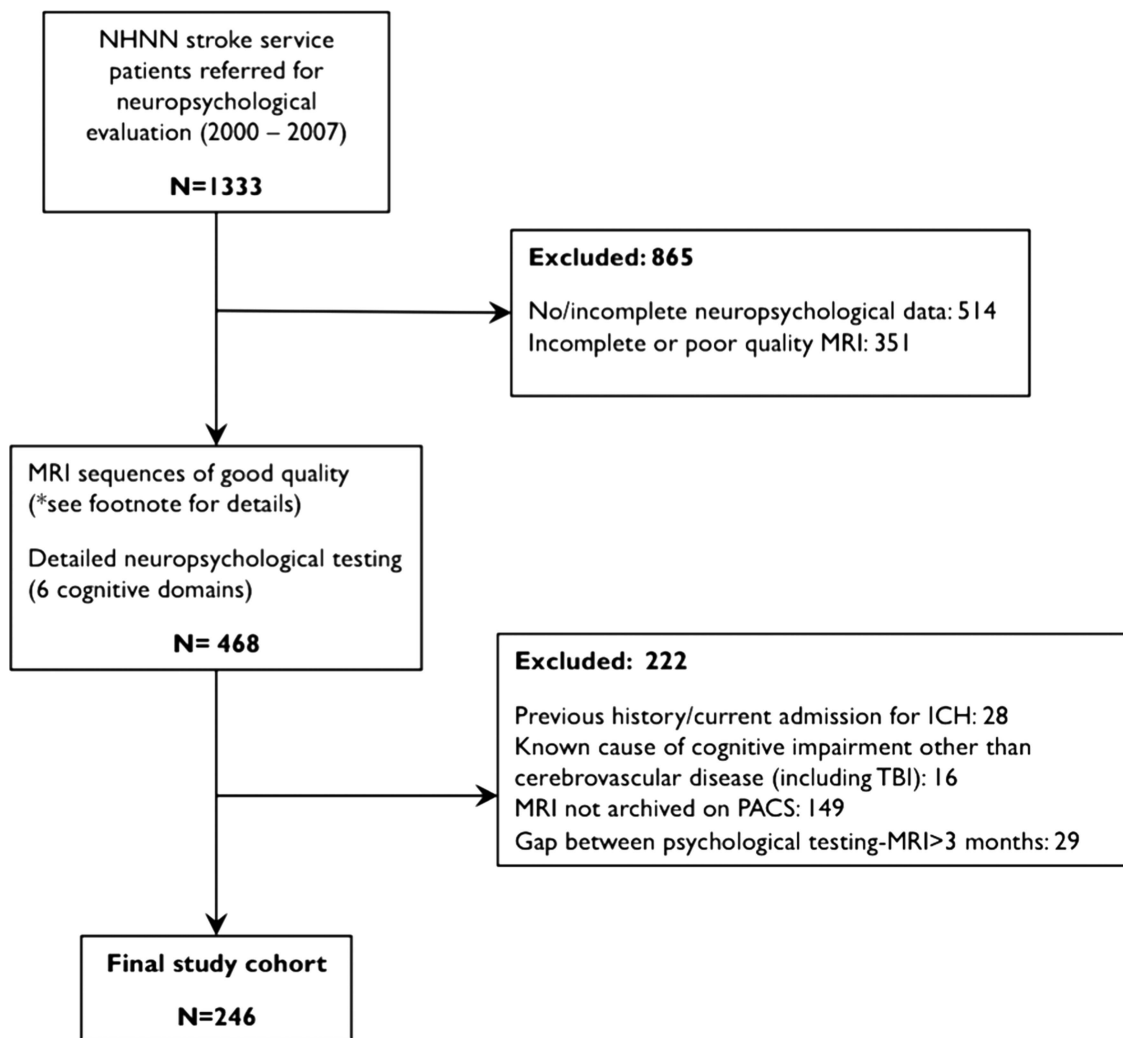


Figure 1 Flow diagram showing the patient exclusion criteria. NHNN, National Hospital for Neurology and Neurosurgery. GRE, gradient echo sequence; FLAIR, fluid attenuated inversion recovery; ICH, intracerebral haemorrhage; TBI, traumatic brain injury; PACS, picture archiving and communication system. *MRI parameters and sequences. MRIs were carried out on a 1.5 Tesla Signa Echospeed system (General Electric, Milwaukee, USA). The sequences included axial T2-weighted fast spin echo sequence (TR/TE=6000/102 ms), axial T2*-weighted GRE sequence (TR=300 ms; ET=40 ms; flip angle: 20; field of view: 24×18; matrix: 256×160, TR/TE=300/40 ms), a sagittal T1-weighted sequence, and a coronal FLAIR sequence (TR/TI/TE=9895/2473/140 ms). Five patients had MRI using similar sequences on a 1.5 Tesla Siemens Avanto MRI scanner. For all these sequences, slice thickness was 5 mm and slice gap 1.5 mm.

functioning, verbal and visual memory, nominal, perceptual, frontal executive and speed and attention functions) was carried out by a neuropsychologist blinded to the patients' clinical and MRI data. For patient-dependent reasons, not all patients were administered identical sets of tests, as decided by the neuropsychologist (see online supplementary material A). Premorbid IQ was assessed using the National Adult Reading Test (NART). Patients were classified as being impaired or unimpaired in each cognitive domain using predefined standardised criteria.¹⁰

MRI rating

Images were analysed by a trained observer blinded to clinical findings. Lacunes were defined as deep infarcts measuring 3–20 mm, seen as well-defined hypointensities on T1-weighted and fluid attenuated inversion recovery (FLAIR) images.¹¹ white matter hyperintensities (WMH) were rated using a validated scale.¹² Cerebral microbleeds were defined according to standardised criteria on T2*-weighted sequences, and rated using the Microbleed Anatomical Rating Scale (MARS).¹³ PVS were rated

by a trained observer using a validated visual rating scale¹¹; they were defined as small (<3 mm), sharply delineated structures (dots or linear structures) of cerebrospinal fluid intensity on axial T2-weighted MRI (TR/TE=6000/102 ms) following the orientation of perforating cerebral small vessels.¹⁴ Lacunes were distinguished from PVS by their larger size (>3 mm), spheroid shape and surrounding hyperintensity on FLAIR. In the centrum semiovale and basal ganglia, patients were grouped into <10, 11–20, 21–40 and >40 PVS (see online supplementary material B for further details of MRI criteria and footnote of figure 1 for MRI strength and sequences).

Statistical analysis

Due to the small number of PVS and the lack of evidence of clinical significance of <10 PVS, the first and second PVS groups (0 and 1–10 PVS) were merged (<10 PVS group). Pearson's χ^2 or Kruskal–Wallis one-way analysis of variance, were used as appropriate to evaluate significant differences in variables between PVS groups. The χ^2 test for trend was used to

establish direct linear correlations. Univariable ordinal logistic regression was used to test for the association between PVS severity categories and impairment in cognitive domains. We considered any p value <0.05 to be significant.

Ordinal logistic regression analyses were used to identify predictors of increasing PVS severity in the centrum semiovale and basal ganglia. Multivariable analysis was conducted controlling for variables found to be significant in the univariable analysis and likely to have pathophysiological influence on PVS. Statistical analysis was conducted on Stata 10.0 (StataCorp LP, Texas, USA).

The study was approved by the National Hospital for Neurology and Neurosurgery and Institute of Neurology joint research ethics committee.

RESULTS

The final cohort consisted of 246 patients; their baseline characteristics are reported online supplementary material C. The mean age was 62.0 years (SD: 16.5 years) and 45.1% of the patients were women. A diagnosis of hypertension was present in 68.2% of the patients. The baseline characteristics, including gender and median premorbid IQ score, did not differ across different PVS categories.

Prevalence of PVS

The proportions of patients in each PVS category are shown in online supplementary material C. There was a lower prevalence of PVS in the basal ganglia compared to the centrum semiovale and midbrain (80.5% vs 99.6% and 87.7%, respectively). There was higher prevalence of more severe PVS grades in the centrum semiovale, compared with the basal ganglia (see online supplementary material D). There was no significant association between basal ganglia and centrum semiovale severity categories (data not shown). There were no significant differences in the prevalence and severity of PVS between TIA and ischaemic stroke patients (data not shown).

Cognitive domain analysis

In unadjusted ordinal logistic regression analysis for clinical and imaging predictors of cognitive impairment in all seven cognitive domains, WMH were significantly associated with impaired perceptual skills ($p=0.03$) and speed and attention ($p=0.001$). Lobar microbleeds were associated with impaired frontal executive function ($p=0.05$). No significant association between PVS severity grade in any brain region and impairment in any cognitive domain was identified (see online supplementary material E). The lack of a significant effect between PVS severity and cognition remained consistent in a sensitivity analysis excluding patients with TIA. Recurrent stroke was not associated with cognitive impairment in any domains in univariable analysis.

Factors associated with increased PVS severity

Univariable analysis demonstrated that age ($p<0.0001$), hypertension ($p<0.0001$), median WMH score ($p<0.0001$), lacunes presence ($p=0.01$, $p<0.0001$), CMBs ($p=0.04$, $p=0.001$) and lobar CMBs ($p=0.05$, $p=0.03$) were significant predictors for both centrum semiovale and basal ganglia PVS severity, respectively (see online supplementary material F). The presence of deep CMBs was a significant predictor of PVS severity only in the basal ganglia (OR 6.14; 95% CI 2.81 to 13.47, $p<0.0001$). Recurrent stroke was not associated with increased PVS severity in any location.

In multivariable analysis, WMH and hypertension (but not age) were independently associated with basal ganglia PVS

Table 1 Multivariable regression analyses for basal ganglia and centrum semiovale PVS severity

	OR (95% CI)	p Value
Basal Ganglia PVS		
Age (for every 5-year increase)	1.18 (0.98 to 1.43)	0.081
Hypertension (yes vs no)	4.89 (1.39 to 17.21)	0.013
Median WMH score	1.27 (1.14 to 1.43)	<0.0001
Lobar CMBs number	0.82 (0.42 to 1.60)	0.551
Deep CMBs number	1.77 (0.59 to 5.33)	0.312
Presence of lacunes	2.93 (1.10 to 7.84)	0.032
Centrum Semiovale PVS		
Age (for every 5-year increase)	1.19 (1.04 to 1.37)	0.013
Hypertension (yes vs no)	3.71 (1.42 to 9.59)	0.007
Median WMH score	0.99 (0.89 to 1.10)	0.840
Lobar CMBs number	1.34 (0.60 to 2.95)	0.476
Number of lacunes	1.58 (0.45 to 5.57)	0.478

All the variables listed in the table have been used in the each multivariable model to assess their independent effect on PVS severity in the respective anatomical location. The results remain consistent after adjusting for transient ischaemic attack diagnosis in the models.

Statistically significant results are in bold.

CI, confidence interval; OR, odds ratio; PVS, perivascular spaces; WMH, white matter hyperintensities.

severity (OR: 1.27; $p<0.0001$ and OR: 4.89; $p=0.013$, respectively; table 1). Age and hypertension (but not WMH) were independently associated with centrum semiovale PVS severity (OR: 1.19; $p=0.013$ and OR: 3.71; $p=0.007$, respectively; table 1). Increasing PVS severity in the basal ganglia, but not the centrum semiovale, was associated with lacunar stroke subtype ($p<0.0001$). No variables were associated with severity of mid-brain PVS (data not shown).

DISCUSSION

Our data suggest that PVS do not have an independent association with cognitive impairment in this population, but we consolidate and extend observations on their associations with other SVD markers.

Our study confirms that PVS are prevalent and severe in this cohort of ischaemic stroke/TIA patients, consistent with other studies.¹⁵ Multiple imaging markers of SVD have been independently associated with cognitive decline in a range of clinical cohorts, but only one study has investigated the association of PVS with detailed cognitive testing. In this study of 97 healthy elderly men, total PVS were significantly associated with worse non-verbal reasoning and visuospatial cognitive ability, after adjusting for prior intelligence.⁵ Another recent population-based study of healthy elderly (65–80 years) individuals found that the highest severity degree of PVS was independently associated with incident dementia during a 4-year follow-up period⁴ In our study, there were no suggestive trends or borderline associations between PVS severity and cognitive impairment. It is possible that no associations were noted because of the significant burden of symptomatic cerebrovascular disease in our cohort including cortical infarcts, SVD and the high proportion of patients with recurrent stroke. This could make it difficult to detect any independent contribution of PVS, in particular, if they are an early feature of SVD. Indeed, some studies suggest that PVS may precede other manifestations of SVD, for example, WMH.^{16 17} Notwithstanding these limitations, our data suggest that PVS do not have any major direct association with cognition in this cohort. Further investigation of PVS and

cognition in larger cohorts without high cerebrovascular disease burden (eg, healthy elderly cohorts) will help clarify this hypothesis.

Our results strengthen the emerging link between PVS and SVD. The strong relationship between basal ganglia PVS severity and hypertension, WMH and small vessel occlusion-related stroke type is in agreement with previous studies,^{15 18} and consistent with the underlying pathophysiology being related to intrinsic disease affecting deep perforating arteries (hypertensive arteriopathy). The link between small vessel occlusion-related stroke mechanism and higher basal ganglia PVS load also supports the hypothesis that basal ganglia PVS reflect the arteriopathy underlying symptomatic small vessel occlusion-related stroke (generally presumed to be hypertensive arteriopathy of deep perforating vessels); SVD in the more eloquent deep white matter is presumed more likely to cause symptomatic small vessel occlusion-related infarcts. These findings thus consolidate previous work suggesting a link between PVS severity and small vessel occlusion-related stroke mechanism.^{8 11} Consistent with our findings, previous studies in various populations, including ischaemic subcortical and cortical stroke patients, have shown that WMH are a significant independent predictor of basal ganglia PVS.¹⁸

The clinical-radiological factors associated with centrum semi-ovale PVS were age and hypertension, but not WMH or small vessel occlusion-related stroke subtype, suggesting that they may have a different mechanism to basal ganglia PVS. CAA is one possible mechanism since it affects cortical and leptomeningeal arteries, which could impair interstitial fluid drainage from white matter to cortical areas.^{19 20}

The main limitation of our study is its cross-sectional and retrospective design, which restricts the analysis to the available routinely collected information. A large number of patients were excluded, leading to a young average age compared to other stroke populations, and a rather high proportion of patients with a recurrent stroke; this may have led to selection bias. Another potential confounding variable in our cohort is the high prevalence of hypertension (68.2%). These factors could potentially limit the generalisation of our results to other cohorts of patients with ischaemic stroke/TIA. Finally, due to the use of retrospective routinely collected data, not all patients had identical neuropsychological tests precluding the presentation of continuous data or z-scores.

Contributors Study concept and design: RH, AC, RJ and DJW. Acquisition of data: RH, AC, LC and DJW. Analysis and interpretation of data: RH, AC, ZF, LC and DJW. Interpretation of imaging: AC, RJ. Drafting of the manuscript: RH, AC and DJW. Critical revision of the manuscript for important intellectual content: RH, AC, ZF, LC, RJ and DJW. Statistical analysis: ZF, AC and RH. Study supervision: DJW, AC.

Funding AC receives research support from the Greek State Scholarship Foundation, the Stroke Association and the British Heart Foundation; DJW receives research support from the Department of Health/Higher Education Funding Council for England (Clinical Senior Lectureship Award), the Stroke Association and the British Heart Foundation. This work was undertaken at UCLH/UCL, which received a proportion of funding from the Department of Health's National Institute for Health Research Biomedical Research Centre's funding scheme.

Competing interests None.

Ethics approval National Hospital for Neurology and Neurosurgery and Institute of Neurology joint research ethics committee.

Provenance and peer review Not commissioned; externally peer reviewed.

Data sharing statement All data are presented.

Open Access This is an Open Access article distributed in accordance with the Creative Commons Attribution Non Commercial (CC BY-NC 3.0) license, which permits others to distribute, remix, adapt, build upon this work non-commercially, and license their derivative works on different terms, provided the original work is properly cited and the use is non-commercial. See: <http://creativecommons.org/licenses/by-nc/3.0/>

REFERENCES

- Greenberg SM. Small vessels, big problems. *N Engl J Med* 2006;354:1451–3.
- Wardlaw JM. What causes lacunar stroke? *J Neurol Neurosurg Psychiatry* 2005;76:617–19.
- Kwee RM, Kwee TC. Virchow-Robin spaces at MR imaging. *Radiographics* 2007;27:1071–86.
- Zhu YC, Dufouil C, Soumare A, et al. High degree of dilated Virchow-Robin spaces on MRI is associated with increased risk of dementia. *J Alzheimers Dis* 2010;22:663–72.
- MacLullich AM, Wardlaw JM, Ferguson KJ, et al. Enlarged perivascular spaces are associated with cognitive function in healthy elderly men. *J Neurol Neurosurg Psychiatry* 2004;75:1519–23.
- Hurford R, Charidimou A, Fox Z, et al. Domain-specific trends in cognitive impairment after acute ischaemic stroke. *J Neurol* 2013;260:237–41.
- Pantoni L. Cerebral small vessel disease: from pathogenesis and clinical characteristics to therapeutic challenges. *Lancet Neurol* 2010;9:689–701.
- Zhu YC, Tzourio C, Soumare A, et al. Severity of dilated Virchow-Robin spaces is associated with age, blood pressure, and MRI markers of small vessel disease: a population-based study. *Stroke* 2010;41:2483–90.
- Adams HP Jr, Bendixen BH, Kappelle LJ, et al. Classification of subtype of acute ischemic stroke. Definitions for use in a multicenter clinical trial. TOAST. Trial of Org 10172 in Acute Stroke Treatment. *Stroke* 1993;24:35–41.
- Werring DJ, Frazer DW, Coward LJ, et al. Cognitive dysfunction in patients with cerebral microbleeds on T2*-weighted gradient-echo MRI. *Brain* 2004;127:2265–75.
- Douba FN, MacLullich AM, Ferguson KJ, et al. Enlarged perivascular spaces on MRI are a feature of cerebral small vessel disease. *Stroke* 2010;41:450–4.
- Wahlund LO, Barkhof F, Fazekas F, et al. A new rating scale for age-related white matter changes applicable to MRI and CT. *Stroke* 2001;32:1318–22.
- Gregoire SM, Chaudhary UJ, Brown MM, et al. The Microbleed Anatomical Rating Scale (MARS): reliability of a tool to map brain microbleeds. *Neurology* 2009;73:1759–66.
- Bokura H, Kobayashi S, Yamaguchi S. Distinguishing silent lacunar infarction from enlarged Virchow-Robin spaces: a magnetic resonance imaging and pathological study. *J Neurol* 1998;245:116–22.
- Zhu YC, Dufouil C, Mazoyer B, et al. Frequency and location of dilated Virchow-Robin spaces in elderly people: a population-based 3D MR imaging study. *AJNR Am J Neuroradiol* 2011;32:709–13.
- Wardlaw JM. Blood-brain barrier and cerebral small vessel disease. *J Neurol Sci* 2010;299:66–71.
- Deramecourt V, Slade JY, Oakley AE, et al. Staging and natural history of cerebrovascular pathology in dementia. *Neurology* 2012;78:1043–50.
- Rouh RP, van Oostenbrugge RJ, Knottnerus IL, et al. Virchow-Robin spaces relate to cerebral small vessel disease severity. *J Neurol* 2008;255:692–6.
- Charidimou A, Gang Q, Werring DJ. Sporadic cerebral amyloid angiopathy revisited: recent insights into pathophysiology and clinical spectrum. *J Neurol Neurosurg Psychiatry* 2012;83:124–37.
- Charidimou A, Meegahage R, Fox Z, et al. Enlarged perivascular spaces as a marker of underlying arteriopathy in intracerebral haemorrhage: a multicentre MRI cohort study. *J Neurol Neurosurg Psychiatry* 2013;84:624–9.