

REVIEW

Stroke and methamphetamine use in young adults: a review

Julia M Lappin,^{1,2} Shane Darke,¹ Michael Farrell¹

► Additional material is published online only. To view please visit the journal online (<http://dx.doi.org/10.1136/jnnp-2017-316071>).

¹National Drug and Alcohol Research Centre (NDARC), University of New South Wales, Sydney, New South Wales, Australia

²School of Psychiatry, University of New South Wales, Sydney, New South Wales, Australia

Correspondence to

Dr Julia M Lappin, National Drug and Alcohol Research Centre, University of New South Wales, NSW, 2052, Australia; j.lappin@unsw.edu.au

Received 17 March 2017
Revised 4 May 2017

Accepted 13 June 2017
Published Online First
23 August 2017

ABSTRACT

Background Methamphetamine use and stroke are significant public health problems. Strokes among people aged below 45 years are much less common than in older age groups but have significant mortality and morbidity. Methamphetamine is a putative cause of strokes among younger people.

Methods A review of methamphetamine-related strokes was conducted. Bibliographic databases were searched until February 2017 for articles related to methamphetamine and stroke. Both haemorrhagic and ischaemic strokes were considered.

Results Of 370 articles screened, 77 were selected for inclusion. There were 81 haemorrhagic and 17 ischaemic strokes reported in case reports and series. Both types were approximately twice as common in males. Route of administration associated with haemorrhagic stroke was typically oral or injecting, but for ischaemic stroke inhalation was most common. Haemorrhagic stroke was associated with vascular abnormalities in a third of cases. One quarter of individuals completely recovered, and a third died following haemorrhagic stroke. One-fifth completely recovered, and one-fifth died following ischaemic stroke.

Conclusions There is a preponderance of haemorrhagic strokes associated with methamphetamine use in young people, and methamphetamine-related stroke is associated with poor clinical outcomes. Mechanisms of methamphetamine-associated stroke include hypertension, vasculitis, direct vascular toxicity and vasospasm. In a period of rising worldwide methamphetamine use, the incidence of methamphetamine-related stroke will increase, with a consequent increase in the burden of disease contributed by such events.

INTRODUCTION

Methamphetamine use is a significant public health problem, particularly in countries around the Pacific rim (North America, East/Southeast Asia and Oceania), with an estimated 35 million stimulant users worldwide, predominantly of methamphetamine.^{1–3} Harmful physical and mental health consequences are common, including cardiovascular and cerebrovascular pathology, psychosis, suicide and premature mortality.^{4–8} The stimulants methamphetamine and amphetamine have been available in various forms since the middle of last century.⁷ Methamphetamine use has changed over years: in 1950s and 1960s, it was popular as benzedrine, later amphetamine became the preferred form, while most recently there has

been a substantial global increase in the availability and use of high potency, crystalline methamphetamine.^{1,3,9} Routes of methamphetamine administration include oral, inhalation (smoking), intranasal and intravenous use.⁷

Stroke too is a major public health problem, with high mortality rates and high levels of subsequent disability.^{10,11} Between 1990 and 2010, stroke has risen from the fifth to the third leading cause of disability-adjusted life years, with increase of 19%.¹⁰ Moreover, the incidence of stroke has been rising among younger persons.¹² While stroke incidence rises with age and is less common in people aged below 45 years, stroke among young people has significant health sequelae and societal costs.¹²

Stroke in young people

In all-age stroke populations, ischaemic strokes (cerebral infarction) are more common.¹³ In younger people (<45 years), this remains the case, but a greater proportion are haemorrhagic (eg, 33.5% in those 20–44 years vs 23.1% in those 45–54 years).¹³ Haemorrhagic strokes in those aged 20–44 years are subarachnoid or intracerebral in approximately equal proportion.¹³ In young people, subarachnoid haemorrhages are most frequently due to an underlying cerebral aneurysm or arteriovenous malformation (AVM).¹⁴ Non-traumatic intracerebral haemorrhage (ICH) is associated with hypertension in 70% of all-age stroke, but in young people it may account for as little as 20%, with a high preponderance of other causes such as AVM, ruptured saccular aneurysm and sympathomimetic drug use.¹⁵

Risk factors for ischaemic stroke include dyslipidaemia, smoking and hypertension.^{16,17} As is the case for haemorrhagic stroke causation differs in young people (<45 years), with a higher preponderance of females, recent illicit substance use and use of the contraceptive pill/oral contraceptives than in those even slightly older (45–49 years).¹⁷

Substance use and stroke in young people

The prevalence of illicit drug use is highest among younger people.^{9,18,19} There is increased relative risk for both ischaemic and haemorrhagic stroke associated with all drug use²⁰ and drug use as a cause of stroke is significantly more common among young people.¹⁷ Intravenous use of any illicit drug increases the risk of ischaemic stroke through thromboembolic mechanisms.²¹ Stroke risk factors are different among users of illicit substances, with higher rates of smoking and lower rates of



CrossMark

To cite: Lappin JM, Darke S, Farrell M. *J Neurol Neurosurg Psychiatry* 2017;**88**:1079–1091.

hypertension and diabetes compared with those with ischaemic stroke in the absence of substance use.²¹ Alcohol has also been demonstrated to increase risk of stroke.¹⁷

One class of drugs that has been associated with stroke incidence is the psychostimulants.¹¹ Cocaine, in particular, has been associated with a substantially increased risk of haemorrhagic stroke.¹¹ Methamphetamine shares pharmacological characteristics and physiological effects in common with cocaine, and both are associated with hypertension and coronary disease.^{5 7 22 23} Methamphetamine, however, has a longer half-life than cocaine,⁷ and there is subsequently a longer exposure to systemic hypertension. Moreover, methamphetamine also substantially increases the risk of stroke.^{24–26} It is important to note that methamphetamine is also strongly associated with the development of ischaemic heart disease and accelerated atherosclerotic coronary artery disease.⁷

Despite its widespread use and potential clinical significance, however, the features and pathogenesis of methamphetamine-related stroke are poorly understood. This is of particular relevance in a period of large increases in worldwide methamphetamine use, when the incidence of methamphetamine-related stroke, particularly among young people, would be expected to increase in conjunction with use. In the context of increased use of methamphetamine, and thus of increased stroke risk, the current study aimed to review the literature on methamphetamine-related stroke among young people (defined as <45 years). Specifically, the study aimed to:

1. summarise the features of stroke in young amphetamine users; and
2. determine the evidence for the pathogenesis of methamphetamine-related stroke.

METHODS

The EMBASE (Embase Classic+Embase), MedLine (Ovid MEDLINE Epub Ahead of Print, In-Process & Other Non-Indexed Citations, Ovid MEDLINE Daily, Ovid MEDLINE and Versions) and PsycINFO (PsycINFO) bibliographic databases were searched until 10 February 2017 for articles on the association between meth/amphetamine use and strokes in young people (figure 1). Search terms included: methamphetamine, amphetamine and common variants, stroke, cerebrovascular disorders and cerebral haemorrhage. Hand-searching of reference lists of included studies was also conducted. The search was restricted to English-language publications or to those with a comprehensive abstract in English that was sufficiently detailed. There was no restriction on year of publication. The search strategy is provided in detail in the online supplementary figure s1.

Inclusion criteria

Studies were eligible for inclusion if they were published in a peer-reviewed journal or referenced in a relevant journal article. Studies that focused on the relationship between methamphetamine use and incident stroke were included. Where putative additional or alternative risk factors for stroke were reported, these were detailed (table 1). Consistent with literature on strokes in young people,^{13 17} studies were included if they reported cases of methamphetamine/amphetamine-associated stroke in people aged 44 years or below. Both ischaemic and haemorrhagic strokes were considered. Studies were included only where the drug was used for abuse purposes, excluding studies reporting effects of prescribed amphetamines and related compounds. Where polydrug use was recorded, this was documented where

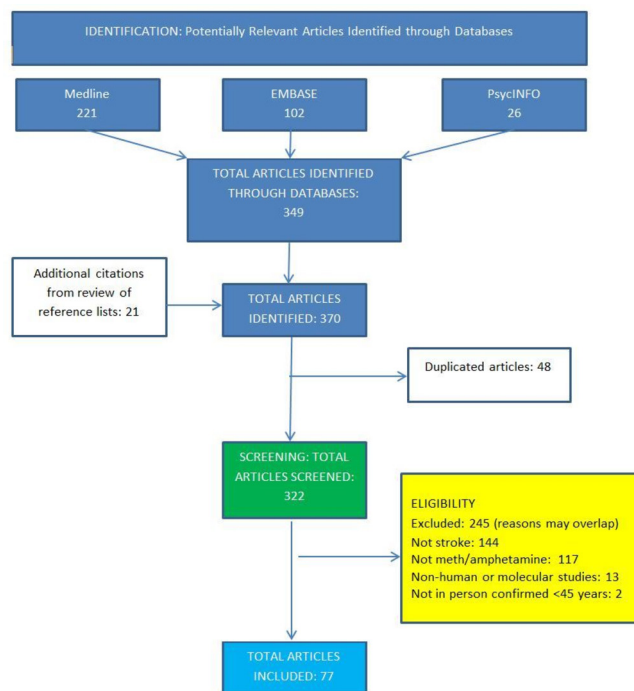


Figure 1 Methodology of the review and flow diagram.

relevant. Dextroamphetamine was included only where it was used for abuse purposes.

RESULTS

A total of 77 papers met search criteria (figure 1). These comprised three postmortem studies, 11 case control and epidemiological studies and 63 case series/case reports.

Methamphetamine-related stroke in young people: postmortem studies

Several large postmortem series report that between 1% and 5% of all-age methamphetamine-related deaths are caused by intracranial haemorrhage, with cases of both subarachnoid and ICH reported^{27–29} (table 2).

Methamphetamine-related stroke in young people: epidemiological studies

Case series conducted over the past four decades identify amphetamines as a cause of stroke in 6%–13% of haemorrhagic^{15 20 30–32} and 2%–6% of ischaemic stroke^{16 21} (table 3). These differences reflect rates of use in the area the study was undertaken, and change in use patterns over time. It is noteworthy that higher rates of stroke associated with methamphetamine were recorded in the past decade, with three studies of haemorrhagic stroke^{32–34} reporting rates of methamphetamine use between 7% and 13%, despite these series being in all-age populations. Because methamphetamine use is predominantly associated with younger age, the proportion of methamphetamine-associated strokes in these series among those <45 years (though unreported) is likely to be even higher. Similarly, Phillips and coworkers¹⁶ case series of ischaemic stroke among individuals aged 15–50 years reports a higher rate due to amphetamine (6%) than the 2% identified in a study conducted a decade earlier.²¹ In addition, it is likely that drug use as a contributory cause may often be underestimated, as suitable investigations or testing for drug use may not be conducted or recorded.

Table 1 Methamphetamine-related stroke reported in case studies and case series. Haemorrhagic strokes are detailed first, followed by ischaemic*

Author	Age	Sex	Drug	Clinical features	Nature of stroke	Angiography	Outcomes
HAEMORRHAGIC STROKES							
Gericke <i>et al</i> (1945)	36	M	Amphetamine	Headache, right hemiparesis within 4 hours. Died within 24 hours.	Subdural and subarachnoid haemorrhage, and intracerebral haemorrhage in occipital and parietal lobes	Not performed. Craniotomy.	Death
Poteliakhoff and Roughton (1956)	42	M	Amphetamine (Benzedrine)	Headache, left hemiparesis. Hypertension (180/100) at 48 hours	Intracerebral haemorrhage; posterior parietal haematoma, subarachnoid haemorrhage	Not performed. Ventriculography suggested posterior parietal mass	Recovery
Coroner's report (1967)	16	M	Amphetamine	Died within hours	Intracerebral haemorrhage	Not performed. No further detail	Death
Kane <i>et al</i> (1969)	24	M	Methamphetamine	Headache	Intracerebral haemorrhage	Not performed. Organic brain impairment testing: cognitive impairment on right side	Residual left-sided spastic hemiplegia
Goodman and Becker (1970)	26	M	Amphetamine	Headache. BP: 130/60 at 72 hours	Right intracerebral haemorrhage	Right fronto-parietal haematoma	Slowly resolving left hemiparesis
Weiss <i>et al</i> (1970)	18	M	Dextroamphetamine	Headache, seizures. BP: 134/80 at 48 hours. Mild fever: 99.6°F	Subarachnoid haemorrhage	No abnormality found at bilateral carotid or vertebral angiography	Recovery
	25	M	Methamphetamine	Headache within minutes. Seizure at 24 hours. No hypertension at 24 hours	Subarachnoid haemorrhage and right intracerebral frontal haemorrhage	Right frontal lobe mass	Mild left hemiparesis
	26	M	Methamphetamine	Headache within 2 hours. BP: 130/80 at 24 hours	Subarachnoid haemorrhage and right intracerebral posterior-temporal haemorrhage	Right temporal lobe mass	Left hemiparesis
Margolis and Newton (1971)	35	F	Methamphetamine (also heroin addict)	Confusion and hallucinations within hours. BP: 134/80. Feverish: 100.2°F	Subarachnoid haemorrhage and intracerebral haemorrhage in right external capsule	Possible aneurysms in right and left middle cerebral arteries	Bilateral hemiparesis with improvement on right side
Rumbaugh <i>et al</i> (1971a) ⁴⁸	38	F	Amphetamine (and heroin)	Headache and aphasia; right hemiparesis. Temporal relationship unclear	Left intracerebral haemorrhage	Beading in branches right callosomarginal artery and extensive small arterial branch occlusions	Right upper hemiparesis and aphasia
	37	M	Methamphetamine (Methedrine) and heroin	Coma. Temporal relationship unclear	Unclear but intracerebral haemorrhage assumed	Extensive small artery occlusive changes	'Returned home'
	32	F	Amphetamine	Coma. Temporal relationship unclear	Unclear but intracerebral haemorrhage assumed	Small artery occlusive changes	Convalescent home
	24	M	Amphetamine	Right hemiparesis	Left intracerebral haemorrhage	Beaded irregular arterial changes and small arterial occlusive changes	Right hemiparesis and convalescent home
	29	F	Amphetamine	Seizures. Temporal relationship unclear	Unclear but intracerebral haemorrhage assumed	Small arterial occlusive changes	Not stated
	21	F	Methamphetamine (Methedrine)	Coma. Temporal relationship unclear	Unclear but intracerebral haemorrhage assumed	Beading of intracranial vessels; small arterial occlusions	Not stated
Hall <i>et al</i> (1973)	26	M	Methamphetamine	Headache and right hemiparesis. Death within hours	Left intracerebral haemorrhage	Left frontal mass. No AVM detected	Death
Yatsu <i>et al</i> (1975)	26	F	Methamphetamine	Headache. Temporal relationship unclear	Right intracerebral haemorrhage	Right posterior-temporal haematoma	Death
Chynn (1975)	19	F	Amphetamine (and cocaine/marijuana)	Headache and stupor. Hypertension (160/100) at 12 hours	Subarachnoid haemorrhage and possible intracerebral haemorrhage	Beading in left middle cerebral artery. Return to normal appearance on repeat angiogram 16 days later	Right hemiparesis

Continued

Table 1 Continued

Author	Age	Sex	Drug	Clinical features	Nature of stroke	Angiography	Outcomes
Edwards ⁴³	21	F	Methamphetamine	Headache within minutes; confusion within hours	Subarachnoid haemorrhage	Segmental narrowing of medium-sized arteries (cerebral arteritis). Some arterial occlusions. No aneurysm or AVM	Recovery
Olsen (1977)	25	M	Methamphetamine (Methedrine)	Headache and coma within 2 hours. Hypertension (190/160) and fever 103.2°F at 4 hours	Subarachnoid haemorrhage	Diffuse beading of intracranial vessels	Death
Kessler <i>et al</i> ⁴⁴	22	M	Amphetamine, cocaine and heroin	Headache and coma within minutes. Hypertension (170/120) at 8 hours	Multiple small intracerebral haemorrhages and subarachnoid haemorrhage	Left frontal haematoma. Stenosis and dilatation of tributaries of middle cerebral artery consistent with cerebral arteritis	Mild dysphasia and right hemiparesis
LoVerne (1979)	25	F	Methamphetamine	Headache and seizures. Temporal relationship unclear	Left frontal intracerebral haemorrhage	Left frontal avascular mass	Recovery: right hemiparesis resolved
Delaney and Estes (1980)	24	F	Methamphetamine	Headache, confusion, right hemiparesis within hours. Death within 48 hours	Subarachnoid haemorrhage and left frontal haematoma	No evidence of aneurysm, AVM or vasculitis	Death
Cahill <i>et al</i> (1981)	25	M	Dextro-amphetamine, methylphenidate	Headache, seizures and hypertension (180/120). Temporal relationship unclear	Subarachnoid haemorrhage	Beaded appearance in multiple middle and anterior cerebral cortical branches of right carotid artery. Steroid treatment commenced. 3 weeks later angiogram normal	Recovery. No residual deficit
D'Souza and Shaberg (1981)	17	M	L- and D-l amphetamine	Headache within an hour. Left hemiplegia and hypertension (210/120) at 3 hours	Right insular intracerebral haemorrhage	Normal: no aneurysm or AVM	Recovery
Shukla (1982)	24	M	Amphetamine	Headache and stupor; hypertension (150/95) within hours	Right intracerebral haemorrhage	Right thalamic avascular mass. No aneurysm or AVM	Left hemiplegia
Harrington <i>et al</i> ⁴⁹	19	M	Amphetamine	Headache, vomiting, hypertension (170/104) within 2 hours	Left frontal intracerebral haemorrhage	Irregularity and partial occlusion of several small cerebral vessels. CT: increased density left frontal lobe	Recovery
Yu <i>et al</i>	19	M	Amphetamine	Headache and right hemiparesis within 24 hours	Left temporo-parietal intracerebral haemorrhage	No abnormalities. CT: left temporo-parietal mass with midline shift.	Minimal right-sided sensory/motor signs
Lukes (1983)	28	M	Methamphetamine	Headache within 1 hour. Blurred vision, stupor, hypertension (160/95) at 24 hours	Superiotemporal intracerebral haemorrhage	Right superior temporal AVM. No arterial narrowing or beading	Left homonymous hemianopia
Matick <i>et al</i> ⁴⁵	25	M	Dextroamphetamine	Stupor, seizures, hypertension (240/100) at 24 hours.	Subarachnoid haemorrhage	Aneurysm in left anterior temporal branch of middle cerebral artery. Multiple widespread areas of luminal irregularity	Mild left hemiparesis
Salanova and Taubner (1983) ⁵²	18	M	Amphetamine	Headache and right hemiparesis within hours	Left intracerebral haemorrhage	Haematoma in internal capsule and basal ganglia. Diffuse narrowing of intracranial arteries. Improved at 18 day angiogram following steroid treatment	Mild residual right hemiparesis
Yu <i>et al</i> (1983) ⁵¹	16	M	Methamphetamine	Vomiting, seizures, hypertension (140/90). Temporal relationship unclear.	Intracerebral haemorrhage in left anterior parietal lobe	Irregularity of flow; beading of anterior and middle cerebral arteries. Appearance normal at re-exam after 1 month of treatment with prednisolone	Recovery
Ogasawara <i>et al</i> ⁴⁶	23	F	Methamphetamine	Headache, vomiting, gait disturbance within minutes. Right hemiparesis at 26 hours	Intracerebral haemorrhage in left parietal-frontal lobe and left lateral ventricle	Irregular segmental arterial narrowing and beading of anterior and middle cerebral arteries	Recovery 'fair'

Continued

Table 1 Continued

Author	Age	Sex	Drug	Clinical features	Nature of stroke	Angiography	Outcomes
Conci <i>et al</i> ²⁴	18	M	Amphetamine	Headache, vomiting, confusion	Left intracerebral haemorrhage	Left intracerebral haematoma left caudate nucleus. Spasm and beading	Residual dysarthria and hypertonus of lower limbs and left upper limb
Lessing and Hyman (1989)	21	M	Amphetamine	Right hemiplegia within hours	Left fronto-parietal intracerebral haemorrhage	Not done at baseline. Normal at 10 weeks with no evidence of AVM or aneurysm. CT: left fronto-parietal haemorrhage with midline shift	Minimal right-handed signs (clumsiness)
Imanse and Vanneste (1990)	31	M	Amphetamine	Headache, seizure within minutes. Hypertension (190/110) and fever (38.5°C) at 1 hour	Intracranial intraventricular haemorrhage with extension to left frontal paraventricular area	Normal CT: extensive intraventricular haemorrhage	Moderate short-term memory disturbances
Shibata <i>et al</i> ⁴⁷	22	F	Methamphetamine	Seizure, loss of consciousness within minutes. Hypertension (160/100).	Subarachnoid and intracerebral haemorrhage	Haematoma. No aneurysm or AVM. At biopsy, many vessels showed medial necrosis	Death
Harries and De Silva (1992)	30	F	Amphetamine and ecstasy	Headache and right hemiparesis within hours	Left fronto-parietal intracerebral haemorrhage	Normal at 6 weeks. Baseline CT: haematoma	Survival, no further details
	22	F	Amphetamine	Headache, seizure, right hemiparesis within hours	Left frontal intracerebral haemorrhage	Left carotid angiogram normal. CT: frontal haematoma	Not stated
Hughes <i>et al</i> (1993)	22	F	Amphetamine	Headache within hours; hemiparesis within 12 hours	Left fronto-parietal intracerebral haemorrhage	Not performed. CT: large haemorrhage, oedema, midline shift	Residual right hemiparesis
Yen <i>et al</i> ⁶²	37	M	Methamphetamine	Vomiting, right hemiplegia, fever, hypertension (240/140) at 5 hours	Left putaminal intracerebral haemorrhage, intraventricular haemorrhage and subarachnoid haemorrhage	Not performed. CT: large intracerebral haemorrhage. Normal carotid and vertebral duplex ultrasound	Death
	17	M	Methamphetamine	Confusion and vomiting within 3 hours	Right fronto-temporo-parietal intracerebral haemorrhage with intraventricular haemorrhage	No vascular beading, AVM or aneurysm	Recovery of right hemiplegia (almost asymptomatic)
	24	M	Methamphetamine	Headache and right hemiplegia within 72 hours	Right parietal intracerebral haemorrhage with subarachnoid haemorrhage	Right middle cerebral artery AVM	Minimal right-sided weakness
	32	M	Methamphetamine	Confusion, headache, right hemiparesis within 24 hours. Hypertension (140/90) at 72 hours	Caudate intracerebral haemorrhage with intraventricular haemorrhage	No vascular beading, AVM or aneurysm	Mild weakness (right hemiparesis) and hemianopia
Selmi <i>et al</i> ³⁷	19	F	Methamphetamine	Headache, vomiting, left hemiparesis within hours	Right fronto-parietal intracerebral haemorrhage; subarachnoid haemorrhage	Vessel biopsy: varying luminal diameter	Recovery
Davis and Swallow (1994 and 1996) ⁴¹ †	42	M	Methamphetamine	Not stated	Subarachnoid haemorrhage	Rupture of berry aneurysm at junction of left internal carotid artery and posterior communicating branch. No small vessel vasculitis	Death
	27	F	Methamphetamine	Not stated	Subarachnoid haemorrhage	Rupture of berry aneurysm	Death
	38	F	Methamphetamine	Not stated	Subarachnoid haemorrhage	Rupture of berry aneurysm	Death
	26	F	Methamphetamine and cocaine	Not stated	Subarachnoid haemorrhage	Rupture of berry aneurysm	Death
El-Omar <i>et al</i> (1996)	23	F	Amphetamine	Left hemiparesis. Temporal relationship unclear	Right frontal intracerebral haemorrhage	Normal	Mild left hemiparesis

Continued

Table 1 Continued

Author	Age	Sex	Drug	Clinical features	Nature of stroke	Angiography	Outcomes
Chaudhuri <i>et al</i> (1999)	19	F	Amphetamine	Headache, seizures, left hemiplegia. Temporal relationship unclear. Death 5 days postadmission	Right basal ganglia intracerebral haemorrhage	Not performed. MRI: haemorrhage in white matter with midline shift	Death
Perez <i>et al</i> ⁷²	29	F	Methamphetamine	Weakness and hypertension (250/160). Temporal relationship unclear. Pregnant with h/o pregnancy-induced hypertension	Cerebellar and brainstem haemorrhage	Not performed. CT: large cerebellar and brainstem haemorrhage	Death
Buxton and McConachie (2000) ⁴⁹	27	M	Amphetamine	Headache, vomiting within 24 hours	Right temporal intracerebral haemorrhage	Normal	Recovery
	26	M	Amphetamine	Headache within 24 hours	Intracerebral (brainstem) haemorrhage	Normal	Recovery
	32	M	Amphetamine	Headache within 24 hours	Subarachnoid haemorrhage	Beading	Recovery
	30	M	Amphetamine	Headache within 24 hours	Right frontal intracerebral haemorrhage	Normal	Recovery
	30	M	Amphetamine	Headache, left hemiplegia within 24 hours	Right frontal intracerebral haemorrhage	Normal	Left hemiparesis
	24	M	Amphetamine	Right hemiplegia within 24 hours	Left frontal intracerebral haemorrhage	Normal	Right hemiparesis
	28	M	Amphetamine	Headache, coma within 24 hours	Left parietal intracerebral haemorrhage	Normal	Right hemiparesis and dysphasia
McEvoy <i>et al</i> ⁷²	22	F	Amphetamine	Headache, vomiting. Temporal relationship unclear	Subarachnoid haemorrhage	Normal	Recovery
	19	M	Amphetamine and ecstasy	Headache, vomiting. Temporal relationship unclear	Left occipital intracerebral haemorrhage and subarachnoid haemorrhage	Left occipital AVM	Recovery
	28	M	Amphetamine and ecstasy	Headache, vomiting. Temporal relationship unclear	Subarachnoid haemorrhage	Aneurysm in anterior communicating artery	Recovery
	29	M	Amphetamine and ecstasy	Headache, vomiting. Temporal relationship unclear	Subarachnoid haemorrhage	Aneurysm in posterior communicating artery	Recovery
	27	M	Amphetamine	Headache, confusion, left hemiparesis. Temporal relationship unclear	Right parietal intracerebral haemorrhage	Right parietal AVM	Severe residual disability
Zhu <i>et al</i> (2000) [†]	35	M	Methamphetamine	Not stated	Subarachnoid haemorrhage	Microscopy from autopsy not detailed	Fall leading to death
Agaba <i>et al</i> (2002)	26	F	Methamphetamine	Not stated	Intracerebral haemorrhage	Microscopy from autopsy not detailed	Death
	21	M	Amphetamine and ecstasy	Headache, vomiting within 24 hours	Right frontal intracerebral and left extradural haemorrhage	No AVM	Recovery
Miranda <i>et al</i> (2002)	21	F	Amphetamine (and heroin intravenously)	Headache, vomiting within hours	Right intracerebral haemorrhage in internal capsule	No AVM. No vascular abnormality	Residual left-sided weakness
Moriya and Hashimoto (2002)	43	M	Methamphetamine	Found dead	Intracranial intraventricular haemorrhage	Autopsy: no cerebral vasculature abnormalities	Death
Inamasu <i>et al</i> (2003)	32	F	Methamphetamine	Left hemiplegia, comatose within hours.	Right parietal intracerebral haemorrhage	Negative	Residual left hemiparesis
Chen <i>et al</i> (2003)	31	M	Amphetamine	Headache, vomiting. Temporal relationship unclear	Subarachnoid haemorrhage	Aneurysm in right internal carotid artery	Recovery

Continued

Table 1 Continued

Author	Age	Sex	Drug	Clinical features	Nature of stroke	Angiography	Outcomes
McGee <i>et al</i> ⁵⁹	31	M	Methamphetamine	Headache, left hemiparesis within 10 hours	Bilateral subarachnoid haemorrhage and intracerebral right frontal haemorrhage	No AVM, aneurysm or inflammation. No vasculitis	Death
Berankova <i>et al</i> ⁷³	31	M	Methamphetamine	Coma within 1 hour	Intracerebral haemorrhage in cerebellum	Autopsy: cerebral oedema with bleeding into cerebellum	Death
Klys <i>et al</i> (2005)	24	F	Amphetamine	Confusion, loss of consciousness within 24 hours; later right hemiparesis and hypertension (170/100)	Right-sided intracerebral haemorrhage	Two haematomas in deep structures; one in thalamus	Death
Schuff <i>et al</i> (2005)	40	M	Amphetamine (and heroin)	Not detailed	Basal ganglia cerebral haemorrhage	No AVM, no vasculitis at autopsy	Death
Ago <i>et al</i> (2006) [†]	20 [†]	M	Methamphetamine	Coma within hours	Subarachnoid haemorrhages in the left and right parietal lobes and cerebellum	SAH and intracerebral haematomas in hippocampus, hippocampal gyri, midbrain and pons	Death due to methamphetamine poisoning (renal failure secondary to rhabdomyolysis)
Pilgrim <i>et al</i> (2009) ⁶⁴ †	44	M	Methamphetamine and amphetamine	Coronary artery disease at autopsy	Intracranial haemorrhage	Autopsy: brain haemorrhage and methamphetamine toxicity	Death
	30	F	Methamphetamine	Cardiac hypoxic damage, pulmonary oedema at autopsy	Subarachnoid haemorrhage	Autopsy: ruptured right middle cerebral artery aneurysm	Death
	19	M	Methamphetamine, amphetamine, MDMA	Cardiomegaly, pulmonary oedema, enlarged liver at autopsy	Subarachnoid haemorrhage	Autopsy: ruptured berry aneurysm	Death
Chiu <i>et al</i> ⁶⁵	16	F	Methamphetamine	Nephrotic syndrome at autopsy	Intracerebral haemorrhage	Cerebral AVM	Death
	29	F	Methamphetamine	Left hemiparesis and headache within 48 hours	Intracerebral (brainstem) haemorrhage	No abnormality on angiogram. MRI: large brainstem haemorrhage	Left-sided hemiparesis and dysarthria
ISCHAEMIC STROKES							
Aldrich <i>et al</i> (1983) [§]	25	M	Amphetamine	Right hemiparesis. Diagnosis of syphilis made based on positive TPHA	Two ischaemic strokes secondary to occlusion of right internal carotid artery and narrowing of left internal carotid artery	Widespread occlusions in medium and small calibre vessels. Mild intimal thickening of superficial temporal artery	First: decreased motor function right hand; second right hemiparesis. Both resolved. Recovery
Rothrock <i>et al</i> ⁶⁰	35	M	Methamphetamine	Headache, right hemiplegia within 12 hours. Smoker and alcohol abuse.	Left midfrontal cortical ischaemic stroke	Occlusion of supraclinoid portion of left internal carotid artery	Non-fluent aphasia and mild right face and arm weakness
	22	M	Methamphetamine	Headache, left hemiplegia. 2 weeks after last use	Right fronto-parietal ischaemic stroke	Mild segmental narrowing 'beading' of right internal carotid artery. Poor filling of branches	Mild left hemiparesis
	23	M	Methamphetamine	Right hemiplegia and aphasia within 12 hours	Left frontal ischaemic stroke	Occlusion of left internal carotid artery	Moderate non-fluent aphasia and right arm weakness
Lambrecht <i>et al</i> ⁶⁰	37	M	Amphetamine and caffeine	Drowsy, hypertension (230/130) within 3 hours. Right hemiplegia after 9 hours. Smoker	Ischaemic stroke in distribution of left anterior cerebral artery	Not performed. CT: infarction in distribution of left anterior cerebral artery	Mild right-sided weakness
Yen <i>et al</i> ⁶²	34	M	Methamphetamine	Right hemiplegia, hypertension (184/104) at 30 hours	Parietal cerebral ischaemic stroke	No vascular beading, AVM or aneurysm	Minimal weakness (right hemiparesis)
	31	M	Methamphetamine	Right hemiparesis at 4 hours	Left temporo-parietal cerebral ischaemic stroke	Not performed. CT: temporo-parietal cerebral infarction	Outcome unknown (loss to follow-up)

Continued

Table 1 Continued

Author	Age	Sex	Drug	Clinical features	Nature of stroke	Angiography	Outcomes
Imanishi <i>et al</i> (1997)	37	M	methamphetamine	Coma, drug toxicity, hyperpyrexial (43.1°C). Temporal relationship unclear	Cerebral ischaemic stroke in left thalamus and basal ganglia	Autopsy: cerebral infarction secondary to bacterial embolus. No vasculitis	Death
Perez <i>et al</i> ⁷²	36	M	Methamphetamine	Right upper limb weakness within 12 hours. Hypertension (199/140) at 36 hours. H/o hypertension and smoking	Ischaemic stroke left basal ganglia	Not performed. CT: radiolucency left basal ganglia consistent with an ischaemic infarct. Doppler carotid arteries: negative	Recovery
	29	F	Methamphetamine, cocaine, marijuana	Right hemiparesis. Temporal relationship unclear. Smoker	Left middle cerebral artery distribution	Not performed. CT: left middle cerebral artery distribution infarct with visible thrombus. Carotid Doppler: thrombus left internal carotid artery	Residual aphasia and right hemiparesis
Ohta <i>et al</i> (2005) ⁵⁶ †	19	F	Methamphetamine	Headache, blurred vision, left hemiplegia. 3 months since last use	Delayed ischaemic stroke right occipital lobe	Narrowing and beading of right posterior cerebral artery	Residual left superior quadrant hemianopia and headache
McIntosh <i>et al</i> ³⁸	36	F	Methamphetamine	Right hemiparesis, aphasia within 12 hours. Smoker, oral contraceptive pill	Ischaemic stroke left frontal lobe (middle cerebral artery)	MRI: small infarct in the left frontal lobe. Narrowing in left internal carotid artery intimal flap and intramural thrombus indicative of carotid dissection	Recovery with mild expressive aphasia and right hemiparesis
	29	F	Methamphetamine	Right hemiparesis, aphasia 4 days post use	Ischaemic stroke in left frontal lobe (middle cerebral artery)	MRI: large left middle cerebral artery infarct. Narrowing in left common carotid artery, intimal flap and filling defect indicative of carotid dissection	Recovery with moderate expressive aphasia and mild right hand weakness
De Silva <i>et al</i> ⁵⁷	30	F	Amphetamine	Right hemiparesis, aphasia within 24 hours	Left parietal ischaemic stroke (left middle cerebral artery)	Irregularity of left middle cerebral artery. Beading. Vasculitis or vasospasm deemed cause. Microbolic signals at site suggest thrombosis leading to embolism in distal arteries	Not stated
Christensen <i>et al</i> ³³	33	M	Methamphetamine and amphetamine	Coma within hours	Bilateral cerebral ischaemic stroke extending from frontal to occipital lobes	Extensive necrosis of cerebral white matter bilaterally and of left cerebellar hemisphere. Extent of tissue damage deemed suggestive of vasospasm of large vessels	Death
Yew <i>et al</i> ⁷⁴	33	M	Methamphetamine	Right hemiparesis, dysphasia. Temporal relationship unclear. Smoker. H/o hypertension and cardiac failure	Ischaemic stroke in left basal ganglia (left total anterior circulation)	Not performed. CT: infarction left basal ganglia commensurate with left total anterior circulation ECG: Left ventricle hypertrophy and severely impaired function	Recovery
Azarpira <i>et al</i> ⁷⁵	33	M	Crystal methamphetamine	Right hemiparesis and aphasia, chest pain, hypertension (180/120) within hours. Smoker	Right-sided ischaemic stroke (and myocardial infarction)	Not performed. CT: right ischaemic stroke with midline shift. ECG: anterior wall myocardial infarction. Cause might be cerebral vasoconstriction or cardiac source of embolism	Brain death and death (support withdrawn)

* Full references for all studies not otherwise referenced in the text are provided in online supplementary file s2.

† Autopsy series.

‡ In 20s.

§ Also had syphilis.

¶ Infarction occurred 3 months following intravenous methamphetamine use (on patient's report).

AVM, arteriovenous malformation; BP, blood pressure; CT, computerized tomography; H/o, history of; MDMA, Methylene dioxy methamphetamine; TPHA, Treponema pallidum hemagglutination assay.

Table 2 Methamphetamine-related stroke reported in postmortem series

Publication	Findings
Logan <i>et al</i> ²⁷ methamphetamine deaths (n=146, all ages)	2 (1.4%) methamphetamine/disease-caused deaths were due to berry aneurysm and subarachnoid haemorrhage.
Karch <i>et al</i> ²⁸ Methamphetamine deaths (n=413) Drug-free trauma control (n=114) (all ages)	10 (2.4%) cases of subarachnoid and intracranial haemorrhage among those deaths where methamphetamine was detected compared with none in control group. Concluded that methamphetamine use is strongly associated with subarachnoid haemorrhage.
Kaye <i>et al</i> ²⁹ Methamphetamine deaths (n=371, all ages)	17 (5%) due to cerebral haemorrhage. Cerebrovascular complications were significantly more common in females.

Several epidemiological studies have demonstrated a significantly increased risk of stroke among young meth/amphetamine users.^{24 25} Westover and coworkers²⁵ conducted separate analyses for haemorrhagic and ischaemic stroke. Amphetamine use was significantly associated with a 4.95 increased risk of haemorrhagic stroke, a risk more than twice that conferred by either cocaine or tobacco use. The authors also noted a dramatic increase in the rate of amphetamine-associated stroke over the 3-year timeframe of their study, which was greater than the rate of increase in strokes associated with any other illicit drug. Consistent with these findings, Huang and coworkers²⁶ compared stroke events in a large cohort of methamphetamine users of all ages and found significantly increased risk of

haemorrhagic stroke among methamphetamine users, but not of ischaemic stroke.

Methamphetamine-related stroke in young people: case reports and case series

Table 1 summarises a total of 63 case studies and series of 98 strokes associated with methamphetamine use in young people aged <45 years.

Haemorrhagic stroke

Of the 81 reported strokes that were haemorrhagic, the male to female ratio was 2:1. There was variation in the route of

Table 3 Methamphetamine-related stroke reported in case control and epidemiological studies

Publication	Subject characteristics	Findings
Toffol <i>et al</i> ¹⁵	15–45 years Spontaneous intracerebral haemorrhage series n=72 of whom n=5 (7%) amphetamine	Five cases related to amphetamines (four oral; one IV). Three in cerebral lobes and two basal ganglia (putamen). All arteriograms normal.
Kaku and Lowenstein ²⁰	15–44 years case-control, ischaemic and haemorrhagic stroke n=214 illicit drugs, of whom n=12 (6%) amphetamine	Relative risk of stroke in illicit drug use: 6.5 (ischaemic) and 11.7 (haemorrhagic) in those aged 35 and below. Of 12 cases caused by amphetamine: Eight haemorrhagic: two subarachnoid and six intracerebral Four ischaemic: two thrombotic and two embolic.
Sloan <i>et al</i> ²¹	15–44 years ischaemic stroke series n=51 of whom n=1 (2%) amphetamine	Risk factors in those with substance use: higher rates smoking; lower rates hypertension and diabetes. Mechanism in those with substance use: cardioembolic, large and small vessel occlusive disease.
Petitti <i>et al</i> ²⁴	15–44 years incident stroke in women retrospective case-control n=347 illicit drugs, of whom n=20 (6%) amphetamine/cocaine n=1021 controls	Amphetamine use associated with a 3.8 times higher risk for stroke than no substance use. Separate ORs for haemorrhagic and ischaemic stroke not reported.
Westover <i>et al</i> ²⁵	18–44 years Population-based study of hospitalised stroke n=937 haemorrhagic and n=998 ischaemic	Amphetamine abuse strongly associated with haemorrhagic stroke (OR=4.95) but not with ischaemic stroke (OR=1.04). Strength of association between haemorrhagic stroke and amphetamine use more than double that of cocaine or tobacco, but less than that of cerebrovascular anomalies, intracranial tumours and hypertension. Amphetamine use associated with increased risk of death following haemorrhagic stroke.
Ho <i>et al</i> (2009)	All-age methamphetamine-associated stroke series n=10 ischaemic and n=20 haemorrhagic	11 ICH: locations typical for hypertensive ICH: basal ganglia, thalamus, pons, subcortical white matter. 9 SAH: all secondary to aneurysm. Postmortem exam in one case of ischaemic stroke found accelerated atherosclerosis, but no evidence of inflammation.
Phillips <i>et al</i> ¹⁶	15–50 years Ischaemic stroke series n=326 n=19 (6%) amphetamines, predominantly intravenous	High rate (9%) of strokes in anterior and posterior circulations concurrently. 24% of these used amphetamine intravenously, significantly higher prevalence than in population as a whole, suggestive that intravenous amphetamine use may cause simultaneous infarction in multiple sites.
Beadell <i>et al</i> ²⁰	All-age spontaneous intracerebral haemorrhage cohort n=374 n=28 (7%) methamphetamine	Methamphetamine users had worse outcomes than age-matched controls at discharge (Glasgow Outcome Scale score).
Moon <i>et al</i> ³¹	All-age series of aneurysmal subarachnoid haemorrhage n=398 n=31 (8%) methamphetamine	Methamphetamine use associated with higher rates tobacco and cocaine use and younger age. No association with severity of presentation but methamphetamine use independently predicted poorer outcomes at 1 and 3 years (Glasgow Outcome Scale), despite strong association of older age and poor outcome.
Nakagawa <i>et al</i> ³²	All-age spontaneous intracerebral haemorrhage cohort n=193 n=25 (13%) methamphetamine	Higher prevalence of methamphetamine use among Native Hawaiian and Other Pacific Islanders (24%) compared with White (0%) and Asian (12%). Conclude racial disparities in methamphetamine-associated intracerebral haemorrhage.
Huang <i>et al</i> ²⁶	All-age stroke series n=1315 methamphetamine users n=54 stroke events	Significantly higher incidence of haemorrhagic stroke compared with control group in the methamphetamine cohort (Hazard Ratio=2.09; p=0.001), but no significant difference for ischaemic stroke or subarachnoid stroke.

ICH, Intracerebral haemorrhage; SAH, subarachnoid haemorrhage.

administration, with an oral to injection to inhalation ratio of 3:3:1. Methamphetamine-related stroke was thus not solely associated with a particular route of administration. Headache was a prominent early clinical feature, with vomiting, one-sided weakness and seizures often developing over time. ICHs were present in 60 cases, predominantly in the temporal, parietal and occipital cortices. Less common sites were the cerebellum (two) and brainstem (three). There were 32 cases of subarachnoid haemorrhage (SAH), among whom 13 had both ICH and SAH. Intraventricular haemorrhage was present in five cases, but only in one case in the absence of ICH. Aneurysms and AVMs were present in 17% and 8%, respectively. Other vasculature abnormalities were reported in a third of cases, most commonly beading of vessel wall or cerebral arteritis with or without occlusive changes in the small arteries. Irregularities of the vessel lumen were present in a minority of cases. No abnormality of vasculature was found in less than half of cases (47%).

Haemorrhagic stroke resulted in death in a third of cases. Complete recovery was reported in one quarter and the remainder (approximately 40%) had residual symptoms ranging from mild weakness and memory difficulties, to permanent hemiparesis, speech and language difficulties and visual defects.

Ischaemic stroke

Of the 17 ischaemic strokes, the male to female ratio was 12:5. The route of administration differed notably from haemorrhagic stroke with a higher preponderance of inhalational use (the oral:injection:inhalation ratio was 1:1:4). Again, these strokes occurred across all routes of administration. Headache was again the predominant early presenting feature, with hypertension frequently reported. Ischaemic strokes were predominantly located in regions whose blood supply derives from the anterior circulation: the frontal and parietal lobes and/or the basal ganglia. A minority were located in the occipital lobe or caudal thalamus indicating a posterior circulation infarction. One case extended from frontal to occipital lobes, suggestive of involvement of both anterior and posterior circulations. Of note, Philips and coworkers¹⁶ found that methamphetamine use was significantly more common among individuals aged 15–50 years with stroke involving both vascular territories compared with their whole study population. Angiography was less commonly conducted in ischaemic stroke cases. Where performed, beading suggestive of arteritis was present in three cases and intimal wall thickening in one. No abnormality was detected in four cases, which was interpreted by some authors as suggestive that vasospasm may have been the cause, due to absence of any permanent vessel occlusion.³³ Other causes of infarction included bacterial embolus (one case) and thrombus from carotid artery dissection (two cases).

The outcome was death in approximately 20% of cases. Complete recovery was achieved in a further 20%. The majority of cases (approximately 60%), however, experienced residual impairments such as hemiparesis, speech and visual deficits.

DISCUSSION

This review highlights the preponderance of haemorrhagic rather than ischaemic strokes associated with methamphetamine use in young people. In case reports and series, 80% of methamphetamine-related strokes reported were haemorrhagic. This is strikingly high compared with reported rates of haemorrhagic stroke in stroke populations below 45 years (40%–55%) and higher again than in the general stroke population (15%–20%).¹² Thus it is possible that this may to some extent reflect reporting

bias. Thus, it is possible that instances of young individuals experiencing haemorrhagic stroke associated with methamphetamine use may be more likely to be reported, and the resultant case study published, than is the case for ischaemic stroke. Both ischaemic and haemorrhagic strokes occur in young people. While haemorrhagic strokes are relatively more common than in older stroke populations, ischaemic strokes remain more common than haemorrhagic even in young people.¹³ Alternatively, it may be that the cases reported reflect the number of cases occurring. Moreover, the finding is in keeping with population-based evidence that methamphetamine use is associated with a highly increased risk of haemorrhagic stroke among individuals aged 18–44 years.²⁵ A significantly increased preponderance of haemorrhagic compared with ischaemic strokes was found in several stroke case series.^{26–35} While the ratios were less stark than the 4:1 reported here, both studies considered all-age populations (in which ischaemia would be expected to be more prominent), rather than young adults. Furthermore, the cerebrovascular pathology reported here must be viewed within the context of a range of known methamphetamine-related cardiovascular pathologies, including accelerated atherosclerosis, ischaemic heart disease, hypertensive heart disease, various cardiomyopathies, arrhythmias, cardiomegaly and aortic dissection.^{7 8 22 23 26}

Individual and use-related characteristics

In keeping with previous reports,³⁴ this review highlights that strokes can occur following any route of methamphetamine administration. Haemorrhagic strokes occurred following oral or intravenous use in similar numbers. Stroke may result following injection of any drug due to increased risk of bacterial endocarditis and embolism, or due to the use of fillers such as talc, which may contribute to both ischaemic and haemorrhagic stroke.³⁶ Injecting alone, however, does not explain all strokes. In these cases, it is use of methamphetamine that confers the risk. The proportions of strokes due to oral, injecting or inhalational routes may reflect general use prevalence of the drug, but it is noteworthy that starkly different use patterns exist between ischaemic and haemorrhagic strokes, with a relatively higher proportion of ischaemic strokes associated with inhalation. Methamphetamine-associated stroke was less common in women than men, which may reflect the 3:1 ratio of use patterns in the general population, and/or other risk factors for stroke in this age population.^{15 17} Many studies did not report additional risk factors for stroke in the affected individuals, suggesting that in this young population haemorrhagic strokes in particular were related primarily to methamphetamine use. However, the presence of other undetected or unreported risk factors cannot be excluded. In the ischaemic stroke literature, other risk factors for stroke were detailed in some cases (table 1). It is notable that several young people were reported to have resting hypertension, which may or may not been a consequence of chronic methamphetamine use.

Where methamphetamine use has directly led to a stroke, headache, nausea, vomiting and confusion (and sometimes motor and sensory neurological signs) are early symptoms of stroke that will typically onset within minutes to hours of taking the drug.³⁷ Hypertension is more often detected when medical support is sought quickly, presumably due to the effects of the drug still being present. The time from most recent use to onset of symptoms (or help-seeking for these) varied widely between studies from hours to weeks. It is likely that this range of use histories and use-to-stroke intervals is explained by different mechanisms of action of methamphetamine-associated stroke

that include hypertension, vasculitis, direct vascular toxicity and vasospasm.³⁸

Pathogenesis of haemorrhagic stroke

Intracranial haemorrhage may occur secondary to methamphetamine-induced hypertension and tachycardia, even in the absence of pre-existing cerebrovascular disease.³⁹ Transient increases in blood pressure caused by methamphetamine through its direct action as a sympathomimetic agent may lead to ICH. Repeated use can raise blood pressure, increasing the risk for stroke, even in those without baseline hypertension.⁴⁰ As is the case in essential hypertension, intracranial haemorrhage risk is increased by vessel wall damage that increases the likelihood of subsequent rupture and haemorrhage, particularly during an acute stress such as methamphetamine use.³⁵

Chronic use can cause long-term systemic hypertension,^{5 7} a major risk factor for stroke. Both methamphetamine and cocaine contribute to physiological vascular fatigue by their pharmacological actions of hypertension and tachycardia.⁴¹ The more prolonged cardiovascular effect of methamphetamine compared with cocaine⁴¹ is a possible explanation for increased rates of ICH in methamphetamine abuse compared with cocaine.²⁵ Vascular fatigue in a berry aneurysm leads to rupture and, often, to death. Furthermore, because vascular fatigue is cumulative, chronic previous methamphetamine use may be a significant factor in the development of berry aneurysms.⁴¹ McEvoy and coworkers⁴² suggest that cerebral aneurysms may form acutely in response to hypertensive crisis and or vasculitis induced by methamphetamine use.

Methamphetamine-induced subarachnoid haemorrhage in the absence of berry aneurysm or AVM can occur associated with necrotising angiitis.^{43–47} Methamphetamine is believed to directly affect the integrity of vasculature, giving rise to fibrinoid necrosis of the intima and media of blood vessel walls and destruction of their vascular smooth muscle predisposing to vessel rupture.^{46 47} Affected vessels are described to have a 'beaded' appearance with segmental narrowing and aneurysm formation⁴⁶ also referred to as cerebral arteritis. Angiography and tissue microscopic examination have identified these abnormalities following intravenous,^{43 44 48} oral^{45 49} and inhalational use.⁵⁰ In some cases, where angiography was repeated several weeks later, these appearances were no longer present^{51 52} suggesting that these may be transient abnormalities that remit on drug discontinuation or following corticosteroid treatment.⁵³ Cerebral vasculitis is not specific to meth/amphetamine and is associated with the abuse of other illicit drugs, including cocaine and heroin.⁵⁴ The possibility that methamphetamine may induce these changes is supported by animal models that show microaneurysm formation, spasm and perivascular cuffing in brains of adult Rhesus monkeys following intravenous injection of methamphetamine over 2 weeks.⁵⁵

Pathogenesis of ischaemic stroke

Methamphetamine-associated ischaemic strokes may occur by various mechanisms. Vasculitis has been demonstrated in several young people with cerebral infarction secondary to methamphetamine use.^{50 56 57} Methamphetamine-associated cerebral vasculitis and its characteristic arterial narrowing, cerebral artery beading and pronounced irregularity of flow^{50 51} may increase the potential for a vessel to become occluded, such as in acute vascular spasm, with consequent ischaemia and infarction in the brain region supplied by the affected vessel.^{50 58 59} Vasospasm or cerebral vasoconstriction may follow a rapid rise in blood

pressure⁶⁰ and/or direct stimulation by methamphetamine of sympathomimetic α -adrenergic and β -adrenergic receptors, with resultant ischaemia.⁶¹

In a large case series of 30 all-age methamphetamine related stroke, however, Ho and coworkers³⁵ found no evidence of an inflammatory vasculitic process underlying ischaemic stroke. Rather, they concluded that methamphetamine-associated vessel damage may occur as a result of accelerated atherosclerosis. Methamphetamine increases both systolic and diastolic blood pressures. Repeated exposure to transient use-related hypertension or the development of chronic hypertension in habitual methamphetamine users exposes individuals to heightened risk of arteriosclerosis pathogenesis, and associated arterial weakness, many years prematurely compared with the general population. Methamphetamine may also increase the risk of stroke through the highly increased risk of cardiomyopathy, and with that an increased risk of arrhythmias and thrombosis, leading to thromboembolic strokes.

As is the case for haemorrhagic stroke, methamphetamine-induced ischaemic stroke may occur in the absence of evidence of cerebral vascular abnormalities, chronic hypertension⁶² or other stroke risk factors.⁶³ Other reports, however, indicate that patients with methamphetamine-associated stroke do carry additional risk factors for stroke including smoking, alcohol, hyperlipidaemia and AVM.^{62 64 65} Lifestyle factors associated with methamphetamine use including smoking and alcohol are likely to increase risk of stroke development as may additional common risk factors such as stroke history in either parent,⁶⁶ dyslipidaemia and diabetes mellitus.¹⁷

Prognosis and outcomes

This review demonstrated that complete recovery was achieved in less than a quarter of cases. One-third of haemorrhagic strokes and one quarter of ischaemic strokes resulted in death. The remainder of individuals suffered a range of disability. It is likely that minor transient cerebrovascular events that resolve spontaneously would not result in help-seeking in this population, so the cases reported in the literature may reflect the more severe end of the spectrum. Nonetheless, these results compare unfavourably with evidence from a recent case series of all-cause stroke patients aged 16–45 years in whom an outcome of absence of symptoms is achieved by approximately two-thirds with a much lower death rate (3%).⁶⁷ It is well known that among young people strokes associated with substance use carry a higher mortality.²⁰ There is evidence for methamphetamine-associated aneurysmal subarachnoid haemorrhage that clinical outcomes are worse than age-matched controls at discharge³⁰ and at 1-year and 3-year follow-up.³¹

Clinical implications

This review highlights the heightened risk of haemorrhagic stroke associated with methamphetamine use. With the use of methamphetamine increasing, particularly more potent forms, there is a growing burden of methamphetamine-related disease and harms, particularly among young people, in whom the majority of methamphetamine use occurs. Indeed, it is likely that methamphetamine abuse is making a disproportionate contribution to the increased incidence of stroke among young people observed over recent years.^{12 25}

Clinicians treating methamphetamine users, and users themselves, need to be aware of the elevated risk of stroke in young methamphetamine users and to be aware of early signs and symptoms. Of note, symptoms such as paraesthesiae, headache,

speech and language difficulties and visual defects, may be experienced transiently as a result of vasospasm, for example, and may herald later experience of a catastrophic stroke event. Conversely, young people presenting with signs and symptoms of stroke may well be methamphetamine users, highlighting the need for illicit drug use to be investigated as a contributory cause. A thorough substance use history should be sought and toxicological screening of urine and serum performed in young people presenting with stroke. This review focused on illicit amphetamine use and the data relating to stroke associated with prescribed amphetamines is beyond its scope. The possibility of increased stroke risk related to prescribed amphetamines for conditions such as attention deficit disorder is important and has been reviewed elsewhere.⁶⁸ Similarly, the therapeutic use of amphetamines in stroke recovery has been systematically reviewed and found to be associated with increased death compared with control groups.⁶⁹ Due consideration should be given to these risks when contemplating treatment options in young people.

The increased risk of haemorrhagic stroke in particular should be highlighted to young people who may use methamphetamine and to their communities in order to ensure appropriate help seeking, detection and intervention. Increasing the number of methamphetamine users in treatment appears to be a priority. There are no proven pharmacotherapies for methamphetamine dependence,⁷⁰ but long-term residential rehabilitation has been shown to reduce methamphetamine use and harm.⁷¹

CONCLUSIONS

There is a preponderance of haemorrhagic strokes associated with methamphetamine use in young people, and methamphetamine-related stroke is associated with poorer clinical outcomes. Mechanisms of methamphetamine-associated stroke include hypertension, vasculitis, direct vascular toxicity and vasospasm. In a period of rising worldwide methamphetamine use, the incidence of methamphetamine-related stroke will increase, with a consequent increase in the burden of disease contributed by such events.

Acknowledgements We wish to thank Mary Kumvaj for her assistance and insights in conducting the literature review.

Contributors Dr JML performed the literature searches and conducted the statistical analyses and write-up of the paper. Professors SD and MF contributed to writing the manuscript and to subsequent revisions. All authors have approved the final manuscript.

Competing interests None declared.

Provenance and peer review Not commissioned; externally peer reviewed.

© Article author(s) (or their employer(s) unless otherwise stated in the text of the article) 2017. All rights reserved. No commercial use is permitted unless otherwise expressly granted.

REFERENCES

- Degenhardt L, Hall W. Extent of illicit drug use and dependence, and their contribution to the global burden of disease. *Lancet* 2012;379:55–70.
- Degenhardt L, Whiteford HA, Ferrari AJ, et al. Global burden of disease attributable to illicit drug use and dependence: findings from the global burden of disease study 2010. *Lancet* 2013;382:1564–74.
- United Nations Office on Drugs and Crime. World Drug Report 2016. New York: United Nations. 2016.
- Callaghan RC, Cunningham JK, Verdichevski M, et al. All-cause mortality among individuals with disorders related to the use of methamphetamine: a comparative cohort study. *Drug Alcohol Depend* 2012;125:290–4.
- Darke S, Kaye S, McKetin R, et al. Major physical and psychological harms of methamphetamine use. *Drug Alcohol Rev* 2008;27:253–62.
- Darke S, Torok M, McKetin R, et al. Patterns of psychological distress related to regular methamphetamine and opioid use. *Addict Res Theory* 2011;19:121–7.
- Karch SB. *Karch's Pathology of Drug Abuse*. 4th edition. Boca Raton: CRC Press, 2009.
- Lappin JM, Roxburgh A, Kaye S, et al. Increased prevalence of self-reported psychotic illness predicted by crystal methamphetamine use: evidence from a high-risk population. *Int J Drug Policy* 2016;38:16–20.
- European Monitoring Centre for Drugs and Drug Addiction. *Exploring methamphetamine trends in Europe EMCCDA Papers*. Luxembourg: Publications Office of the European Union, 2014.
- Murray CJ, Vos T, Lozano R, et al. Disability-adjusted life years (DALYs) for 291 diseases and injuries in 21 regions, 1990–2010: a systematic analysis for the global burden of disease study 2010. *Lancet* 2012;380:2197–223.
- Sordo L, Indave BI, Barrio G, et al. Cocaine use and risk of stroke: a systematic review. *Drug Alcohol Depend* 2014;142:1–13.
- Griffiths D, Sturm J. Epidemiology and etiology of young stroke. *Stroke Res Treat* 2011;2011:209370.
- Kissela BM, Khoury JC, Alwell K, et al. Age at stroke: temporal trends in stroke incidence in a large, biracial population. *Neurology* 2012;79:1781–7.
- Zebian B, Critchley G. Spontaneous intracranial haemorrhage. *Surgery* 2012;30:136–41.
- Toffol GJ, Biller J, Adams HP. Nontraumatic intracerebral hemorrhage in young adults. *Arch Neurol* 1987;44:483–5.
- Phillips MC, Leyden JM, Chong WK, et al. Ischaemic stroke among young people aged 15 to 50 years in Adelaide, South Australia. *Med J Aust* 2011;195:610–4.
- Putala J, Haapaniemi E, Kaste M, et al. How does number of risk factors affect prognosis in young patients with ischemic stroke? *Stroke* 2012;43:356–61.
- Center for Behavioral Health Statistics and Quality. *Behavioral health trends in the United States: results from the 2014 National Survey on Drug Use and Health*. Rockville: US Department of Health and Human Services, 2015.
- Lader D. *Drug Misuse: findings from the 2015/16 crime survey for England and Wales*. Second edition. London: Home Office, 2016.
- Kaku DA, Lowenstein DH. Emergence of recreational drug abuse as a Major risk factor for stroke in young adults. *Ann Intern Med* 1990;113:821–7.
- Sloan MA, Kittner SJ, Feeser BR, et al. Illicit drug-associated ischemic stroke in the Baltimore-Washington Young Stroke Study. *Neurology* 1998;50:1688–93.
- Neeki MM, Kulczycki M, Toy J, et al. Frequency of Methamphetamine Use as a Major contributor toward the severity of Cardiomyopathy in adults ≤50 Years. *Am J Cardiol* 2016;118:585–9.
- Voskoboinik A, Ihle JF, Bloom JE, et al. Methamphetamine-associated cardiomyopathy: patterns and predictors of recovery. *Intern Med J* 2016;46:723–7.
- Petitti DB, Sidney S, Quesenberry C, et al. Stroke and cocaine or amphetamine use. *Epidemiology* 1998;9:596–600–600.
- Westover AN, McBride S, Haley RW. Stroke in young adults who abuse amphetamines or cocaine: a population-based study of hospitalized patients. *Arch Gen Psychiatry* 2007;64:495–502.
- Huang MC, Yang SY, Lin SK, et al. Risk of Cardiovascular Diseases and Stroke events in Methamphetamine Users: a 10-Year Follow-Up study. *J Clin Psychiatry* 2016;77:1396–403.
- Logan BK, Fligner CL, Haddix T. Cause and manner of death in fatalities involving methamphetamine. *J Forensic Sci* 1998;43:16085J–34.
- Karch SB, Stephens BG, Ho C-H. Methamphetamine-related deaths in San Francisco: demographic, pathologic, and toxicologic profiles. *J Forensic Sci* 1999;44:14464J–8.
- Kaye S, Darke S, Duffou J, et al. Methamphetamine-related fatalities in Australia: demographics, circumstances, toxicology and Major organ pathology. *Addiction* 2008;103:1353–60.
- Beadell NC, Thompson EM, Delashaw JB, et al. The deleterious effects of methamphetamine use on initial presentation and clinical outcomes in aneurysmal subarachnoid hemorrhage. *J Neurosurg* 2012;117:781–6.
- Moon K, Albuquerque FC, Mitkov M, et al. Methamphetamine use is an independent predictor of poor outcome after aneurysmal subarachnoid hemorrhage. *J Neurointerv Surg* 2015;7:346–50.
- Nakagawa K, Vento MA, Ing MM, et al. Racial disparities in methamphetamine-associated intracerebral hemorrhage. *Neurology* 2015;84:995–1001.
- Christensen MR, Lesnikova I, Madsen LB, et al. Drug-induced bilateral ischemic infarction in an amphetamine addict. *Forensic Sci Med Pathol* 2013;9:458–61.
- Conci F, D'Angelo V, Tampieri D, et al. Intracerebral hemorrhage and angiographic beading following amphetamine abuse. *Ital J Neurol Sci* 1988;9:77–81.
- Ho EL, Josephson SA, Lee HS, et al. Cerebrovascular complications of methamphetamine abuse. *Neurocrit Care* 2009;10:295–305.
- Kelly MA, Gorelick PB, Mirza D. The role of drugs in the etiology of stroke. *Clin Neuropharmacol* 1992;15:249–75.
- Selmi F, Davies KG, Sharma RR, et al. Intracerebral haemorrhage due to amphetamine abuse: report of two cases with underlying arteriovenous malformations. *Br J Neurosurg* 1995;9:93–6.
- McIntosh A, Hungs M, Kostanian V, et al. Carotid artery dissection and middle cerebral artery stroke following methamphetamine use. *Neurology* 2006;67:2259–60.
- Harrington H, Heller HA, Dawson D, et al. Intracerebral hemorrhage and oral amphetamine. *Arch Neurol* 1983;40:503–7.
- Esse K, Fossati-Bellani M, Traylor A, et al. Epidemic of illicit drug use, mechanisms of action/addiction and stroke as a health hazard. *Brain Behav* 2011;1:44–54.

- 41 Davis GG, Swallowell CI. The incidence of acute cocaine or methamphetamine intoxication in deaths due to ruptured cerebral (berry) aneurysms. *J Forensic Sci* 1996;41:13965J–8.
- 42 McEvoy AW, Kitchen ND, Thomas DG. Intracerebral haemorrhage and drug abuse in young adults. *Br J Neurosurg* 2000;14:449–54.
- 43 Edwards KR. Hemorrhagic complications of cerebral arteritis. *Arch Neurol* 1977;34:549–52.
- 44 Kessler JT, Jortner BS, Adapon BD. Cerebral vasculitis in a drug abuser. *J Clin Psychiatry* 1978;39:559–64.
- 45 Matick H, Anderson D, Brumlik J. Cerebral vasculitis associated with oral amphetamine overdose. *Arch Neurol* 1983;40:253–4.
- 46 Ogasawara K, Ogawa A, Kita H, et al. [Intracerebral hemorrhage and characteristic angiographic changes associated with methamphetamine--a case report]. *No To Shinkei* 1986;38:967–71.
- 47 Shibata S, Mori K, Sekine I, et al. Subarachnoid and intracerebral hemorrhage associated with necrotizing angitis due to methamphetamine abuse--an autopsy case. *Neurol Med Chir* 1991;31:49–52.
- 48 Rumbaugh CL, Bergeron RT, Fang HC, et al. Cerebral angiographic changes in the drug abuse patient. *Radiology* 1971;101:335–44.
- 49 Buxton N, McConachie NS. Amphetamine abuse and intracranial haemorrhage. *J R Soc Med* 2000;93:472–7.
- 50 Rothrock JF, Rubenstein R, Lyden PD. Ischemic stroke associated with methamphetamine inhalation. *Neurology* 1988;38:589–92.
- 51 Yu YJ, Cooper DR, Wellenstein DE, et al. Cerebral angitis and intracerebral hemorrhage associated with methamphetamine abuse. Case report. *J Neurosurg* 1983;58:109–11.
- 52 Salanova V, Taubner R. Intracerebral haemorrhage and vasculitis secondary to amphetamine use. *Postgrad Med J* 1984;60:429–30.
- 53 Kase CS. Intracerebral hemorrhage: non-hypertensive causes. *Stroke* 1986;17:590–5.
- 54 Citron BP, Halpern M, McCarron M, et al. Necrotizing angitis associated with drug abuse. *N Engl J Med* 1970;283:1003–11.
- 55 Rumbaugh CL, Bergeron RT, Scanlan RL, et al. Cerebral vascular changes secondary to amphetamine abuse in the experimental animal. *Radiology* 1971;101:345–51.
- 56 Ohta K, Mori M, Yoritaka A, et al. Delayed ischemic stroke associated with methamphetamine use. *J Emerg Med* 2005;28:165–7.
- 57 De Silva DA, Wong MC, Lee MP, et al. Amphetamine-associated ischemic stroke: clinical presentation and proposed pathogenesis. *J Stroke Cerebrovasc Dis* 2007;16:185–6.
- 58 Bostwick DG. Amphetamine induced cerebral vasculitis. *Hum Pathol* 1981;12:1031–3.
- 59 McGee SM, McGee DN, McGee MB. Spontaneous intracerebral hemorrhage related to methamphetamine abuse: autopsy findings and clinical correlation. *Am J Forensic Med Pathol* 2004;25:334–7.
- 60 Lambrecht GL, Mailbrain ML, Chew SL, et al. Intranasal caffeine and amphetamine causing stroke. *Acta Neurol Belg* 1993;93:146–9.
- 61 Büttner A. Review: the neuropathology of drug abuse. *Neuropathol Appl Neurobiol* 2011;37:118–34.
- 62 Yen DJ, Wang SJ, Ju TH, et al. Stroke associated with methamphetamine inhalation. *Eur Neurol* 1994;34:16–22.
- 63 Sachdeva K, Woodward KG. Caudal thalamic infarction following intranasal methamphetamine use. *Neurology* 1989;39:305–6.
- 64 Pilgrim JL, Gerostamoulos D, Drummer OH, et al. Involvement of amphetamines in sudden and unexpected death. *J Forensic Sci* 2009;54:478–85.
- 65 Chiu ZK, Bennett IE, Chan P, et al. Methamphetamine-related brainstem haemorrhage. *J Clin Neurosci* 2016;32:137–9.
- 66 Kiely DK, Wolf PA, Cupples LA, et al. Familial aggregation of stroke. the Framingham Study. *Stroke* 1993;24:1366–71.
- 67 Goeggel Simonetti B, Mono ML, Huynh-Do U, et al. Risk factors, aetiology and outcome of ischaemic stroke in young adults: the swiss young Stroke Study (SYSS). *J Neurol* 2015;262:2025–32.
- 68 Westover AN, Halm EA. Do prescription stimulants increase the risk of adverse cardiovascular events?: a systematic review. *BMC Cardiovasc Disord* 2012;12:41.
- 69 Sprigg N, Bath PM. Speeding stroke recovery? A systematic review of amphetamine after stroke. *J Neurol Sci* 2009;285:3–9.
- 70 Darke S, Farrell M. Which medications are suitable for agonist drug maintenance? *Addiction* 2016;111:767–74.
- 71 McKetin R, Najman JM, Baker AL, et al. Evaluating the impact of community-based treatment options on methamphetamine use: findings from the Methamphetamine treatment evaluation study (MATES). *Addiction* 2012;107:1998–2008.
- 72 Perez JA, Arsuara EL, Strategos S. Methamphetamine-related stroke: four cases. *J Emerg Med* 1999;17:469–71.
- 73 Beránková K, Habrdová V, Balíková M, et al. Methamphetamine in hair and interpretation of forensic findings in a fatal case. *Forensic Sci Int* 2005;153:93–7.
- 74 Yew KL, Go CS, Razali F, et al. Methamphetamine-associated reversible cardiomyopathy and stroke risk. *Eur Rev Med Pharmacol Sci* 2014;18:2403–4.
- 75 Azarpira N, Pourjafar M, Delavar-Kasmai H. Concurrent myocardial and cerebral infarctions after crystal methamphetamine use. *Neurosurg Q* 2015;25:286–7.

JOURNAL OF NEUROLOGY NEUROSURGERY & PSYCHIATRY

Methamphetamine use linked to heightened stroke risk in the young

Brain bleed rather than clot most common stroke type; men twice as likely as women to succumb

The stimulant methamphetamine, also popularly known as 'speed,' 'ice' and 'meth,' is linked to a heightened risk of stroke among young people, reveals a review of the available evidence, published online in the ***Journal of Neurology Neurosurgery & Psychiatry***.

A stroke caused by a bleed into the brain (haemorrhagic) rather than a clot (ischaemic) is the most common type associated with taking this drug, with men twice as likely to succumb as women, the findings show.

Given the often disabling or fatal consequences of a stroke, and the increasing use of methamphetamine among young people, particularly in countries around the Pacific rim (North America, East and Southeast Asia, and Oceania), the findings are a cause for concern, warn the researchers.

They base their findings on a comprehensive trawl of research looking at a potential link between methamphetamine use and associated stroke risk in young people (under the age of 45), and published up to February 2017.

They found 77 relevant pieces of research out of 370, including epidemiological studies and case report series.

Some 81 haemorrhagic and 17 ischaemic strokes were reported. Both types were around twice as common in men as they were in women.

In the case reports/series, eight out of 10 strokes associated with the use of methamphetamine use among young people were haemorrhagic.

This is much higher than reported rates of this type of stroke in people under the age of 45 (40-50%) or in older people (15-20%), the researchers point out.

Methamphetamine can be swallowed, inhaled, or injected. Haemorrhagic strokes were equally associated with swallowing the drug and injecting it while inhalation was the most common method of getting high associated with ischaemic stroke.

Haemorrhagic stroke was associated with vascular abnormalities, such as high blood pressure and vasculitis (inflamed blood vessels), in a third of cases. Repeated use of methamphetamine can drive up blood pressure even in those whose blood pressure is normal to start with, say the researchers.

Risk of death was also higher after a haemorrhagic stroke: one in four people recovered completely, but a third died. This compares with complete recovery for one in five people and death in one in five after an ischaemic stroke.

“With the use of methamphetamine increasing, particularly more potent forms, there is a growing burden of methamphetamine related disease and harms, particularly among young people, in whom the majority of methamphetamine use occurs,” write the researchers.

“Indeed, it is likely that methamphetamine abuse is making a disproportionate contribution to the increased incidence of stroke among young people observed over recent years,” they add.