

Cerebellar atrophy in neurodegeneration—a meta-analysis

Helena M Gellersen,¹ Christine C Guo,² Claire O'Callaghan,^{3,4} Rachel H Tan,^{4,5} Saber Sami,⁶ Michael Hornberger^{7,8}

► Additional material is published online only. To view, please visit the journal online (<http://dx.doi.org/10.1136/jnnp-2017-315607>).

¹Department of Cognitive Neuroscience, Faculty of Psychology and Neuroscience, Maastricht University, Maastricht, The Netherlands

²Mental Health Program, QIMR Berghofer Medical Research Institute, Herston, Queensland, Australia

³Behavioural and Clinical Neuroscience Institute and Department of Psychology, University of Cambridge, Cambridge, UK

⁴Brain and Mind Centre, Sydney Medical School, The University of Sydney, Sydney, Australia

⁵Neuroscience Research Australia, Sydney, Australia

⁶Department of Clinical Neuroscience, University of Cambridge, Cambridge, UK

⁷Norwich Medical School, University of East Anglia, Norwich, UK

⁸Dementia and Complexity in Later Life, NHS Norfolk and Suffolk Foundation Trust, UK

Correspondence to

Professor Michael Hornberger, Norwich Medical School, University of East Anglia, Norwich, UK; m.hornberger@uea.ac.uk

Received 17 January 2017

Revised 23 March 2017

Accepted 10 April 2017

Published Online First

13 May 2017

ABSTRACT

Introduction The cerebellum has strong cortical and subcortical connectivity, but is rarely taken into account for clinical diagnosis in many neurodegenerative conditions, particularly in the absence of clinical ataxia. The current meta-analysis aims to assess patterns of cerebellar grey matter atrophy in seven neurodegenerative conditions (Alzheimer's disease (AD), Parkinson's disease (PD) and Huntington's disease (HD), frontotemporal dementia (FTD), amyotrophic lateral sclerosis (ALS), multiple system atrophy (MSA), progressive supranuclear palsy (MSP)).

Methods We carried out a systematic search in PubMed (any date: 14 July 2016) and a hand search of references from pertinent articles according to the Preferred Reporting Items for Systematic Reviews and Meta-Analyses (PRISMA) guidelines. The authors were contacted to provide missing coordinate data. Peer-reviewed studies with direct comparison of patient and control groups, and availability of coordinate data of grey matter cerebellar atrophy in patients were included. These coordinates were used in an anatomical likelihood estimation meta-analysis.

Results Across 54 studies, clusters of cerebellar atrophy were found for AD, ALS, FTD, MSA, and PSP. Atrophy patterns were largely disease-specific, with overlap in certain areas of the cerebellar hemisphere, which showed marked atrophy in AD, ALS, FTD and PSP (Crus I/II), and MSA and PSP (lobules I–IV), respectively. Atrophy colocalized with cerebellar areas implicated for motor (PSP, MSA) or cognitive symptoms (FTD, ALS, PSP) in the diseases.

Discussion Our findings suggest that cerebellar changes are largely disease-specific and correspond to cortical or subcortical changes in neurodegenerative conditions. High clinical variability in PD and HD samples may explain the absence of findings for consistent grey matter loss across studies. Our results have clinical implications for diagnosis and cerebellar neuroimaging referencing approaches.

INTRODUCTION

The cerebellum has long been regarded as critical for intact motor functioning.¹ However, an accumulating body of evidence demonstrates that it also plays a significant role in cognitive and affective processing. This plethora of studies has revealed that motor functions are mostly localised in anterior regions, whereas cognitive processes are supported by posterior cerebellum. Furthermore, limbic and affective processes are most strongly associated with

vermis and paravermis.^{2–5} It has been proposed that the cerebellum contributes to cognition and motor functioning through the formation of internal models that support coordination of behaviour and skill learning. As a new model is formed, it may shape cortical representations such that once the internal model of behaviour is acquired, it can be stored in the cortex and accessed flexibly.⁶

Such processes require substantial interactions between the cerebellum and (sub)cortical regions. Indeed, the cerebellum has multiple reciprocal modular anatomical loops with the motor and sensory cortices and with areas serving higher cognitive functions including prefrontal and parietal cortices.^{7–9} Thus, the cerebellum exhibits specificity in the topography of its connectivity and consequently in its function across motor, cognitive, autonomic and affective domains. Damage to this brain structure could therefore result in a variety of impairments depending on the location.

Recent findings demonstrate that cerebellar-cortical connectivity has implications for neurodegenerative diseases,^{10–11} which can often show a mixture of motor, cognitive and even neuropsychiatric symptoms. While the cerebellum has previously received little attention in the study of neurodegenerative diseases without ataxia, these findings show that this may be unjustified. Network-specific neurodegeneration with distinct patterns of regional cerebellar grey matter (GM) loss can be identified for Alzheimer's disease (AD), amyotrophic lateral sclerosis (ALS), frontotemporal dementia (FTD) and Parkinson's disease (PD). Furthermore, these distinct patterns of cerebellar GM atrophy have been associated with dysfunction across several cognitive and affective domains.^{10–12} Finally, the cerebellum is also gradually being identified as potential player in manifest Huntington's disease (HD).^{13–15}

The aforementioned findings demonstrate the increasing interest to elucidate the pattern of cerebellar atrophy across diseases and its role in pathophysiology. However, to date it is still not clear how cerebellar changes overlap or differ between neurodegenerative syndromes. The current study sets out to rectify this by conducting a systematic literature search and a voxel-based meta-analysis of neuroimaging data across seven major neurodegenerative diseases. We chose to include diseases for which the literature has traditionally paid little attention to the cerebellum, but which warrant further investigation based on shared connectivity between the



CrossMark

To cite: Gellersen HM, Guo CC, O'Callaghan C, et al. *J Neurol Neurosurg Psychiatry* 2017;**88**:780–788.

cerebellum and affected brain regions. This is the case for AD, ALS, FTD, HD and PD. Furthermore, we were interested in comparing cerebellar atrophy patterns of these diseases with that of conditions for which cerebellar involvement has been established and that exhibit similar clinical characteristics. Therefore, we also included multiple system atrophy (MSA) and progressive supranuclear palsy (PSP) in the meta-analysis.

The results will clarify whether the cerebellum is involved across the whole neurodegenerative disease spectrum and how specific or generic the identified cerebellar atrophy is across conditions. We hypothesise that cerebellar atrophy in these diseases is specific and relates to motor and cognitive symptoms exhibited by patients.

METHODS

Systematic literature search

A systematic literature search was carried out according to the Preferred Reporting Items for Systematic Reviews and Meta-Analyses (PRISMA) guidelines from any date until 14 July 2016 on PubMed. Specific search terms were used for each disease in addition to the common terms 'voxel-based morphometry' and 'structural MRI' (see online supplementary material 1, [table 1](#)).

A hand search of references of relevant articles was additionally carried out. In case data were not available in articles or supplementary material, the authors were contacted to provide the missing information. The study inclusion criteria were as follows:

- ▶ publication in peer-reviewed journals and written in English;
- ▶ inclusion of $n \geq 3$ patients;
- ▶ comparison of a patient group of interest (AD, ALS, FTD, HD, MSA, PD or PSP) with a healthy age-matched control group;
- ▶ assessment of differences between patients and controls using voxel-based morphometry and a direct comparison between groups;
- ▶ availability of coordinate data of group-level grey matter cerebellar atrophy in patients compared with controls, either in the article proper, the supplementary material or on request for missing data from the authors.

These criteria were chosen in order to minimise heterogeneity between studies.

Uncertainty regarding inclusion was resolved between HMG, SS and MH. After exclusion of duplicates, the search yielded 924

Table 1 Results of the ALE meta-analysis

Disease group	Cluster size (mm ³)	Extent and centre (MNI)	Local extrema (MNI)	p Value	Label
AD					
Cluster 1	1016	(26 -78 -40) to (42 -58 -24) centred at (31 -66 -33)	30 -68 -38	0.014	R posterior lobe, tonsil
			34 -60 -26	0.011	R anterior lobe, culmen
			28 -70 -28	0.009	R posterior lobe, uvula
			28 -76 -26	0.009	R posterior lobe, uvula
ALS					
Cluster 1	648	(-34 -80 -52) to (-26 -72 -44) centred at (-30 -76 -48)	-30 -76 -48	0.009	L posterior lobe, inferior semi-lunar lobule
Cluster 2	496	(12 -66 -62) to (20 -58 -54) centred at (16 -62 -58)	16 -62 -58	0.009	No GM found
Cluster 3	456	(6 -60 -18) to (14 -52 -10) centred at (10 -56 -14)	10 -56 -14	0.008	R anterior lobe, culmen
Cluster 4	448	(-8 -72 -30) to (-2 -66 -24) centred at (-5 -69 -27)	-4 -68 -26	0.008	L anterior lobe, nodule
FTD					
Cluster 1	1 736	(-56 -78 -48) to (-30 -56 -34) centred at (-43 -70 -40)	-46 -72 -40	0.011	L posterior lobe, inferior semi-lunar lobule
			-34 -66 -40	0.010	L posterior lobe, tonsil
			-54 -76 -36	0.010	L posterior lobe, pyramis
			-38 -68 -42	0.010	L posterior lobe, tonsil
			-52 -74 -48	0.008	L posterior lobe, inferior semi-lunar lobule
			-38 -60 -42	0.008	L posterior lobe, tonsil
Cluster 2	728	(38 -68 -50) to (50 -56 -40) centred at (42 -61 -45)	42 -60 -44	0.013	R posterior lobe, tonsil
			48 -66 -48	0.008	R posterior lobe, tonsil
Cluster 3	640	(46 -72 -36) to (54 -64 -20) centred at (50 -68 -27)	52 -68 -28	0.011	R posterior lobe, tuber
			50 -68 -24	0.010	R posterior lobe, declive
HD					
		No clusters found			
MSA					
Cluster 1	1080	(0 -46 -26) to (20 -34 -14) centred at (8 -38 -19)	6 -36 -20	0.011	R anterior lobe, culmen
			16 -40 -16	0.010	R anterior lobe, culmen
Cluster 2	560	(-10 -48 -28) to (-2 -40 -18) centred at (-7 -44 -23)	-6 -44 -24	0.013	L anterior lobe, culmen
PD					
		No clusters found			
PSP					
Cluster 1	976	(-12 -42 -22) to (2 -32 -10) centred at (-6 -38 -16)	-6 -38 -16	0.014	L anterior lobe, culmen
Cluster 2	912	(-48 -58 -50) to (-42 -42 -42) centred at (-45 -49 -46)	-46 -46 -46	0.011	L posterior lobe, tonsil
			-46 -54 -46	0.010	L posterior lobe, tonsil
Cluster 3	584	(4 -54 -46) to (12 -46 -32) centred at (8 -50 -38)	6 -48 -36	0.009	R anterior lobe
			10 -52 -44	0.008	R posterior lobe, tonsil

AD, Alzheimer's disease; ALS, amyotrophic lateral sclerosis; FTD, frontotemporal dementia; GM, grey matter; HD, Huntington's disease; L, left; MNI, Montreal Neurological Institute; MSA, multisystem atrophy; PD, Parkinson's disease; PSP, progressive supranuclear palsy; R, right.

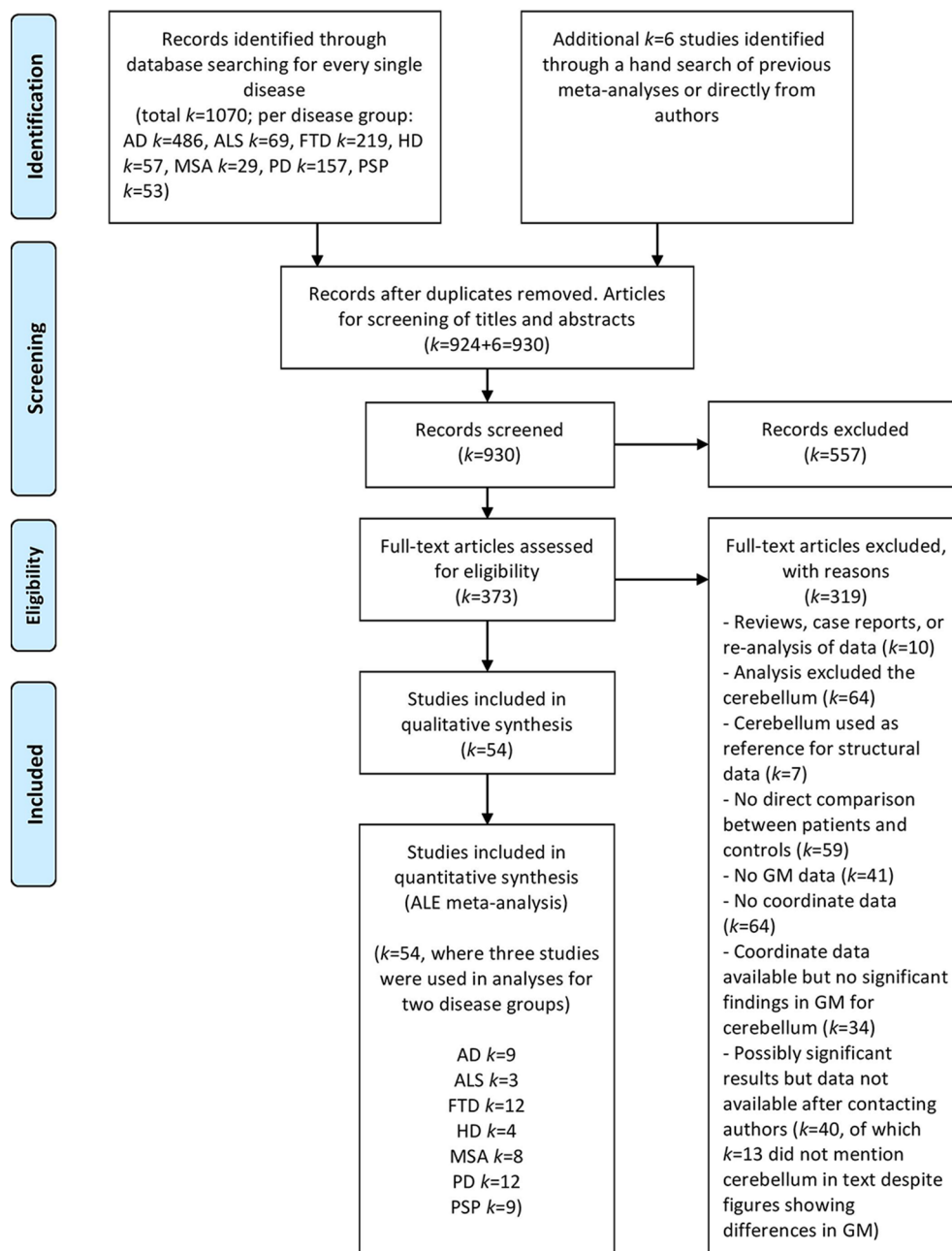


Figure 1 PRISMA flow chart of study selection and reasons for exclusion. AD, Alzheimer's disease; ALS, amyotrophic lateral sclerosis; FTD, frontotemporal dementia; GM, grey matter; HD, Huntington's disease; MND, motor neuron disease; MSA, multisystem atrophy; PD, Parkinson's disease; PSP, progressive supranuclear palsy.

studies on PubMed. Additional 6 studies were identified in the hand search, leaving a total of 930 studies for screening of titles and abstracts. After exclusion of irrelevant studies, 373 remained for full-text assessment. Fifty-four studies met the inclusion criteria, three of which reported results for two diseases each. When it became apparent that different studies used the same participant data, the study with the larger sample size was selected. The procedure for study selection and reasons for exclusion are summarised in the PRISMA flow chart in [figure 1](#) (see online supplementary material 2 for the PRISMA checklist).

We did not include patients with ALS-FTD because we felt this would require an additional analysis separate from that of either ALS or FTD, for which there was insufficient data. Incidentally, all studies that identified cerebellar GM atrophy in FTD

included patients with a diagnosis of behavioural variant FTD (bvFTD). Therefore, in the following the term FTD refers to the behavioural subtype of the disease. Finally, for the MSA sample we carried out the analysis across studies that included the cerebellar (MSA-C) or the parkinsonian (MSA-P) subtype because several studies investigated these in unison and thus not enough data were available for separate analyses with sufficient power.

The primary outcome measures used in the meta-analysis were coordinates of peak GM atrophy in patients compared with controls. For longitudinal studies, only coordinates comparing the most recent brain scans of patients and controls were used for the analysis. Extracted data were assessed for correctness by multiple authors before data analysis. In case the authors did not report whether coordinates corresponded to grey or white

matter, the Talairach Client (www.talairach.org) was used to identify the label of the brain region and type of tissue.¹⁶ For the main analysis, all foci in Talairach space were converted to Montreal Neurological Institute space using a tool from the GingerALE meta-analysis software (brainmap.org) that employs the *icbm2tal* transform.^{17–19}

In addition to anatomical data, demographic and clinical data were also extracted to give an indication of comparability between studies and between patients and controls included in each comparison (supplementary material 1, table 2). Finally, in case the included studies reported results from analyses relating symptomatology or cognitive and motor function to patient-control differences in GM volume, the outcomes were included in a qualitative synthesis (supplementary material 1, table).

Anatomical likelihood estimation meta-analysis

We employed anatomical/activation likelihood estimation (ALE) using the latest GingerALE software V2.3.6 (brainmap.org).^{20,21} This version corrects an error in multiple comparisons correction methods that had resulted in lenient thresholding in previous versions.²²

The GingerALE software requires coordinate and sample size data, the latter of which is used to assign a relative weight to every study as it is assumed that studies with larger sample sizes have greater precision. The ALE meta-analysis treats every coordinate ('focus') as a spatial probability distribution centred around the given coordinate. For every experiment, foci are modelled as Gaussian probability distributions using a full-width half-maximum that takes into account the sample size of the experiment. A modelled activation (MA) map for a given experiment is created from the probability distributions of all its foci. The ALE image is formed from the union of MA maps for all experiments. The null distribution is determined using the analytical method, where all voxels with the same MA values are tallied in one histogram bin until the entire MA map is summarised in this manner.^{20,21}

The current ALE algorithm takes into account both intersubject and interexperiment variability for the computation of probability distributions by employing a random-effects model. As some studies may report more foci than others, ALE controls for the possible within-experiment effect of multiple foci from one experiment influencing the modelled activation of a single voxel.

As recommended by the ALE manual, cluster-level inference was used as thresholding method for maximal statistical rigour. For the cluster-forming threshold, an uncorrected *p* value of 0.001 was chosen, whereas the *p* value for cluster-level inference was 0.05.^{20,21,23} For visualisation, results were projected on cerebellar surface-based flatmaps provided by the SUIT toolbox.²⁴

It should be noted that the ALE method does not provide a metric for study heterogeneity and cannot inform the reader about possible publication bias due to the fact that only studies with positive findings can be included in the analysis. Nonetheless, it is the most widely accepted method for coordinate-based meta-analysis.

RESULTS

A total number of *n*=1609 patients (AD *n*=369; ALS *n*=60; FTD *n*=233; HD *n*=104; MSA *n*=160; PD *n*=528; PSP *n*=155) and *n*=1471 controls (not counting twice the control subjects that were included in analyses for two disease groups) from *k*=54 studies (AD *k*=9; ALS *k*=3; FTD *k*=12; HD *k*=4; MSA *k*=8; PD *k*=12; PSP *k*=9; three of these conducted analyses on two diseases each, resulting in a total of 57 comparisons between a disease and a control group) were included in this meta-analysis. Study characteristics including age, disease duration and symptom severity can be found in online (supplementary material 1, table 2). In the vast majority of studies, patients and controls did not differ in age.

Table 1 and figure 2 show the results of the ALE meta-analysis for all diseases that revealed significant GM loss. In AD, one cluster of cerebellar GM atrophy was found in the right hemisphere spanning Crus I and II, as well as lobule VI.

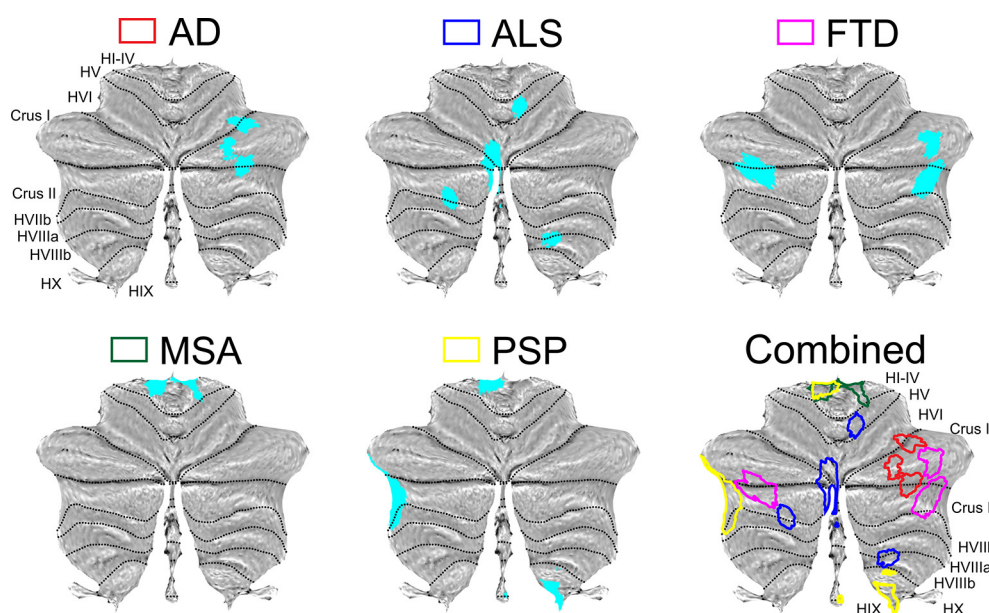


Figure 2 Structural atrophy in the cerebellum in AD, ALS, FTD, MSA, PSP and the overlay across these diseases. Atrophy map of each disease is colour coded in the overlay, corresponding to the coloured box on top of the individual atrophy map. Atrophy is displayed on surface-based flatmaps provided by the SUIT toolbox.²⁴ AD, Alzheimer's disease; ALS, amyotrophic lateral sclerosis; FTD, frontotemporal dementia; GM, grey matter; MSA, multisystem atrophy; PSP, progressive supranuclear palsy.

In patients with ALS, the largest cluster of GM reduction spanned parts of the vermis and neighbouring regions in left lobule VI, Crus I and Crus II. Another cluster in the left hemisphere stretched from Crus II to lobule VIIb. In the right hemisphere, one cluster was situated in lobule V close to the vermis and the other affected region included lobules VIIIa/b.

The analysis of FTD-related atrophy revealed three clusters of GM loss. Two were located in the right hemisphere, in Crus I and Crus II, respectively, with a small portion of right lobule VIIb being affected as well. The third cluster spanned parts of left Crus I and II.

The results for MSA show that regions of GM atrophy were constrained to posterior cerebellum. Two clusters that mirrored each other were found in left and right hemispheres in the medial regions of lobules I–IV.

In PSP, three clusters were found. One was located in left lobules I–IV, partially covering the vermis. The second cluster showed atrophy in a small part of the lateral most left Crus I, extending towards lateral regions of Crus II and lobule VIIb. The final cluster was constrained to the inferior most part of right lobule IX.

The analysis for HD and PD did not find any clusters that exceeded the significance thresholds of 576 and 488 mm³ per cluster, respectively, that were chosen in the permutation procedure.

As evident in figure 2, there were distinct atrophy patterns across groups as well as several clusters that were shared between diseases. Interestingly, one cluster in left lobules I–IV was virtually identical in both MSA and PSP. Marked lobular overlap was found in Crus I and II, which were most affected across diseases. The analyses for AD, ALS, FTD and PSP all showed atrophy in these regions in both hemispheres, although at different locations.

Table 3 in online supplementary material 1 lists the results of all studies that have included the cerebellum in an analysis that aimed to relate regional GM loss to behavioural measures or clinical outcome. None of these studies found relationships between Mini-Mental State Examination (MMSE) scores and other cognitive or clinical measures in AD.^{25–27} In contrast, in a mixed analysis of patients with ALS and FTD, correlations between cerebellar GM and scores on the Addenbrooke's Cognitive Examination Revised and Cambridge Behavioural Inventory Revised were found across all lobules apart from lobule X.¹¹ The same study also found associations between ALS Functional Rating Score Revised and GM volume of right lobule V, VIIIa/b and IX, bilateral lobule VI and VIIb and left lobule VII in patients with ALS and ALS-bvFTD. Further studies found that declines in memory performance and confrontation naming correlated with reduced cerebellar GM volume in patients with FTD.^{28 29}

Despite the absence of significant GM atrophy clusters in HD identified here, cerebellar volume in patients correlated with changes in affective functions, symptom duration, and visuo-motor performance.^{15 30 31}

In patients with MSA, one study reported that cerebellar volume loss in regions that we identified as bilateral lobules IV–VI correlated with disease duration and that atrophy in lobules I–IV, V and IX was associated with disease stage.³² Furthermore, cerebellar ataxia was correlated with volume decrease across widespread regions.³³

For PD, greater cerebellar atrophy was associated with decreased baroreflex sensitivity,³⁴ higher motor score on the Unified Parkinson's Disease Rating Scale (UPDRS-III), decreased connectivity between cerebellar motor regions and the default

mode, sensorimotor and dorsal attention networks,¹² and a decline in executive functions.³⁵

Finally, greater cerebellar atrophy in patients with PSP correlated with lower Frontal Assessment Battery scores, greater postural instability (lobules I–IV) and disease duration (lobules I–IV, VIIIb),³⁶ decreased phonological verbal and letter fluency (left lobule VI, right I–IV)^{36 37} and impaired emotion recognition and theory of mind (right Crus II).³⁸

DISCUSSION

To our knowledge, this is the first study to systematically review and quantitatively perform a meta-analysis of GM atrophy in the cerebellum across neurodegenerative disorders. Using the ALE method, consistent clusters of cerebellar atrophy were identified in AD, ALS, FTD, MSA and PSP, but not in HD and PD. The analysis revealed that the diseases have unique patterns of cerebellar atrophy, suggesting that cerebellar changes are not homogenous across neurodegenerative conditions, but specific to underlying pathology. Some lobular overlap was found in AD, ALS, FTD and PSP (Crus I/II), as well as between MSA and PSP (left lobules I–IV), although only the latter showed an identical cluster. To simplify the interpretation of the results and their implications for changes in functioning across these diseases, we provide a diagram of functions and connectivity of the different subregions of the cerebellum (figure 3).

Alzheimer's disease

Atrophy in AD was found in a large cluster in right Crus I/II, with involvement of lobule VI. This atrophy in AD contradicts previous assertions that the cerebellum remains unaffected in the disease.³⁹ More importantly, these regions have been implemented in cognitive and affective functions. Specifically, Crus I/II and lobule VI participate in the executive control network (ECN), the default mode network (DMN) and the salience network (SN).⁴⁰ This atrophy pattern dovetails with the predominant cognitive impairment characteristic of AD including episodic and working memory decline,⁴¹ and the connections Crus I/II and lobule VI share with the hippocampus and prefrontal regions.⁴² This raises the question as to whether cerebellar atrophy contributes to typical cognitive deficits observed in AD.⁴³ None of the studies included in our meta-analysis found correlations between cognitive decline and degree of cerebellar atrophy. In contrast, other authors have reported a correlation between MMSE scores and abstract reasoning abilities with grey matter volumes in the right cerebellar hemisphere, which fits with our account of right-lateralised GM loss.^{44 45}

Therefore, associations between cognitive impairment and cerebellar GM loss in AD remain inconsistent, and it is unclear as to whether such associations are causally linked to cerebellar degeneration or if they are due to atrophy in other brain regions typically affected in AD, which then impact the cerebellum. Regions of atrophy in the cerebellum are intrinsically connected with atrophied areas in cerebral cortex in AD and FTD, suggesting that atrophy spreads through brain networks.¹⁰ Clearly, the relationship between cerebellar atrophy and AD symptomatology warrants further study in the future.

Frontotemporal dementia and amyotrophic lateral sclerosis

Results of FTD and ALS are discussed jointly as both diseases are considered to lie on a spectrum.¹¹ Our analysis revealed multiple clusters of atrophy in FTD in bilateral Crus I/II. In ALS, Crus I/II are affected to a smaller degree and the cluster is situated in the

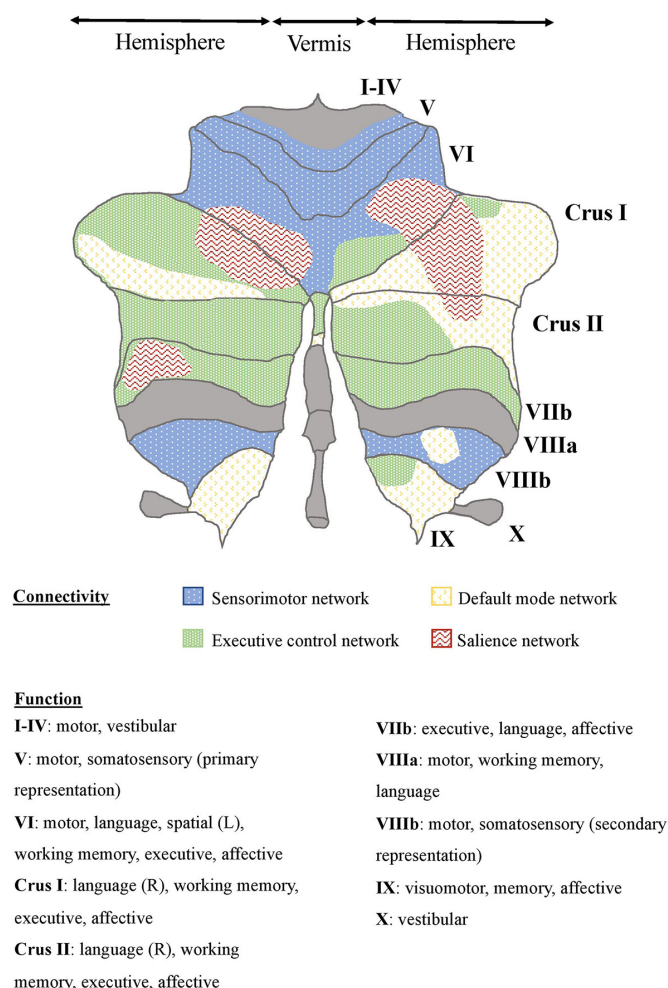


Figure 3 Diagram of functions and connectivity of the human cerebellum. This diagram is a simplified approximation of cerebellar connectivity and function. The map shows a synthesis of the results of several connectivity analyses.^{7,8,40} Please note that this diagram is meant to provide a general overview and is therefore limited to four major networks. A detailed account of cerebellar topography that exceeds the scope of one figure can be found in Buckner *et al.*⁷ Cortical and subcortical regions included in each network are as follows: *Sensorimotor network*: sensorimotor cortex (M1/S1), premotor cortex, supplementary motor area, anterior cingulate cortex, occipital cortex, insula, lentiform and caudate nucleus, ventral thalamus, rostral left red nucleus. *Default mode network*: dorsomedial prefrontal cortex, medial prefrontal cortex, superior parietal cortex, angular gyrus, posterior cingulate, retrosplenial cortex, medial temporal lobe, ventral temporal cortex. *Executive network*: dorsolateral and dorsomedial prefrontal cortex, orbitofrontal cortex, caudal cingulate cortex, superior parietal cortex, angular and supramarginal gyri, left caudate nucleus. *Salience network*: medial frontal cortex, dorsolateral prefrontal cortex, frontoinsula, thalamus, red nuclei.⁴⁰ Functions are listed based on two meta-analyses,²⁴ one functional imaging study⁵ and the other studies listed above.^{7,8,40} L, left; R, right.

vermal/paravermal region rather than the hemisphere. Atrophy clusters in ALS were also found in inferior cerebellum, additionally affecting hemispheric lobules V, VI and VIII, reflecting greater motor impairment in ALS.

In contrast to AD, cerebellar changes in ALS and FTD are now commonly accepted, having first been identified in C9orf72 mutation carriers⁴⁶ and more recently, in patients with sporadic disease.¹¹ Importantly, throughout the cerebellum atrophy has

been found to correlate with cognitive, motor and neuropsychiatric symptomatology in FTD and ALS (see online supplementary material 1, table 3).¹¹ In particular, Crus I and lobule VI were associated with deficits in memory, language, executive, emotion and visuospatial domains in bvFTD.⁴⁷ Neuropsychiatric deficits were most strongly associated with the Crus in patients with FTD.¹¹

Moreover, connectivity of the cerebellar subregions with GM loss in FTD also dovetails with characteristic symptoms. Regions of Crus I/II identified here share major connections with prefrontal and parietal areas as part of the DMN and ECN,⁴⁰ resulting in coactivation during executive functioning, memory and emotion processing.⁴⁸ This may explain the relationship between cerebellar atrophy and specific cortical changes in FTD.¹⁰ The atrophied regions in Crus I may also be involved in the SN, which has been recognised to be affected by degeneration in FTD.¹⁰

One explanation besides frontal atrophy for the lack of inhibition, depressed mood, and inappropriate behaviour in FTD may therefore be abnormal functioning of the cerebellum caused by GM loss. Comparable symptoms have been shown in a variety of patients with damage in similar regions of the cerebellum and have been explained on the basis of the dysmetria of thought hypothesis.⁴⁹ This hypothesis postulates that cerebellar damage results in similar patterns of impairment across all domains the cerebellum is involved in. that is, damage to motor regions causes dysmetria of movement, just as damage to cognitive/affective regions results in a dysmetria of thought, meaning that in both cases maintenance of appropriate behaviour is defective.⁶

While ALS also exhibited atrophy in cerebellar regions of the ECN (left Crus I/II), most clusters belonged to areas of the sensorimotor network (lobules, V, VI, VIIIb) as would be expected from a disease primarily characterised by motor impairments. Taken together, there is substantial support for the notion that cerebellar atrophy is highly specific and related to cortical symptomatology in FTD and ALS. Despite these exciting findings, future studies in the ALS-FTD continuum are clearly needed to explore how repeat expansions of the C9orf72 gene and sporadic forms impact on cerebellar integrity and associated symptomatology.

Huntington's disease

We did not find any clusters that survived corrections for multiple comparisons in HD. However, studies have shown decreased corticocerebellar functional coupling in HD and revealed associations of cerebellar atrophy with impaired gait and motor score, deficits in emotion recognition and working memory.^{13,31,50} Cerebellar changes thus seem to be related to clinical symptomatology of HD. Given that the basal ganglia, one of the major affected regions in HD, shows strong connectivity with the cerebellum this may not be surprising.⁵¹ Nonetheless, few studies have investigated the involvement of the cerebellum in HD. A recent review on HD has summarised cerebellar findings in the disease, which include reduced total cerebellar volume, atrophy in both anterior and posterior lobes and neuronal cell loss in cerebellar cortex and deep nuclei.¹⁴ These anatomical changes explain several motor-related HD symptoms including but not limited to ataxia, dysarthria and impaired gait balance. Given the clear evidence of cerebellar involvement in HD, the small sample size in our analysis likely contributed to the failure to identify consistent regions of atrophy. Likewise, large clinical variability inherent in patients with HD with respect to symptom phenotype and cortical

neuronal degeneration may also impact the consistency of cerebellar atrophy.⁵² Such heterogeneity cannot be dealt with in a sample as small as the one in this study. Future studies should further investigate the role of the cerebellum in HD.

Parkinson's disease

Our meta-analysis surprisingly revealed no cerebellar involvement in patients with PD. Despite the cerebellum being involved in tremor,⁵³ no motor areas of the cerebellum emerged in our analysis. This surprising finding could be due to diverse clinical presentations of patients in the different studies, as the level of cognitive impairment in PD seems to play a large role in the presence of cerebellar atrophy.¹² Indeed, when extracting the data from the PD studies, it became apparent that especially those patients with concurrent cognitive impairment (eg, patients with PD-mild cognitive impairment) exhibit cerebellar atrophy. One could speculate, therefore, that the cerebellar changes in PD are more related to cognitive deficits than motor symptoms, per se. Clearly, such a controversial notion needs to be investigated further in the future. Along these lines, a recent study found that GM differences in Crus I—a region that is involved in cognitive rather than motor functions—could differentiate PD from controls with 95% accuracy.⁵⁴ Another recent study lends further support for the importance of PD-related changes in Crus I, revealing reduced negative functional coupling between the right Crus I and the subthalamic nucleus in the resting state.⁵⁵

Multiple system atrophy and progressive supranuclear palsy

In MSA and PSP, previous studies have shown that cerebellar atrophy is most common in the white matter of the cerebellar peduncles.^{56 57} Here we find consistent clusters of GM atrophy in MSA lobules I–IV. Studies have shown that this atrophy correlates with gait and balance impairments and longer disease duration.^{32 33} Indeed, these regions are confined to the anterior lobe of the cerebellum, which is involved in sensorimotor processing and shares connections with the spinal cord, brainstem and cortical areas responsible for sensorimotor functions and postural stability.^{4 58}

We did not identify any regions implicated in cognitive functions that were affected in the cerebellum in MSA and none of the studies showed correlations between cerebellar atrophy and cognitive symptoms, suggesting that cerebellar involvement in MSA may be limited to the motor domain. However, the absence of clusters in posterior regions could be a consequence of the small sample size of our meta-analysis.

Inspection of the ALE summary data revealed that two out of the three MSA studies that included only patients with MSA-P did not contribute to the clusters of GM atrophy identified here. This suggests that our findings could have been driven by patients with MSA-C in the mixed patient studies and that the pattern of cerebellar atrophy in patients with MSA-P differed too much from that in MSA-C to contribute to the clusters in this analysis.

For PSP one cluster was identified in left lobules I–IV at the same location as in MSA. Studies have found atrophy in these regions to be related to postural instability and phonological changes in PSP.³⁶ A second cluster is located in right lobule IX. Atrophy in lobule IX has been found to be related to oculomotor deficits in patients with lesion.⁵⁹ Indeed, ocular motor impairment is a prominent and early feature of PSP in patients with Richardson syndrome (the most common subtype of PSP), who exhibit slowed vertical saccades.⁶⁰ It is also in line with the prominent decrease in white matter volume of the superior

cerebellar peduncle in PSP, which connects the cerebellum with the thalamus, which then in turn projects to the frontal eye field.⁶¹ However, lobule IX has also been linked to the DMN and affective and memory functions and may therefore also play a role in mood changes in PSP.⁴⁰

Finally, the third cluster in PSP covered a region of left Crus I/II and lobule VIIb that has been implicated in the ECN, which fits with executive dysfunction being the most common cognitive symptom in the disease.⁶² Based on these findings, the cerebellum may be involved in motor symptoms of PSP and in cognitive-affective changes. However, few studies have found correlations between cerebellar GM and clinical scales in PSP. Therefore, this notion needs to be more thoroughly investigated in the future.

While only motor functions correlated with cerebellar GM volume in patients with MSA, both cognitive and motor deficits in patients with PSP were associated with atrophy across studies. This is in line with the patterns of cerebellar atrophy we find in these diseases, as only posterior regions were affected in MSA, whereas posterior and anterior regions of the cerebellum were involved in PSP.

Summary and limitations

Our results demonstrate distinct patterns of cerebellar GM loss across most of the neurodegenerative diseases investigated here. In addition, our combined plot showed that there exists some overlap in atrophy patterns. These findings suggest that cerebellar changes are highly disease-specific and correspond to the cortical or subcortical changes characteristically reported in each disease.¹⁰ Lobular overlap between ALS and FTD in Crus I/II further corroborates this notion as both diseases lie on a spectrum. Similarly, the shared cluster between MSA and PSP can be explained on the basis of the clinical motor characteristics found in both diseases like impairments in posture and balance.

Despite these novel and exciting findings, there are limitations to our study: i) the employed meta-analytical tool (ALE) does not weight clusters based on effect or cluster sizes and does not consider null findings; nonetheless, ALE is the most validated and accepted method of coordinate-based meta-analysis; ii) inspection of excluded studies revealed that cerebellar atrophy was often present in the figures of the studies but the peak coordinates and cluster sizes were not reported. Despite repeated contacts with the authors, we could not obtain the data for some studies and thus, our results very likely underestimate the cerebellar atrophy; iii) our results might have been affected by the inclusion of different disease stages across conditions; iv) most importantly, our meta-analysis is limited by the small sample sizes for each disease group, especially in ALS and HD, which was due to the absence of direct patient-control comparisons of structural brain changes in many identified studies which had to be excluded. Future studies are therefore needed to validate our findings, in particular once studies report cerebellar changes more consistently.

The current meta-analysis benefits from specificity resulting from the strict selection criteria we used by only including direct comparisons of patients and controls, rather than considering correlation analyses that may include additional variables. Furthermore, through personal contact with the authors we obtained additional coordinate data that had not been included in previous whole-brain meta-analyses of the diseases investigated here.

In summary, consistent patterns of cerebellar atrophy can be found for AD, ALS, FTD, MSA and PSP with atrophy being

highly disease-specific and relating to cognitive, sensorimotor and affective symptoms in the respective disorder. Particularly for ALS and FTD, cerebellar atrophy is related to clinical rating scales and specific atrophy patterns can be identified for different phenotypes along the disease spectrum.¹¹ In contrast, for AD the relationship between clinical assessment and cerebellar GM is inconsistent. Finally, motor symptoms in MSA, particularly MSA-C, have been linked to cerebellar changes, whereas the role of the cerebellum in symptom generation of PSP is less clear. Furthermore, the patterns of cerebellar GM decline may at least in part be explained on the basis of connectivity with cortical and subcortical regions that are the main affected regions in the diseases. However, it is currently still unclear whether cerebellar atrophy in these diseases is a result of Wallerian degeneration due to cortical or subcortical changes, or whether it has a separate origin and contribution in the neurodegenerative processes. Regardless, this increasing evidence of cerebellar atrophy has implications for neuroimaging referencing and diagnosis. Most studies use the cerebellum as a reference region for cortical investigations. Thus, cerebellar atrophy may need to be taken into account, for example, when considering positron emission tomography uptake loads in such analyses. We hope these findings will pave the way for future investigations into the cerebellum and its role in neurodegeneration.

Acknowledgements The authors acknowledge support from the National Health and Medical Research Council Neil Hamilton Fairley Fellowship (GNT1091310), Alzheimer's Research UK, the Wellcome Trust, the National Health and Medical Research Council (NHMRC) - Australian Research Council (ARC) Dementia Research Development Fellowship (APP1110369), and the James S. McDonnell Foundation.

Contributor HMG, SS, MH: contributed to systematic literature search, statistical analysis and writing and revising of the manuscript. CCG: contributed to writing and revising of the manuscript; created cerebellar flatmaps. CO, RT: contributed to writing and revising of the manuscript.

Funding CO is supported by a National Health and Medical Research Council Neil Hamilton Fairley Fellowship (GNT1091310). MH is funded by Alzheimer's Research UK and Wellcome Trust. RT is supported by a National Health and Medical Research Council—Australian Research Council Dementia Research Development Fellowship (APP1110369). SS would like to acknowledge funding from the James S. McDonnell Foundation.

Competing interests The authors declare that the research was conducted in the absence of any commercial or financial relationships that could be construed as a potential conflict of interest.

Provenance and peer review Not commissioned; externally peer reviewed.

Data sharing statement All data used in this meta-analysis are available either in the main article or in the supplementary materials. All authors have full access to the raw data files used in this meta-analysis.

© Article author(s) (or their employer(s) unless otherwise stated in the text of the article) 2017. All rights reserved. No commercial use is permitted unless otherwise expressly granted.

REFERENCES

- Strick PL, Dum RP, Fiez JA. Cerebellum and nonmotor function. *Annu Rev Neurosci* 2009;32:413–34.
- E KH, Chen SH, Ho MH, et al. A meta-analysis of cerebellar contributions to higher cognition from PET and fMRI studies. *Hum Brain Mapp* 2014;35:593–615.
- Koppelmans V, Hoogendam YY, Hirsiger S, et al. Regional cerebellar volumetric correlates of manual motor and cognitive function. *Brain Struct Funct* 2016;24.
- Stoodley CJ, Schmahmann JD. Functional topography in the human cerebellum: a meta-analysis of neuroimaging studies. *Neuroimage* 2009;44:489–501.
- Stoodley CJ, Valera EM, Schmahmann JD. Functional topography of the cerebellum for motor and cognitive tasks: an fMRI study. *Neuroimage* 2012;59:1560–70.
- Kozioł LF, Budding D, Andreasen N, et al. Consensus paper: the cerebellum's role in movement and cognition. *Cerebellum* 2014;13:151–77.
- Buckner RL, Krienen FM, Castellanos A, et al. The organization of the human cerebellum estimated by intrinsic functional connectivity. *J Neurophysiol* 2011;106:2322–45.
- Krienen FM, Buckner RL. Segregated fronto-cerebellar circuits revealed by intrinsic functional connectivity. *Cereb Cortex* 2009;19:2485–97.
- Schmahmann JD, Pandya DN. The cerebrocerebellar system. *Int Rev Neurobiol* 1997;41:31–60.
- Guo CC, Tan R, Hodges JR, et al. Network-selective vulnerability of the human cerebellum to Alzheimer's disease and frontotemporal dementia. *Brain* 2016;139:1527–38.
- Tan RH, Devenney E, Dobson-Stone C, et al. Cerebellar integrity in the amyotrophic lateral sclerosis-frontotemporal dementia continuum. *PLoS One* 2014;9:e105632–10.
- O'Callaghan C, Hornberger M, Balsters JH, et al. Cerebellar atrophy in Parkinson's disease and its implication for network connectivity. *Brain* 2016;139:845–55.
- Rees EM, Farmer R, Cole JH, et al. Cerebellar abnormalities in Huntington's disease: a role in motor and psychiatric impairment? *Mov Disord* 2014;29:1648–54.
- Rüb U, Hoche F, Brunt ER, et al. Degeneration of the cerebellum in Huntington's disease (HD): possible relevance for the clinical picture and potential gateway to pathological mechanisms of the disease process. *Brain Pathol* 2013;23:165–77.
- Wolf RC, Thomann PA, Sambataro F, et al. Abnormal cerebellar volume and corticocerebellar dysfunction in early manifest Huntington's disease. *J Neurol* 2015;262:859–69.
- Lancaster JL, Woldorff MG, Parsons LM, et al. Automated Talairach atlas labels for functional brain mapping. *Hum Brain Mapp* 2000;10:120–31.
- Collins DL, Neelin P, Peters TM, et al. Automatic 3D intersubject registration of MR volumetric data in standardized Talairach space. *J Comput Assist Tomogr* 1994;18:192–205.
- Laird AR, Robinson JL, McMillan KM, et al. Comparison of the disparity between Talairach and MNI coordinates in functional neuroimaging data: validation of the Lancaster transform. *Neuroimage* 2010;51:677–83.
- Talairach J, Tournoux P. *Co-planar stereotaxic atlas of the human brain. 3-dimensional proportional system: an approach to cerebral imaging*. New York, NY: Thieme Medical, 1988.
- Eickhoff SB, Bzdok D, Laird AR, et al. Activation likelihood estimation meta-analysis revisited. *Neuroimage* 2012;59:2349–61.
- Turkeltaub PE, Eden GF, Jones KM, et al. Meta-analysis of the functional neuroanatomy of single-word reading: method and validation. *Neuroimage* 2002;16:765–80.
- Eickhoff SB, Laird AR, Fox PM, et al. Implementation errors in the GingerALE Software: description and recommendations. *Hum Brain Mapp* 2017;38:7–11.
- Turkeltaub PE, Eickhoff SB, Laird AR, et al. Minimizing within-experiment and within-group effects in activation likelihood estimation meta-analyses. *Hum Brain Mapp* 2012;33:1–13.
- Diedrichsen J, Zotow E. Surface-Based display of Volume-Averaged Cerebellar Imaging Data. *PLoS One* 2015;10:e0133402.
- Colloby SJ, O'Brien JT, Taylor JP. Patterns of cerebellar volume loss in dementia with lewy bodies and alzheimer's disease: a VBM-DARTEL study. *Psychiatry Res* 2014;223:187–91.
- Farrow TF, Thiayagesh SN, Wilkinson ID, et al. Fronto-temporal-lobe atrophy in early-stage Alzheimer's disease identified using an improved detection methodology. *Psychiatry Res* 2007;155:11–19.
- Möller C, Vrenken H, Jiskoot L, et al. Different patterns of gray matter atrophy in early- and late-onset Alzheimer's disease. *Neurobiol Aging* 2013;34:2014–22.
- Grossman M, McMillan C, Moore P, et al. What's in a name: voxel-based morphometric analyses of MRI and naming difficulty in Alzheimer's disease, frontotemporal dementia and corticobasal degeneration. *Brain* 2004;127:628–49.
- Irish M, Devenney E, Wong S, et al. Neural substrates of episodic memory dysfunction in behavioural variant frontotemporal dementia with and without C9ORF72 expansions. *Neuroimage Clin* 2013;2:836–43.
- Gómez-Ansón B, Alegret M, Muñoz E, et al. Prefrontal cortex volume reduction on MRI in Preclinical Huntington's disease relates to visuomotor performance and CAG number. *Parkinsonism Relat Disord* 2009;15:213–9.
- Scharmüller W, Ille R, Schienle A. Cerebellar contribution to anger recognition deficits in Huntington's disease. *Cerebellum* 2013;12:819–25.
- Minnerop M, Specht K, Ruhlmann J, et al. Voxel-based morphometry and voxel-based relaxometry in multiple system atrophy—a comparison between clinical subtypes and correlations with clinical parameters. *Neuroimage* 2007;36:1086–95.
- Brenneis C, Boesch SM, Egger KE, et al. Cortical atrophy in the cerebellar variant of multiple system atrophy: a voxel-based morphometry study. *Mov Disord* 2006;21:159–65.
- Chen MH, Lu CH, Chen PC, et al. Association between Autonomic impairment and structural deficit in Parkinson Disease. *Medicine* 2016;95:e3086.
- Camicoli R, Gee M, Bouchard TP, et al. Voxel-based morphometry reveals extranigral atrophy patterns associated with dopamine refractory cognitive and motor impairment in parkinsonism. *Parkinsonism Relat Disord* 2009;15:187–95.
- Giordano A, Tessitore A, Corbo D, et al. Clinical and cognitive correlations of regional gray matter atrophy in progressive supranuclear palsy. *Parkinsonism Relat Disord* 2013;19:590–4.
- Agosta F, Kostić VS, Galantucci S, et al. The in vivo distribution of brain tissue loss in Richardson's syndrome and PSP-parkinsonism: a VBM-DARTEL study. *Eur J Neurosci* 2010;32:640–7.
- Ghosh BC, Calder AJ, Peers PV, et al. Social cognitive deficits and their neural correlates in progressive supranuclear palsy. *Brain* 2012;135:2089–102.

- 39 Karas GB, Burton EJ, Rombouts SA, *et al.* A comprehensive study of gray matter loss in patients with Alzheimer's disease using optimized voxel-based morphometry. *Neuroimage* 2003;18:895–907.
- 40 Habas C, Kamdar N, Nguyen D, *et al.* Distinct cerebellar contributions to intrinsic connectivity networks. *J Neurosci* 2009;29:8586–94.
- 41 Gagnon LG, Belleville S. Working memory in mild cognitive impairment and Alzheimer's disease: contribution of forgetting and predictive value of complex span tasks. *Neuropsychology* 2011;25:226–36.
- 42 Sang L, Qin W, Liu Y, *et al.* Resting-state functional connectivity of the vermal and hemispheric subregions of the cerebellum with both the cerebral cortical networks and subcortical structures. *Neuroimage* 2012;61:1213–25.
- 43 Stopford CL, Thompson JC, Neary D, *et al.* Working memory, attention, and executive function in Alzheimer's disease and frontotemporal dementia. *Cortex* 2012;48:429–46.
- 44 Thomann PA, Schäfer C, Seidl U, *et al.* The cerebellum in mild cognitive impairment and Alzheimer's disease – a structural MRI study. *J Psychiatr Res* 2008;42:1198–202.
- 45 Yoshiura T, Hiwatashi A, Yamashita K, *et al.* Deterioration of abstract reasoning ability in mild cognitive impairment and Alzheimer's disease: correlation with regional grey matter volume loss revealed by diffeomorphic anatomical registration through exponentiated lie algebra analysis. *Eur Radiol* 2011;21:419–25.
- 46 Whitwell JL, Weigand SD, Boeve BF, *et al.* Neuroimaging signatures of frontotemporal dementia genetics: c9orf72, tau, progranulin and sporadics. *Brain* 2012;135:794–806.
- 47 Tan RH, Devenney E, Kiernan MC, *et al.* Terra incognita-cerebellar contributions to neuropsychiatric and cognitive dysfunction in behavioral variant frontotemporal dementia. *Front Aging Neurosci* 2015;7:121.
- 48 Balsters JH, Laird AR, Fox PT, *et al.* Bridging the gap between functional and anatomical features of cortico-cerebellar circuits using meta-analytic connectivity modeling. *Hum Brain Mapp* 2014;35:3152–69.
- 49 Schmahmann JD. Disorders of the cerebellum: ataxia, dysmetria of thought, and the cerebellar cognitive affective syndrome. *J Neuropsychiatry Clin Neurosci* 2004;16:367–78.
- 50 Wolf RC, Vasic N, Schönfeldt-Lecuona C, *et al.* Cortical dysfunction in patients with Huntington's disease during working memory performance. *Hum Brain Mapp* 2009;30:327–39.
- 51 Pelzer EA, Hintzen A, Goldau M, *et al.* Cerebellar networks with basal ganglia: feasibility for tracking cerebello-pallidal and subthalamo-cerebellar projections in the human brain. *Eur J Neurosci* 2013;38:3106–14.
- 52 Mehrabi NF, Waldvogel HJ, Tippet LJ, *et al.* Symptom heterogeneity in Huntington's disease correlates with neuronal degeneration in the cerebral cortex. *Neurobiol Dis* 2016;96:67–74.
- 53 Hallett M. Tremor: pathophysiology. *Parkinsonism Relat Disord* 2014;20(Suppl 1):S118–22.
- 54 Zeng LL, Xie L, Shen H, *et al.* Differentiating patients with Parkinson's Disease from Normal Controls Using Gray Matter in the Cerebellum. *Cerebellum* 2017;16:151–7.
- 55 Mathys C, Caspers J, Langner R, *et al.* Functional Connectivity differences of the Subthalamic Nucleus Related to Parkinson's Disease. *Hum Brain Mapp* 2016;37:1235–53.
- 56 Quinn N, Wenning G. Multiple system atrophy. *Br J Hosp Med* 1994;51:492–4.
- 57 Dickson DW, Rademakers R, Hutton ML. Progressive supranuclear palsy: pathology and genetics. *Brain Pathol* 2007;17:74–82.
- 58 Drikkoningen D, Leunissen I, Caeyenberghs K, *et al.* Regional volumes in brain stem and cerebellum are associated with postural impairments in young brain-injured patients. *Hum Brain Mapp* 2015;36:4897–909.
- 59 Baier B, Stoeter P, Dieterich M. Anatomical correlates of ocular motor deficits in cerebellar lesions. *Brain* 2009;132:2114–24.
- 60 Anderson TJ, MacAskill MR. Eye movements in patients with neurodegenerative disorders. *Nat Rev Neurol* 2013;9:74–85.
- 61 Josephs KA, Xia R, Mandrekar J, *et al.* Modeling trajectories of regional volume loss in progressive supranuclear palsy. *Mov Disord* 2013;28:1117–24.
- 62 Gerstenecker A, Mast B, Duff K, *et al.* Executive dysfunction is the primary cognitive impairment in progressive supranuclear palsy. *Arch Clin Neuropsychol* 2013;28:104–13.