

Journal of Neurology Neurosurgery and Psychiatry

Editor

Professor C Kennard

Deputy Editor

Dr G D Perkin

Associate Editors

Dr L Caplan
Dr S Fleming
Professor I R Whittle

Editorial board

R Al-Shahi (UK)
M P Barnes (UK)
Y Ben-Shlomo (UK)
S F Berkovic (Australia)
I Bone (UK)
M-G Bousser (France)
T Brandt (Germany)
D J Brooks (UK)
M C Dalakas (USA)
M Donaghy (UK)
J S Duncan (UK)
M Filippi (Italy)
P J Goadsby (UK)
M Husain (UK)
P J Kirkpatrick (UK)
S Love (UK)
S Lovestone (UK)
H Markus (UK)
R Maurice-Williams (UK)
T M McMillan (UK)
K Mills (UK)
I F Moseley (UK)
AHV Schapira (UK)
A Thompson (UK)
E Tolosa (Spain)
J Wardlaw (UK)
J H J Wokke (The Netherlands)
N W Wood (UK)
Editor, *BMJ*

Editorial assistants

A L Kirk
E Ioannou

Technical editor

A L Kirk

Instructions to authors

Full instructions are available online at www.jnnp.com/misc/ifora.shtml
If you do not have web access please contact the editorial office:
Journal of Neurology, Neurosurgery & Psychiatry
Division of Neuroscience and Psychological Medicine
Room 10E 15, Imperial College School of Medicine
Charing Cross Hospital
Fulham Palace Road
London W6 8RF, UK
Telephone +44 (0)20 8846 1213
Fax +44 (0)20 8846 7730
Email: editor.jnnp@ic.ac.uk

Subscription information

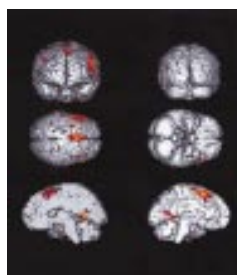

See page iv

Copyright

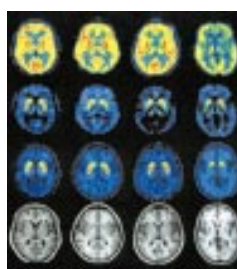
© 2002 *Journal of Neurology Neurosurgery and Psychiatry*. All rights reserved; no part of this publication may be reproduced, stored in a retrieval system, or transmitted in any form or by any means, electronic, mechanical, photocopying, recording, or otherwise without the prior permission of *Journal of Neurology Neurosurgery and Psychiatry*

Authors are required to grant *Journal of Neurology Neurosurgery and Psychiatry* an exclusive licence to publish; further details available online at www.jnnp.com/misc/ifora.shtml

- Journal of Neurology Neurosurgery and Psychiatry* is published by BMJ Publishing Group and printed in UK on acid free paper by Thanet Press Limited, Margate, Kent
- Periodicals postage paid, Rahway, NJ. Postmaster: send address changes to: *Journal of Neurology Neurosurgery and Psychiatry*, c/o Mercury Airfreight International Ltd, 365 Blair Road, Avenel, NJ 07001, USA



See p 483



See p 519



www.publicationethics.org.uk

This journal is a member of and subscribes to the principles of the Committee on Publication Ethics

contents JNNP

Volume 73 Number 5 November 2002

Editorial

- 465 Neutralising antibodies to interferon beta during the treatment of multiple sclerosis
G Giovannoni, F E Munschauer 3rd, F Deisenhammer

Editorial commentaries

- 470 Surgical treatment of temporal lobe epilepsy
S F Berkovic
470 Hippocampal atrophy and neocortical dysfunction in early Alzheimer's disease
J C Baron
471 Meaningful treatment outcomes in Alzheimer's disease
A S Burns
472 Cortical bricks and mortar
D H ffytche

Review: Physical signs

- 473 Joint position sense and vibration sense: anatomical organisation and assessment
S Gilman

Papers

- 478 Bilateral hemispheric alteration of memory processes in right medial temporal lobe epilepsy
S Dupont, Y Samson, P-F Van de Moortele, S Samson, J-B Poline, D Hasboun, D Le Bihan, M Baulac
486 Long term outcome of temporal lobe epilepsy surgery: analyses of 140 consecutive patients
L Jutila, A Immonen, E Mervaala, J Partanen, K Partanen, M Puranen, R Kälviäinen, I Alafuzoff, H Hurskainen, M Vapalahti, A Ylinen
495 Chronic alcohol use and first symptomatic epileptic seizures
M Leone, C Tonini, G Bogliun, F Monaco, R Mutani, E Bottacchi, P Gambaro, E Rocci, T Tassinari, C Cavestro, E Beghi, for the ARES (Alcohol Related Seizures) Study Group
500 Goal setting and attainment in Alzheimer's disease patients treated with donepezil
K Rockwood, J E Graham, S Fay, for the ACADIE Investigators
508 Relation between medial temporal atrophy and functional brain activity during memory processing in Alzheimer's disease: a combined MRI and SPECT study
G E J Garrido, S S Furuie, C A Buchpiguel, C M C Bottino, O P Almeida, C G Cid, C H P Camargo, C C Castro, M F Glabus, G F Busatto
517 Differentiating multiple system atrophy from Parkinson's disease: contribution of striatal and midbrain MRI volumetry and multi-tracer PET imaging
M Ghaemi, R Hilker, J Rudolf, J Sobesky, W-D Heiss
524 Cognitive slowing in Parkinson's disease resolves after practice
D Z Press, D J Mechanic, D Tarsy, D S Manocha
529 How valid is the clinical diagnosis of Parkinson's disease in the community?
A Schrag, Y Ben-Shlomo, N Quinn
535 The neural basis of Charles Bonnet hallucinations: a hypothesis
W Burke

- 542 Head injury outcome prediction in the emergency department: a role for protein S-100B? *W J Townend, M J Guy, M A Pani, B Martin, D W Yates*
- 547 Prevalence of adults with brain arteriovenous malformations: a community based study in Scotland using capture-recapture analysis *R Al-Shahi, J S Y Fang, S C Lewis, C P Warlow*
- 552 Intracranial cerebrospinal fluid measurement studies in suspected idiopathic normal pressure hydrocephalus, secondary normal pressure hydrocephalus, and brain atrophy *A Tsunoda, H Mitsuoka, H Bandai, T Endo, H Arai, K Sato*
- 556 Glial fibrillary acidic protein in late life major depressive disorder: an immunocytochemical study *S Davis, A Thomas, R Perry, A Oakley, R N Kalaria, J T O'Brien*
- 561 Electrophysiological evidence for a defect in the processing of temporal sound patterns in multiple sclerosis *S J Jones, L Sprague, M Vaz Pato*
- 568 Central motor conduction in patients with anti-ganglioside antibody associated neuropathy syndromes and hyperreflexia *Y Oshima, T Mitsui, H Yoshino, I Endo, M Kunishige, A Asano, T Matsumoto*
- 574 Lateralised motor control: hemispheric damage and the loss of deafness *B Hanna-Pladdy, J E Mendoza, G T Apostolos, K M Heilman*

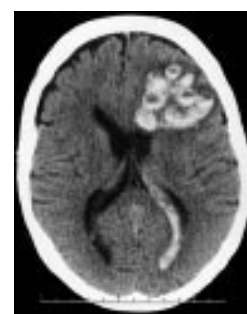Short reports

- 578 Are functional motor and sensory symptoms really more frequent on the left? A systematic review *J Stone, M Sharpe, A Carson, S C Lewis, B Thomas, R Goldbeck, C P Warlow*
- 582 Relative high frequency of the c.255delA parkin gene mutation in Spanish patients with autosomal recessive parkinsonism *E Muñoz, E Tolosa, P Pastor, M J Martí, F Valldor, J Campdelacreu, R Oliva*
- 585 Peripheral mechanisms in tremor after traumatic neck injury *T Hashimoto, H Sato, M Shindo, R Hayashi, S Ikeda*
- 588 Unilateral globus pallidus internus stimulation improves delayed onset post-traumatic cervical dystonia with an ipsilateral focal basal ganglia lesion *J W Chang, J Y Choi, B W Lee, U J Kang, S S Chung*
- 591 Endovascular coiling versus neurosurgical clipping in patients with a ruptured basilar tip aneurysm *E Lusseveld, E H Brilstra, P C G Nijssen, W J J van Rooij, M Sluzewski, C A F Tulleken, D Wijnalda, R L L A Schellens, Y van der Graaf, G J E Rinkel*

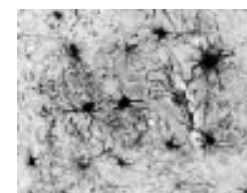
- 594 Non-invasive assessment of extracranial-intracranial bypass grafts using advanced ultrasound technology *D Birchall, P English, L Tacconi*

Letters

- 597 Irregular presence of abnormal prion protein in appendix in variant Creutzfeldt-Jakob disease *S Joiner, J Linehan, S Brandner, J D F Wadsworth, J Collinge*
- 598 Cytokine profiles in HIV seropositive patients with tuberculous meningitis *V B Patel, A Bhigjee, P A Bill, C A Connolly*
- 599 Festination as the leading symptom of late onset idiopathic aqueductal stenosis *O Lehet, J Boschert, J K Krauss, I R Whittle*
- 600 Myoclonic movement disorder associated with microdeletion of chromosome 22q11 *D Baralle, D Trump, C French-Constant, D J Dick*
- 601 Phenobarbitone induced gingival hyperplasia *S Sinha, V Kamath, G R Arunodaya, A B Taly*
- 601 Hashimoto's encephalopathy mimicking Creutzfeldt-Jakob disease: brain biopsy findings *C P Doherty, M Schlossmacher, N Torres, E Bromfield, M A Samuels, R Folkerth*
- 602 Long term tolerability of high dose ergoline derived dopamine agonist therapy for the treatment of Parkinson's disease *P Navan, P G Bain*



See p 534



See p 558

Correspondence

- 604 Dysport produces intrinsically more swallowing problems than Botox: unexpected results from a conversion factor study in cervical dystonia *D Dressler. Reply by D Ranoux, M Zuber, C Gury*
- 604 Diagnostic value of history and physical examination in patients suspected of lumbosacral nerve root compression *D J Lanska*
- 605 Superficial temporal artery pseudoaneurysm following craniotomy *M T Walker, B P Liu*

Book reviews

Neurological picture

- 533 Footprints of coagulopathy *R D Ecker, E F M Wijdicks*

Neurological stamp

- 596 Harvey Williams Cushing (1869–1939) *L F Haas*