

PostScript

LETTERS

Paraneoplastic cerebellar degeneration in olfactory neuroepithelioma

Anti-Hu antibody was first discovered in patients with paraneoplastic encephalomyelitis associated with small cell lung cancer (SCLC). This antibody recognises proteins comprised in the Hu family expressed by neuronal cells as well as SCLC. After the first report, anti-Hu antibody was found in other neoplasms including prostate and breast cancer, adrenal carcinoma, chondromyxosarcoma, neuroblastoma, and neuroendocrine neoplasms at other sites.¹ Olfactory neuroepithelioma (9523/3)² is thought to differ from classic neuroblastoma (9500/3) in its expression pattern of tyrosine hydroxylase, *MYCN* amplification, and fusion of the Ewing sarcoma gene and the Friend leukaemia virus integration 1 gene or the ETS related gene.³

Anti-Hu antibody in association with olfactory neuroepithelioma has not been reported previously. We report a patient with cerebellar ataxia that paralleled the recurrence of the tumour. Serum and cerebrospinal fluid (CSF) from the patient contained anti-Hu antibody, and the olfactory neuroepithelioma resected from the patient expressed Hu antigen.

CASE REPORT

Seven years before admission, a 65 year old man presented with olfactory neuroepithelioma that had invaded the orbit and frontal lobe. The tumour was dissected surgically, and dura mater graft was not used in the surgery. The patient underwent irradiation (total dose of 50 Gy). The tumour recurred at the parotid gland in January 2001, and there was gait instability. The patient consulted a neurologist, but there was no specific finding. The recurrent tumour was surgically dissected; however, the instability progressed rapidly, and at the patient's admission in November 2001, he needed support when walking. There was neither alcoholism nor family history of cerebellar ataxia. His parents were not consanguineous.

General physical examination was negative. There was no lymphadenopathy. He was alert and mentally normal. Olfactory sensation had been decreased since the first surgery, there was a downbeat nystagmus, and muscle strength was maximum. Both superficial and deep sensation were normal. Deep tendon reflex was symmetrical and normal, Romberg test was negative, and no pathological reflex was found. Nose–finger–nose test was normal, but heel–shin test was poor. Dysmetria was marked in both legs. His gait was wide based and ataxic, and tandem gait was impossible. There was no dysarthria.

Haematological studies, blood chemical analyses, and serological studies were normal. Tumour markers including α -fetoprotein, prostate specific antigen, pro-gastrin releasing peptide, neurone specific enolase, sialyl Lewis (a) (CA19–9), and sialyl Lewis

(x) (SLX) were within normal limits. Levels of vitamin B1 and B12 were normal. Protein level in cerebrospinal fluid (CSF) was increased to 105 mg/dl with normal cellularity. Myelin basic protein and oligoclonal IgG band was negative. IgG index was 0.6. No malignant cells were found in the CSF. Nerve conduction study was normal. Short sensory evoked potentials of upper and lower limbs were normal. Electroencephalogram showed beta rhythm at the bilateral frontal region, with otherwise normal findings.

Computed tomography (CT) showed no lung tumour. Magnetic resonance imaging (MRI) showed bilateral leukoaraiosis at bilateral frontal lobes that had been present since after the first surgery. The cerebellum was slightly atrophic.

Titres of anti-Hu antibody in the serum and CSF were 1:1920 and 1:64, respectively (indirect immunofluorescence and Western blotting for recombinant HuD). Serum:CSF antibody titre ratio was 30. The ratio for (CSF/serum antibody titre)/(CSF/serum albumin) was 1.8. These values indicated that intrathecal synthesis of anti-Hu antibody had stopped at this time point. Other anti-neuronal antibodies including anti-Yo, Ri, CV2, Tr, Ma, amphiphysin, and glutamic acid decarboxylase were all negative. Systemic examination including ⁶⁷Ga-citrate scintigraphy did not disclose malignant tumours. Immunohistochemistry with anti-HuD antibody (Santa Cruz, sc-5977, $\times 100$) revealed that a part of the tumour expressed Hu protein (fig 1).

Over the course of 4 years after discharge, the cerebellar ataxia did not worsen further in the absence of immunological treatment. Follow up thoracic CT and tumour marker study did not disclose other malignant tumours. There was no evidence of the recurrence of olfactory neuroepithelioma.

CONCLUSION

This patient presented cerebellar ataxia of the trunk and lower limbs that progressed rapidly within approximately 6 months after the second surgery and stabilised thereafter.

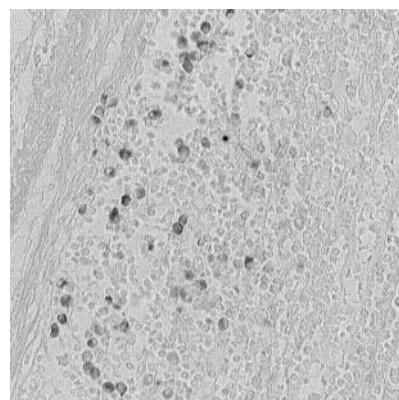


Figure 1 Immunohistochemistry using anti-HuD antibody. A part of the patient's tumour expressed HuD antigen ($\times 400$).

This clinical course is not inconsistent with the natural course of paraneoplastic cerebellar degeneration. Although isolated cerebellar ataxia in anti-Hu antibody positive patients is rare (4/200 patients),¹ a high titre of serum anti-Hu antibody (1:1920) corroborated the diagnosis of paraneoplastic syndrome.¹ The expression of the HuD protein by the olfactory neuroepithelioma confirmed the diagnosis.

Olfactory neuroepithelioma is a neuroectodermal neoplasm that arises from the olfactory epithelium. It is distinguished from classic neuroblastoma as described by Sorensen *et al.*³ Unlike neuroblastoma, olfactory neuroepithelioma shows differentiation to the neural processes and glandular structure and is rarely associated with catecholamine secretion. In addition, olfactory neuroepithelioma expresses epithelial markers such as cytokeratin and a 34 kDa epithelial membrane glycoprotein recognised by monoclonal antibody named Ber-EP4. The tumour in this case expressed both Ber-EP4 and cytokeratin (see Okabe *et al.*,⁴ case no. 6). Moreover, it also expressed luteinising hormone releasing hormone. The expression pattern of Ber-EP4 and cytokeratin was heterogeneous in this tumour.⁴ These findings suggest that the tumour in this case had arisen from the olfactory placode and was distinct from classic neuroblastoma arising from the neural crest.⁵ This neuroepithelial tumour has not been reported to be associated with paraneoplastic syndrome. Our data clearly demonstrate the expression of Hu antigen by the olfactory neuroepithelioma cells and the presence of Hu antibody in his serum and CSF. It is interesting that neurological manifestations developed in parallel with the recurrence of the tumour. The recurrence might have enhanced immune response. Despite resection of the recurrent tumour, the cerebellar ataxia worsened for several months after surgery. However, it did not progress thereafter. In patients with neurological symptoms and Hu antibody, olfactory neuroepithelioma should be considered when a neoplasm is not found at the common sites such as the lung or breast.

K Maeda, T Sasaki, Y Murata, M Kanasaki, T Terashima, H Kawai, H Yasuda

Division of Neurology, Department of Medicine, Shiga University of Medical Science, Otsu, Shiga, Japan 520-2192

H Okabe

Department of Clinical Laboratory Medicine, Shiga University of Medical Science, Otsu, Shiga, Japan 520-2192

K Tanaka

Department of Neurology, Brain Research Institute, Niigata University, Niigata, Japan

Correspondence to: Kengo Maeda, Division of Neurology, Department of Medicine, Shiga University of Medical Science, Otsu, Shiga, Japan 520-2192; kengo@belle.shiga-med.ac.jp

doi: 10.1136/jnnp.2005.066977

Competing interests: none

REFERENCES

- 1 Graus F, Keime-Guibert F, Reñe R, *et al*. Anti-Hu-associated paraneoplastic encephalomyelitis: analysis of 200 patients. *Brain* 2001;**124**:1138–48.
- 2 In: Kleihues P, Cavenee WK, eds. *World Health Organisation classification of tumours: pathology and genetics of tumours of the nervous system*. Lyon: IARC Press, 2000.
- 3 Sorensen PHB, Wu JK, Berean KW, *et al*. Olfactory neuroblastoma is a peripheral primitive neuroectodermal tumor related to Ewing sarcoma. *Proc Natl Acad Sci USA* 1996;**93**:1038–43.
- 4 Okabe H, Okubo T, Ochi Y. On the origin and diagnostic criteria of olfactory neuroblastoma. *Acta Histochem Cytochem* 1997;**30**:181–8.
- 5 Okabe H, Okubo T, Ochi Y. Expression of epithelial membrane glycoprotein by neurons arising from olfactory plate through development. *Neuroscience* 1996;**72**:579–84.

The collagen 1A2 polymorphism rs42524, which is associated with intracranial aneurysms, shows no association with spontaneous cervical artery dissection (sCAD)

In the last decade, extracranial spontaneous cervical artery dissection (sCAD) became increasingly recognised as a common cause of juvenile stroke. Hereditary connective tissue diseases such as Ehlers-Danlos syndrome type IV (EDS IV) and Marfan syndrome can be associated with sCAD and clinical signs of mild connective tissue weakness have been described in some patients with sCAD.¹ Brandt and co-workers found connective tissue aberrations mainly affecting the collagen fibres in skin biopsies of approximately 60% of patients with sCAD.² Similar skin aberrations were found in patients with intracranial aneurysms (IA).³ A familial association of IA and sCAD has been observed in a few families.⁴ These findings suggest that connective tissue abnormalities are common to both diseases and might predispose to IA as well as to sCAD. Recently, association between the functional coding single nucleotide polymorphism (SNP) rs42524 in the collagen 1A2 (COL1A2) gene and IA has been described.⁵ The SNP rs42524 causes a base change G1645C and an amino acid change alanine 549 to proline in the COL1A2 gene (cDNA NM_000089).

In this study we test the hypothesis that the SNP rs42524 is also associated with sCAD. We studied 144 unrelated patients with extracranial sCAD (86 men, mean age 47.4 (standard deviation (SD) 11.5) years; 89 sCAD of the internal carotid artery (ICA), 49 of the vertebral artery (VA), and 6 of the ICA and the VA; patients without known specification of the dissected artery were excluded) and 162 healthy age and sex matched blood donors (98 men, mean age 43.5 (SD 8.7) years) from the province of North Rhine-Westphalia, Germany. All patients were enrolled retrospectively by the Department of Neurology of the University of Münster (described in Konrad *et al*)⁶ and the Department of Neurology of the Alfried Krupp Hospital, Essen in essentially the same way. The diagnosis of sCAD required clinical symptoms suggestive of sCAD and either evidence of intramural haematoma on MRI examination of the cervical arteries with

Table 1 COL1A2 rs42524 genotypes

Group	Genotypes				Alleles		
	GG	CG	CC	p	G	C	p
All sCAD	87 (61)	48 (33)	9 (6)	0.99	222 (77)	66 (23)	1.00
sCAD of ICA	57 (64)	28 (31)	4 (5)	0.79	142 (80)	36 (20)	0.57
sCAD of VA	27 (55)	17 (35)	5 (10)	0.59	71 (72)	27 (28)	0.41
Controls	98 (61)	54 (33)	10 (6)	–	250 (77)	74 (23)	–

Values are n (%), except for the p values. ICA, internal carotid artery; VA, vertebral artery. Six individuals suffered from concomitant sCAD of ICA and VA and were excluded from the subgroup analysis.

transverse sections through the neck or typical signs of sCAD on intra-arterial digital subtraction angiography. Subjects gave informed consent and the study was approved by the local ethics committee. Genomic DNA was extracted from peripheral blood lymphocytes. Genotyping was performed using a PCR-RFLP assay. Genotype and allele differences between groups were assessed using χ^2 statistics. Hardy-Weinberg equilibrium was calculated using an online resource (<http://kursus.kvl.dk/shares/vetgen>). Probability (p) values of less than 0.05 were considered statistically significant. The study had 84% power to detect an association with an OR of 3.19 described in familial Japanese IA and 58% to detect an association with an OR of 1.99 described in sporadic Japanese IA with 95% confidence (PS program; <http://statgen.iop.kcl.ac.uk/gpc/>). The genotype and allele frequencies of the SNP rs42524 are shown in table 1. Genotype frequencies in the patients, as well as in the control group, were in good agreement with Hardy-Weinberg equilibrium ($p=0.49$ for controls and $p=0.47$ for patients). Neither genotype nor allele frequencies showed significant differences between sCAD patients and controls in the whole sample, after stratification for the affected vessel (ICA or VA) (table 1) or after stratification for gender (results not shown).

Comment

The COL1A2 gene is located on chromosome 7q22.1, a chromosomal region showing linkage with IA.⁷ The SNP rs42524 in the COL1A2 gene showed strong association with IA in a Japanese IA cohort and supposedly influences the thermal stability of collagen.⁵ We investigated this SNP in sCAD patients because of the presumed pathophysiological similarities between both diseases. We did not find an association between sCAD and the SNP rs42524. However, it can not be excluded that this is due to ethnically determined differences in allele frequencies, because the chromosome 7q locus for IA as well as the association with the SNP rs42524 were originally found in a Japanese sample in which the C allele has a frequency of only 2.7% in the control group, while we studied a Caucasian population in which the C allele had a frequency of 23%.⁵ The sample size of the Japanese study (260 IA patients) and of our own study (144 sCAD) were of the same order of magnitude. In summary, this study renders it unlikely that the SNP rs42524 plays a major role in the pathogenesis of sCAD in Caucasians. However, this study does not exclude the possibility that other polymorphisms in the COL1A2 gene, which is a very large gene covering 37 000 bp of genomic DNA, are associated with sCAD.

G Kühlenbäumer

Leibniz-Institute of Atherosclerosis Research, University of Münster, Münster, Germany

C Konrad

Department of Psychiatry, University of Münster, Münster, Germany

S Krämer

Department of Radiology, University of Münster, Münster, Germany

B Kis

Department of Neurology, Alfried Krupp Hospital, Essen, Germany

D Nabavi, R Dittich

Department of Neurology, University of Münster, Münster, Germany

E B Ringelstein

Leibniz-Institute of Atherosclerosis Research, University of Münster, Münster, Germany

Correspondence to: Dr G Kühlenbäumer, Leibniz-Institute of Atherosclerosis Research, University of Münster, Domagaskr. 3, D-48149 Münster, Germany; gkuhlen@uni-muenster.de

doi: 10.1136/jnnp.2005.065847

The research reported in this manuscript has partly been sponsored by the Bundesministerium für Bildung und Forschung (BMBF) within the stroke competence network

Competing interests: none declared

Electronic-database information



The following websites have been mentioned in this letter: <http://kursus.kvl.dk/shares/vetgen> and <http://statgen.iop.kcl.ac.uk/gpc/>.

References

- 1 Schievink WI, Wijdicks EF, Michels VV, *et al*. Heritable connective tissue disorders in cervical artery dissections: a prospective study. *Neurology* 1998;**50**:1166–9.
- 2 Brandt T, Hauser I, Orberk E, *et al*. Ultrastructural connective tissue abnormalities in patients with spontaneous cervicocerebral artery dissections. *Ann Neurol* 1998;**44**:281–5.
- 3 Grand-Ginsbach C, Schnippering H, Hauser I, *et al*. Ultrastructural connective tissue abnormalities in patients with intracranial aneurysms. *Stroke* 2002;**33**:2192–6.
- 4 Schievink WI, Mokri B, Michels VV, *et al*. Familial association of intracranial aneurysms and cervical artery dissections. *Stroke* 1991;**22**:1426–30.
- 5 Yoneyama T, Kasuya H, Onda H, *et al*. Collagen type I alpha2 (COL1A2) is the susceptible gene for intracranial aneurysms. *Stroke* 2004;**35**:443–8.
- 6 Konrad C, Langer C, Müller GA, *et al*. Protease inhibitors in spontaneous cervical artery dissections. *Stroke* 2005;**36**:9–13.

- 7 **Onda H**, Kasuya H, Yoneyama T, *et al.* Genomewide-linkage and haplotype-association studies map intracranial aneurysm to chromosome 7q11. *Am J Hum Genet* 2001;**69**:804–19.

BOOK REVIEWS

Essential Neurosurgery, 4th edition

Edited by Andrew H Kaye. Published by Oxford University Press, Oxford 2005, £29.95 (soft-cover), pp 297. ISBN 1405116412

This is a short running textbook running to 280 pages of narrative on the basic principles of neurosurgery written by a Professor of neurosurgery in Melbourne. The author indicates that the book describes his own practice, which he describes as the best from the differing North American and European approaches, incorporating some of the unique advances and philosophies of the Asia Pacific Rim region.

It is a nicely laid out and well written book. It covers all the basic aspects of neurosurgery and someone who reads it from cover to cover will have a good basic grounding in the speciality. I would recommend it to anyone just about to take up an SHO post in neurosurgery and would also advise career neurologists to read it early in their career, to give them a sense of what their neurosurgical colleagues will be up to. Keen medical students who wish to inform themselves well about neurosurgery would also benefit from reading it, although, given the short time that students are exposed to neurosciences nowadays, they may consider it too detailed for the basic level of knowledge they are expected to acquire. I think neurosurgical registrars should already be familiar with the concepts outlined in the book before they start their training.

I suppose it is a sad reflection on our times that I attended a meeting recently with a medical negligence lawyer who was carrying a copy of the second edition of Professor Kaye's book. This is another category of potential purchasers, to whom the third edition can be recommended.

P Richards

The neurology of AIDS, second edition

Edited by Howard E Gendelman, Igor Grant, Ian Paul Everall, Stuart A Lipton, Susan Swindells. Published by Oxford University Press, Oxford, 2005, £145.00 (hardcover), pp 829. ISBN 0-19-852610-5

Today nearly 40 million people are infected with HIV, 95% living in the developing world. Since the first edition of *The Neurology of AIDS* in 1999 there has been considerable progress in understanding HIV. However despite rapid advances in highly active anti-retroviral therapy (HAART) neurological disease continues often in a more chronic form. The recent major advances in basic and clinical research are reflected in the

extensive new information presented in the second edition of this comprehensive book.

The previous four sections have now been expanded to 12 sections divided into several chapters with multiple contributors, including clinicians, patients, and healthcare professionals.

The book starts with a panel discussion setting the scene for the subsequent text and emphasising the challenges for the future.

The first five sections cover advances in basic research on HIV including molecular and cellular biology, immunology, vaccines, the blood brain barrier, and animal models and mechanisms of neurotoxicity including host factors and cellular factors. Parallels are drawn with other neurodegenerative diseases. Section 6 is a poignant collection of patients' accounts of living with neurological complications of AIDS. The next section deals comprehensively with the clinical aspects including dementia, more subtle cognitive disorders seen since the introduction of HAART, spinal cord disease, peripheral neuropathy, myopathy, neoplasms, opportunistic infection, and psychiatric disorders. A section on diagnostics follows including imaging and CSF markers. There is then an expanded paediatric section followed by discussion of antiretroviral and adjunctive drug treatment. The last section reviews the social and behavioural consequences of HIV infection including legal and ethical issues.

The book is very well illustrated throughout.

This outstanding book therefore provides an up to date comprehensive review of the basic science and the clinical aspects of the neurology of AIDS whilst emphasising future likely developments.

It is highly recommended for clinicians, research scientists, students, and other professionals involved in the care of these patients.

J Ball

Classification and diagnosis of headache disorders

Edited by Jes Olsen. Published by Oxford University Press, Oxford, 2005, £85.00 (hardcover), pp 311. ISBN 0-19-856590-9

This volume of *Frontier's in Headache Research* focuses on the application in research and clinical practice of the International Classification of Headache Disorders II (2004).

Section I presents epidemiological considerations, general principles in headache classification, and use of tools such as questionnaires, structured interviews, diaries, and diagnostic software programmes. Section II presents the sub-classification of migraines with and without aura and chronic migraine, probably the most well supported by epidemiological and genetic evidence.

In section III fervent debate continues about the entity "Tension-type headache" and nuances in classification—infrequent, frequent, and chronic tension-type headache. The diagnostic and pathophysiological basis for the core trigeminal autonomic cephalalgias (cluster headache, paroxysmal hemicrania, and SUNCT) is followed by syndromes that occupy the fringe of accepted

sub-classifications—for example, hypnic headache, haemicrania continua, and new persistent daily headache. There is elaboration on a more pragmatic and intuitive ordering of other primary headache disorders such as idiopathic stabbing, cough, exertional, and sexual headache.

Sections IV and V provide the most interesting and thought provoking aspect of headache classification—the secondary headaches—undoubtedly the least evidence-based and consequently the most wanting in reclassification. The chapters discuss the literature and clinical characteristics of disorders such as post-traumatic headache, headache associated with substance (medication) use, infection, and vascular disorders. The chapter "Cranial Neuralgias and Central Causes of Pain" is superbly written. It dispels the myths of ophthalmoplegic "migraine", Eagle's syndrome, and Vidian neuralgia (was it all cluster headache?), while clarifying the phenotype of neuralgia associated with single nerves and their branches—for example, supraorbital neuralgia.

Section VI elaborates upon the successes and difficulties of implementation of ICDH II in practice and research. As one author points out, if a classification is not user friendly, it won't be used. Therefore, the call for a revised shortened classification for clinical practice, reserving the complexities of diagnostic hierarchy to the researcher, is required.

The preface concludes with, "Hopefully it (the current volume) will be useful and interesting reading for all those caring for headache patients as well as for researchers in headache, and others with a general interest in disease classification". It adeptly delivers as intended. It is easy to read, informative, provides helpful tools for the practising clinician, and provides further insights into the developing field of headache research.

A Bahra

CORRECTIONS

doi: 10.1136/jnnp.2004.062455corr1

A Serrano-Pozo, J Nevado-Portero, G Sanz-Fernández, *et al.* Spinal anterior artery territory infarction simulating an acute myocardial infarction (*J Neurol Neurosurg Psychiatry* 2005;**76**:1584). The authors of this Neurological Picture were mistakenly grouped according to their affiliation. The correct ordering of the authors is: A Serrano-Pozo, J Nevado-Portero, G Sanz-Fernández, E Martínez-Fernández.

doi: 10.1136/jnnp.2004.059212corr1

A Ragoschke-Schumm, H Axer, C Fitzek, *et al.* Intracerebral haemorrhage in CADASIL (*J Neurol Neurosurg Psychiatry* 2005;**76**:1606–7). The authors of this Letter were mistakenly grouped according to their affiliation. The correct ordering of the authors is: A Ragoschke-Schumm, H Axer, C Fitzek, M Dichgans, N Peters, J Mueller-Hoecker, O W Witte, S Isenmann.