

SUPRACHIASMAL MENINGIOMA IN A 2-YEAR-OLD CHILD

BY

PAUL TENG

From the Neurosurgical Service, Kaiser Foundation Hospital, Los Angeles, U.S.A.

Intracranial meningioma is a rare tumour in children. In Cushing and Eisenhardt's book (1938) on meningiomas, six occurred in the pre-adolescent age group. A review of the literature found six patients to be under 2 years of age with only one survival (Stern, 1937; Bailey, Buchanan, and Bucy, 1939; Grant, 1947; Cuneo and Rand, 1952). The present report concerns a case of giant meningioma successfully removed from a 2-year-old boy. The tumour was unusual in location, suprachiasmal, and unusual in size, 250 g.

Case Report

A 2-year-old boy was admitted to the hospital on January 14, 1960, his second birthday. He had apparently been well until about nine weeks ago when he vomited repeatedly and gradually became listless, apathetic, irritable, and cross-eyed. The mother stated that he was frequently noted with his right eye turned inward since he was 2 months old. About one month before admission both his hands were shaking, the right more than the left.

Neurological examination showed that the child was not lethargic but listless. He weighed 26 pounds. The head appeared larger than normal, and measured 56 cm. in circumference. Markedly dilated veins were noted in both frontal areas. There was a positive Macewen's sign on percussion. Both pupils were normal in size and reacted well to light. Gross visual field examination showed no defect. There was a mild weakness in the left lateral rectus muscle. Choked disc was noted on both sides. The right arm was hypotonic and weak. Fine tremors were noted in the hands, especially the right. Deep tendon reflexes were all brisk and equal on both sides. No pathological reflex was elicited. A radiograph of the skull showed marked separation of cranial sutures, especially the coronal, at places about 2 cm. wide.

A lumbar puncture showed a pressure of 219 mm. water, and the total protein content was 300.07 mg. %.

On January 18, 1960, under general anaesthesia a ventriculogram was performed through the separated coronal suture. On the right side, at a depth of about 2 cm. from the skin, the ventricular needle was deflected to the side by a hard mass. Five ml. of air was injected along the surface of the mass (Fig. 1). A similar attempt for a ventricular tap on the opposite side was made and the needle again failed to enter the ventricle but the same resistance was encountered. Another 5 ml. of air was

instilled in this side. The injected air outlined a huge lobulated mass in the anterior and middle fossa extending from the midline to both sides.

After the ventriculogram, the patient was operated upon. Two vertical incisions, 2½ in. long, were made in the frontal vertex across the coronal suture and a craniectomy window, 2 × 2 in. in size, was made on each side. The dura flaps were reflected toward the midline, and were sutured temporarily over the scalp. The frontal cortex was noted to be atrophic with obliterated sulci and gyri. Both frontal lobes were pushed backward by an enormous tumour with a hard, nodular, pinkish white glistening surface. The tumour was well encapsulated. It extended anteriorly to the frontal pole of the cranial cavity, posteriorly about 5 cm. behind the coronal suture, and laterally about 3 cm. from the temporal bone on both sides. It was removed piecemeal by intracapsular excavation. The collapsed capsule was lifted easily off the floor of the middle fossa. The optic nerves, chiasm, and optic tracts were markedly stretched downward and posteriorly by the tumour. The flattened optic nerves, chiasm, and optic tracts resembled a small concave hammock upon which had nested a giant meningioma which weighed 250 g. Both internal carotid arteries were depressed and pushed laterally by the tumour. No dural attachment of this tumour was noted. Its blood supply was mainly from the ethmoid arteries.

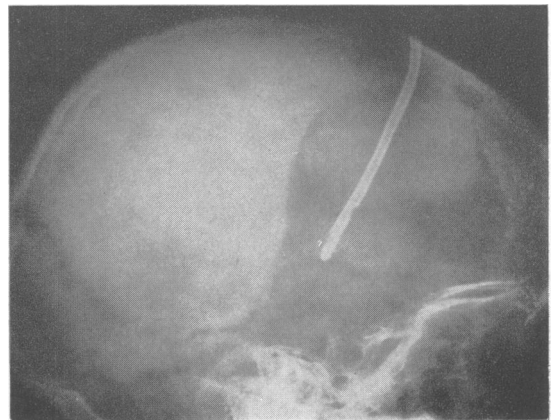


Fig. 1.—Perineoplasm injection of air outlines the lobulated lateral surface of the tumour.

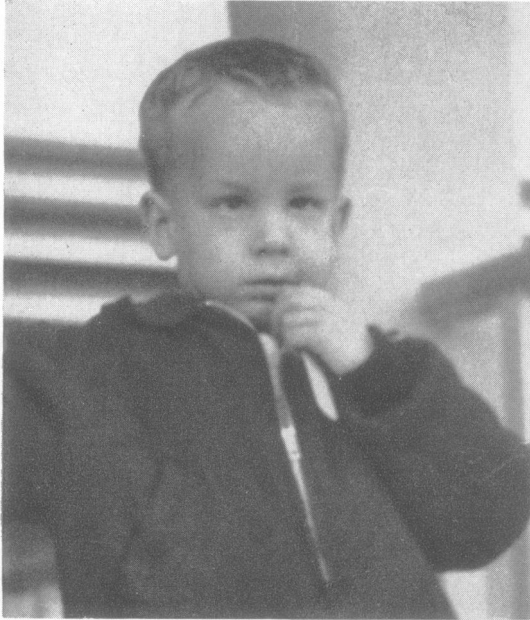

FIG. 2.—Patient photographed one year after surgery.

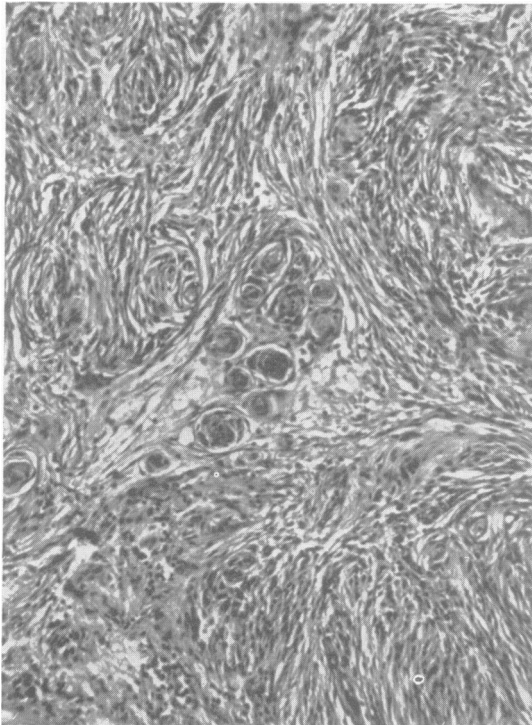


FIG. 3.—Meningioma. $\times 100$.

The post-operative course was uneventful, and the child has made a complete recovery (Fig. 2). The sixth nerve palsy had largely disappeared three months later. His speech was clear and he recited nursery rhymes well. He was active, often 'overactive', and had frequent tantrums.

The pathological diagnosis was psammatous meningioma (Fig. 3).

Comment

A review of the literature revealed several unusual features of intracranial meningioma in children. They are (1) often large or enormous with (2) minimal neurological signs as a result of compensatory head enlargement through separated sutures, (3) more frequent recurrence of growth, (4) higher incidence of sarcomatous change than in adults, (5) lack of dural attachment, and (6) high operative mortality.

In the present case the ventriculogram was performed through the widely separated coronal suture instead of through a regular burr hole, and air was injected between the tumour and the neighbouring surface of the brain instead of intraventricularly. The enormous tumour had displaced the ventricular system posteriorly and shielded it from in front, and therefore, any attempt to reach the lateral ventricle by a frontal puncture would be impossible. The perineoplasm deposition of air had clearly outlined the tumour. The neoplasm was removed through two small craniectomy rectangular windows made through the widened coronal suture lateral to each side of the sagittal line. The exposure of the tumour was satisfactorily adequate throughout the operation. After the intracapsular excavation of the tumour, the capsule was easily lifted off a remarkably stretched optic chiasm. In spite of the fact that the optic tracts, chiasm, and optic nerves were flattened ribbon-like, it is gratifying to note that there has been no visual disturbance. Both fundi showed no evidence of atrophy.

Summary

A case of a large intracranial meningioma in a 2-year-old child has been described. The tumour was successively removed from the anterior and middle fossae. Here it had rested directly upon the optic nerves, chiasm, and tracts.

REFERENCES

- Bailey, P., Buchanan, D. N., and Bucy, P. C. (1939). *Intracranial Tumors of Infancy and Childhood*. University of Chicago Press, Chicago.
- Cuneo, H. M., and Rand, C. W. (1952). *Brain Tumours of Childhood*. Thomas, Springfield, Illinois.
- Cushing, H., and Eisenhardt, L. (1938). *Meningiomas*. Thomas, Springfield, Illinois.
- Grant, F. C. (1947). *Surg. Gynec. Obstet.*, 85, 419.
- Stern, R. O. (1937). *Arch. Dis. Childh.*, 12, 291.