

Intradural enterogenous cyst

S. MOHANTY, C. J. RAO, P. K. SHUKLA, D. N. VERMA,
AND ASHOK K. NAYAK

From the Section of Neurosurgery, Department of Surgery, and Departments of Pathology and Radiology, Institute of Medical Sciences, Banaras Hindu University, Varanasi, India

SUMMARY A 23 year old woman with an intradural extramedullary enterogenous cyst in the cervical region, unassociated with vertebral cleft, presented with two episodes of neurological disturbance at an interval of five years. Subtotal excision of the anteriorly placed cyst at C6 vertebral level was followed by rapid and complete recovery.

Only 23 cases of intradural enterogenous cyst (neurenteric cyst) have been reported in the cervical region (Despande *et al.*, 1972; Reddy *et al.*, 1972; Wilkins and Odom, 1976). Although an associated vertebral cleft is usually present in this condition, we report here an intradural cervical enterogenous cyst which was situated anteriorly, producing an intermittent clinical course as described in cases of arachnoid cysts (Adams and Wegner, 1947; Raja and Hankinson, 1970) and which was not associated with a vertebral cleft.

Case report

A 23 year old married woman (KD, hospital number 1278) was admitted on 26 January 1978 with a history of rapid onset of pain in the cervical region, tingling, numbness, and severe weakness in all four limbs five years previously. With these complaints she had been bedridden for three months, but recovered completely in a further three months with medical treatment only. One month before the present admission she again noticed pain in the cervical region which was sharp, shooting in character, and aggravated on walking. This was associated with tingling and numbness in upper and lower limbs. She had also had difficulty in walking for 15 days and had been confined to bed for the previous week. There was no history of trauma, tuberculosis, or lathyrism, and no history of sphincter disturbances. General examination was normal. Neurological examination disclosed normal higher functions and no cranial nerve deficit. She had complete loss of all sensory

modalities below the eighth cervical segment. Spasticity was present in all four limbs and there were flexor spasms in the lower limbs. She had grade 2 power in the upper limbs and complete paralysis in the lower limbs. The biceps, triceps, brachioradialis, knee, and ankle jerks were grossly exaggerated. The Babinski sign was positive on both sides, and the abdominal reflexes were absent.

Examination of the spine revealed tenderness at C7 level. Investigations showed a normal haemogram, fasting blood sugar 4.4 mmol/l, and blood urea 3.3 mmol/l. The cerebrospinal fluid contained no cells, sugar 3.9 mmol/l, and proteins 5 g/l. Plain radiography of the cervical spine revealed no abnormality. A myelogram disclosed an intradural extramedullary type of block at the level of the C6 vertebra (Fig. 1). Laminectomy (C5-C7) showed bulging of the dura mater. It was opened to reveal humping of the cervical cord at C6 segment. On retraction of the cord after sectioning the ligamentum denticulatum, a bluish coloured cystic mass was seen situated anteriorly and adherent to the dura mater. The cyst was aspirated of 10 ml of clear colourless fluid. Subtotal excision of the cyst was performed. The patient started moving the lower limbs a few hours after the operation, and regained normal power after 10 days. Microscopic examination of the cyst revealed an enterogenous cyst (Fig. 2) lined by low columnar epithelium thrown into villous structures. Many cells were engorged with material which stained positive for mucin. The wall of the cyst consisted of loose fibrovascular tissue without any muscle or cartilage.

Discussion

Intraspinal enterogenous cyst is a relatively rare

Address for reprint requests: Dr S. Mohanty, Head of Neurosurgery, Department of Surgery, Institute of Medical Sciences, Banaras Hindu University, Varanasi-221005, India.

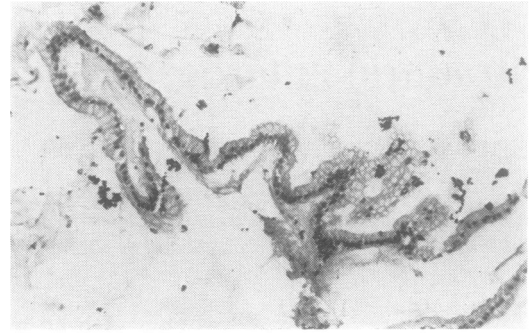
Accepted 26 October 1978

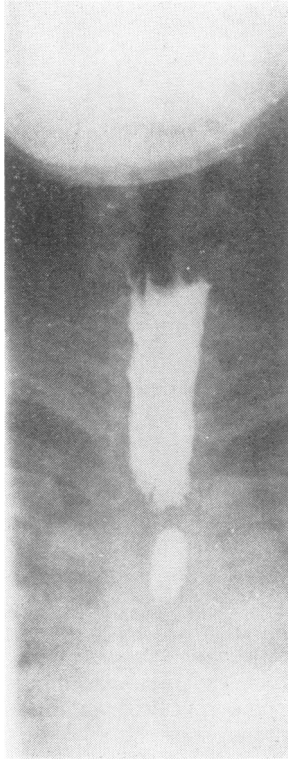

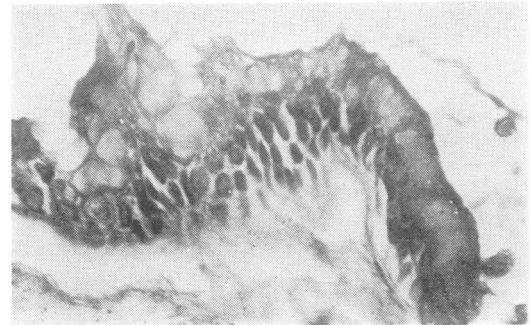
Fig. 1 Myelogram (AP) showing intradural extramedullary block at C6 level.

cause of spinal cord compression. It is more often seen in males during the first decade of life in the cervical region, and occasionally produces a relapsing clinical course (Neuhauser *et al.*, 1958) as seen in our case, rather than the progressive course reported by Despande *et al.* (1972). Interestingly there was a gap of five years between two episodes of neurological disturbance in our case. If untreated, enterogenous cysts may rupture into the spinal cord (Despande *et al.*, 1972) or the cyst wall may undergo peptic ulceration and haemorrhage (Wilkins and Odom, 1976). Complete or partial excision of the cyst has produced excellent results.

The enterogenous cyst originates from the incomplete separation of the notochord and endoderm at about the third week of gestation, resulting in the inclusion of endodermal elements in the spinal canal. According to Bently and Smith (1960), enterogenous cysts are invariably associated with a vertebral cleft, but there are a few reports of intraspinal enterogenous cyst not associated with abnormality of the spine (Scoville *et al.*, 1963; Despande *et al.*, 1972). The present patient did not have any abnormality of the spine (ver-



(a)



(b)

Fig. 2 (a) Cyst wall made up of a single layer of columnar epithelium with basally placed nuclei and thrown into villi-like folds. There is also evident mucin activity. H and E, original magnification $\times 160$. (b) Area of cyst wall showing large mucin globules bursting on to the surface. The apparent heaping up of epithelial cells is an artefact caused by oblique sectioning. PAS, original magnification $\times 600$.

tebral cleft) indicating a complete sequestration of the endodermal element in the spinal canal. Wilkins and Odom (1976) have grouped the intraspinal enterogenous cysts into three groups—group A consisting of cysts with simple epithelial lining over a basement membrane, group B having epithelial folds and invaginations and other elements of gastrointestinal tract, muscle and cartilage, and group C showing presence of ependymal and glial tissues. A study of sex chromatin in 11 of the reported intraspinal neurenteric cysts suggested presence of a teratoma lined by enterogenous epithelium. Our patient appears to be in group A. Occasionally, such a cyst may be confused with an ependymal cyst at histology. However, enterogenous cysts show the presence of mucin as in the present case and a lack of blepharoplasts which are seen in the epithelium cyst.

References

- Adams, R. D., and Wegner, W. (1947). Congenital cyst of the spinal meninges as cause of intermittent compression of the spinal cord. *Archives of Neurology and Psychiatry (Chicago)*, **58**, 57–69.
- Bently, A., and Smith, J. R. (1960). Developmental posterior enteric remnants and spinal malformations. The split notochord syndrome. *Archives of Disease in Childhood*, **35**, 76–86.
- Despande, D. H., Pandya, S. K., Dastur, H. M., and Bharucha, E. P. (1972). An intraspinal enterogenous cyst. *Neurology (India)*, **20**, 217–220.
- Neuhauser, E. B. D., Harris, G. B. C., and Berrett, A. (1958). Roentgenographic features of neurenteric cysts. *American Journal of Roentgenology*, **79**, 235–240.
- Raja, I. A., and Hankinson, J. (1970). Congenital spinal arachnoid cysts. *Journal of Neurology, Neurosurgery, and Psychiatry*, **33**, 105–110.
- Reddy, D. R., Subrahmaniam, M. V., Pravakar, V., and Rao, B. D. (1972). Neurenteric cyst (a case report). *Neurology (India)*, **20**, 221–223.
- Scoville, W. M., Manlapaz, J. S., Otis, R. D., and Cabieses, F. (1963). Intraspinal enterogenous cyst. *Journal of Neurosurgery*, **20**, 704–706.
- Wilkins, R. H., and Odom, G. L. (1976). Spinal intradural cyst. In *Handbook of Clinical Neurology*, volume 20, pp. 53–102. Edited by P. J. Vinken and G. W. Bruyn. North-Holland: Amsterdam.