

Progressive hemi-dystonia due to focal basal ganglia lesion after mild head trauma

SIR,—We wish to record a case of a young girl who developed progressive hemi-dystonia following a mild head injury. The particular points of interest are the delay in the onset of the neurological deficit following the accident, the subsequent observed progression of dystonia for a period of 24 months, and the finding of a focal basal ganglia lesion on CT scan.

In April 1971, a five-year-old previously healthy girl was involved in a road traffic accident and was knocked down. She grazed the right side of her head and face, but did not lose consciousness or fracture her skull. She vomited and required admission to hospital, but no neurological damage was evident and she was discharged well two days later. One week after discharge, her parents noted clenching of the right hand; in the next few weeks, she developed difficulty with walking due to a tendency to catch her right foot. Over the next 24 months she developed frank dystonic posturing of the right hand, right arm and right foot. The only possible evidence of pyramidal deficit was weakness of the long finger extensors on the right. Since then, the child's condition has not deteriorated; indeed, her gait has improved and she no longer walks on her toes.

She was born to healthy unrelated parents at term following a normal pregnancy. Birth weight was 8 lb. The neonatal period was normal. Her developmental milestones were normal; she walked at 12 months and began to talk at 17 months. Two elder siblings are normal. On examination now, at the age of 14 years, the right upper limb exhibits dystonic spasms, which extend the arm behind the child's back, and there are superimposed slow writhing, mainly extensor, movements of the right fingers and wrist. There is inversion and some plantar flexion of the right foot as she walks. There is no dystonia of the left limbs or axial muscles.

Initially, it was thought that this child's dystonia was idiopathic in origin,

particularly as it progressed in severity over a period of 24 months. Skull radiographs, an air encephalogram, EEG, and copper studies were normal. However, a CT scan, performed in March 1980, revealed a discrete area of low attenuation in the basal ganglia of the left hemisphere, with the appearance of an old infarct (figure). It now

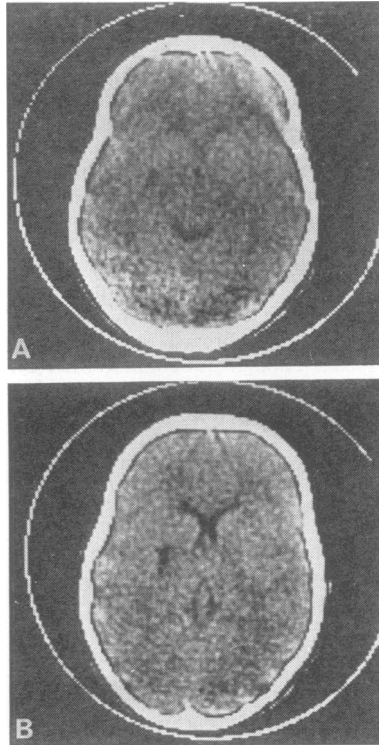


Figure CT scan shows a narrow band of low attenuation extending laterally into the left putamen from the posterior limb of the internal capsule (A: cut 4A; B: cut 4B; 1 cm above A).

seems most likely that the child's hemi-dystonia was secondary to a mild non-concussive head injury. Maki *et al*¹ recently have reported four children, aged 10 months to 10 years, who developed unilateral basal ganglia infarcts after mild head injuries, which were insufficient to cause loss of consciousness for more than a few minutes. All

had a mild to moderate hemiparesis, and one developed transient abnormal movements of the affected limbs as they regained power. Maki *et al* also reported three other children with severe head injuries producing coma and a dense hemiparesis, who developed transient athetoid movements of the affected limbs as they regained power. Burke *et al*² also report a two-year-old girl rendered unconscious with a hemiparesis by a severe head injury, who six years later developed hemi-dystonia superimposed on the mild residual hemiparesis. They also quote a case report by Messimy *et al*³ of a thirty-year-old man who developed a focal dystonia of the left arm beginning four years after a non-concussive head injury, and associated with calcification of the right caudate nucleus. It is of particular interest to note that trauma-induced dystonia in our patient appeared days after the incident and, like its idiopathic counterpart, progressed over a period of two years. This child also supports the proposition that hemi-dystonia often is caused by unilateral rather than by generalised basal ganglia disease.

References

- 1 Maki Y, Akimoto H, Enomoto T. Injuries of basal ganglia following trauma in children. *Child's Brain* 1980; 7:113–23.
- 2 Burke RE, Fahn S, Gold AP. Delayed-onset dystonia in patients with "static" encephalopathy. *J Neurol Neurosurg Psychiatry* 1980; 43:789–97.
- 3 Messimy R, Diebler C, Metzger J. Dystonie de torsion du membre supérieur gauche probablement à un traumatisme crânien. *Rev Neurol (Paris)* 1977; 133:199–206.

EM BRETT, RD HORNE

The Hospital for Sick Children,
Great Ormond Street, London WC1

MP SHEEHY, CD MARSDEN

University Department of Neurology
Institute of Psychiatry and
King's College Hospital Medical School,
Denmark Hill, London SE5