

Short report

Vertical supranuclear gaze palsy with secondary syphilis

NGR PAGE, JS LEAN, MD SANDERS

From the Medical Ophthalmology Department, St Thomas' Hospital, London

SUMMARY A 48-year-old man presented with a vertical gaze palsy associated with secondary syphilis. It is suggested that the eye movement disorder is due to syphilitic endarteritis in the mesodiencephalic region.

Secondary syphilis presents most frequently as a cutaneous eruption with generalised lymphadenopathy 2-6 weeks after the primary infection. Meningitis, hepatitis and periostitis are other features seen less consistently.¹ Iritis is the most common ophthalmological manifestation, but retinal periphlebitis and optic neuritis also are recognised.² During this phase of the disease, dissemination of *Treponema pallidum* occurs and ocular involvement may occasionally be detected in the aqueous.³ However, consistently high levels of anti-treponemal antibody, both IgG and IgM subtypes, are found. An endarteritis associated with this immune response is thought to be responsible for many of the systemic manifestations.

Neurological involvement in the secondary stage is usually either asymptomatic and detected only by cerebrospinal fluid (CSF) analysis, or the result of meningeal inflammatory changes. Isolated cranial nerve palsies during or following an attack of basal meningitis may occur, but are now seen infrequently.² Communicating hydrocephalus due to impairment of CSF absorption associated with such a meningitis may rarely cause gaze and pupil abnormalities as a late manifestation of syphilis. Conjugate gaze palsies due to cerebral infarction are rare and so far as we are aware, a vertical gaze palsy due to early syphilis has not been previously recorded.

Case report

The patient was a 48-year-old white man who presented with double vision and feeling unsteady. Four days

Address for reprint requests: NGR Page, MRCP, St Thomas' Hospital, London SE1 7EH, UK.

Received 1 August 1981

Accepted 29 August 1981

before admission he had developed a non-itchy rash on his arms which subsequently spread to his legs and trunk. On the day of admission he awoke with double vision, worse on looking to the right, and felt as if he was drunk. He had a mild generalised headache and was sensitive to bright light. He was slightly unsteady on walking. One month previously he had been treated with oral indomethacin by his family doctor for a painful leg. There was no relevant past medical history. He was a homosexual who had a regular partner, but who had had a casual sexual contact one to two months before presentation. He was a fit-looking man with a generalised erythematous maculo-papular rash involving the trunk and the limbs, including the palms and the soles. Axillary and inguinal nodes were palpable. There was no evidence of a primary syphilitic lesion. He was afebrile and normotensive. The visual acuity was 6/6, N5 in each eye. Vertical saccadic and pursuit eye movements were completely abolished both on attempted elevation and depression (fig), however, oculocephalic (doll's head) movements were preserved. Bell's phenomenon could not be elicited. Vertical optokinetic nystagmus was abnormal, but did not evoke convergence movements. Initially, unusual small amplitude vertical and oscillatory movements of the left eye were noted, but these rapidly resolved. Horizontal eye movements and convergence were normal and there was no diplopia. The pupils reacted normally to light and near reflexes, there was no evidence of lid retraction. Slit lamp examination, visual fields and fundal examination were all normal. There was no meningism and the rest of the nervous system was normal apart from a tendency to veer to the left when walking. There were no cerebellar or long tract signs.

INVESTIGATIONS

A clinical diagnosis of secondary syphilis was made and confirmed by identification of the *T pallidum* from the skin lesions by dark ground illumination microscopy. The blood serology showed VDRL positive 1:32, TPHA positive 1:640 and FTA Abs IgG and IgM positive.

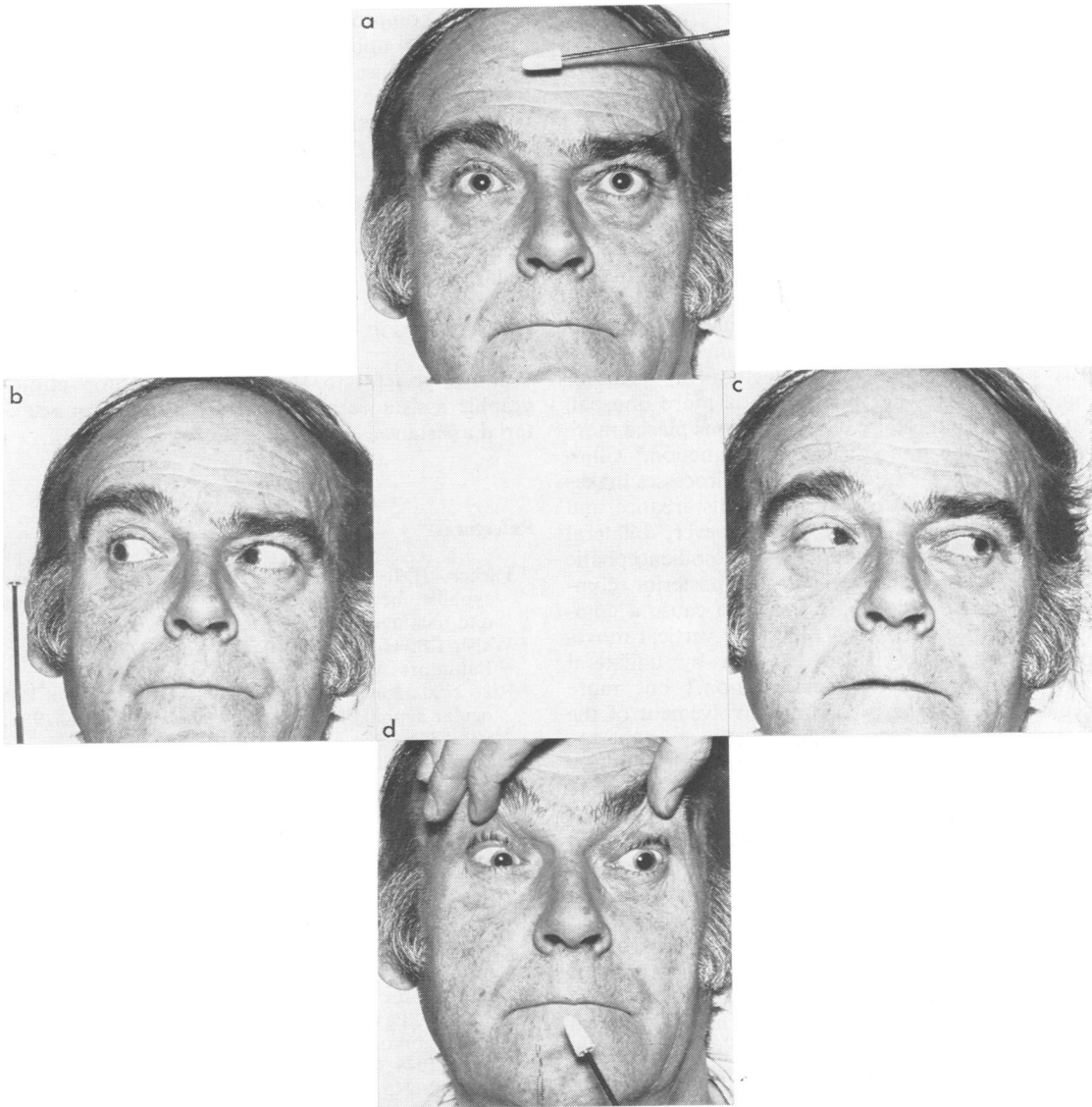


Figure Full horizontal eye movements and failure of attempted elevation and depression on command and following at the start of the illness (the pupils have been dilated by mydriatics).

The ESR was 44 and the Hb and PCV normal with a mild macrocytosis. The skull radiographs were normal and a CT scan with overlapping cuts of the brain stem did not reveal any mass lesion or displacement. At lumbar puncture the CSF was colourless and under normal pressure. There was no increase in the red or white cell counts, the protein was 0.39 g/l and all CSF serology negative. Polyacrylamide gel electrophoresis of the CSF did not reveal any evidence of intrathecal immunoglobulin synthesis

Progress

He was treated for syphilis with daily penicillin injections, initially under steroid cover, with rapid symptomatic improvement. When reassessed one month later, his eye movements also showed considerable improvement. At this time he had full elevation of both eyes and depression was possible to about 75% of normal. Eye movements were otherwise normal and the rest of the neurological and ophthalmological examination was also normal.

Discussion

This patient presented with a complete paralysis of both saccadic and pursuit components of voluntary gaze suggesting a vertical supranuclear gaze palsy. The exact anatomical substrate for vertical eye movements is still unclear. However, supranuclear control of saccadic eye movements via the fronto-mesencephalic pathway and pursuit movements via the occipito-mesencephalic pathway certainly become closely associated in the region of the subthalamic nuclei.⁴ Lesions in these regions may lead to isolated loss of supranuclear control.⁵ Experimentally, the critical areas affected in paralysis of upgaze are the pretectum or posterior commissure.⁶ Downgaze paralysis is more unusual, but can be produced by bilateral lesions placed more rostrally at the meso-diencephalic junction.⁷ Clinically, the irregular extent of disease processes makes it difficult to relate ocular motor disturbance and precise anatomical locations. However, bilateral lesions of the pretectum or mesodiencephalic junction, or those involving the posterior commissure, are considered necessary to cause a complete vertical gaze palsy.⁸ Binocular vertical movements have been elicited in man by unilateral stimulation within the diencephalon.⁹ but more recent work¹⁰ suggests that the involvement of the posterior commissure is of importance.

In this case the presence of normal pupillary responses and the absence of lid retraction, imply that the pathology is more rostral than the pretectal nuclei or the posterior commissural pathways, and almost certainly bilateral. Such a location is consistent with the absence of convergence and retraction nystagmus.¹¹ The eye movement disorder developed at the same time as the acute eruption of syphilis, but the exact aetiological relationship remains presumptive, although the rapid response to treatment favours that diagnosis. The neurological manifestations of secondary syphilis are typically the result of meningitis, but there were no clinical signs or abnormalities of the cerebrospinal fluid to suggest this. There was no evidence of demyelination in other sites or at other times, and there was no biochemical evidence of immunoglobulin synthesis in the CSF. Wernicke's encephalopathy was considered in view of the high alcohol consumption and blood macrocytosis, but vertical supranuclear gaze palsy does not occur without other ocular abnormalities in this condition.¹² Moreover, neither a confusional state nor polyneuritis was present; nor was there evidence to support the diagnosis of either a progressive supranuclear palsy (Steele Richardson Syndrome) or a lipoid storage disease. The normal CT scan excluded hydrocephalus and

makes a compressive lesion of the brain stem or pineal region unlikely.

The acute onset of an isolated gaze palsy followed by gradual recovery suggests a vascular aetiology with microinfarction. Although there was no evidence of degenerative or hypertensive vascular disease in this case, it is well recognised that the endarteritis of syphilis can cause cerebral infarction.¹³ It seems probable that a localised infarction at the meso-diencephalic or subthalamic region related to the endarteritis occurring during secondary syphilis was responsible for the unusual ocular motor abnormalities in this patient.

We are grateful to Mr R Sennhenn for photographic assistance and to Mrs P Wright for secretarial assistance.

References

- 1 Parker JDJ. Uncommon complications of early syphilis, hepatitis, periostitis, iritis with papillitis and meningitis. *Brit J Vener Dis* 1972;**48**:32-6.
- 2 Walsh FB, Hoyt WF. *Clinical Neuro-Ophthalmology*. Baltimore: Williams and Wilkins, 1969.
- 3 Rice NSC, Jones BR, Wilkinson AE. A study of late ocular syphilis II. *Trans Ophthalmol Soc UK* 1968; **88**:257-73.
- 4 Daroff RB, Hoyt WF. Supranuclear disorders of ocular control systems in man; clinical, anatomical and physiological correlates. In: Bach-y-Rita P and Collins CC, eds. *The control of eye movements*. New York: Academic Press, 1971.
- 5 Sanders MD, Bird AC. Supranuclear abnormalities of the vertical ocular motor system. *Trans Ophthalmol Soc UK* 1970;**90**:433-49.
- 6 Pasik P, Pasik T, Bender MB. The pretectal syndrome in monkeys. I, Disturbances of gaze and body posture. *Brain* 1969;**92**:521-34.
- 7 Kömpf D, Pasik T, Pasik P, Bender MB. Stimulation and lesion of studies of downward gaze in monkeys. *Brain* 1979;**102**:527-58.
- 8 Christoff N. A clinico-ophthalmologic study of vertical eye movements. *Arch Neurol* 1974;**31**:1-8.
- 9 Nashold BS, Gillis JP. Ocular signs from brain stimulation. *Arch Ophthalmol* 1967;**77**:609-18.
- 10 Seaber JM, Nashold BS. Comparison of ocular motor effects of unilateral stereotactic midbrain lesions in man. *Neuro-ophthalmology* 1980;**1**:95-9.
- 11 Bender MB, Pasik P, Pasik T, Rudolph SH. Vertical gaze: clinical and experimental considerations with particular reference to oblique movements. *Neuro-ophthalmology* 1980;**1**:2:79-94.
- 12 Victor MD, Adams RD, Collins GA. *The Wernicke-Korsakoff Syndrome*. Oxford: Blackwell Scientific Publications, 1971.
- 13 Merritt MM, Adams RD, Solomon HC. *Neurosyphilis*. New York: Oxford University Press, 1946.