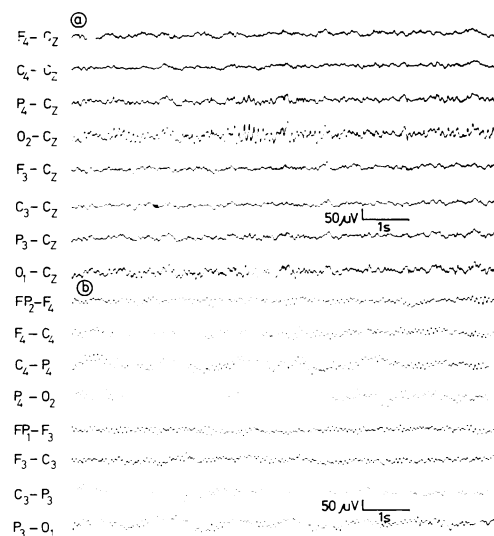


Alpha coma in a child

Sir: Electroencephalographic (EEG) activity in the alpha frequency has been reported in comatose patients following anoxic encephalopathy or brainstem infarction.¹⁻³ Features which distinguish this abnormal pattern from normal alpha activity have been well described and include (1) a diffuse or frontal distribution, (2) decreased or absent reactivity to external stimuli, and (3) a clinical setting of coma.³ The pathogenesis of the alpha-like activity is unclear, particularly with respect to whether it represents an abnormal presentation of the patient's prior alpha rhythm, or is abnormal rhythmic activity generated *de novo* by damaged cortical or diencephalic neurons or both.³ The prognosis for survival in patients with alpha coma pattern is poor, but there are several reports of patients who have survived, although most with neurologic sequelae.^{4,5}

A 12-year-old boy with idiopathic ventricular tachycardia was seen with cardiac arrest following ventricular fibrillation. He had a history of cardiac arrhythmias and required chronic therapy with antiarrhythmic drugs including quinidine, propranolol, and disopyramide phosphate. A prior episode of ventricular fibrillation at age 3 years resulted in coma for 2 weeks. An EEG obtained at age 10 was normal showing a well-developed 50-60 μV 10 Hz alpha rhythm which attenuated with eye opening (fig A). Examination on admission revealed a semi-comatose child with spontaneous respirations, flexion movements to painful stimuli, and absent corneal response with intact pupillary light reflexes and oculovestibular reflexes. The child remained unresponsive for 19 days when his neurological condition began slowly to improve. Six months later his examination showed limb and gait ataxia, dysarthric speech and a moderately severe learning disorder. An EEG obtained on day 1 revealed diffuse slowing comprised of low voltage polymorphic 1-2 Hz waves and small amounts of intermixed 7-8 Hz activity. On day 3 the EEG was characterised by widespread 11.5 Hz rhythmic activity unreactive to auditory, visual or noxious stimuli (fig B). At times during the record, this alpha-like pattern disappeared and electrographic changes suggesting sleep were seen including 12 Hz spindles in the para-



sagittal area intermixed with 6-7 Hz waves. On day 10, the EEG showed continuous polymorphic and rhythmic 5-7 Hz activity, residual 1-3 Hz waves and abnormal sleep patterns.

The term "alpha coma" refers to the association of clinical coma with an EEG pattern superficially resembling that of relaxed wakefulness. It is most commonly seen within 3-4 days after an acute anoxic injury, but can also be seen transiently in patients with brainstem lesions involving portions of the rostral pons and midbrain tegmentum.⁴ Particularly, in these latter circumstances, the alpha coma pattern must be distinguished from the normal EEG of patients with the "locked-in" syndrome due to lesions of the ventral pons. To our knowledge, there are only two other reports of alpha coma in children.^{6,7} One child died, but the other recovered without neurological sequelae. Our child survived, but with moderately severe deficits secondary to the anoxic injury. A previously normal EEG showed an alpha rhythm that was clearly different in frequency, distribution, and reactivity to the alpha-like activity recorded while the patient was in coma. This supports the interpretation that the alpha coma pattern is an abnormally generated rhythm and not a distortion of retained normal activity. Since two of the three paediatric cases reported with alpha coma survived, the prognosis associated with this EEG abnormality may be less dismal in children than adults.

Fig (A) EEG obtained at age 10 yr. The child is drowsy but an intermittent well-formed 10 Hz alpha rhythm is present, of slightly higher amplitude on the right.

Fig (B) EEG obtained at age 12 yr. Three days after a cardiorespiratory arrest. Widespread 11.5 Hz alpha-like activity is present, unreactive to eye opening or alerting stimuli.

WALTER J MOLOFSKY

College of Medicine and Dentistry of New Jersey,
100 Bergen Street-MSB H506,
Newark, New Jersey 07103, USA

References

- 1 Chatrjian GE. EEG pattern resembling wakefulness in unresponsive decerebrate state following traumatic brain-stem infarct. *Electroencephalogr Clin Neurophysiol* 1964;**16**:285-9.
- 2 Vignaendra V. Electroencephalographic rhythms of alpha frequency in comatose patients after cardiopulmonary arrest. *Neurology (Minneapolis)* 1974;**24**:582-8.
- 3 Westmorland BF. Alpha-Coma. *Arch Neurol* 1975;**32**:713-8.
- 4 Grindal AB. "Alpha pattern coma": 24 cases with 9 survivors. *Ann Neurol* 1977;**1**:371-7.
- 5 Sorensen K. Prognostic significance of alpha frequency EEG rhythm in coma after cardiac arrest. *J Neurol Neurosurg Psychiatry* 1978;**41**:840-2.
- 6 Yamada T. Alpha pattern coma in a 2 year old child. *Arch Neurol* 1979;**36**:225-7.
- 7 Collins TA. EEG rhythm of alpha frequency in a 22 month old child after strangulation. *Neurology (Minneapolis)* 1980;**30**:1316-9.