

## Short report

# Spinal cord compression by amyloid tissue

OLIVER J McANENA, MICHAEL P FEELY, WF KEALY

*From the Departments of Neurosurgery and Histopathology, the Regional Hospital, Wilton, Cork, Ireland*

**SUMMARY** Spinal cord compression by a mass of amyloid tissue arising from the thoracic vertebrae is described in a 72-year-old female. Investigations failed to provide a primary cause for this amyloid tissue.

In a review of the literature, only one case of spinal cord compression by an amyloid deposit has been found.<sup>1</sup> Amyloidosis of the nervous system is known to cause peripheral neuropathy and autonomic disturbances due to direct involvement of peripheral nerves.<sup>2,3</sup> Multiple myeloma is known to cause paraplegia by extradural deposits and vertebral collapse. Compression of nerve roots by myelomatous tissue extending from contiguous bone have been described. Peripheral neuropathy which does not depend on compression of nervous structures by tumour tissue has also been well recognised both in cases of primary amyloidosis and multiple myeloma.<sup>4</sup> Progressive paraparesis due to a mass of amyloid tissue compressing the spinal cord has only recently been described.<sup>1</sup>

### Case report

A 72-year-old female presented in July 1980 with progressive lower limb paraparesis and urinary retention during the past three weeks. She was anorectic and had lost 7 kg in weight. She had no pain. There was no relevant drug or family history and no history of chronic illness. She had lower limb weakness and a sensory deficit below the mid-thoracic region with urinary retention. Lower limb reflexes were brisk. Erythrocyte sedimentation rate was 50 mm/h; haemoglobin 11.7 g/dl, blood urea 34 mmol/l; serum calcium 2.34 mmol/l. Twenty-four hour urinary protein was 0.44 g from 1460 ml of urine. Repeat Bence Jones protein urinalysis was negative. Serum immunoelectrophoresis detected no abnormal bands. Serum immunoglobulins were IgG 149 iu/ml (12.95 g/l) (normal range (NR) 84–

201 iu/ml, 7.3–17.5 g/l). IgA 105 iu/ml (1.76 g/l) (NR 45–211 iu/ml, 0.76–3.54 g/l). IgM 61 iu/ml (0.53 g/l) (NR 82–313 iu/ml, 0.71–2.72 g/l). Repeat bone marrow aspirations were normal. Rectal biopsy was negative. A myelogram revealed a complete block at the sixth thoracic vertebral level. Multiple well-circumscribed sclerotic lesions were seen on skeletal survey (fig 1). There was no evidence of vertebral collapse or nephrocalcinosis. At operation, a friable extradural mass was found arising from the laminae and transverse processes of the sixth and seventh thoracic vertebrae compressing the dura and obstructing its blood flow. Histology, using haematoxylin and eosin (fig 2), Congo Red and fluorescein staining showed trabeculated, soft bony tissues lying in the marrow spaces and, separately, round sometimes laminated and partially calcified eosinophilic structureless masses which had the tinctorial qualities of amyloid.

Electron microscopy confirmed the fibrillary appearances characteristic of amyloid. The amyloid was also distributed in the connective tissue and in the walls of some muscular blood vessels. The marrow contained occasional plasma cells. Green birefringence, also characteristic of amyloid was present on examination under polarising light microscopy. The patient had minimal neurological improvement after the operation. She had an episode of gastrointestinal haemorrhage one month later. Barium meal, follow through and barium enema were normal. Approximately three months after her initial assessment, urinary Bence Jones protein was positive. Her blood urea rose to 50 mmol/l. She died one month later. There was no necropsy.

### Discussion

Much has been discovered in recent years regarding the aetiology and pathogenesis of amyloidosis and its classification has recently been redefined.<sup>5</sup> Immunocytic amyloidosis refers to acquired amyloidosis syndromes not associated with infectious, inflammatory or non-immunocyte derived dys-

Address for reprint requests: Dr OJ McAnena, Cork Regional Hospital, Cork, Eire.

Received 4 December 1981 and in revised form 7 May 1982  
Accepted 28 June 1982

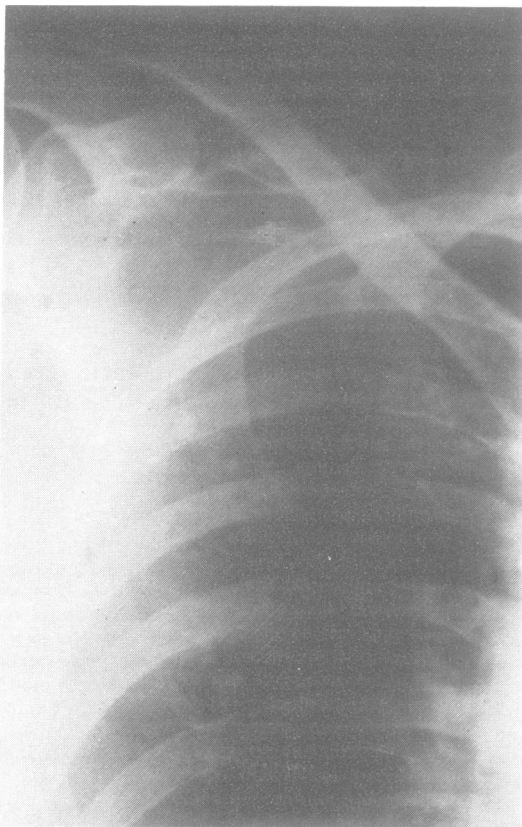


Fig 1 Radiograph of right upper thorax showing osteosclerotic lesions.

crasis or neoplastic disorder, regardless of the organ distribution of amyloid deposits. Plasma-cell-myeloma associated amyloidosis (myeloma amyloidosis) is similar to monoclonal gammopathy (monoclonal protein) with amyloidosis except for the overt neoplastic character of the underlying plasma cell disorder.

Our patient presented with atypical symptoms and signs. She had no bone pain. Skeletal lesions were mainly osteosclerotic. Repeated bone marrow aspirations failed to show plasmacytosis. Serum immunoelectrophoresis showed no homogenous peak. Depressed levels of IgM with normal mean levels of IgG and IgA in monoclonal protein amyloidosis have been previously reported.<sup>6</sup> The presence of a Bence Jones protein in the urine of a patient with amyloidosis suggests the existence of both an immunocytic amyloidotic process and amyloid fibrils derived from the circulating Bence Jones proteins.<sup>5</sup> This may have been the underlying pathology in our patient's case.

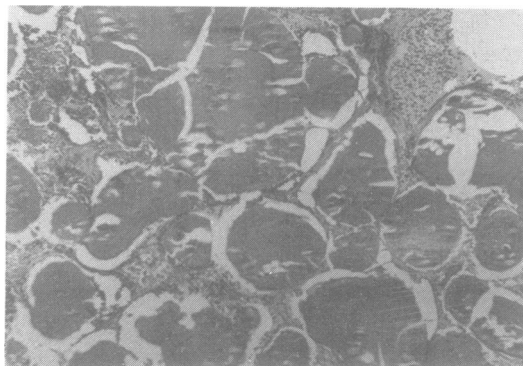


Fig 2 Section of bone showing large amyloid deposits (H & E  $\times 44$ ).

Multiple myeloma patients present almost exclusively with osteolytic lesions although sclerotic lesions have been described.<sup>7,8</sup> Despite a later development of gastrointestinal haemorrhage and identification of urinary Bence Jones attempts at attributing the presence of amyloid tissue to an underlying myeloma were inconclusive.<sup>9</sup>

Amyloidosis primarily involving bone has been described previously but is rare unless associated with a plasma cell dyscrasia.<sup>10</sup> On the other hand, most if not all cases of primary amyloidosis result from deposition in tissue of a plasma cell product.<sup>11</sup>

Our patient would probably be best classified as a case of monoclonal gammopathy amyloidosis which, by definition, is similar to plasma-cell-myeloma-associated amyloidosis as described by Glenner.<sup>5</sup> Whether of primary or secondary origin, spinal cord compression in this case was due to the presence of amyloid tissue as diagnosed by biopsy.

We are grateful for the assistance of Professor E Sweeney, Department of Histopathology, St James' Hospital, Dublin in carrying out electron microscopy on the specimens.

#### References

- 1 Prasad BK, Andrews K, Dutton J, Reid H. Localised amyloid deposit producing paraplegia. *Br Med J* 1981;**283**:1087.
- 2 Cohen AS. Amyloidosis. *N Engl J Med* 1962;**277**:522-30, 547-83, 628-38.
- 3 Norborg C, Kristensson K, Olsson Y, Sourander P. Involvement of the autonomous nervous system in primary and secondary amyloidosis. *Acta Neurol Scand* 1973;**49**:31-8.
- 4 Victor M, Banker BQ, Adams RD. The neuropathy of multiple myeloma. *J Neurol Neurosurg Psychiatry* 1958;**21**:73-88.

- <sup>5</sup> Glenner GG. Amyloid deposits and amyloidosis. *N Engl J Med* 1980;**302**:1283–92, 1333–44.
- <sup>6</sup> Cathart ES, Ritchie RF, Cohen AS, Brandt K. Immunoglobulins and amyloidosis; an immunologic study of 62 patients with biopsy proven disease. *Am J Med* 1972;**52**:93–101.
- <sup>7</sup> Rodriguez AR, Lutcher CL, Coleman RW. Osteosclerotic myeloma. *JAMA* 1976;**236**:1872–4.
- <sup>8</sup> Rondier J, Simon F, Cayla J, Bontoux D, Delbarre F. Myeloma et osteocondensation (A propos de deux observations). *Sem Hop Paris* 1975;**51**:157–67.
- <sup>9</sup> Costa G, Engle RL Jr, Schilling A, *et al.* Melphalan and prednisone: An effective combination for the treatment of multiple myeloma. *Am J Med* 1973;**54**:589–99.
- <sup>10</sup> Khojasteh A, Arnold LK, Farhangi M. Bone lesions in primary amyloidosis. *Am J Haematol* 1979;**7**:77–86.
- <sup>11</sup> Glenner GG, Page DL. Amyloid, amyloidosis, and amyloidogenesis. *Int Rev Exp Pathol* 1976;**15**:1–81.