

Short report

Joubert-Boltshauser syndrome with polydactyly in siblings

J EGGER, MH BELLMAN, EM ROSS, M BARAITSER

From the Hospital for Sick Children, Great Ormond Street, and the Central Middlesex Hospital, London, UK

SUMMARY Two siblings are described with clinical features of the Joubert-Boltshauser syndrome. Both had polydactyly and one had fleshy tumours of the tongue. Computed tomography of the brain showed hypoplasia of the cerebellar vermis, associated in one case with a cyst of the fourth ventricle.

The association of developmental defects of the cerebellar vermis with mental retardation, episodic hyperpnoea and abnormal eye movements was recognised by Joubert *et al*¹ in four siblings and one sporadic case. Boltshauser *et al* distinguished it from simple aplasia of the vermis and from the Dandy-Walker syndrome.²⁻⁴ Several case reports have since been published adding other abnormalities such as unsegmented midbrain tectum,⁵ occipital meningoencephalocoele,⁶ agenesis of the corpus callosum,⁷ epilepsy,⁸ and chorioretinal colobomata.¹ Two siblings, whose clinical signs and symptoms resemble those of Joubert-Boltshauser syndrome have been reported with polydactyly,¹⁰ which was also present in the single case reported in Joubert's original paper.¹ We describe two siblings who fulfil the criteria for Joubert-Boltshauser syndrome. Neuroradiological examination in one showed features of the Dandy-Walker malformation and both had polydactyly.

Patients and investigations

Case 1

BK, a girl, was the first child of unrelated healthy parents of Indian origin. Pregnancy was normal. She was born by forceps delivery because of meconium stained liquor. The airways were cleared immediately via an endotracheal tube. Birth weight was 3720 g and the headcircumference 38 cm. Apgar scores were 5, 6 and 10 at 1, 5, and 10 minutes. Abnormalities noted at birth were the presence of

six well formed digits on both hands and feet and a large posterior fontanelle. At the age of 9 hours the infant became increasingly restless and began having apnoeic episodes with bradycardia and cyanosis as well of tachpnoea (frequency up to 95 respirations/min). Haemoglobin, glucose, calcium, blood gases, CSF examination, chest radiograph, ECG and chromosomes were normal. An EEG showed irregular theta and delta waves and irregular sharp and slow waves. Radiographs of the skull revealed a small midline defect inferior to the lambdoidal sutures. Computed tomography (CT) of the brain showed moderate dilatation of the lateral and third ventricles and the posterior fossa was almost entirely filled with a cyst of CSF attenuation which was continuous with the fourth ventricle. There was a remnant of brain tissue anteriorly in the floor of the posterior fossa. The cerebellum appeared to be absent (fig 1). At the age of 7 days a cystoperitoneal shunt was inserted. The child continued to have frequent episodes of apnoea and tachypnoea and died at 6 weeks from a purulent meningitis.

Case 2

MK, the brother of the girl described in the case history 1, was born at term after an uneventful pregnancy. There was polyhydramnios and the amniotic fluid was meconium stained. The airways were cleared after immediate endotracheal intubation and the child received positive pressure ventilation for five minutes. Apgar scores were 4, 9 and 10 at 1, 5, and 10 minutes. Birth weight was 3300 g and headcircumference was 35 cm. Malformations noted at birth were polydactyly of both hands and feet and bilateral fleshy nodules on the under surface of the tongue. At the age of 9 hours he began having apnoeic episodes followed by tachypnoeic respiration. Unless terminated by tactile stimulation, or mask and bag ventilation, the apnoea lasted up to two minutes and was associated with bradycardia and cyanosis. The tachypnoeic episodes lasted up to 20 minutes with a respiration rate of 80 to 100/min. Haemoglobin, glucose, calcium, blood gases, CSF examination and a chest radiograph showed no abnormalities and blood and urine

Address for reprint requests: Dr J Egger, The Hospital for Sick Children, Great Ormond Street, London WC1N 3JH, UK.

Received 19 January 1982 and in revised form 26 March 1982
Accepted 9 April 1982

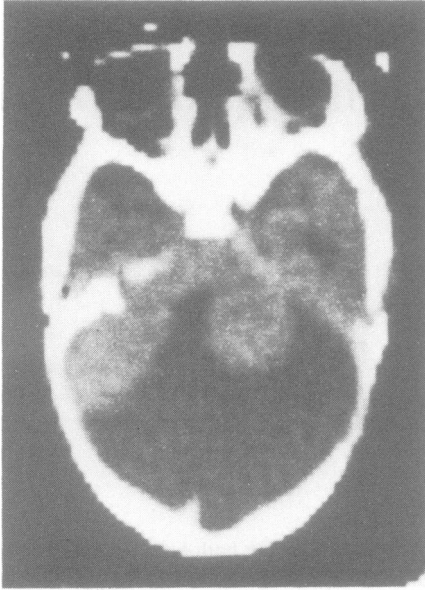

Fig 1 Case 1: CT showing a large cyst of CSF attenuation in the posterior fossa. Small remnant of brain tissue anteriorly on the floor of the posterior fossa. The cerebellar vermis is absent. The cerebellar hemispheres are hypoplastic.

cultures remained sterile. An EEG showed patchy irregular slow activity. A skeletal survey revealed postaxial polydactyly of hands and feet with supranumerary carpal bones, obtuse mandibular angles, upper cervical vertebrae with patent posterior arches, numerous wormian bones in the lambdoid sutures and a small midline defect inferior to the lambda. CT of the brain showed an enlarged fourth ventricle communicating with a midline cystic space extending to the cisterna magna (fig 2). Chromosomes were normal. Ultrasound examination of the kidneys showed no abnormality. All aspects of his development have been delayed: He smiled at three months, was able to lift up his chin at four months and followed with his eyes at ten months. He continued to have episodes of irregular respiration. When examined at 26 months he could hold his head upright but was unable to sit unsupported. He was generally hypotonic and tendon reflexes could not be elicited. He had developed a roving nystagmus, he reacted to auditory stimuli but had not started speaking. The head circumference was below the 2nd centile. A repeat CT scan showed no change compared to the previous one and ERG and VER were normal.

Discussion

Developmental defects of the cerebellar vermis are classified into the following categories: simple aplasia, Joubert syndrome, Dandy-Walker malformation, and tectocerebellar dysraphism with occipi-

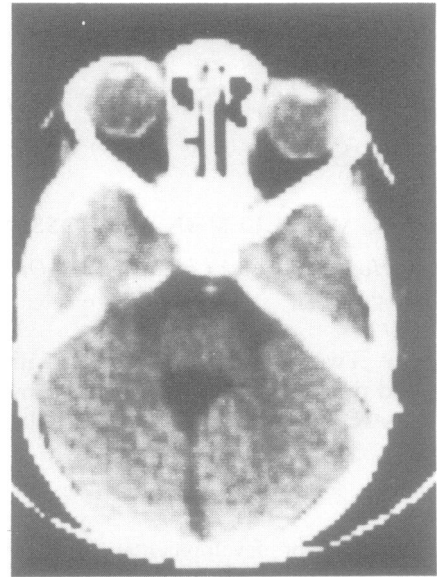


Fig 2 Case 2: CT showing an enlarged fourth ventricle communicating with cisterna magna.

tal encephalocoele.¹¹ Each of these is distinct clinically and pathologically, although overlaps occur.

The symptoms of the Joubert-Boltshauser syndrome are episodes of tachypnoea occurring in wakening and in non-rapid eye movement sleep, apnoeic episodes and irregular jerking eye movements. Postmortem examination in one case³ showed aplasia of the vermis, heterotopia of cerebellar nuclei and anomalies at the level of the cervicomedullary junction. These included absence of the pyramidal decussation and abnormalities of the solitary and gracile nuclei, which were thought to account for the abnormal respiration.

In Dandy-Walker malformation neuropathological findings are aplasia of the vermis, heterotopia of the cerebellar and cerebral cortex, anomalies of medullary centres with a widespread distribution and cystic dilatation of the fourth ventricle.³ The clinical picture is dominated by excessive enlargement of the head. Agenesis of the corpus callosum, polydactyly, and cleft palate may be associated features.^{12,13} A cyst of the fourth ventricle, found to be composed of an outer layer of pia and an inner layer of ependyma occasionally with cerebellar tissue in between is one important pathological criterion for the diagnosis of the Dandy-Walker malformation.¹² A cyst has not been present in reported cases of the Joubert-Boltshauser syndrome.

CT in case 1 in this study showed a cyst of the fourth ventricle compatible with the Dandy-Walker

malformation. The signs and symptoms, however, did not differ from the sib (Case 2), whose CT findings are comparable with those seen in Joubert-Boltshauser syndrome. Polydactyly, present in both siblings in this report has occasionally been reported in the Dandy-Walker malformation,¹² but once only in the Joubert-Boltshauser syndrome.¹ Polydactyly was also present in two siblings, reported as having the orofacial digital syndrome type II.¹⁰ With mental retardation, intermittent tachypnoea, a large fourth ventricle on pneumoencephalography and a fleshy lingual tumour in one, these patients clearly resemble ours. However the designation of orofacial digital syndrome type II is questionable; in this condition midline cleft lip is common,¹⁴ but mental retardation, tachypnoea and roving eye movements are not.

The clinical features in our patients were characteristic of Joubert-Boltshauser syndrome. However, neuroradiological findings in case 1 were typical of Dandy-Walker malformation. In addition, both patients had occipital bony defects in the skull indicating the presence of an encephalocele which is a feature of tectocerebellar dysraphism.¹¹ Considerable overlap between syndromes with dysplasia of the cerebellar vermis has occurred in our patients. They have a condition resembling Joubert-Boltshauser syndrome with polydactyly and tongue tumours. Whether this association is a separate entity will have to be determined by further reports of sibships.

We thank Dr John Wilson for permission to study his patient, and Miss Damsari Silva for typing the manuscript.

References

- ¹ Joubert M, Eisenring JJ, Robb JP, Andermann F. Familial agenesis of the cerebellar vermis. A syndrome of episodic hyperpnea, abnormal eye movements, ataxia, and mental retardation. *Neurology (Minneapolis)* 1969;**19**:813-25.
- ² Boltshauser E, Isler W. Joubert syndrome: Episodic hyperpnea, abnormal eye movements, retardation and ataxia, associated with dysplasia of the cerebellar vermis. *Neuropädiatrie* 1977;**8**:57-66.
- ³ Friede RL, Boltshauser E. Uncommon syndromes of cerebellar vermis aplasia. I: Joubert syndrome. *Dev Med Child Neurol* 1978;**20**:758-63.
- ⁴ Boltshauser E, Herdan M, Dummermuth G, Isler W. Joubert syndrome: Clinical and polygraphic observations in a further case. *Neuropediatrics* 1981;**12**:181-91.
- ⁵ Calogero JA. Vermian agenesis and unsegmented mid-brain tectum. Case report. *J Neurosurg* 1977;**47**:605-8.
- ⁶ Dralle ED, Schmidt-Sommerfeld E. Zusammenhaenge zwischen Atemregulation und paradoxem Schlaf bei einem Patienten mit Joubert-Syndrom. *Klin Pädiat* 1979;**191**:83-90.
- ⁷ Curatolo P, Mercuri S, Cotroneo E. Joubert syndrome: A case confirmed by computerized tomography. *Dev Med Child Neurol* 1980;**22**:362-6.
- ⁸ Burroni M, Perrotta F, Rossolini V. Sindrome di Joubert. Contributo clinico. *Minerva Pediatrica* 1980;**32**:763-6.
- ⁹ Lindhout D, Barth PG, Valk J, Boen Tan TN. The Joubert syndrome associated with bilateral chorioretinal coloboma. *Eur J Pediatr* 1980;**134**:173-6.
- ¹⁰ Gustavson KH, Kreuger A, Petersson PO. Syndrome characterized by lingual malformation, polydactyly tachypnoea and psychomotor retardation. (Mohr syndrome.) *Clin Genet* 1971;**2**:261-6.
- ¹¹ Friede RL. Uncommon syndromes of cerebellar vermis aplasia. II: Tectocerebellar dysraphia with occipital encephalocele. *Dev Med Child Neurol* 1978;**20**:764-72.
- ¹² Hart MN, Malamud N, Ellis WG. The Dandy-Walker syndrome. A clinicopathological study based on 28 cases. *Neurology (Minneapolis)* 1972;**22**:771-80.
- ¹³ Tal Y, Freigang B, Dunn HG, Durity FA, Moyes PD. Dandy-Walker syndrome: Analysis of 21 cases. *Dev Med Child Neurol* 1980;**22**:189-201.
- ¹⁴ Mohr OL. A hereditary sublethal syndrome in man. *Skr. Norske Vidensk. Akad., I Mat.-Naturv. Kl.* 1941;**14**:3-17.
- ¹⁵ Fried K, Liban E, Lurie M, Friedman S, Reisner SH. Polycystic kidneys associated with malformations of the brain, polydactyly and other birth defects in newborn siblings. *J Med Genet* 1971;**8**:285-90.
- ¹⁶ Tucker CC, Finley SC, Tucker ES, Finley WH. Orofacial-digital syndrome, with polycystic kidneys and liver: pathological and cytogenetic studies. *J Med Genet* 1966;**3**:145-7.