

## Letters

## References

- <sup>1</sup> Kogure KP, Scheinberg A, Matsumoto R, Busto R, Reinmuth O. Catecholamines in experimental brain ischemia. *Arch Neurol* 1975;32:21-4.
- <sup>2</sup> Moskowitz MA, Wurtman RJ. Acute stroke and brain monoamines. In: Scheinberg P, ed. *Cerebrovascular Diseases*. New York: Raven Press, 1976:153-66.
- <sup>3</sup> Bralet J, Beley P, Bralet AM. Catecholamine levels and turnover during brain ischemia in the rat. *J Neural Transmission* 1980; 48:143-55.
- <sup>4</sup> Harrison MJG, Marsden CD, Jenner P. Effect of experimental ischemia on neurotransmitter amines in the gerbil brain. *Stroke* 1979;10:165-8.
- <sup>5</sup> Robinson RG. Differential behavioural and biochemical effects of right and left hemispheric cerebral infarction in the rat. *Science* 1979;205:705-10.
- <sup>6</sup> Frattola L, Albizzati M, Spano PF, Trabucchi M. Treatment of Huntington's chorea with bromocriptine. *Acta Neurol Scand* 1977; 56:37-45.
- <sup>7</sup> Prescott RJ, Garraway AJ. Predicting functional outcome following acute stroke using a standard clinical examination. *Stroke* 1982;13:641-7.
- <sup>8</sup> Meyer JS, Welch KMA, Okamoto S, Shimazu K. Disordered neurotransmitter function. Demonstration by measurements of norepinephrine and 5-hydroxytryptamine in CSF of patient with recent cerebral infarction. *Brain* 1974;97:655-64.
- <sup>9</sup> Margolin DI, Marsden CD. Episodic dyskinesias and transient cerebral ischemia. *Neurology (NY)* 1982;32:1379-80.
- <sup>10</sup> Bae SH, Vates TS, Kenton EJ. Generalized chorea associated with chronic subdural hematomas. *Ann Neurol* 1980;8:449-50.
- <sup>11</sup> Bloom FE. Neurotransmitters and CNS disease. The future. *Lancet* 1982;ii:1381-5.

### Myelopathy secondary to metastatic carcinoid tumour

Sir: Metastasis of carcinoid tumour to the nervous system is uncommon<sup>1-5</sup> and spinal cord compression from a metastasis has been reported on only one occasion.<sup>6</sup> This is a report of a 56-year-old woman who presented with a thoracic myelopathy due to metastatic carcinoid tumour.

She was admitted with a three month history of T<sub>3</sub> radicular pain, paraesthesiae in both legs, ataxia and falls. Three years previously she had had a laparotomy for small bowel obstruction due to an ileo-caecal carcinoid tumour. The bowel wall was infiltrated and similar tumour was found in the mesenteric lymph nodes. After operation an isotope liver scan was normal and screening for 5-hydroxyindole acetic acid (5-HIAA) was negative. On this admission

examination showed an asymmetric spastic paraparesis without a sensory level. Palpation of T<sub>3</sub> and T<sub>4</sub> was painful. Plain radiography of the thoracic spine showed sclerosis of the body and pedicle of T<sub>3</sub>. A myodil myelogram demonstrated an extradural block at the level of T<sub>3</sub>. The CSF total protein was 4.0 g/l without a pleocytosis.

A T<sub>2</sub>-T<sub>3</sub> laminectomy was performed. After removal of the right T<sub>3</sub> pedicle a mass was seen in the anterior extradural space to the right of T<sub>3</sub> and in contact with the T<sub>3</sub> nerve root. A biopsy of this mass was taken and found to be carcinoid tumour (fig). During surgery there were wide fluctuations in blood pressure: the systolic pressure varying between 160 and 70 mm Hg; diastolic pressures between 105 and 40 mm Hg. These variations were directly related to manipulation of the tumour. On returning to the ward a urinary screen for 5-HIAA was negative.

After operation the patient was paraplegic. Treatment with radio-therapy was commenced on the eighth post-operative day and a total of 3570 rads were delivered in 16 sessions over 28 days to the affected part of the cord. The paraplegia slowly improved and three months later she was walking with the aid of a frame and leg caliper. Eleven months later she became jaundiced and at laparotomy multiple metastases were found in the liver, pelvis and mesentery. The urine now contained 5-HIAA. A cholecysto-jejunostomy was performed followed by abdominal radio-

therapy but she died 10 months later. 2 years 1 month after she presented with a paraparesis and 5 years after her original symptoms.

It is unknown why carcinoid tumours rarely metastasise to involve the central nervous system. This is the second reported case of carcinoid presenting as a spinal tumour. Both cases were middle aged women who presented with an asymmetric spastic paraparesis. In Kirkpatrick *et al*'s patient the primary site was in the bronchus and the natural history of the disease was much longer. She was alive 10 years after her first neurological symptoms whereas this patient was dead within two and a half years. Although our patient's paraplegia improved following radiotherapy resolution of cord oedema or ischaemia may have contributed to her improvement.

Troublesome changes in blood pressure during surgery have been reported before<sup>7</sup> and are thought to be due to the effect of vasoactive peptides released from the carcinoid tumour. These include serotonin, bradykinin, histamine, noradrenaline, dopamine,<sup>8</sup> ACTH,  $\beta$ -endorphin and methionine enkephalin.<sup>9</sup> Prostaglandins have also been detected and they too have haemodynamic effects on the cardiovascular system.<sup>10</sup>

Although carcinoid tumours were thought to be resistant to irradiation, improved prognosis with total abdominal radiotherapy has been reported.<sup>11</sup> Management of carcinoids metastasising from

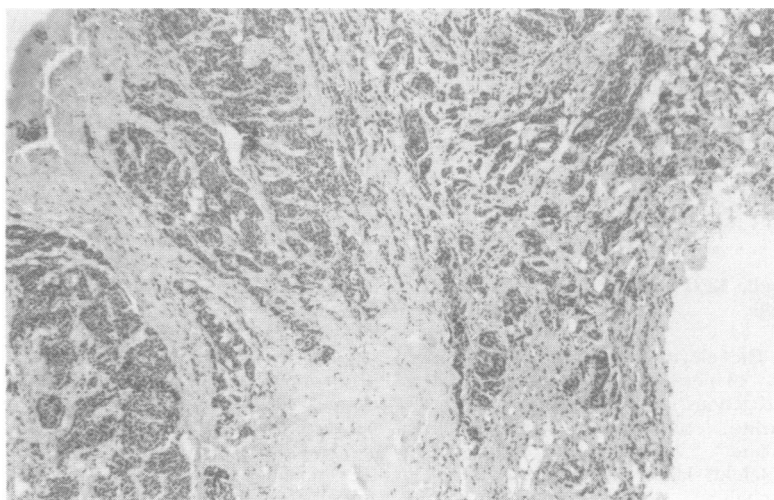


Fig Microscopic appearance of the T<sub>3</sub> extradural mass showing carcinoid tumour ( $\times 240$ ).

the bowel should be surgical and followed by total abdominal radiotherapy. Spinal metastases causing a paraparesis should be in most cases decompressed, biopsied and treated with radio-therapy.

CJM POOLE  
 Department of Neurology,  
 St Thomas' Hospital,  
 London SE1 7EH.

**References**

- 1 Bouldin TW, Killebrew K, Boone SC, Gay RM. Metastasis of a rectal carcinoid to the posterior fossa. *Neurosurgery* 1979;5:496-9.
- 2 Fishman ML, Rosenthal S. Optic nerve metastasis from a mediastinal carcinoid tumour. *Br J Ophthalmol* 1976;60:583-8.
- 3 Karkos J. Morphological picture of intestinal carcinoid metastasis to the cerebellum. *Neuropathol Pol* 1971;9:231-7.
- 4 Kovachev D, Ruseva V. Carcinoid of the stomach with metastasis into the dura mater. *Vutr Boles* 1976;15:98-103.
- 5 Wagner PK, Gabbert H, Brunner H. Gastric carcinoid with brain metastases. *Med Clin* 1979;74:1439-43.
- 6 Kirkpatrick DB, Dawson E, Haskell CM, Batzdorf U. Metastatic carcinoid presenting as a spinal tumour. *Surg Neurol* 1975;4:283-7.
- 7 Dery R. Theoretical and clinical considerations in anaesthesia for secreting carcinoid tumours. *Can Anaesth Soc J* 1971;18:245-63.
- 8 Goedert M, Otten U, Suda K, et al. Dopamine, norepinephrine and serotonin production by an intestinal carcinoid tumour. *Cancer* 1980;45:104-7.
- 9 Pullan PT, Clement-Jones V, Corder R, et al. Ectopic production of methionine encephalin and beta-endorphin. *Br Med J* 1980;280:758-9.
- 10 Sandler M, Karim SMM, Williams ED. Prostaglandins in amine-peptide-secreting tumours. *Lancet* 1968;ii:1053-4.
- 11 Gaitan-Gaitan A, Rider WD, Bush RS. Carcinoid tumour—cure by irradiation. *Int J Radiat Oncol Biol Phys* 1975;1-2:9-13.

Accepted 5 May 1984

**Periodic EEG pattern in meningovascular syphilis**

Sir: The electroencephalographic abnormality of periodic complexes occurs in a heterogenous group of disorders, such as subacute sclerosing panencephalitis, subacute vascular encephalopathy, Creutzfeldt-Jakob disease, herpes simplex encephalitis, anoxic encephalopathy, metabolic encephalopathy, drug intoxication, subcortical arteriosclerotic

encephalopathy, human rabies encephalitis and infectious mononucleosis encephalitis.<sup>1-4</sup> The following report of periodic EEG activity in association with meningovascular syphilis is believed to be unique.

The patient, a 32-year-old right handed black Libyan soldier was hospitalised on 22 January 1984 with a six week history of headache and impairment of memory and intellectual capacity. He became inefficient at his work and exhibited nervousness and aggression. A week prior to admission he had two episodes of generalised convulsions after which he lapsed into a state of semi-stupor. He was married and had four children. On examination at the time of admission, he was drowsy, mute and failed to respond to verbal commands. He had neck stiffness. The pupils, ocular movements and the optic fundi were normal. There was a partial right facial paresis. He moved the right upper and lower limbs less, the right sided deep tendon jerks were brisk and the right plantar response was extensor. His temperature was normal; the general physical examination and the rest of the systemic examination revealed no abnormality. Normal investigations included routine haematology, urine analysis, blood biochemistry, radiographs of chest and skull, ECG and echocardiogram. Lumbar puncture yielded clear cerebrospinal fluid (CSF) with a protein content of 1.9 g/l. It contained  $23 \times 10^6$  lymphocytes/l, but no organisms were seen on Gram and Ziehl-Nielsen stains. The serum and CSF VDRL was positive at titres of 1:160 and 1:80, respectively. Serum fluorescent treponemal antibody—absorption (FTA-Abs) test using Bio Merieux kit with serum diluted in sorbent in serial dilution was positive at 1:320. The first EEG recording obtained on the second day of admission showed generalised slow wave complexes having a duration of 400-500 ms and an amplitude of 50-150  $\mu$ V (fig. (A)). They occurred in a periodic fashion at the intervals varying between 1.6 and 2.2 seconds. The discharges were larger in the left temporal region, where they appeared to have the earliest origin, and were least evident in the right temporal region. This implied that they are a variant of periodic lateralised epileptiform discharges (PLEDs). The background activity between the periodic transients showed 4-5 Hz slowing and burst suppression. The EEG repeated three days later still demonstrated the periodic discharges, but at a reduced amplitude. The last EEG recorded on 7 February 1984 did not show the

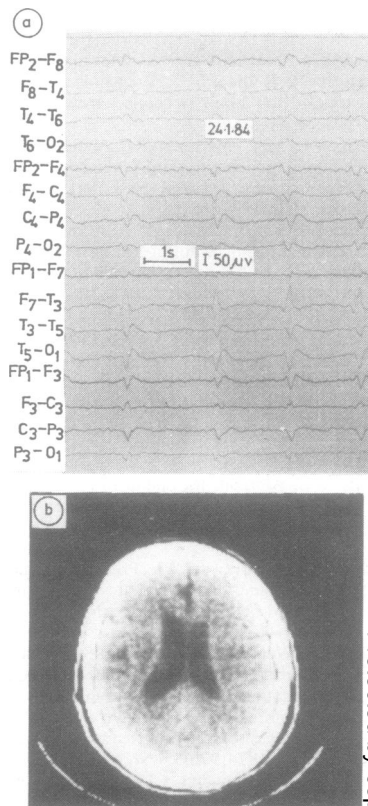


Fig (A) EEG shows left temporal dominant periodic slow wave discharges. (B) CT scan demonstrates ventricular enlargement and left parietal low-density lesion.

periodic activity. It disclosed alpha rhythm in the background and 6-7 Hz slowing and suppressed voltage over the parietal temporal region of the left hemisphere. A CT scan done on 2 February 1984 showed an area of decreased density involving left parietal cortex and slight ventricular dilatation (fig. (B)). The lesion exhibited no enhancement with contrast.

A diagnosis of meningovascular syphilis was made and the patient was treated with high doses of penicillin administered parenterally starting from the fourth day of admission. The patient's progress was satisfactory. He became conscious within a week; however, he remained apathetic and his mentation was slow. During the next two weeks his conversational speech became fluent but empty, with almost no substantive words. Language comprehension was limited to following elementary