

stem origin. A case is presented of acute onset of opsoclonus-myoclonus following the intranasal usage of cocaine.

A 26 year old woman was admitted for uncontrollable shaking of her entire body, associated with nausea, vomiting, and an inability to keep her eyes still. The symptoms began when she awoke after having "snorted" cocaine late the previous night. The cocaine was the first from its batch and was provided by her usual supplier. It was not known whether the batch was adulterated, but it was established that the patient was the only person who reported an adverse reaction. There was no history of ingestion of alcohol, medications, or other drugs. The patient had never used intravenous drugs. Past medical history was notable only for a single seizure, associated with cocaine use, some eight years previously. Family history and review of systems were entirely negative. There was no fever, arthralgia, recent upper respiratory infection, focal weakness or weight loss. The patient was a college student, living with her parents, and had been "snorting" cocaine once a week for many years.

On examination, she was a young, thin, white woman in marked distress. She was unable to sit upright in bed without severe myoclonic jerking involving trunk and extremities. Her pulse was 110 and regular. Respirations were 20 per minute and not laboured. The blood pressure was 118/68 mm Hg and the oral temperature was 36.7°C. There were no rashes or petechiae. The general examination was normal except for ocular abnormalities and periodic myoclonic jerking. Neurological examination revealed that the patient was alert and fully oriented. The optic fundi were poorly visualised due to opsoclonus; visual fields were intact to confrontation. The pupils were equal and reactive to light and accommodation. Extraocular movements were full. Marked continuous opsoclonus was present; spontaneous conjugate jerking was observed in all directions, as well as in a clockwise rotatory direction. The remaining cranial nerves were normal, and there was no palatal myoclonus. Motor strength, tone, and sensory modalities were all normal. Deep tendon reflexes were 2+ and symmetrical. Plantar reflexes were flexor. There was severe myoclonus involving all extremities; titubation and prominent truncal ataxia were present. Myoclonus increased with arm movement, on finger to nose and finger to finger testing. The patient was unable to sit upright without assistance; efforts to do so elicited vertigo, nausea and, on one occasion, vomiting.

The patient was admitted to the neurology

unit and sedated with lorazepam. Attempts to control the myoclonus with valproic acid and clonazepam met with moderate success. CT, MRI brainstem auditory evoked potentials, electroencephalogram, cultures, serologies and the remainder of an extensive workup failed to yield a definite aetiology. The syndrome proved self-limiting over a period of four weeks. All medications were discontinued two weeks later. At follow up one year later, a careful neurological examination failed to yield any abnormalities. There have been no further episodes of opsoclonus or myoclonus and the patient reports excellent health.

Opsoclonus is defined as periodic, jerking, ataxic conjugate eye movements occurring in all planes and sometimes in a rotary fashion. It is usually part of a syndrome seen with myoclonus of the trunk and limbs along with cerebellar dysfunction. Opsoclonus-myoclonus has also been called "dancing eyes, dancing feet" and the syndrome of "lightning eyes", among other descriptive terms.

Despite reported clinico-pathological studies, there is no consistently found structural lesion in opsoclonus or opsoclonus-myoclonus. Opsoclonus is thought to occur when there is a loss of inhibitory control over the system that produces ocular saccades. The loci of control have been variously placed in the pontine paramedian reticular formation, cerebellum, superior colliculus, midbrain tegmentum, pretectal region of the rostral dorsal midbrain, thalami, and parts of the cerebral hemispheres.^{1,2} Thus, there are probably several sites in the CNS that, when disrupted structurally or functionally, can result in the clinical picture of opsoclonus-myoclonus.

The differential diagnosis of opsoclonus-myoclonus includes a wide variety of disorders. It has been associated with demyelinating disease, namely brainstem involvement in multiple sclerosis; structural lesions such as glioma; hydrocephalus in a child; trauma; degenerative diseases; metabolic disturbances such as hyperosmolar non-ketotic coma; and in vascular events such as thalamic haemorrhage, and vertebral-basilar insufficiency. Opsoclonus-myoclonus has been reported in a variety of encephalitides, both viral and bacterial. Classically, opsoclonus-myoclonus was seen as a paraneoplastic manifestation of neuroblastoma. It has also been reported as a paraneoplastic syndrome of a number of other malignancies.

Finally, a variety of drugs and toxins have been associated with the syndrome of opsoclonus-myoclonus. These include chloroquine poisoning, the combination of lithium and haloperidol lactate, amitriptyline hydro-

chloride, thallium, phenytoin, and toluene. Despite the long list, the exact pathogenesis of these insults, be it autoimmune, directly toxic or compressive, remains obscure.¹⁻⁵

To the best of our knowledge, this is the first reported case of opsoclonus-myoclonus in association with cocaine usage. The self-limiting nature of the syndrome in this case argues against a structural lesion or a paraneoplastic syndrome. It is tempting to postulate a direct toxic effect of cocaine, or a toxic effect of one of the many substances that are used to "cut" cocaine. Alternatively, one might postulate that the opsoclonus-myoclonus was the result of a mild encephalitis or an immune complex-mediated phenomenon. Extensive investigation failed to support any of these hypotheses.

In summary, cocaine usage should be added to the list of toxic substances thought to induce the syndrome of opsoclonus-myoclonus. This striking neurological finding has a long list of suggested aetiologies, while its pathogenesis remains elusive.

The author thanks Dr Harry Fang, for his guidance and encouragement in pursuing this subject, and Ms Sherry Trotter, for expert preparation of the manuscript.

DAVID SCHARR
Department of Neurology
LAC-USC Medical Center
1200 North State Street
Los Angeles, CA 90033

References

- Hunter S, Kooistra C. Neuropathologic findings in idiopathic opsoclonus and myoclonus: their similarity to those in paraneoplastic cerebellar cortical degeneration. *Clin Neuro Ophthalmol* 1986;6:236-41.
- Keane JR. Transient opsoclonus with thalamic hemorrhage. *Arch Neurol* 1980;37:423-4.
- Dropcho E, Payne R. Paraneoplastic opsoclonus-myoclonus: association with medullary thyroid carcinoma and review of the literature. *Arch Neurol* 1986;43:410-5.
- Case Records of the Massachusetts General Hospital (Case 9-1988). *N Engl J Med* 1988;318:563-70.
- Cogan DG. Opsoclonus, body tremulousness and benign encephalitis. *Arch Ophthalmol* 1968;79:345-51.

Autosomal dominant cerebellar ataxia with deafness, myoclonus and amyotrophy

Sir: Autosomal dominant cerebellar ataxia (ADCA) can be associated with ophthalmoplegia, optic atrophy, retinal degeneration, dementia, extrapyramidal signs, deafness, amyotrophy and bulbar signs.¹ Baraitser described a family with a syndrome

J Neurology 1989; 131: 1448-1449. Received October 10, 1988. Accepted for publication December 10, 1988. Downloaded from http://jnnp.bmj.com/ by guest on February 8, 2023 by

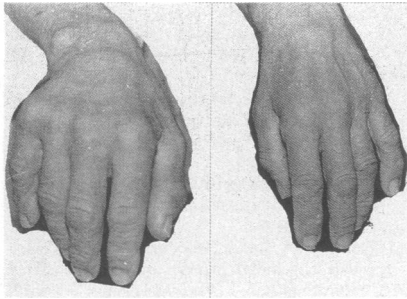


Fig 1 Atrophy of the interossei.

autosomal dominant late onset cerebellar ataxia with myoclonus, peripheral neuropathy and sensorineural deafness. Necropsy in one patient showed loss of cells in the dentate nuclei, a reduced amount of cerebellar white matter, and pallor of the gracile tracts in the spinal cord. We report another case with this syndrome.

A 56 year old male was referred to us with an intention tremor involving both arms. In his twenties he noticed bilateral hand tremor and decreased hearing in both ears. In his thirties he had bilateral deafness, increasing ataxia and tremor in both arms and an increasing gait imbalance. During the past three years he experienced jerking of his arm when engaged in purposeful movements and also progressive thinning of his legs and hands. One of his two daughters had pes cavus and one (maternal) uncle was deaf. His mother had pes cavus and tremor and his maternal grandmother had tremor and deafness. Positive findings on examination included bilateral deafness, mild dysarthria, marked ataxia, a slight postural and a marked intentional tremor and intention myoclonus in his arms. He had decreased reflexes in the upper limbs, abolished reflexes in the lower limbs, wasting of the interossei, thenar and hypothenar eminences and distal legs with pes cavus, slight distal loss of vibration sense in the lower limbs and a mild gait ataxia. Mental status, optic fundi and ocular movements were normal, and there was no nystagmus or pyramidal signs.

Normal laboratory values included cholesterol, tryglicerides, ceruloplasmin, lactate, pyruvate, lead (urine and serum), δ -aminolevulinic acid and hexosaminidase A. Audiometry confirmed bilateral severe hearing loss of more than 100db for both high and low tones (from 250 to 8000 HZ). EMG showed signs of chronic partial denervation and reinnervation, both on the upper and lower limbs, with reduction in the number of motor units and polyphasic, large, high-amplitude motor unit potentials. Motor nerve conduction velocity was reduced in

ulnar (31.7 m/s) and peroneal nerves 15.4 m/s). Sensory nerve conduction velocity was slowed on the ulnar (27.3 m/s). No sensory potential was obtained from stimulation of the sural nerve at the ankle. Visual evoked potentials were normal. Somatosensory evoked potentials showed delayed lumbar responses on tibial stimulation and delayed Erb's point potentials after stimulation of the median. Latencies between next potentials were normal. No high-amplitude cortical waves were recorded. The EEG showed a few paroxysms of spikes and sharp waves on both temporal leads. Simultaneous EMG recording demonstrated intention myoclonus, without any temporal relationships to the EEG paroxysms. CT showed mild atrophy of the cerebellar vermis. Skin biopsy was normal, with no PAS-positive inclusions on cells of eccrine sweat ducts. Muscle biopsy (deltoid) showed that the muscle was composed of type I fibres only. No ragged-red fibres were seen.

The following drugs were used to try to control tremor and myoclonus: biotin (15 mg/daily), piracetan (4800mg/daily), baclofen (45 mg/daily), propranolol (60 mg/daily) and isoniazid (900 mg/daily) had no effect. Lisuride 0.1 mg (IV) produced no improvement but caused nausea, vomiting and drowsiness. Valproate (1500 mg/daily) slightly improved the myoclonus and had minimal benefit on the tremor. Clonazepam (up to 10 mg) clearly reduced myoclonus, but produced intolerable sedation.

Classification of ADCA of late onset is controversial. Harding¹ grouped the ADCA on four types, based on clinical features only. Our patient fits the characteristics of ADCA type IV (with myoclonus and deafness). Furthermore he also had tremor, amyotrophy, absent tendon reflexes in the lower limbs and electrophysiological evidence of a sensori-motor polyneuropathy. ADCA type IV is rare. Only two families^{2,3} have, to our knowledge, been described. The family described by May and White³ had cerebellar ataxia, myoclonus and deafness, but no muscular atrophy or evidence of polyneuropathy. Like our patient, the family observed by Baraitser² presented with polyneuropathy and absent tendon reflexes in the lower limbs, but none of them had marked amyotrophy, a clinical feature not previously reported in ADCA type IV. As usually seen in other types of ADCA¹ in this family expressivity was variable, both on the severity and diversity of the clinical picture, ataxia, deafness and amyotrophy being either an isolated finding or combined with each other. Late onset ataxic disorders with additional features such as dementia, myoclonus, deafness or peripheral neuropathy

have been described in association with defects of the mitochondrial respiratory chain.⁴ Andermann *et al.*⁵ suggested that the hearing loss in the May-White syndrome indicated that this disorder is also due to mitochondrial dysfunction. Previous cases have not had muscle histology with the modified Gomori Trichrome method, or reveal ragged-red fibres, the morphological hallmark of mitochondrial myopathy.⁶

Mitochondrial diseases can be transmitted by either mendelian or maternal inheritance, and usually show a wide variability in the phenotypes of affected individuals,⁶ as in this family. However the pedigree is incompatible with maternal inheritance, as the daughter of the proband was also affected. Furthermore our patient had no ragged red fibres on muscle biopsy and his serum pyruvate and lactate levels were normal.

TERESA P MELO,

JOSÉ M FERRO

Department of Neurology,
Hospital de Santa Maria,
Lisbon, Portugal.

We thank Drs M Alves, R Serrão, F Morgado and Dr Baraitser for their help with this study.

References

- 1 Harding AE. Autosomal dominant cerebellar ataxia of late onset. In: *The Hereditary Ataxias and Related Disorders* 1984:129-65.
- 2 Baraitser M, Goody W, Halliday AM, Harding AE, Rudge P, Scaravilli F. Autosomal dominant late onset cerebellar ataxia with myoclonus, peripheral neuropathy and sensorineural deafness: a clinicopathological report. *J Neurol Neurosurg Psychiatry* 1984; **47**:21-5.
- 3 May DL, White H. Familial myoclonus, cerebellar ataxia, and deafness. *Arch Neurol* 1968; **19**:331-8.
- 4 Petty RKH, Harding AE, Morgan-Hughes JA. The clinical features of mitochondrial myopathy. *Brain* 1986; **109**:915-38.
- 5 Andermann F, Berkovic S, Carpenter S, Andermann E. 2. The Ramsay Hunt syndrome is no longer a useful diagnostic category. *Movement Disorders* 1989; **4**:13-7.
- 6 Zeviani M, Bonilla E, De Vivo D, Di Mauro S. Mitochondrial diseases. *Neurol Clin* 1989; **7**:123-56.

Persistent primitive trigeminal artery: a possible cause of trigeminal and abducens nerve palsy

Sir: The persistence of a primitive trigeminal artery (PTA) is usually found coincidentally on angiography. Several authors have documented its possible association with