

# LETTERS TO THE EDITOR

## Numb chin syndrome in the elderly

The numb chin syndrome is due to an isolated mental nerve palsy. Since the earliest description by Charles Bell in 1830, the condition has been described in association with a number of conditions including tumour of the jaw, trauma and drug toxicity.<sup>1,2</sup> The following cases differ from those previously reported.

A 73 year old woman (case 1) noticed numbness in the chin for three months. Hypoaesthesia was detected in the area shown in fig 1. Neurologically she had no other abnormality. Skull radiographs showed that her mandible was considerably atrophic and edentulous. She had a gastric ulcer, but extensive studies for malignancy were negative. Details of the case have been described elsewhere.<sup>3</sup>

An 81 year old man (case 2) had been treated for Parkinson's disease. Sensation on the chin was examined and was found to be decreased bilaterally on the lower lip and chin. The patient had no teeth and the mandible was atrophic. When the mental nerve was pressed with a fingertip at the outlet of the mental foramen, he experienced pain in the area supplied by the nerve.

A 69 year old woman (case 3) presented with left-sided facial spasm. Neurological examination revealed no abnormalities except for occasional twitching of the left eyelid and bilateral numbness of the chin. Skull radiographs revealed an atrophic edentulous mandible.

The salient findings common to all three cases is the markedly atrophic mandible. In 1806 Charles Bell, in his "Essays on the anatomy of expression in painting",<sup>4</sup> described the characteristic facial features of

elderly people as due to the lack of teeth and of that part of the jawbone which supports them. Fig 2 is taken from his monograph,<sup>4</sup> and clearly illustrates the markedly atrophic mandible in the elderly. It is worth emphasising that the site of the mental foramen is changed as the bone becomes atrophic. In the markedly atrophic mandible, pressure around the outlet of the foramen causes pain.

I consider an atrophic mandible to be one of the causes of the numb chin syndrome in the elderly. Mild numbness in the chin causes no difficulty in daily life and the patient is usually symptomless. However, if elderly people are carefully examined, numb chin syndrome is not rare and often not due to serious illness but to the natural ageing process.

TETSUO FURUKAWA

Department of Neurology, Faculty of Medicine, Tokyo Medical and Dental University, Yushima, Bunkyo-ku, Tokyo 113, Japan

- 1 Furukawa T. Charles Bell's description of numb chin syndrome. *Neurology* 1988;38:331.
- 2 Bell C. *The nervous system of the human body*. London: Longman, 1830.
- 3 Karasawa H, Kin H, Furukawa T. Numb chin syndrome. *Neurol Med (Tokyo)* 1986;25:1-3.
- 4 Bell C. *Essays on the anatomy of expression in painting*. London: Longman, 1806.

## Methylprednisolone therapy in tropical spastic paraparesis

Tropical spastic paraparesis (TSP) is associated with high titres of HTLV-1 antibodies in serum and CSF, and oligoclonal bands of IgG or IgM in the CSF, specific for HTLV-1.<sup>1-3</sup> The pathogenesis of TSP is uncertain. Local immunoglobulin production and perivascular inflammatory exudate is consistent with an immune mechanism. Oral prednisolone was reported to be beneficial in four of six patients with HTLV-1 associated

myelopathy.<sup>4</sup> We report the effects of treating nine patients with TSP, all of whom had HTLV-1 antibodies in serum and CSF, and evidence of HTLV-1 infection of peripheral blood leucocytes from polymerase chain reactions, with a five day course of 500 mg intravenous methylprednisolone (table 1).

The results are summarised in table 2. Pain and paraesthesiae in the back and legs were prominent in seven patients. In four patients, these symptoms improved for between three weeks and four months; there was no change in three. Spasticity was marked in eight patients and three improved: one improved for one week, one for six weeks and one remained improved at eight months. All nine patients had pyramidal weakness in the legs; four improved for one to six weeks, and in one the improvement appeared to be continuing at eight months, four did not improve. All nine suffered urgency and incontinence of micturition, and five had sensory loss in the legs. These symptoms did not improve in any patient. In three patients, there was no improvement in any symptom. There were no complications. In seven patients HTLV-1 antibody titres were measured in serum and CSF before and immediately after giving methylprednisolone, and in all nine patients the repeated estimation of serum titres for up to one year did not reveal any significant changes.

In conclusion, a five day course of methylprednisolone did not have any sustained benefit in nine patients with TSP, apart from one patient in whom tone and power remained improved at eight months. Three patients showed no benefit and in the remainder, improvement was only transient. Further, as the study was not blinded, positive placebo effects may have contributed to the apparent short term benefits. The utility of methylprednisolone in TSP appears to be limited.

JOHN DUNCAN

PETER RUDGE

National Hospital for Nervous Diseases, Queen Square, London WC1N 3BG, United Kingdom

Correspondence to: Dr J. Duncan.

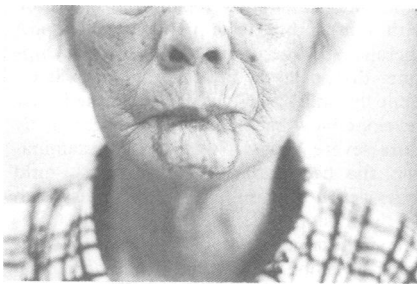

Figure 1 Case 1: Hypoaesthesia is present on the lower lip and chin as shown.

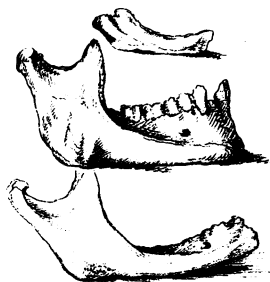

Figure 2 Mandibles of infant (top), adult (middle) and elderly person (bottom) by Charles Bell.<sup>4</sup>

Table 1 Clinical features

No	Age, sex	Duration (year)	Sphincter dysfunction	Pain and Paraesthesiae	Spasticity	Pyramidal weakness	Sensory loss*
1	65f	11	+	+	+	+	-
2	39m	2	+	+	+	+	+
3	51f	1	+	-	+	+	-
4	60m	0.5	+	+	+	+	+
5	50f	7	+	+	+	+	+
6	60f	18	+	+	+	+	-
7	56f	11	+	+	+	+	+
8	54f	18	+	-	+	+	+
9	55f	18	+	+	-	+	+

\*Impaired proprioception and vibration in legs (and impaired pinprick sensation in 1). + = Present - = Absent.

Table 2 Effect of methylprednisolone and duration of benefit

No	Sphincter dysfunction	Pain and Paraesthesiae	Spasticity	Pyramidal weakness	Sensory loss*
1	-	+	+	+	NA
2	-	-	-	-	-
3	-	NA	-	-	NA
4	-	+	+	+	-
5	-	+	-	-	-
6	-	+	-	+	NA
7	-	-	+	+	NA
8	-	NA	NA	-	-
9	-	-	NA	+	-

NA = Not applicable. - = No effect. + = Beneficial effect (duration).

- 1 Newton M, Cruickshank K, Miller D, *et al.* Antibody to Human T-lymphotropic virus Type 1 in West-Indian-born UK residents with spastic paraparesis. *Lancet* 1987;i:415-6.
- 2 Dalgleish A, Richardson J, Matutes E, *et al.* HTLV-1 infection in tropical spastic paraparesis: lymphocyte culture and serologic response. *AIDS research and human retroviruses* 1988;4:475-85.
- 3 Cruickshank JK, Rudge P, Dalgleish AG, *et al.* Tropical spastic paraparesis and human T cell lymphotropic virus type 1 in the United Kingdom. *Brain* 1989;112:1057-90.
- 4 Osame M, Matsumoto M, Usoko K, *et al.* Chronic progressive myelopathy associated with elevated antibodies to human T-lymphotropic virus type 1 and adult T-cell leukemia-like cells. *Ann Neurol* 1987;21:17-22.

### Trunkal myoclonus with spontaneous priapism and seminal ejaculation in Wilson's disease

We wish to record an uncommon clinical phenomenon seen in a patient with Wilson's disease which to our knowledge has not been previously reported.

A 25 year old unmarried male was admitted in December 1988 for the treatment of tremor and frequent jerkings of the body. He became symptomatic at the age of 14 years with postural tremor of the right hand. Frequent myoclonic jerks of the trunk appeared at the age of 20 years. During the past two years, he experienced priapism with seminal ejaculation up to three and four times per day, associated with some of the myoclonic episodes of the trunk. There were no other symptoms.

Examination revealed bilateral Kayser-Fleischer rings with postural tremors of the upper limbs, myoclonic jerkings of the limbs and trunk and a dystonic gait. No long tract signs were seen and no abnormality was detected in any other system. Examination of the genitalia did not reveal any abnormality.

The diagnosis of Wilson's disease was established by the bilateral Kayser-Fleischer rings and the low serum ceruloplasmin. The ejaculate during priapism was confirmed to be semen by the detection of spermatozoa. The patient was put on d-penicillamine which caused almost total amelioration of his symptoms over a period of six months.

K RAJASEKHARAN NAIR  
P GOPALA PILLAI  
Department of Neurology,  
Medical College Hospital,  
Trivandrum - 695 011,  
India

### Increased amplitude of F-response in Lambert-Eaton myasthenic syndrome

Increased amplitude of the F response may be due to synchronisation of different motor units activated in this response, as in spasticity, or to reinnervated large amplitude single motor units, as in neurogenic disorders.<sup>1</sup> We describe one case of Lambert-Eaton myasthenic syndrome (LEMS) with F amplitude exceeding M amplitude.

A patient with a recurrence of bronchial neoplasia after surgery was admitted to our unit because of diffuse weakness which he had experienced for some weeks. Muscle weakness without amyotrophy was evident in

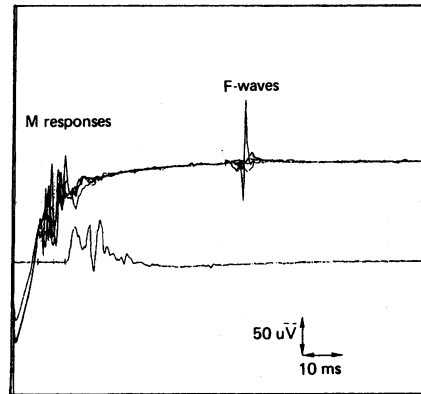


Figure Recording: extensor digitorum brevis. Upper traces: 4 selected traces; stimulation of peroneal nerve at the ankle. Lower trace: stimulation at the peroneal head.

the arms and legs. Facial and ocular motricity were normal and the Babinski sign absent. Sensation was not impaired. Needle electromyography (tibialis anterior, rectus femoris) was performed with concentric needle electrodes. No fibrillations were seen but trigger and delay-line techniques showed fluctuation of amplitude and morphology of individual motor units. Conduction velocities were normal for the sural nerve (47 m/s-15  $\mu$ V) and the peroneal motor conduction velocity was also normal (62 m/s). However, compound muscle action potential amplitude (CMAP) was reduced (100  $\mu$ V) and morphology fluctuated from one stimuli to another in spite of supramaximal stimuli. F waves were recorded at the extensor digitorum brevis by subcutaneous needle electrodes by stimulating the peroneal nerve at the ankle. Stimulation rate was 2/s and more than 20F responses were recorded. Most of them had an amplitude up to 25  $\mu$ V and some were greater than M amplitude (135  $\mu$ V). Minimal F latency was normal for the height (50.9 ms). Repeated stimulation (20 Hz) of the median nerve at the wrist, with recording at the abductor pollicis brevis, was consistent with the diagnosis of LEMS (increment: 532%).

F waves are produced by centrifugal discharges from motoneurons initiated by artificially produced antidromic impulses in the axon by electric stimulation. F-waves studies have proved to be useful in detecting peripheral neuropathies, especially proximal lesions.<sup>1</sup> Some parameters of F waves were studied, including F maximal amplitude, often expressed in per cent of M response (F%). In normal subjects, F is usually lower than 5%.<sup>2,3</sup> Significant increase in the percentage of F response exists in neuropathies of various origin. In chronic spasticity, F amplitude is said to be larger<sup>1</sup> but some studies showed that there was no significant variation but an increased occurrence of F responses.<sup>3</sup>

Nevertheless, in all these cases, F amplitude never exceeded the value of M response, the latter representing the electrical activity of all motor units, the former only part of them. LEMS is a condition in which antibodies directed against calcium channels in the presynaptic nerve terminal membrane are responsive for a decrease in ACh release. At low rates of stimulation, CMAP is reduced in amplitude and shows a decrement in successive responses. At higher rates, usually above 20 Hz, the response becomes strongly in-

cremental.<sup>4</sup> In our patient the interval between the direct stimulation (at the ankle for the peroneal nerve) and the reactivation by the F response was between 45 and 31 ms, estimated by the interval between M and F responses. These intervals correspond to shocks delivered at a frequency between 22 and 32 Hz, which corresponded to the facilitating rate and thus explains the unusually high amplitude of F response.

MARC HENRIET  
JEAN JACQUY  
Service de Neurologie,  
Hôpital Civil de Charleroi,  
Bd P Jansen  
6000 Charleroi,  
Belgium

- 1 Shahani BT, Summer AJ. Electrophysiological studies in peripheral neuropathy: early detection and monitoring. In: Stalberg E, Young RY, eds. *Clinical Neurophysiology*. London: Butterworths, 1981:117-44.
- 2 Shahani BT, Potts F, Dominigue JN. F response studies in peripheral neuropathies. *Neurology* 1980;30:409.
- 3 Eisen A, Odusote K. Amplitude of the F wave: a potential means of documenting spasticity. *Neurology* 1979;29:1306-8.
- 4 Stalberg E, Sanders DB. Electrophysiological tests of neuromuscular transmission. In: Stalberg E, Young RY, eds. *Clinical Neurophysiology*. London: Butterworths, 1981: 88-116.

### Subarachnoid haemorrhage related to a lumbosacral fusion: a case report

Subarachnoid haemorrhage is a common disorder which is usually caused by the rupture of an aneurysm or arteriovenous malformation. We report an unusual case where the subarachnoid haemorrhage was caused by bleeding into a lumbar pseudomeningocele which developed after lumbosacral fusion.

A 43 year old woman had an L5/S1 discectomy and fusion with a stainless steel (Hartshill) rectangle two years previously. This was complicated by a small dural tear which was apparently repaired at operation with one suture. She made a good post operative recovery and her previous symptoms disappeared. Fourteen months later, while flyfishing, she twisted and immediately developed low back pain and a progressively more severe bilateral sciatica. On examination she had marked neck stiffness, mild pyrexia and bilateral extensor plantars with no other signs. Cerebrospinal fluid (CSF) obtained at lumbar puncture for myelography was blood stained and xanthochromic. Her clotting screen and cranial CT scan were normal. The first myelogram which was done at the referring hospital showed only a hint of a lumbosacral pseudomeningocele. The examination, however, was incomplete. A second myelogram a week later showed a more readily filling lumbosacral pseudomeningocele closely related to the Hartshill rectangle. There was a filling defect on the left side in the pseudomeningocele due to a clot (fig 1b). There were no other abnormalities.

The symptoms persisted for three weeks and the patient had surgical exploration. The cavity of the pseudomeningocele was opened and found to be filled with a blood clot on the left and heavily bloodstained CSF. The anchoring wires of the Hartshill rectangle were engaged into the posterior wall of the