

MATTERS ARISING

Meningioma mimicking fibrous dysplasia of the skull

Dr Frankel *et al*¹ give an interesting account of what is clearly a very unusual and instructive case. We note, however, the absence of histological proof of fibrous dysplasia. Despite very persuasive clinical and radiological evidence, we must emphasise that histological examination is crucial in establishing the validity of any association between fibrous dysplasia and the development of a meningioma. Meningiomatous infiltration of bone, without soft tissue extension, may closely simulate the typical radiological appearances of fibrous dysplasia.² A recent case of ours, showing some similarities to that of Frankel *et al*, illustrates this important point.

A 46 year old woman was admitted in June 1987 with increasing proptosis and pain in the left orbit. Four years previously she had undergone a frontal craniotomy and left optic nerve decompression in another hospital. At that time her complaint had been an 18 month history of left orbital pain and progressive blindness. She also had a very long history, extending over more than 20 years, of temporomandibular joint dysfunction. On examination there was decreased sensation to light touch and pinprick over the left side of the face associated with proptosis. There was no vision in the left eye and fundal examination showed optic atrophy. She was otherwise well. Skull radiographs and CT scan of the

head showed evidence of previous surgery to the postero-lateral wall of the left orbit and region of the optic foramen. There was thickening of the medial end of the left sphenoid bone and part of the postero-lateral wall of the left orbit (fig, inset). Features were regarded by both surgeons and radiologists as typical of fibrous dysplasia. Routine serum biochemistry, and in particular serum calcium and alkaline phosphatase levels, were normal.

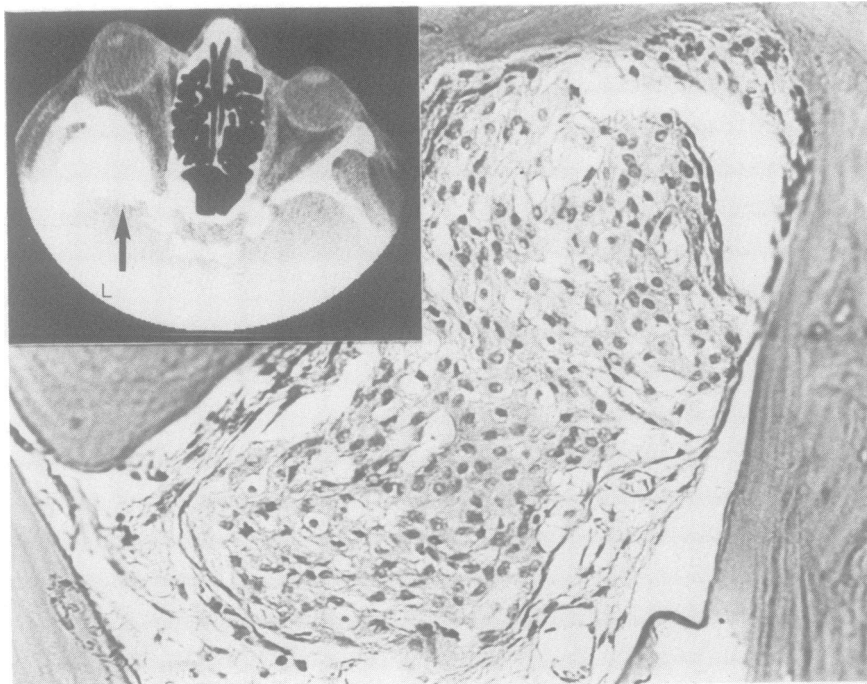
The patient had a further frontal craniotomy and abnormal bone was removed from the left sphenoid and orbit. The side wall of the orbit was repaired using a rib graft. No soft tissue mass was identified. The bone was sent for histological examination. Tissue sections showed no evidence of fibrous dysplasia. Trabeculae were composed of dense, sclerotic but otherwise normal, lamellar bone. The intervening spaces contained infiltrating islands of transitional meningioma (fig).

Meningioma infiltrating bone without any associated soft tissue mass is a rare but recognised phenomenon.³ It is clear from our case that such a tumour associated with hyperostosis may closely mimic the clinical and radiological features of fibrous dysplasia. We suggest therefore that claims of a causal link between fibrous dysplasia and the subsequent development of meningioma cannot be proved without histological evidence of the former condition.

AP BOON
MP CAREY
A HOCKLEY

Department of Pathology,
University of Birmingham,
The Medical School, Birmingham

- 1 Frankel J, Ianotti F, Powell M, Schon F. Meningioma—an unrecognised complication of fibrous dysplasia of the skull? *J Neurol Neurosurg Psychiatry* 1989;52:546-7.
- 2 Burger PC, Vogel FR. *Surgical pathology of the nervous system and its coverings*. New York: John Wiley and Sons, 1982:15.
- 3 Wagman AD, Weiss EK, Riggs HE. Hyperplasia of the skull associated with intrasosseous meningioma in the absence of gross tumour. *J Neuropathol Exp Neurol* 1960; 19:111-5.



Island of transitional meningioma within sclerotic bone. Inset shows CT scan of skull (abnormality arrowed).

Disappearing CT lesions in Indian patients with epilepsy

We read with interest the article by Ahuja *et al* on "disappearing" CT lesions in Indian patients with epilepsy.¹ We agree with their conclusion that tuberculosis is rarely, if ever, the cause of these lesions. We are, however, convinced that in nearly all cases cysticercosis is the causative pathology. We are discussing lesions which are single, rounded, less than 10 mm in size, enhancing with contrast in patients with seizures.

In our study of 15 consecutive patients in whom lesions were excised, cysticercosis was the definite diagnosis in seven, and a parasitic granuloma was diagnosed in five patients.² In the other three patients also there was inflammation, calcification and gliosis in the biopsy specimens which could be the result of a resolving parasitic granuloma. Since the end of this study we have stopped routine excision of these lesions as they are self-limiting and benign. In isolated cases (10) where excision was carried out because of persistence of the lesion, cysticercosis was the only pathology identified.

We presume that the authors speculated on a hypothetical "micro" lesion of unknown aetiology as the cause of some of the lesions, because of the inability to detect cysticercus antibodies in two-thirds of their patients. It is well known that serological tests do not identify all patients with cysticercosis and negative tests are more common in patients with benign forms of the disease.³ Negative tests have been reported even with more sensitive serological tests such as the immunoblot assay.⁴

We also do not agree with the authors' contention that enhancement of the lesion is related to the seizure. In all except one patient in our study, CT scans were carried out more than two weeks after a seizure and all of them had enhancing lesions. The nature of the lesion on the CT scan and its enhancement depend on the stage of natural evolution of the parasite. The phenomenon of disappearance and reappearance of the lesion at the same site is intriguing. We have never seen such an event and one possibility to consider is that lesions can be missed if the CT scan slices in the region of interest are not thin (2-4 mm).

VEDANTAM RAJSHEKHAR
JACOB ABRAHAM
Department of Neurological Sciences,
Christian Medical College and Hospital,
Vellore 632004, India

- 1 Ahuja GK, Behari M, Prasad K. Disappearing CT lesions in epilepsy: is tuberculosis or cysticercosis the cause? *J Neurol Neurosurg Psychiatry* 1989;52:915-6.
- 2 Chandy MJ, Rajshekhar V, Prakash S, *et al*. Cysticercosis causing single small CT lesions in Indian patients with seizures. *Lancet* 1989;i:390-1.
- 3 Rosas N, Sotelo J, Nieto D. ELISA in the diagnosis of neurocysticercosis. *Arch Neurol* 1986;43:353-6.
- 4 Rawlings D, Ferrero DM, Messing RD. Early CT reevaluation after empiric praziquantel therapy in neurocysticercosis. *Neurology* 1989;39:739-41.

Dr Ahuja *et al* reply:

We thank Drs Rajshekhar and Abraham for their comments. There is little doubt that we are talking of similar lesions.^{1,2} Being aware of the natural history of the CT lesions we considered excision biopsy of cerebral lesion unethical and followed a different strategy to