

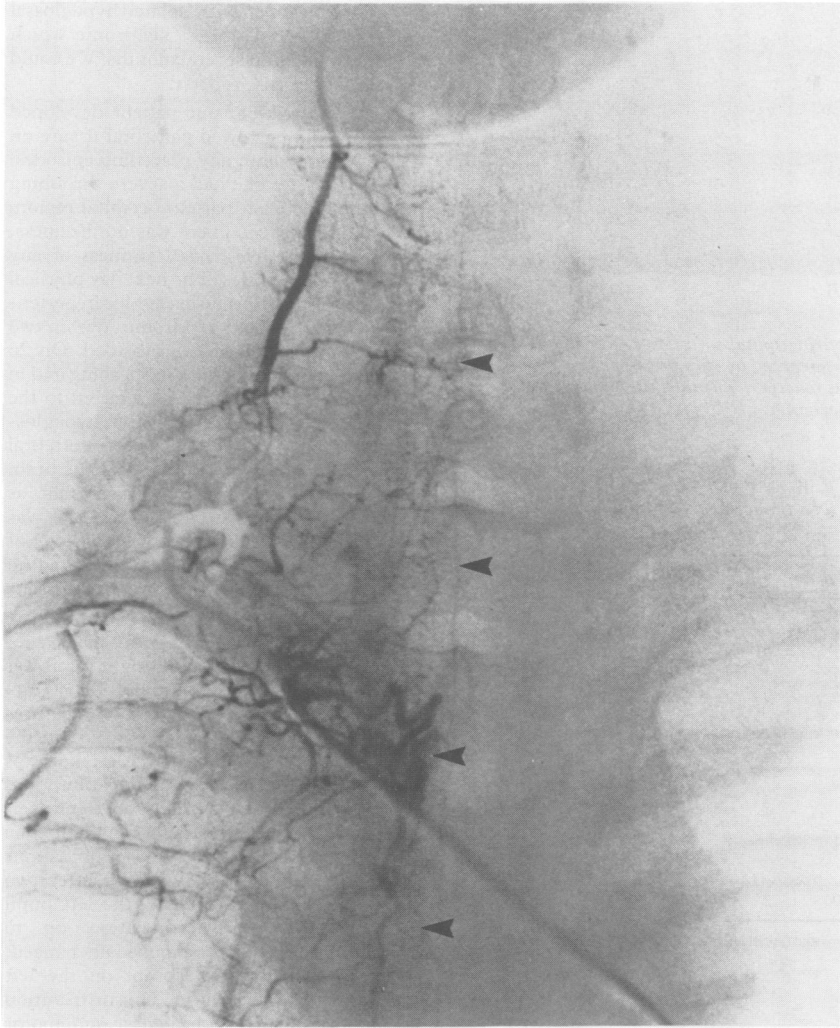Figure 2 Right thyrocervical and costocervical trunk angiograms showing the anterior spinal artery (arrowheads), from the ascending cervical artery, to the T-4 level without any intradural vascular malformation.

Recently Lobato *et al*³ reported cases of angiographically occult intracranial vascular malformations and proposed several reasons why angiographic identification had not been possible. Their conclusions can also be applied to angiographically occult spinal vascular malformations. In our case the AVM was less than 5 mm in size and was located at the boundary of the territory between the two anterior spinal arteries, one from the deep cervical artery and the other from the Adam-Kiewicz's artery. We believe that its small size and location at the boundary of the anterior spinal artery territories are the most likely reasons why it was not recognised by angiography.

Smaller intracranial AVMs have a higher risk of haemorrhage,¹ and we wonder if this can also be applied to spinal AVM lesions. Koos has suggested that a microangioma may be present in cases of haematomyelia in the absence of large spinal AVM.² We suggest that bleeding due to a spinal AVM should be considered, even when angiography is negative.

TATSUYA ISHIKAWA
KOUHEI ECHIZENYA
HIROSHI MURAI
MASAHARU SATOH
Department of Neurosurgery,
Municipal Second Hospital,
Otaru,
Hokkaido, Japan

Correspondence to: Dr Ishikawa, Department of Surgical Neurology, Research Institute for Brain

and Blood Vessels-Akita, 6-10, Senshu-Kubotamachi, Akita 010, Japan.

- 1 Forster DMC, Steiner L, Hakanson S. Arteriovenous malformation of the brain. A long-term clinical study. *J Neurosurg* 1972;32:562-70.
- 2 Koos WT, Bock F. Spontaneous multiple intramedullary hemorrhages. *J Neurosurg* 1970;32:581-4.
- 3 Lobato RD, Pertz C, Rivas JJ, Cordobes FC. Clinical, radiological, and pathological spectrum of angiographically occult intracranial vascular malformation. Analysis of 21 cases and review of the literature. *J Neurosurg* 1988;68:581-3.
- 4 McCormick PC, Michelsen WJ, Post KD, Carmel PW, Stein BM. Cavernous malformations of the spinal cord. *Neurosurgery* 1988;23:459-63.
- 5 Veerapen RJ, Sbeih IA, O'Laoire SA. Surgical treatment of cryptic AVM's and associated hematoma in the brain stem and spinal cord. *J Neurosurg* 1986;65:188-93.

Extraneural metastases from brainstem astrocytoma through ventriculo-peritoneal shunt

In 1954 Wolf *et al*¹ reported a case of a 14 year old female with a thalamic glioblastoma who needed a ventriculo-pleural shunt to relieve hydrocephalus. She died 8.5 months after shunt placement, and at necropsy tumoural cells were found in the pleural cavity. There have been at least 43 other cases of CNS

primary tumours that have metastasised through shunts used in the treatment of hydrocephalus. We report the case of a patient who had a brainstem astrocytoma with extraneural metastases through a ventriculo-peritoneal shunt (VPS) with development of ascites, and spinal cord seeding.

A four year old girl, previously in good health was admitted to hospital on 27 December, 1985 with a clinical picture of continuous and intense occipital headache, dizziness and vomiting. Her past medical history was normal. Positive neurological findings included vertical nystagmus in upward gaze and horizontal nystagmus in right gaze; palsy of the VI, VII and IX left cranial nerves; right crural paresis with hypertonia, hyperreflexia and Babinski sign; right limb dysmetria and ataxic gait. A brain CT revealed a left pontomesencephalic hypodense area extending to the left cerebellar peduncle with an irregular enhancing after injection of contrast material. The fourth ventricle appeared displaced backwards with a mild compression in its floor. There was also a moderate supratentorial hydrocephalus. The patient improved considerably after treatment with dexametasone and radiotherapy. Five months after diagnosis she was again admitted because of bilateral action tremor, dysmetria and ataxic gait. A month later she experienced headache and vomiting, and was found to have bilateral papilloedema in addition to the previous neurological signs.

A second brain CT showed a prominent obstructive hydrocephalus. A VPS was implanted and the patient's symptoms rapidly improved. Ten months after diagnosis she complained of a sudden intense back pain and developed a progressive ascending hypotonic quadriplegia with arreflexia and bilateral Babinski sign. Sensory loss and sphincter dysfunction were not present. A new CT showed brainstem widening and cystic lesions in the left pontocerebellar angle, retrocerebellar region and right medial temporal lobe, that were interpreted as necrotic cysts secondary to radiotherapy. Eleven months after diagnosis, and five months after VPS placement she presented with abdominal distension caused by ascites.

An abdominal ultrasound failed to show masses or encapsulated collections. On 7 November, 1986 the abdominal catheter was removed, but the ascites followed a progressive course. Two cerebrospinal fluid (CSF) specimens showed moderate rise in protein content, but all CSF cytologies were negative. Ascitic fluid had normal biochemical parameters and negative cytology. Because of the poor condition of the patient we decided to avoid aggressive diagnostic and therapeutic manoeuvres. She died two weeks later.

Necropsy showed a white mass in the left pontomesencephalic region spreading to the cerebellar peduncles, septum, fourth ventricle walls and periventricular white matter. There was also involvement of the arachnoid of the cerebellum and the whole length of the spinal cord but with sparing of the spinal cord itself and the spinal nerve roots (fig A). Peritoneum was diffusely thickened, white in colour and nodular in appearance. Histological examination showed a diffuse astrocytic growth in the CNS but with sparing of the abdominal organs. Glial fibrillar astrocytic protein (GFAP) stain was strongly positive for samples of the tumour from brainstem,

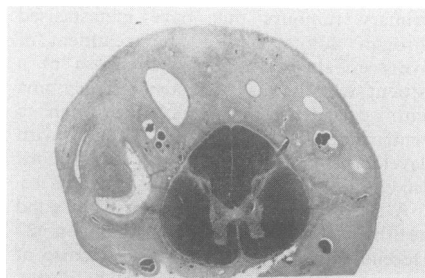


Fig A

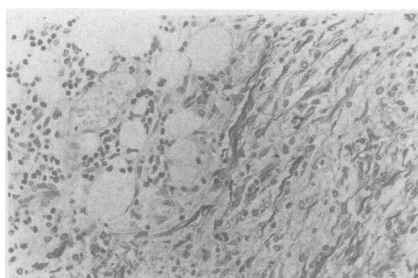


Fig B

Figure (A) Involvement of arachnoid of spinal cord sparing spinal cord tissue (Woelke). (B) Surface of peritoneum infiltrated by a tumour mass composed by spindle-shaped cells lying near the mesenteric adipose tissue. There is a fibrous reaction. The cells are positive for the PAP method for GFAP demonstrating their astrocytic origin.

Table Cases reported of extraneural metastases from CNS tumours through shunt systems. Histological and shunt system types

Primary tumour	VP	VA	VPL	LP	VV	Total
Medulloblastoma (1)	9	5		1	1	15
Germinoma	8	1				9
Glioblastoma (2)	4	1	2			6
Astrocytoma	1*	1	1			3
Astrocytoma-oligodendroglioma		1				1
Dysgerminoma	1					1
Optic nerve glioma	1					1
Gliomatosis cerebri				1		1
Ependymoma	1					1
Ependymoblastoma	1					1
Sarcoma	1					1
Pinealoblastoma	1					1
Chorinepithelioma		1				1
Atypical teratoma	1					1
Pineal unclassified tumour	1					1
Total	30	10	3	2	1	44

VP = ventriculoperitoneal; VA = ventriculoatrial; VPL = ventriculopleural; LP = lumboperitoneal; VV = ventriculo-venous.

(1) 1 patient had VP and VA shunts.

(2) 1 patient had VA and LP shunts.

*Case reported.

spinal cord and peritoneal metastases (fig B).

Extracranial metastases of CNS tumours are infrequent. In a recent review of the literature there was a total of 282 cases.² The placement of shunt systems to relieve hydrocephalus seems to be an important factor in metastasis, and some authors have proposed the systematic use of millipore filters in VPS to avoid tumour cells seeding through the shunt systems to the peritoneum.³ The table shows the histological origin and shunt type of previously reported CNS primary tumours with extraneural metastases through shunt systems. Medulloblastoma is the most frequent histological type reported while astrocytoma was reported in three previous cases.⁴⁻⁶ Nevertheless, our patient is the first to have metastases through VPS. Ascites as a complication of VPS is also infrequent. Our case is the tenth to be reported with metastatic ascites associated with VPS placement, and the first one due to astrocytoma. These features, together with the presence of spinal cord seeding, makes our case exceptional and to our knowledge not previously reported in the literature.

We thank Dr J A Villanueva Osorio and Dr A Roldán Montaud for their help with the English translation, and Professor J Escalona Zapata for the photograph of the GFAP stain of the peritoneum.

F J JIMÉNEZ-JIMÉNEZ
C GARZO-FERNÁNDEZ
J DE INOCENCIO-AROCENA
M PÉREZ-SOTELO

P CASTRO-DE CASTRO
E SALINERO-PANIAGUA
Departments of Neuropediatrics and Pathology,
Hospital General Gregorio Marañón, Madrid

Correspondence to: Dr Félix Javier Jiménez Jiménez, C/Corregidor José de Pasamonte 24, 3º D 28030 Madrid, Spain.

- 1 Wolf A, Cowen D, Stewart WB. Glioblastoma with extraneural metastases by way of a ventriculo-pleural anastomosis. *Trans Am Neurol Assoc* 1954;79:140-2.
- 2 Hoffman HJ, Duffner PK. Extraneural metastases of Central Nervous System tumors. *Cancer* 1985;56(1):778-82.
- 3 Hoffman HJ, Hendrick EB, Humphreys RP. Metastasis via ventriculo-peritoneal shunt in patients with medulloblastoma. *J Neurosurg* 1976;44:562-66.
- 4 Brust JCM, Moiel RH, Rosenberg RN. Glial tumor metastases through a ventriculo-pleural shunt. Resultant massive pleural effusion. *Arch Neurol* 1968;18:649-53.
- 5 Eade OE, Ulrich H. Metastasising gliomas in young subjects. *J Pathol* 1971;103:245-6.
- 6 Mosca L, Baldini M. Early glial tumor metastases through a ventriculo-atrial shunt. *Tumori* 1976;62:47-54.

Isolated hypoglossal nerve palsy and Horner's syndrome with benign course

The hypoglossal nerve may be affected by various diseases, sometimes together with other lower cranial nerves and sympathetic fibres as in Villaret's syndrome.¹ We describe

a 54 year old woman with isolated hypoglossal nerve palsy and Horner's syndrome which disappeared within several months. We could find no similar case reports.

On 23 May 1988, our patient developed tinnitus and a narrowed palpebral fissure on the left side without any preceding episodes. Two hours later she had a severe throbbing headache in the left parieto-occipital region, and vomited twice. There was no dizziness, watering of the eyes, nasal stiffness or any sensory abnormalities. The next day physical examination was normal except for hypertension and left Horner's syndrome. Within two days the severe headaches subsided. On 26 May, she noticed difficulty in speaking and in tongue movements, and was referred to the Department of Neurosurgery. Left hypoglossal angiograms, CT scan and MRI of the brain and upper cervical region were normal, as were the otological examinations. She was referred to the Department of Neurology of Tohoku University on 14 June. She had no personal or family history of recurrent headaches.

She had no lymphadenopathy or organomegaly. The diameter of the right pupil was 3.0 mm, and the left, 2.5 mm. Pupillary reactions were normal. The palpebral fissures were symmetric. The tongue curved to the right at rest in the mouth. Its left side was atonic with occasional fasciculation, and appeared larger than the right side. However, left-sided palsy was evident when the tongue was protruded (fig top). Other examinations were non-contributory. An hour after two drops of 1.25% epinephrine, the left pupil showed supersensitive dilatation up to 7.0 mm, while the right remained unchanged. Thermal sweating was absent on the left medial part of the forehead. This distribution of anhidrotic area indicated a sudomotor sympathetic lesion distal to the bifurcation of the common carotid artery.² Routine laboratory data and cerebrospinal fluid were normal. VDRL was negative. Serum antibody-titres against herpes simplex, varicella-zoster, Epstein-Barr (EB) and cytomegalovirus were examined on 14 and 28 June. IgG against cytomegalovirus was 1:11264 on both occasions. No significant increase or temporal changes in other antiviral titres were detected. Her symptoms regressed without specific treatment. On 11 July, the pupils were equal and no longer reacted to 1.25% epinephrine. The tongue was slightly atrophic on the left side, but its movements were normal (fig bottom). Carotid arteriography and jugular venography were not performed because of a spontaneous recovery. During the subsequent 19 months, she had no recurrence of headaches or any other neurological symptoms. Follow up CT and MRI were unremarkable. On the last examination in February 1990, the appearance and movements of the tongue were entirely normal.

Our patient had left hypoglossal nerve palsy and ipsilateral Horner's syndrome which was shown to be postganglionic by the supersensitivity to 1.25% epinephrine and anhidrosis over the left medial part of the forehead. The association suggests that the causative lesion must be in the left retroparotid space. Clinical and radiological examinations rule out mass lesions. Their acute onset with hemicrania, and subsequent regression suggest focal inflammation or vascular disorders. DeSimone and Snyder³ reported hypoglossal nerve palsy with good