

patient the lesion in the retro orbital portion of the right optic nerve was thought to be an inflammatory granuloma or glioma preoperatively but it proved to be cysticercosis. To our knowledge this has not been described previously.

V S MADAN
R M DHAMIJA
H S GILL
M S BOPARAI
P D SOUZA
P C SANCHETEE
J R BHARDWAJ
The Army Hospital, Delhi,
and the Lady Harding Medical College,
New Delhi, India

Correspondence to: Dr Madan, Department of Neurology, Sir Ganga Ram Hospital, Rajinder Nager, New Delhi-110060, India

- 1 Baranski MC. Teniasis. In: Chaia G, Ed. *Atlas of parasitology*. Sao Paulo: Johnson and Johnson Research Institute for Endemic Diseases, 1975:69-76.
- 2 Malik SRK, Gupta AK, Choudary S. Ocular cysticercosis. *Am J Ophthalmol* 1968;66:1166-71.
- 3 Mingnetti G, Ferreira MVC. Computed tomography in neurocysticercosis. *J Neurol Neurosurg Psychiatry* 1983;46:936-42.
- 4 Venkataraman S, Vijayan GP. Neurocysticercosis. In: Ahuja MMS, ed. *Progress in clinical medicine in India*, Series Four. New Delhi: Arnold Heinemann, 1981:382-406.
- 5 Kapoor S, Sood GC, Aurora AL, Sood M. Ocular cysticercosis, report of a free floating cysticercus in the anterior chamber. *Acta Ophthalmologica* 1977;55:927-30.

Vertebral haemangioma causing acute recurrent spinal cord compression

Vascular tumours are commonly seen in bone, particularly in vertebral bodies; they are, however, far less common in the epidural space. Most of these epidural tumours represent extension of vertebral lesions. Patients with epidural lesions usually present with slowly progressive symptoms of back pain or compression of the spinal cord. Our patient presented with neurological symptoms that developed with unusual rapidity and seemed to be recurrent. This clinical picture has not to our knowledge previously been described.

A 73 year old woman had difficulty in walking. Ten years earlier, the patient had had a gradual onset of stiffness in both legs. Results of neurological examination and radiography of the spine and chest were normal. A non-organic mechanism was considered. The symptoms improved over three months, and the patient remained asymptomatic for nine years.

Six months before the present examination, the patient experienced gradual unsteadiness of gait. Five days before this evaluation, she experienced mild difficulty lifting her right foot. On admission, she was unable to walk without assistance. Examination showed mild paraparesis. Exaggerated patellar reflexes and Babinski's signs were bilaterally present. Sensory examination disclosed a mild deficit to soft touch on the right leg below the knee.

Results of routine blood studies and CT of the head were normal. Radiography of the spine demonstrated severe compression at T6 and diffuse osteoporosis. Review of the findings on chest radiography obtained 10 years earlier revealed a compression at T6 that had not been observed originally; however, this status was unchanged (fig 1A).

On the day after admission, bilateral sensory impairment developed below the T6-7 level. Myelography demonstrated complete block at T6 (fig 1A). Total laminectomy at T4-6 demonstrated a highly vascular epidural tumour extending from the affected T6 vertebra, which was excised. Pathological evaluation revealed a cavernous haemangioma (fig 1B).

Sensation and strength returned to both legs, and six days after the operation, the patient walked with assistance. She recovered well at a rehabilitation hospital.

Vertebral haemangioma that does not involve the epidural space is a common, usually asymptomatic, lesion. In Töpfer's¹ series of 2154 patients, the incidence of vertebral haemangioma was 11.9%. In a series of more than 10 000 necropsies by Junghanns,² the incidence was 10%. Extension into the epidural space is uncommon. In a comprehensive study, Hurth³ estimated that 12% of all intraspinal haemangiomas involve the epidural space and suggested that these lesions are underdiagnosed. Most symptomatic epidural and vertebral haemangiomas involve the thoracic spine,⁴ possibly because the spinal canal is narrow at this level.

Rapid progression of symptoms associated with an epidural vascular lesion is a rare occurrence. Four pathophysiological mechanisms have been postulated^{5,6} that may lead to spinal cord compression: extension into the epidural space; expansion of the vertebrae, which causes narrowing of the spinal canal; epidural haemorrhage, possibly involving thrombosis; and compression fracture. We suggest that the most recent presentation in our patient fits the first or second category best because no new fracture was present and no acute bleeding or obvious thrombosis was found at operation.

We did not have the benefit of nuclear MRI at the time this patient was treated. Today, this procedure might well be the optimal method of imaging a lesion before operation. Some authors⁷ suggest that angiography be performed in less acute situations to permit embolisation of the lesion preoperatively.

Reports of neurological symptoms that developed as quickly as they did in our patient form a small minority of cases. We have not found a case previously described in which symptoms of subacute spinal cord compression developed and then resolved completely for 10 years, only to recur in an acute fashion as a result of an epidural haemangioma. Unsuspected epidural or vertebro-epidural vascular tumour, which may be recurrent, is a rare but treatable cause of acute spinal cord compression.

JONATHAN NEWMARK*
H ROYDEN JONES Jr
Department of Neurology
CHRISTINE B THOMAS
H THOMAS ARETZ
Department of Anatomic Pathology
STEPHEN R FREIBERG
Department of Neurosurgery
RICHARD A BAKER
Department of Diagnostic Radiology,
Lahey Clinic Medical Center,
Burlington, MA, USA

*Present address: Hospital of the University of Pennsylvania, Neuromuscular Division, 3 Gates Building West, 3400 Spruce Street, Philadelphia, PA 19104, USA.

Correspondence to: Dr Jones Jr, Department of Neurology, Lahey Clinic Medical Center, 41 Mall Road, Burlington, MA 01805, USA.

- 1 Töpfer D. Infiltrating hemangioma of skin and multiple capillary ectasias: angioma of vertebra. *Frankfurt Ztschr f Path* 1928;36:337-45.
- 2 Junghanns H. Hämangiome des 3. Brustwirbelkörpers mit Rückenmark-kompression. Laminektomie. Heilung. *Arch f klin Chir* 1932;169:321-30.
- 3 Hurth M. Les hémangioblastomes intrarachidiens. *Neurochirurgie* 1975;21(suppl 1):1-136. (Eng abstr.)
- 4 McAllister VL, Kendall BE, Bull JW. Symptomatic vertebral haemangiomas. *Brain* 1975;98:71-80.
- 5 Graham JJ, Yang WC. Vertebral hemangioma with compression fracture and paraparesis treated with preoperative embolization and vertebral resection. *Spine* 1984;9:97-101.
- 6 Padovani R, Tognetti F, Proietti D, et al. Extrathecal cavernous hemangioma. *Surg Neurol* 1982;18:463-5.

Giant intracranial aneurysm associated with Marfan's syndrome: a case report

We report a case of Marfan's syndrome presenting with the thromboembolic or mass effects of a giant basilar aneurysm: this was successfully clipped by direct exposure, an outcome we believe not previously described in Marfan's syndrome.

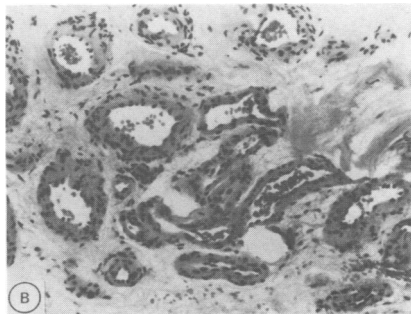
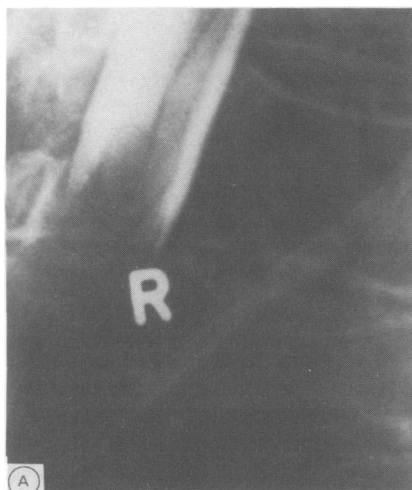


Figure 1A Lateral myelograph from above demonstrates total block at the level of the compressed T6 vertebra consistent with an epidural process; (B) section from the epidural component of the tumour shows large thick-walled vessels. Bone involvement was seen in other sections. (H&E; original magnification $\times 100$.)

A 22 year old white female was admitted to hospital following an unwitnessed coma producing event in which she developed a dense right sided weakness. During the preceding fortnight she had experienced severe intermittent headaches, worse in the mornings and associated with pain and stiffness in the back of the neck, and had suffered a single generalised fit with urinary incontinence.

Neurological examination disclosed an alert, orientated patient with marked neck stiffness, moderate dysarthria, an incomplete upper motor neuron lesion of the right seventh cranial nerve and a dense right spastic hemiplegia.

Computed tomography (CT) without contrast showed a moderately well-defined area of high density anterior to the pons and mid-brain with further attenuation in the left parasellar region, findings compatible with either localised subarachnoid haemorrhage or an aneurysm. Transfemoral cerebral angiography (figure) demonstrated a giant aneurysm 2.5 cm in length arising from the basilar trunk and displacing the trunk slightly to the right.

Although previously unrecognised, and lacking a family history, this patient displayed the classic external features of Marfan's syndrome. Furthermore, she had a chondrosteronoplasty for pectus excavatum at the age of ten, and had a metacarpal index of 9.2 which is within the range (8.4 to 10.4) for this syndrome.¹

Eighteen days after admission the aneurysm was explored through a combined right pterional and subtemporal approach, splitting the free edge of the tentorium. At this time there was no evidence of subarachnoid blood. After exposure of the basilar trunk and aneurysm and identification of midbrain perforating vessels, the neck of the aneurysm was controlled with two Sugitta clips.

Apart from a temporary incomplete right fourth nerve palsy her postoperative recovery was uneventful. Within two weeks she recommenced walking and four months later her only disability was a slight limp.

Several mechanisms may account for the pure motor hemiplegia in this patient: embolisation from the aneurysm causing a small

lacunar infarct in the cerebral peduncle;² mechanical distortion of midbrain perforating vessels; and vascular spasm following localised subarachnoid haemorrhage.

Marfan's syndrome is an uncommon though frequently unrecognised¹ disorder characterised biochemically by a deficiency of nonreducible cross-links in collagen.³ It is usually transmitted in autosomal dominant fashion with variable penetrance although up to 15% of cases arise sporadically. Cystic medial necrosis typically affects large arteries such as the aorta with the attendant risks of progressive aortic dilation, valvular incompetence, aneurysm formation and arterial dissection. Of four previously reported cases of large intracranial aneurysms in this condition⁴⁻⁷ three aneurysms were giant (>2.5 cm) whilst the size of the fourth was not recorded. Two of these cases appear to have been successfully treated. One giant intracranial internal carotid artery aneurysm⁵ was managed by internal carotid artery ligation with near fatal arterial dissection down to the aortic arch. The other, a giant intracavernous aneurysm,⁶ was managed with internal carotid artery ligation and superficial temporal to middle cerebral artery bypass, without mishap. We add a further case of a giant intracranial aneurysm occurring in association with Marfan's syndrome, which we believe to be the first reported in the basilar territory to be isolated and clipped.

Early reports of aortic surgery in this disorder considered reparative and reconstructive surgery to be contraindicated on account of the cystic medial necrosis. It has been suggested that the problems of treating giant intracranial aneurysms in patients with connective tissue disorders are compounded by the friability of the vessel wall.³ Given the possibly lower risk of spontaneous rupture of giant aneurysms and the basilar location of this aneurysm, a dilemma exists regarding intervention. In the light of this case we would suggest that coexistent Marfan's syndrome does not prevent surgical management governed by the usual clinical considerations.

PJ HAINSWORTH
AD MENDELOW

Department of Neurosurgery,
Newcastle General Hospital,
Westgate Road,
Newcastle upon Tyne NE4 6BE, UK

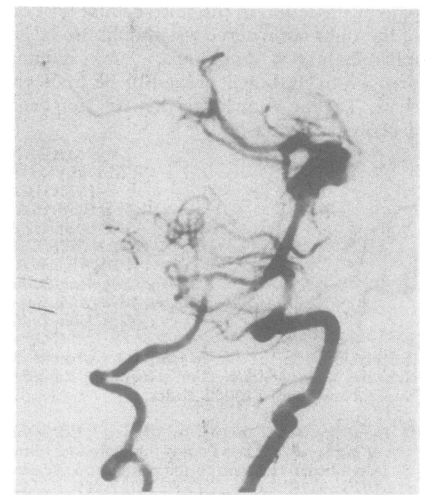

Figure Vertebral angiogram showing both vertebral arteries, the basilar artery, and the aneurysm arising from the basilar bifurcation.

Correspondence to: Mr Mendelow.

- 1 Sinclair RJG, Kitchin AH, Turner RWD. The Marfan Syndrome. *Quart J Med* 1960;29:19-46.
- 2 Fisher M, Smith TW, Jacobs R. Pure motor hemiplegia secondary to a saccular basilar artery aneurysm. *Stroke* 1988;19:104-7.
- 3 Boucek RJ, Noble NL, Gunja-Smith Z, Butler WT. The Marfan Syndrome: A deficiency in chemically stable collagen cross-links. *N Eng J Med* 1981;305:988-90.
- 4 Speciali JG, Lison MP, Junqueira GL. Anaerisma Intracraniano Na Sindrome De Marfan. *Arq Neuro-Psiquiatria (Sao Paulo)* 1971;29:453-57.
- 5 Finney HL, Roberts TA, Anderson RE. Giant intracranial aneurysm associated with Marfan's Syndrome. *J Neurosurg* 1976;45:342-7.
- 6 Matsuda M, Matsuda I, Handa H, Okamoto K. Intracavernous Giant Aneurysm Associated with Marfan's Syndrome. *Surg Neurol* 1979;12:119-21.
- 7 Resende LADL, Asseis EA, Costa LDS, Gallina RA. Sindrome de Marfan e Aneurismas Intracranianos Gigantes. *Arq Neuro-Psiquiatria (Sao Paulo)* 1984;42:294-7.