

Neuropsychiatric manifestations of defect in mitochondrial beta oxidation response to riboflavin

William J Triggs, Charles R Roe, William J Rhead, Sandra K Hanson, Shen-Nan Lin, L James Willmore

Abstract

A 29 year old woman is described with severe hyperemesis gravidarum, atypical migraine, numerous admissions to hospital for psychiatric illness, non-epileptic seizures, and valproate-induced coma. Metabolic studies and measurement of [9,10(n)-³H]palmitate oxidation by cultured fibroblasts suggested a multiple acyl-CoA dehydrogenation disorder. Treatment with riboflavin abolished headaches and abnormal behaviour and normalised the plasma free carnitine level. Subtle defects in mitochondrial beta oxidation may be a treatable cause of disordered behaviour in adults.

The multiple acyl-CoA dehydrogenation disorders (MAD) include glutaric aciduria type II, ethylmalonic-adipic aciduria, and riboflavin-responsive C6-C10 dicarboxylic aciduria.¹ The primary defect in MAD seems to be a deficiency of the electron transfer flavoprotein (ETF) or its dehydrogenase, electron transfer flavoproteinubiquinone oxidoreductase (ETF-QO). In its severe form (MAD:S) patients present with non-ketotic hypoglycaemia, metabolic acidosis, and seizures—most do not survive infancy. In its milder form (MAD:M) patients have had symptomatic onset between 7 weeks and 22 years of age. The clinical spectrum of this disorder includes sudden infant death, recurrent Reye's syndrome-like illness, and a lipid-storage myopathy. Improvement after riboflavin supplementation has been reported in cases of MAD:M, presumably related to a defect in flavin transport, metabolism, or binding to ETF or ETF-QO.¹

We describe a woman with headaches, depression, non-epileptic seizures, and coma after valproate (VPA) treatment,² in whom biochemical studies were consistent with MAD:M. The dramatic response to riboflavin in this case suggests that a defect in acyl-CoA dehydrogenation may account for some of this patient's behavioural abnormalities.

Case report

A 29 year old woman was referred to us when she developed VPA-induced coma (previously described as case 1²). She had been treated for complex partial seizures and had a history of behavioural disturbances characterised by

emotional withdrawal and confusion. She often vomited and complained of severe headache. Episodes of vomiting and altered behaviour, first developing during pregnancy five years earlier, were attributed to severe hyperemesis gravidarum. The symptoms that continued after pregnancy were attributed to migraine. Prophylactic treatment with propranolol, atenolol, verapamil, amitriptyline, phenytoin, carbamazepine, and phenobarbital was ineffective. She had attempted suicide on several occasions.

After recovery from VPA-induced coma she was accusatory, delusional, and sometimes violent towards hospital staff. She complained of frequent headaches and vomited on occasion. Examination of the patient was always normal. Laboratory studies including CBC, platelets, coagulation studies, electrolytes, BUN, creatinine, liver function studies, ESR, and ANA were normal. A lumbar puncture was normal. CT MRI scans of the brain, electromyography, and multiple electroencephalograms were normal. Indeed, clinical observation revealed her seizures to be non-epileptic. Psychiatric evaluation suggested dysthymic disorder (DSM III, Axis I) and a mixed personality disorder with borderline and histrionic character traits (DSM III, Axis II). She received counselling and psychotherapy during the next five months without improvement.

Riboflavin (100 mg/day) was administered 21 weeks after coma. The patient's headaches, vomiting, and abnormal behaviour abated within two weeks after starting treatment. She discontinued psychotherapy and became employed for the first time in five years. A voluntary trial off riboflavin at week 61 caused reappearance of her symptoms resulting in hospitalisation. Re-starting riboflavin resulted in prompt clinical improvement. Improvement associated with riboflavin administration has persisted for 15 months. The patient's 5 year old son is clinically normal.

Materials and methods

Urine and plasma samples were obtained within 24 hours after the last VPA dose and at intervals of 1, 7, 21, 23, 24, 34, 62, and 65 weeks after recovery from VPA-induced coma. Samples were stored at -20°C until analysis. Urine creatinine was measured spectrophotometrically. Urinary organic acids were analysed after derivatisation and extraction

University of Texas
Health Science Center
at Houston,
Department of
Neurology
W J Triggs
S K Hanson
L J Willmore

Analytical Chemistry
Center
Shen-Nan Lin

Department of
Pediatrics, Duke
University Medical
Center, Durham,
North Carolina
C R Roe

Department of
Pediatrics, University
of Iowa Hospitals and
Clinics, Iowa City
W J Rhead

Correspondence to:
Dr Willmore, Department of
Neurology, University of
Texas Medical School,
6431 Fannin #7.044,
Houston, TX 77030, USA.

Received 12 March 1991 and
in revised form 24 June 1991.
Accepted 9 July 1991

using a gas chromatograph mass spectrometer with an electron impact ion source (Finnigan-MAT model INCOS 50 GC/MS).³ Organic acid excretion was determined as $\mu\text{mol}/\text{mg}$ creatinine relative to the mean and 96th percentile established for 46 patients without metabolic disorders. Carnitine levels were determined by the radioenzymatic method of Brass and Hoppel,⁴ and urinary acylcarnitine profiles by fast atom bombardment with tandem mass spectrometry.⁵

Oxidation of medium and long chain fatty acids by cultured fibroblasts was assessed by measuring the production of $^3\text{H}_2\text{O}$ from [9,10(n)- ^3H]palmitate.⁶

Results

Urinary organic acid analysis during the VPA-induced coma showed clearly increased excretion of acetoacetic, lactic, adipic, and ethylmalonic acids (table). Urinary excretion of 3-hydroxybutyric, 2-ketoglutaric, and suberic acids was moderately elevated. Only the urinary excretion of ethylmalonic acid remained elevated one week after coma. Urinary organic acid analysis was normal at weeks 7, 21, 23, and 34. When the patient was hospitalised at week 62, however, after discontinuation of riboflavin, organic acid analysis again showed increased excretion of acetoacetic and 2-ketoglutaric acids. Riboflavin therapy was restarted and organic acid analysis was again normal at week 65. The plasma free carnitine level was decreased both during VPA-induced coma and after recovery. Excluding VPA-induced coma, riboflavin administration increased the mean plasma free carnitine level from 22.0 (SEM 2.4) to 35.7 (1.7) $\mu\text{mol}/\mu\text{l}$, (normal 45 (8) $\mu\text{mol}/\mu\text{l}$, $n = 3$, $p < 0.02$). Plasma acylcarnitines were always normal.

Table Results of urinary organic acid analysis on women with possible mitochondrial beta oxidation defects

Organic acids ($\mu\text{mol}/\text{mg cr}$)	Week 0*	Week 1	Week 62†	Normal (96%ile)
Acetoacetic	34.6	*	108.7	3.43
3-OH butyric	0.26	*	0.10	0.05
2-Ethylmalonic	1.37	0.52	0.05	0.06
Adipic	8.81	*	*	0.49
Suberic	0.16	*	*	0.11
Glutaric	0.06	*	*	0.04
2-OH butyric	0.30	*	*	0.35
2-Ketoglutaric	1.79	0.05	2.18	1.20
Lactic	19.60	0.31	*	0.78
Pyruvic	0.07	0.18	*	0.45

cr = Creatinine.

* = Valproate coma.

† = Riboflavin stopped, clinical decompensation.

There was no definite effect of riboflavin administration on the urinary acyl-to-free carnitine ratio; the ratio was increased⁷ at weeks 0, 7, 21, 23, and 34, and was normal at weeks 62 and 65.

The urinary acylcarnitine profile during coma showed acetylcarnitine (the predominant normal urinary acylcarnitine) as well as dicarboxylic acylcarnitines, butyrylcarnitine and glutarylcarnitine. Butyrylcarnitine, glutarylcarnitine, and dicarboxylic acylcarnitines were also detected one week after VPA-induced coma, at week 34 during a brief intercurrent illness, and at week 62 while hospitalised after discontinuation of riboflavin (figure). The mean (SEM) oxidation of [9,10(n)- ^3H]palmitate by this patient's fibroblasts was 1710 (266) pmol/mg protein/h. This value was 66% of control (2610 (324) pmol/mg protein/h, $n = 6$). In a repeat assay this patient's fibroblasts oxidised [9,10(n)- ^3H]palmitate at a rate of 1080 (98) pmol/mg protein/h (normal 2072 (180) $n = 4$).

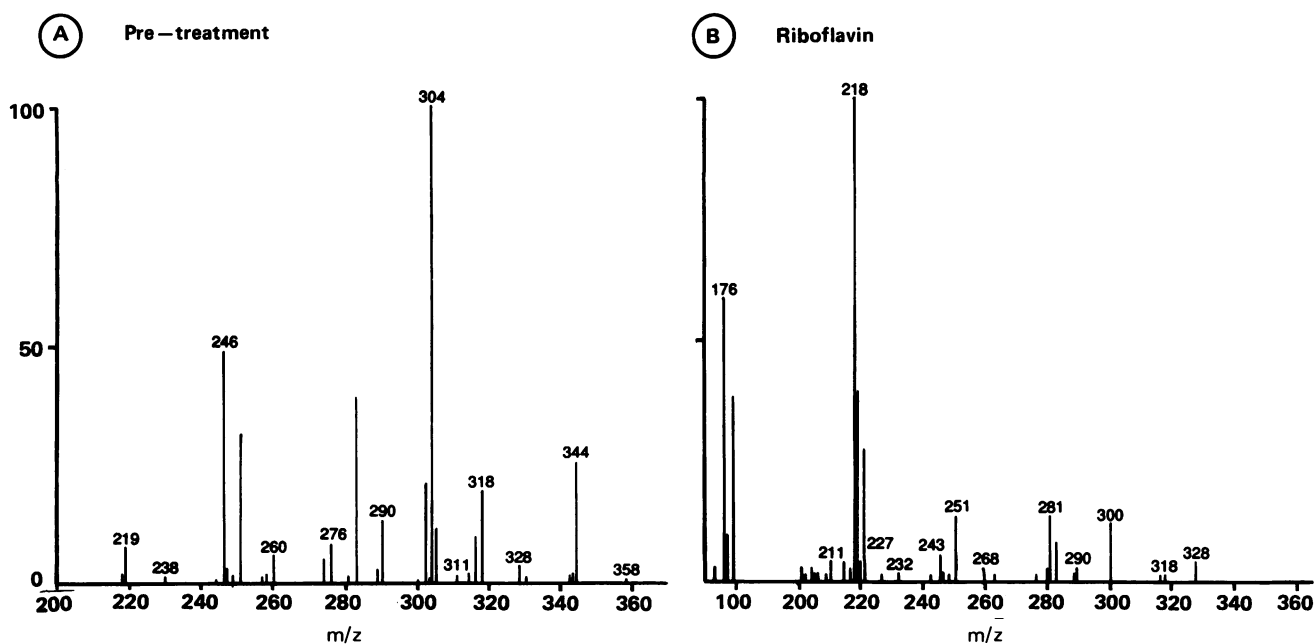


Figure Profile of urinary acylcarnitines (fast atom bombardment tandem mass spectrometry): (a) during clinical decompensation induced by stopping riboflavin, showing prominent peaks corresponding to methyl esters of butyrylcarnitine (m/z 246), glutarylcarnitine (m/z 304), and dicarboxylic acylcarnitines (m/z 318, 344); (b) after riboflavin treatment, showing normal profile dominated by acetylcarnitine (m/z 218) and free carnitine (m/z 176).

Discussion

Valproate precipitated coma in this patient. Metabolic assessment revealed ketosis with lactic, ethylmalonic, and adipic aciduria. Ethylmalonic acid is produced by the carboxylation of butyryl-CoA and adipic acid is formed through the microsomal omega oxidation of hexanoyl-CoA, suggesting that VPA may have unmasked a partially compensated defect in the beta oxidation of fatty acids.² Patients with organic acidurias have decreased plasma free carnitine levels and excrete urinary acylcarnitines corresponding to the acyl-CoA esters known to accumulate in these diseases.⁷ Although organic aciduria in our patient resolved after discontinuation of VPA, the plasma free carnitine level was decreased and the urinary acyl-to-free carnitine ratio was increased both during VPA-induced coma and after recovery. Further, the detection of butyrylcarnitine and glutarylcarnitine both during VPA treatment and at 34 and 62 weeks after recovery from coma suggests a multiple acyl-CoA dehydrogenation defect (MAD).⁸ Indeed, cultured fibroblasts from this patient showed decreased residual oxidation of palmitate between 66% and 52% of control, a level comparable to MAD:M.⁶

The administration of riboflavin to our patient caused reproducible amelioration of headache, vomiting, and abnormal behaviour and normalisation of the plasma free carnitine level. Riboflavin is the precursor of flavin adenine dinucleotide (FAD), a coenzyme in the transfer of electrons from acyl-CoA dehydrogenases through ETF and ETF-QO.¹ The biochemical response to riboflavin we observed is consistent with the stabilisation of a defective ETF or ETF-QO by increased levels of intramitochondrial FAD. As we did not directly assay ETF and ETF-QO activity, we cannot distinguish between primary defects in flavin metabolism, transport, or apoenzyme binding as a cause for acyl-CoA dehydrogenase dysfunction in our patient.¹

Clinical improvement with riboflavin suggests that this patient's partially compensated metabolic defect was symptomatic. Precipitation of symptoms during pregnancy has also been reported in two other cases of MAD-M presenting in adults.^{9,10} A recent study found normal riboflavin levels in pregnant women at delivery.¹¹ However, a substantial fall in plasma free carnitine with an increase in the acyl-to-free carnitine ratio occurs during pregnancy.¹² As carnitine buffers toxic acyl-CoA metabolites in disorders of beta oxidation through the formation and excretion of acylcarnitines,⁷ the development of a physiological carnitine insufficiency could explain the onset of symptoms during pregnancy.

Behavioural abnormalities as a primary manifestation of MAD have not been reported

previously. Clearly, however, this disorder may affect central nervous system function; seizures and hypotonia are common among infants with MAD:S.¹ A recent study found biochemical evidence of MAD:M in a young girl with recurrent demyelinating disease mimicking multiple sclerosis.¹³ A patient with ETF-deficient MAD:M has recently been described with an extrapyramidal movement disorder and basal ganglia gliosis.¹⁴ The results of the biochemical and fibroblast oxidation studies in our patient suggested a mild acyl-CoA dehydrogenation disorder. While the clinical presentation may be subtle, we suggest that defective mitochondrial beta oxidation may be a treatable cause of behavioural abnormalities in adults.

Supported by the Texas Comprehensive Epilepsy Program (LJW), by National Institutes of Health grants NS16704 (LJW), DK 33289 (WJR), and HD 24908 (CRR), and by a clinical research grant from the Muscular Dystrophy Association (WJR). The authors have no proprietary interest in the drug valproate or in any commercially available riboflavin preparation.

This paper was presented in part at the 42nd annual meeting of the American Academy of Neurology, Miami Beach, Florida, May 2, 1990.

References

- Frerman FE, Goodman SI. Glutaric acidemia type II and defects of the mitochondrial respiratory chain. In: Scriver CR, Beaudet AL, Sly WS, Valle D, eds. *The metabolic basis of inherited disease*. 6th ed. New York: McGraw-Hill, 1989:915-31.
- Triggs WJ, Bohan TP, Lin S-N, Willmore LJ. Valproate induced coma with ketosis and carnitine insufficiency. *Arch Neurol* 1990;47:1131-3.
- Jonas AJ, Lin S-N, Conley SB, et al. Urine glycerolaldehyde excretion is elevated in the renal fanconi syndrome. *Kidney Int* 1989;35:99-104.
- Brass EP, Hoppel CL. Carnitine metabolism in the fasting rat. *J Biol Chem* 1978;253:2688-93.
- Millington DS, Norwood DL, Kodo N, et al. Application of fast atom bombardment with tandem mass spectrometry and liquid chromatography/mass spectrometry to the analysis of acylcarnitines in human urine, blood and tissue. *Anal Biochem* 1989;180:331-9.
- Moon A, Rhead WJ. Complementation analysis of fatty acid oxidation disorders. *J Clin Invest* 1987;79:59-64.
- Chalmers RA, Roe CR, Stacey TE, Hoppel CL. Urinary excretion of L-carnitine and acylcarnitines by patients with disorders of organic acid metabolism: evidence for secondary insufficiency of L-carnitine. *Pediatr Res* 1984;18:1325-8.
- Roe CR, Millington DS, Maltby DA. Diagnostic and therapeutic implications of acylcarnitine profiling in organic acidurias associated with carnitine insufficiency. In: Borum PR, ed. *Clinical aspects of human carnitine deficiency*. New York: Pergamon, 1986:97-107.
- Dusheiko G, Kew MC, Joffe BI, Lewin JR, Mantagos S, Tanaka K. Recurrent hypoglycemia associated with glutaric aciduria type II in an adult. *N Engl J Med* 1979;301:1405-9.
- Harpey J-P, Charpentier C, Goodman SI, Darbois Y, Lefebvre G, Sebbah J. Multiple acyl-CoA dehydrogenase deficiency occurring in pregnancy and caused by a defect in riboflavin metabolism in the mother. *J Pediatr* 1983;103:394-8.
- Kirshenbaum NW, Dancis J, Levitz M, Lehanka J, Young BK. Riboflavin concentration in maternal and cord blood in human pregnancy. *Am J Obstet Gynecol* 1987;157:748-52.
- Cederblad G, Fähræus L, Lindgren K. Plasma carnitine and renal-carnitine clearance during pregnancy. *Am J Clin Nutr* 1986;44:379-83.
- Powell BR, Kennaway NG, Rhead WJ, Reece CJ, Burlingame TG, Buist NRM. Juvenile multiple sclerosis-like episodes associated with a defect of mitochondrial beta oxidation. *Neurol* 1990;40:487-91.
- Loehr JP, Goodman SI, Frerman FE. Glutaric acidemia type II: Heterogeneity of clinical and biochemical phenotypes. *Pediatr Res* 1990;27:311-5.