

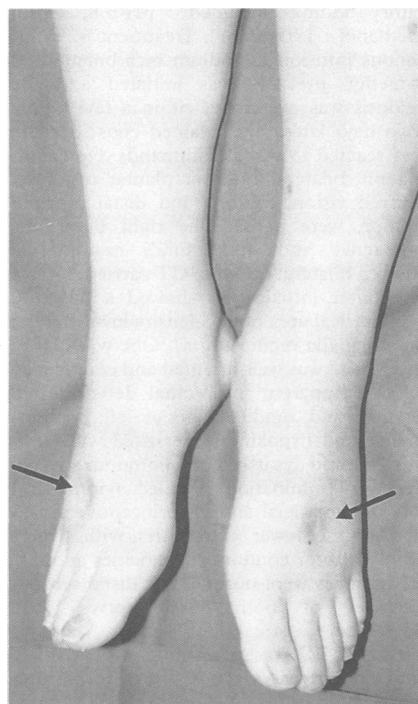Figure 2 Photograph of the legs, showing marked pitting oedema (arrow).

than 30 seconds apart. The skin responses were normal in the palms and soles (fig 1A). With oral administration of prednisolone the symptoms improved. In March 1990 she had the second attack of transverse myelopathy when she did not have prednisolone. Sensory loss below the level of T5, paraplegia with

pyramidal feature, marked pitting oedema of the shins and feet (fig 2), constipation and abdominal distention, and dysuria were observed. Oedema was not noted in the hands or face. The skin temperature in the legs was increased compared with that before the second attack. The oedema was exacerbated and improved in accordance with the abdominal distention and dysuria. There were no signs or abnormal laboratory data suggesting heart failure, renal failure, liver dysfunction, thyroid dysfunction or local inflammation. Venography of the left leg did not show obstruction in the deep veins.

MRI showed lesions with high signal intensity on T₂-weighted image at the lower cervical and the mid-thoracic segments. There were no abnormal results in brain MRI, visual evoked potential, brainstem auditory evoked potential, or somatosensory evoked potential by stimulation of the median nerves. On SSR the plantar responses bilaterally disappeared while the palmar responses were well preserved (fig 1B). Post-ganglionic function was evaluated with local sweat response to intradermal injection of 10⁻⁴ g/ml acetylcholine using silastic impression mold technique.² The density of sweat droplets at the dorsum of the right foot was normal. After plasma exchange and intravenous administration of prednisolone, the motor impairment and oedema gradually improved. In December 1990 the foot oedema was minimal and the plantar SSR responses had reappeared (fig 1C).

Swelling and oedema is often observed in patients with Raynaud's disease or causalgia after acute interruption of post-ganglionic sympathetic fibres such as a wide-spread sympathectomy. Complete sympathetic block dilates vein and capillary and increases peripheral pooling, which raises hydrostatic

pressure within the vessels causing localised oedema. We showed that the preganglionic sympathetic tract in the spinal cord was often disturbed in patients with multiple sclerosis with myelopathy.¹ Most patients with complete transection of the spinal cord due to injury showed swelling of the lower limbs or oedema, but they gradually subsided within several months even without restoration of somatic function. Probably some compensatory mechanism improves the hydrostatic condition in the chronic stage and explains why oedema is not noted in patients with chronic autonomic failure syndrome. On the other hand, SSR was normally recorded in three patients with marked lower limb oedema due to nephrotic syndrome or hypothyroidism. Therefore, it was considered in this patient that the acute thoracic cord lesion interrupted the sympathetic tract, which participated in the production of oedema in the legs. It is suggested that preganglionic sympathetic lesion in the spinal cord should be considered when investigating the cause of oedema in patients with acute myelopathy.

TAKANORI YOKOTA
Department of Neurology,
Tokyo Medical and Dental University
HITOSHI TANABE
Department of Neurology,
Tokyo Metropolitan Neurological Hospital,
Tokyo, Japan

Correspondence to: Dr Yokota, Department of Neurology, Tokyo Medical and Dental University, 1-5-45 Yushima, Bunkyo-ku Tokyo 113, Japan.

- 1 Yokota T, Matsunaga T, Okiyama R, et al. Sympathetic skin response in patients with multiple sclerosis compared with patients with spinal cord transection and normal controls. *Brain* 1991;114:1381-94.
- 2 Kennedy WR, Sakuta M, Sutherland D, Goetz FC. Quantitation of the sweating deficiency in diabetes mellitus. *Ann Neurol* 1984; 15:482-8.

Incremental response to repetitive stimulation in Guillain-Barré syndrome

The integrity of neuromuscular synaptic transmission may be studied by repetitive stimulation. In a normal individual, the amplitude of the compound muscle action potential (CMAP) changes very little on repetitive stimulation at slow (3 Hertz) or fast (50 Hertz) rates.¹ We recorded an incremental response to repetitive stimulation in a patient with Guillain-Barré syndrome (GBS), who had clinical features resembling those seen in botulism.

A five year old girl was admitted with a cough lasting a week, double vision and difficulty raising her eyelids for four days. On examination she had bilateral lower motor neuron facial weakness, bilateral loss of abduction of the eyes and restriction of upgaze, and a bilateral bulbar palsy. The pupil size and responses were normal. She had moderate proximal weakness of the right upper and lower limbs and all reflexes apart from the right ankle jerk were absent. By the third hospital day she developed complete ophthalmoplegia, complete bilateral ptosis and weakness in all four limbs but distal and

left upper limb proximal strength were relatively preserved.

Investigations showed a leukocyte count of 9.6 × 10⁹/L. Cerebrospinal fluid on the seventh hospital day contained protein 2.27 g/L, with no cells. A cranial CT scan was normal. A mouse injection test of the patient's serum for botulinum toxin was negative. Stool culture for *Clostridium botulinum* was negative.

Upper limb nerve conduction studies showed the following (table): a) Reduction of resting CMAP amplitude; b) Motor conduction velocity below 80% of the lower limit of

Table Repetitive stimulation and nerve conduction studies

Day No	Repetitive stimulation test			Nerve conduction study											
	CMAP (mV) resting	CMAP (mV) 50 Hz*	Increment (%)	NCV(ms) [distal latency (ms)]				SAP (μV)				F-wave (ms)			
				RU	RM	LU	LM	RU	RM	LU	LM	RU	RM		
3	2.6 (L)	4.7	81												
7	2.0 (R)	2.7	37	53 [2.0]	48 [2.5]	50 [3.7]	50 [2.6]	17	13	8	15	20.6	22		
13	3.6 (R)	3.6	0												
21	3.1 (L)	3.4	9.7	50 [2.0]	46 [3.3]	44 [3.0]	35 [3.0]	3	12	4	7		23.8		
28	3.2 (L)			54 [2.2]	37 [2.6]	54 [2.2]	NE [3.1]					23.8	25.0		

*Amplitude of largest CMAP.

(L) = left, (R) = right.

CMAP = compound muscle action potential amplitude.

NCV = forearm motor nerve conduction velocity.

SAP = orthodromic sensory action potential amplitude recorded at wrist.

RU = right ulnar, RM = right median, LU = left ulnar, LM = left median.

NE = no CMAP elicited on stimulation at elbow.

Normal values²: Motor conduction velocity: Median = 47-72 m/s; Ulnar = 51-76 m/s.

CMAP amplitude: Median = 2.6-9.7 mV; Ulnar = 3.7-11.6 mV.

Distal motor latency: Median = 1.8-2.8 ms; Ulnar = 1.1-2.2 ms.

Sensory action potential amplitude: Median = 7-36 μV; Ulnar = 7-22 μV.

F wave latency: Median = 16.2-19.8 ms; Ulnar = 15.8-18.8 ms.

Values 20% above or below the limits of normal shown in bold.

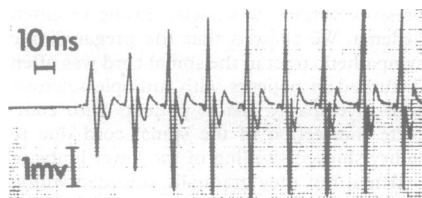

Figure Incremental increase in the compound motor action potential of the left abductor digiti minimi on repetitive stimulation of the ulnar nerve at 50 Hertz.

normal in two nerves; c) CMAP ratio from proximal and distal stimulation less than 0.7 in the right median and left ulnar nerves recorded on day 21; d) A reduction of both ulnar sensory action potential amplitudes below 80% of the lower limit of normal; d) F wave latency prolongation from day 7, increasing to 120% of the upper limit of normal by day 21.

Repetitive stimulation of the left ulnar nerve was performed, with the active surface recording electrode over the midportion of the abductor digiti minimi muscle. The CMAP at rest was compared with the highest amplitude CMAP on stimulation. On the third hospital day supramaximal stimulation at 3 Hertz gave an increment of 18%, and stimulation at 50 Hertz gave an abnormal incremental response of 81% (normal mean increment = 2.4%; upper limit of normal = 42.4%)¹ (figure). The incremental response decreased over the next 10 days (table).

The patient was intubated. She was started on guanidine, 240 mg every six hours. Slow improvement began by the twelfth hospital day, but eye movements took over a month to return to normal. The patient started to walk after two months and subsequently made a complete recovery.

An incremental response to repetitive stimulation is characteristic of impairment of presynaptic release of acetylcholine (ACh), as seen in the myasthenic syndrome, botulism, and also with some drugs and with certain types of arthropod envenomation. In the myasthenic syndrome it appears very likely that an antibody, probably IgG, interferes with ACh release. In botulism, the botulinus toxin also decreases ACh release.¹

Although the progression of signs in our patient was similar to that seen in botulism, the normal pupils and inability to detect *Clostridium botulinum* or botulinus toxin were against botulism. The raised CSF protein is very atypical for botulism and the finding of abnormal motor and sensory nerve conduction and F wave prolongation are strongly in favour of GBS.² A clinical picture resembling botulism is known to occur as a variant of GBS.³

There is increasing evidence for a humoral role in GBS. Antibodies to several myelin antigens have been found in GBS and complement fixing antibodies to peripheral nerve myelin appear to be involved in myelin destruction.⁴ The titre of these antibodies is highest when neurological symptoms first occur⁴ and the abnormal incremental response early in the course of our patient's illness fits this pattern. The finding of an incremental response to repetitive stimulation in our patient with GBS suggests the presence of an antibody directed against the

presynaptic terminal, interfering with ACh release.

PATRICK PULLICINO
NOEL BECK
Department of Medicine,
St Luke's Hospital,
Guardamangia, Malta

Correspondence to: Dr Pullicino, Department of Neurology/SUNY Buffalo, Buffalo General Hospital, Buffalo, NY 14203, USA.

- 1 Oh SJ. *Electromyography. Neuromuscular transmission studies*. Baltimore, MD: Williams and Wilkins;1988:69.
- 2 Ropper AH, Widjicks EFM, Shahani BT. Electrodiagnostic abnormalities in 113 consecutive patients with Guillain-Barré Syndrome. *Arch Neurol* 1990;47:881-7.
- 3 Ropper AH. Unusual clinical variants and signs in Guillain-Barré syndrome. *Arch Neurol* 1986;43:1150-2.
- 4 Koski CL, Graz E, Sutherland J, Mayer RF. Clinical correlation with anti-peripheral myelin antibodies in Guillain-Barré syndrome. *Ann Neurol* 1986;19:573-7.
- 5 Miller RG, Kuntz NL. Nerve conduction studies in infants and children. *J Child Neurol* 1986;1:19-26.

Putaminal necrosis after methanol intoxication

Optic neuropathy and putaminal necrosis are the two main complications of methanol poisoning,^{1,2} generally occurring in combination after severe intoxication of either suicidal or accidental origin. Surviving patients usually show permanent sequelae consisting of bilateral blindness and motor dysfunction including rigidity, hypokinesia, and other Parkinsonian-like signs, occasionally associated with limb polyneuropathy. Brain pathology has been documented in earlier studies showing the specific involvement of the basal ganglia, especially the putamen. This unusual lesion site was more recently confirmed in reports including brain imaging data, either with CT or MRI.³ We report a new case study in which repeated CT and MRI examinations may help elucidate the specific putaminal damage.

A 40 year old depressive woman was admitted to hospital after attempting suicide by methanol ingestion, having drunk nearly one litre of methylated spirits several hours earlier. On admission, she was comatose with generalised hypotonia, non reactive pupils and hyperventilation. Her vital signs were: apyrexia, blood pressure 120/60, pulse rate 110 bpm, respiration 30/mn. The main labo-

ratory findings included: pH 6.8; serum methanol: 180 mmol/l. Treatment by intravenous infusion of sodium bicarbonate and 4-methyl pyrazole was initiated and the acidosis was overcome within a few hours. Two days later, she regained consciousness and reacted to verbal commands. On examination, bilateral extensor plantar response, blurred vision, rigidity, and distal postural tremor, were noted. The right pupil was unreactive and optic fundi examination showed bilateral oedema. CT carried out five days after intoxication showed a bilateral, symmetrical area of low density involving the basal ganglia region (fig a). One week later, the patient was well-oriented and cooperative without apparent intellectual deterioration. Tremor and rigidity were of left predominance and hypokinesia persisted with amimic face and dysarthric, monotonous speech. Sensory examination revealed symmetrical loss of superficial and proprioceptive sensation of the lower extremities with hyperpathia. Motor conduction velocities and distal latencies were normal, but distal sensory latencies of both sural nerves were decreased.

Brain MRI was performed with a 0.5 T superconductive magnet three weeks after intoxication (fig b, c). The core lesion (fig b) centred on the putamen, surrounded by a large hyperintensity (fig c), suggested major oedema. Two months later she remained almost totally blind with optic atrophy on fundus examination. Signs of moderate bilateral sensory neuropathy and extrapyramidal syndrome persisted. Neuropsychological evaluation was within normal limits. Repeat CT and MRI examinations showed residual bilateral putaminal cavities.

Our report illustrates the usual consequences of massive methanol intoxication on the nervous system.² After a short comatose period, severe bilateral blindness and moderate extrapyramidal syndrome were found in association with lower limb axonal neuropathy.

The relationship between methanol-induced blindness and damage to the retina and optic nerve was the first feature to be well documented in early clinical-pathological works. Subsequently, several necropsy studies of the brain revealed symmetrical haemorrhagic necrosis of the putamen or prominent hyperaemia in the basal ganglia⁴ as the specific neuropathological outcome of human methanol intoxication. Selective putaminal locus of lesions was confirmed in

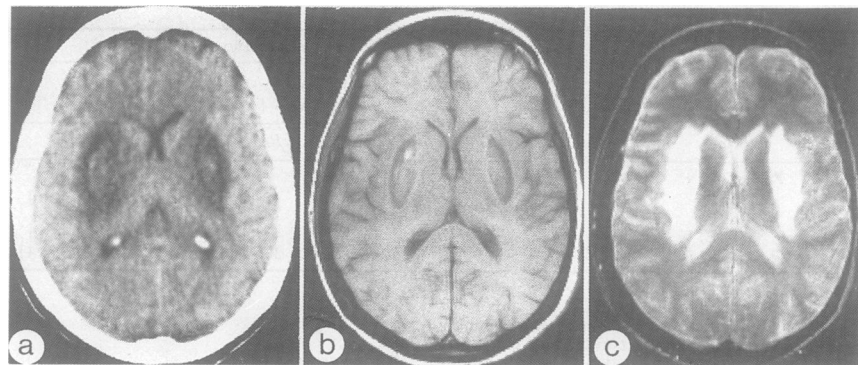


Figure 1 (a) First non injected CT scan five days after intoxication. Bilaterally symmetrical, low density lesion in the putaminal region with central isodense zone possibly suggesting microhaemorrhages; (b) MRI scan: T1 weighted axial section (TR = 450ms; TE = 28ms). Bilateral putaminal lesions; (c) T2 weighted sequence (TR = 2000ms, TE = 120ms). High signal intensity of the basal ganglia and the periventricular white matter suggesting major oedematous participation.