

brain stem. In our case the lesion was involving the pons and medulla.

Pathological laughter may be a rare and unusual presentation of a brain stem lesion (glioma) that has not been reported earlier.

ANIL P LAL
MATHEW J CHANDY
Department of Neurological Sciences,
Christian Medical College and Hospital,
Vellore, India

Correspondence to: Dr Chandu, Department of Neurological Sciences, Christian Medical College and Hospital, Vellore 632004, India.

- 1 Poock K. Pathological laughter and crying. In: Vinken PJ and Bruyn GW, eds. *Handbook of clinical neurology*, Vol 45. Amsterdam: North Holland, 1985;219-26.

Post radiation monomelic amyotrophy

Lamy *et al* recently reported three cases of post radiation lower motor neuron syndrome presenting as monomelic amyotrophy.¹ I would like to report a further case.

A thirty six year old man presented in 1989 with weakness abducting his left hip. Nineteen years before he had been treated for a left testicular seminoma with an orchidectomy and radiotherapy. The abdominal radiotherapy field dispensed a prescribed tumour dose of 32.5 Gy, and the para-aortic fields increased the dose to 50 Gy in twenty fractions. The fields included the lower 6 cm of the spinal cord, the whole cauda equina and the lumbrosacral roots and plexuses. The initial weakness of the left leg has gradually progressed to weakness and wasting of all muscle groups with ankle dorsiflexion, hip flexion and abduction being more severely affected. He now walks with a stick. The limb is areflexic with a flexor plantar response. There is no sensory loss or sphincter involvement. The right leg is not involved. Six months of treatment with prednisolone (20 mg per day) was of no benefit. Electrophysiological examination showed advanced denervation confined to the muscles of the left leg, with large amplitude motor unit potentials. An abnormal axon reflex and absent F wave in extensor digitorum brevis suggests a lesion at the root or anterior horn cell level. Motor and sensory conduction velocities and distal latencies were normal. General examination, laboratory investigations including CSF analysis and a myelogram were all normal.

The 17 year latency in this case, and the nine and twelve year latencies reported by Lamy *et al*,¹ as well as the previously mentioned electrophysiological data point to an anterior horn cell disorder reminiscent of the postpolio syndrome.² It is plausible that the radiotherapy damaged a critical number of motor neurons and that surviving neurons sprout to reinnervate more muscle fibres than normal. This process produces large motor units that may stress the cell body. After a number of years these hyperfunctioning motor units may not be able to maintain the metabolic demands of all their sprouts and a deterioration of individual terminals may result. Eventually enough nerve terminals are destroyed and enough reserves are diminished for weakness to appear. This would be consistent with the focal nature of post radiation lower motor neuron syndrome and

its slow, stepwise and unpredictable progression.

As Lamy *et al* state, the cause of this disorder seems unpredictable. My patient continues to deteriorate. Maier *et al*³ report that three of their 15 patients had a monomelic amyotrophy, but give no information on clinical course. Vibeke Schiodt and Kristenson⁴ report that two of their patients had monomelic amyotrophy—one had "slight subjective weakness of the left leg" which had improved by six months and the other case had non-progressive right leg weakness.

MATTHEW JACKSON
Department of Neurology,
Queen's Medical Centre,
Nottingham, UK

- 1 Lamy C, Mas JL, Zeigler M, De Recondo J. Postradiation lower motor neuron syndrome presenting as monomelic amyotrophy. *J Neurol Neurosurg Psychiatry* 1991;54:649-9.
- 2 Munsak TL, ed. *Post polio syndrome*. Boston: Butterworth-Heinemann, 1991.
- 3 Maier JG, Perry RH, Taylor N, Sielak MH. Radiation myelitis of the dorsolumbar spinal cord. *Radiology* 1969;93:153-60.
- 4 Vibeke Schiodt A, Kristenson O. Neurological complications after irradiation of malignant tumours of the testis. *Acta Radiologica Oncologica* 1978;17:369-78.

Sellar tuberculoma

In Asian countries, before the advent of chemotherapy, tuberculomas accounted for about 30% of all intracranial mass lesions.¹ They remain a major problem even though they are now less common due to anti-tuberculosis drugs and improved living conditions. Intrasellar tuberculomas, not uncommonly, seen at post mortem examinations, rarely present clinically.²⁻⁴ Only five surgically verified cases have been reported to date.

A 40 year old man, resident of an area where tuberculosis is endemic, presented in January 1988 complaining of an intermittent, dull, generalised headache of two years duration, and progressive diminution of vision in both eyes over a period of six months. He was in good general health with no clinical signs of endocrinopathy. Visual acuity was reduced (right eye—finger counting 3 m; left eye—hand movement perception at one meter). Perimetry showed constricted field of vision in the right eye, the left was unascertainable. He had bilateral optic atrophy, but no other neurological abnormality. The clinical diagnosis was a sellar tumour. Haematological and biochemical investigations were unremarkable except for an erythrocyte sedimentation rate (ESR) of 90 mm in the first hour. Radiographic examination revealed a normal chest and an enlarged sellar on x ray of the skull. CT scan (figure) showed a uniformly hyperdense enhancing sellar mass with a suprasellar extension.

An operation was performed on 14 January 1988 using a transnasal transsphenoidal route. The sellar floor and dura mater were intact. The dura mater was tough and thickened and when it was opened, a greyish white, tough nonsuckable tumour was revealed. It was adequately decompressed under intraoperative pneumoencephalography.

Microscopic examination showed that pituitary tissue had been partially replaced by granulomas comprising of epithelioid cells,

Langhan type of giant cells surrounded by lymphocytes, and plasma cells. Minimal caseation was present in some granulomas. Tuberculoma of the pituitary gland was diagnosed. A postoperative Mantoux test was positive but sputum culture for acid fast bacilli was negative. Treatment was started with isonex, rifampicin and ethambutol. The patient developed hepatotoxicity to rifampicin, but isonex and ethambutol were continued for nine months. He was in good health, had no headache, and vision in the left eye had improved (finger counting—3 m). The right eye vision showed no improvement in the constricted field (finger counting—6 m).

A pituitary tuberculoma is extremely rare but usually presents as a chiasmal syndrome. In two reported cases the lesion was successfully removed subfrontally.^{2,3} An exclusively intrasellar tuberculoma⁵ was approached transsphenoidally and treated with isonex only for three months. In our patient the lesion was intrasellar with a suprasellar extension. It could be treated, however, by a transnasal transsphenoidal approach. There was little reason to suspect a pituitary tuberculoma before the operation except for the raised ESR. The transnasal transsphenoidal approach allowed a subtotal removal of the tuberculoma while avoiding CSF contamination by tuberculous material.

Tuberculous meningitis occurs in the majority of surgically treated intracranial tuberculomas without anti-tuberculous chemotherapy.¹⁻³ Chemotherapy should be given in a three drug combination for three months, followed by a two drug combination for a further 15 months.

SUHIL C TAPARIA
GIRISH TYAGI
ANIL K SINGH
RANJANA GONDAL
BRAHM PRAKASH

Department of Neurosurgery and Pathology,
GB Pant Hospital,
Maulana Azad Medical College & Hospital,
New Delhi, India

Correspondence to: Dr Taparia, Department of Neurosurgery, GB Pant Hospital, New Delhi-110 002, India.

- 1 Dastur HM. Tuberculoma. In: Vinken PJ, Bruyn GW, eds. *Handbook of Clinical Neurology*, Vol 18. New York: American Elsevier, 1975:413-26.
- 2 Brooks HB, Dumalo JS, Bronsky D, Waldstein SS. Hypophysial tuberculoma with hypopituitarism. *Am J Med* 1973;54:777-81.
- 3 Coleman CC, Meredith JM. Diffuse tuberculosis of the pituitary gland simulating tumour with postoperative recovery. *Arch Neurol Psychiatry* 1940;44:1076-85.
- 4 Eckland DJA, O'Neill JH, Lightman SL. A pituitary tuberculoma. *J Neurol Neurosurg Psychiatry* 1987;50:360-1.
- 5 Esposito V, Fraioli B, Ferrante L, Palma L. Intrasellar tuberculoma. Case report. *Neurosurgery* 1987;21:721-3.

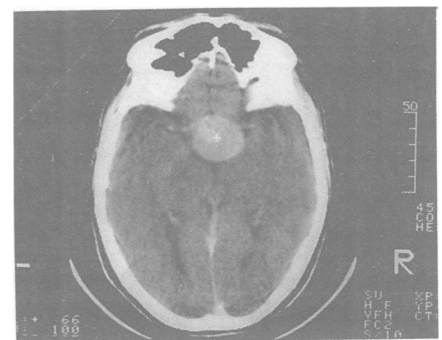


Figure CT scan showing sellar and suprasellar hyperdense lesion.