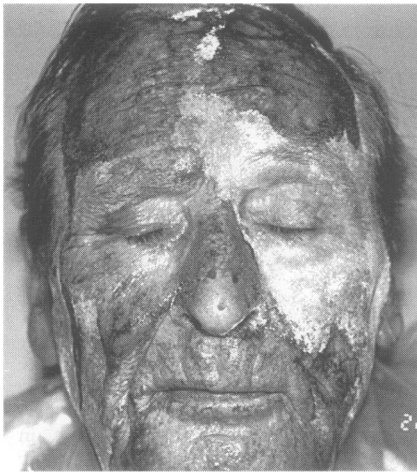



Localised anhidrosis around the left orbit on the side of botulinum toxin injections.

the footpads of kittens.² The area of anhidrosis does not correspond to any particular peripheral nerve distribution. In the absence of sensory disturbance it is unlikely that anhidrosis is the result of inadvertent direct nerve injury from the injecting needle.

Localised facial anhidrosis is clearly of no clinical significance as a side effect of botulinum toxin injections. These results suggest a further therapeutic use for the toxin, however. Botulinum toxin type A might be useful as a treatment for patients with severe focal hyperhidrosis. The treatment may be of particular help in axillary hyperhidrosis, a socially and emotionally disturbing condition in which the hyperhidrotic area is usually localised to the central part of the axilla where eccrine glands are heavily concentrated producing 70–80% of axillary sweat secretion.⁵ If medical treatment proves ineffective or produces unacceptable side effects, surgical excision of the axillary sweat glands is the other current option.⁵ In this group of patients, treatment with botulinum toxin type A might be a worthwhile alternative. The dosage and the required interval between injections remain to be determined, as the recovery time for sudomotor terminals is unknown. This study indicates that the effect is likely to persist for at least three months.

KHALAFALLA O BUSHARA
DAVID M PARK
Department of Neurology,
Southend Hospital,
Essex S50 0RY, UK

Correspondence to: Dr K Bushara, Department of Neurology, University of Wisconsin Hospital and Clinics, 600 Highland Avenue, Madison, Wisconsin 53792, USA.

- Molgo J, Comella JX, Angaut-Petit D, *et al.* Presynaptic actions of botulinum neurotoxins at vertebrate neuromuscular junctions. *Journ de Physiologie (Paris)* 1990;84:152–66.
- Ambache N. A further survey of the action of clostridium botulinum toxin upon different types of autonomic nerve fibre. *J Physiol (Lond)* 1951;113:1–17.
- Girlanda P, Vita G, Nicolosi C, Milone S, Messina C. Botulinum toxin therapy: distant effects on neuromuscular transmission and autonomic nervous system. *J Neurol Neurosurg Psychiatry* 1992;55:844–5.
- Vita G, Girlanda P, Puglisi, Maraballo L, Messina C. Cardiovascular reflex testing and single fibre electromyography in botulinum. *Arch Neurol* 1987;44:202–6.
- Hurley HJ, Shelley WB. A simple surgical approach to the management of axillary hyperhidrosis. *JAMA* 1963;186:109–15.

Measures of medial temporal lobe atrophy in Alzheimer's disease

Diagnosis of Alzheimer's disease in life is made on clinical grounds,¹ and currently employed criteria are burdened with considerable subjective judgement.² In view of the increasing possibility of treatment, an objective and early stage sensitive indicator of the disease could prove extremely valuable. Jobst *et al*³ have proposed that a simple CT measurement of the medial temporal lobe might improve in vivo diagnosis of Alzheimer's disease. Patients had pathologically confirmed Alzheimer's disease but dementia was of severe degree (mean mini mental state examination (MMSE) 9.3) and scanning occurred as late as one year before death. Work by Scheltens *et al*⁴ on other measures of medial temporal lobe atrophy focusing more precisely on the hippocampus (hippocampal height, width of the choroid fissure, and width of the temporal horn), has shown greater atrophy in moderately demented Alzheimer's disease patients than in controls.

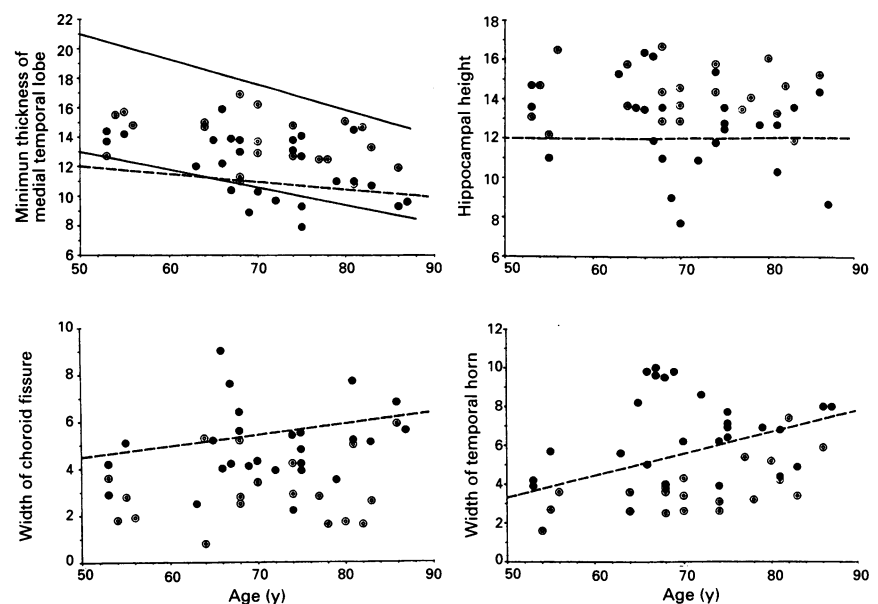
At present, there are no data as to which of these indicators of temporal lobe atrophy is more useful in the detection of Alzheimer's disease in its early phase. Therefore, we assessed the sensitivity of the measures obtained with MRI in patients with clinically defined mild to moderate Alzheimer's disease.

Twenty six consecutive patients with clinically defined Alzheimer's disease¹ (age 53 to 87, mean 71.0 (SD 9.1) years; MMSE 12 to 27, mean 18.5 (4.6)) and 21 normal controls (age 53 to 86, mean 70.2 (9.9) years; MMSE 23 to 30, mean 28.9 (1.9)) were recruited in the study. Patients with Alzheimer's disease underwent extensive neuropsychological testing, as previously described.⁵ Cases and controls underwent MRI of the brain with a 1.5 tesla MRI system. A three dimensional technique was employed for image acquisition, allowing reconstruction of 1 mm thick slices. Minimum thickness of the medial temporal

lobe was measured on axial temporal lobe oriented images 20° caudal to the orbito-meatal line.³ Hippocampal height, width of the choroid fissure, and width of the temporal horn were measured in the coronal plane according to Scheltens *et al*.⁴ All measurements were made by a single observer, blind to clinical diagnosis, on T1 weighted images. Only the right or left measurement indicating greater atrophy was considered for each subject.

Minimum thickness of the medial temporal lobe for all controls fell between the 5th and 95th centiles of normal values (figure). On average, all measures indicated greater atrophy in patients with Alzheimer's disease (12.0 (2.2) v 13.7 (1.8) mm in controls; $t = 2.97$; $p = 0.005$ for minimum thickness of the medial temporal lobe, 12.6 (2.2) v 14.2 (1.4) mm; $t = 3.07$; $p = 0.004$ for hippocampal height, 4.9 (1.6) v 3.0 (1.4) mm; $t = 4.26$; $p < 0.0005$ for width of the choroid fissure, 6.8 (2.0) v 3.8 (1.4) mm; $t = 6.30$; $p < 0.0005$ for width of the temporal horn). Overlapping was considerable for the first measure, however, and less pronounced for the other measures (figure).

To take into account the effect of age on atrophy, measurements were transformed into multiples of the median (MoM); observed/expected value as computed with linear regression on controls.³ The best value of MoM discriminating patients with Alzheimer's disease from controls and the relative expected sensitivity were then computed by fitting a gaussian model to patients with Alzheimer's disease and controls with specificity set to 95%. Jobst *et al*³ have shown that in their sample a cut off of 0.79 MoM for minimum thickness of the medial temporal lobe gave an expected sensitivity of 92%. In our less severely demented patients, we found a similar cut off of 0.80 MoM for 95% specificity, but the expected sensitivity was only 30%. Expected sensitivity was higher for hippocampal height (39%, cut off 0.84 MoM), width of the choroid fissure (40%, cut off 1.71 MoM), and width of the temporal horn (72%, cut



Measures of medial temporal lobe atrophy in relation to age. Full circles: patients with Alzheimer's disease ($n = 26$); open circles: controls ($n = 21$). Dotted lines = cut off values for 95% specificity. Solid lines = 5th to 95th centile distribution of minimum thickness of the medial temporal lobe for normal controls according to Jobst, *et al*.³

off 1.49 MoM). When all measures were included in a discriminant function with stepwise selection of variables, hippocampal height, width of the choroid fissure, and width of the temporal horn alone allowed correct classification of 22 of 26 cases (85% sensitivity) and 20 of 21 controls (95% specificity).

Our data suggest that measures of medial temporal lobe atrophy focusing more precisely on the hippocampus might be useful aids in the diagnosis of Alzheimer's disease even in the early stages of the disease.

GIOVANNI B FRISONI
ANGELO BIANCHETTI
CRISTINA GEROLDI
MARCIO TRABUCCHI

*Alzheimer's Disease Unit,
Istituto S Cuore-FBF and Geriatric Research Group,
Brescia, Italy*

ALBERTO BELTRAMELLO
CLAUDIA WEISS
*Institute of Radiology,
University of Verona,
Verona, Italy*

- 1 McKhann G, Drachman D, Folstein MF, Katzman R, Price D, Stadlan EM. Clinical diagnosis of Alzheimer's disease: report of the NINCDS-ADRDA Work Group. *Neurology* 1984;34:939-44.
- 2 Kazee AM, Eskin TA, Lapham LW, et al. Clinicopathologic correlates in Alzheimer Disease: assessment of clinical and pathologic diagnostic criteria. *Alzheimer Dis Assoc Disord* 1993;7:152-64.
- 3 Jobst KA, Smith AD, Szatmari M, et al. Detection in life of confirmed Alzheimer's disease using a simple measurement of medial temporal lobe atrophy by computed tomography. *Lancet* 1992;340:1179-83.
- 4 Scheltens Ph, Leys D, Barkhof F, et al. Atrophy of medial temporal lobes on MRI in "probable" Alzheimer's disease and normal ageing: diagnostic value and neuropsychological correlates. *J Neurol Neurosurg Psychiatry* 1992;55:967-72.
- 5 Binetti G, Magni E, Padovani A, Cappa SF, Bianchetti A, Trabucchi M. Neuropsychological heterogeneity in mild Alzheimer's disease. *Dementia* 1993;4:321-6.

Reversible cortical oedema mimicking cortical dysplasia in mitochondrial disorder

Partial seizures are invariably associated with focal brain pathology. Optimised MRI in the evaluation of these patients for surgery has greatly improved the detection of a spectrum of lesions. Imaging findings, however, are not always specific for a particular pathology, and may transiently mimic a fixed structural lesion.

We briefly report the clinical and laboratory findings of a patient who has had occipital lobe epilepsy since the age of 18. Seizures consisted of frequent and prolonged visual auras (hallucinations, palinopsia, photopsias) followed by reversible but progressive visual loss, as well as complex partial and secondary generalised seizures. Clinical findings were short stature, severe hearing and visual loss, mild ataxia, and dysarthria. The patient's mother had had a stroke at the age of 34 followed by seizures and dementia.

Visual evoked potentials showed abnormal latencies. Monitoring with EEG showed non-specific interictal slowing of background rhythms and focal seizures arising from left and right occipital lobes.

A mitochondrial cytopathy was confirmed by the presence of ragged red fibres and abnormal mitochondrial ultrastructure in the muscle biopsy.

Magnetic resonance imaging during a

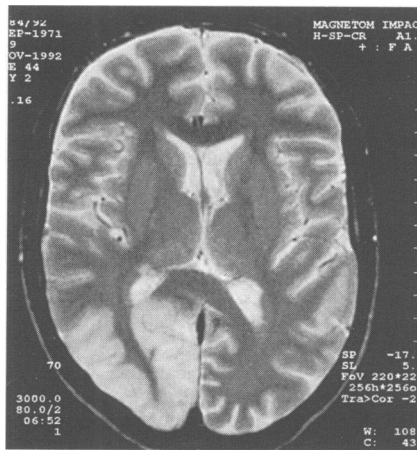


Figure 1 Axial T2 weighted MRI obtained during period of increased seizure activity shows widened cortex ribbon due to increased signal of the right occipital cortex and subcortical white matter.

period of increased seizure activity showed thickening of the cortical ribbon of the right parieto-occipital cortex in T1 weighted images. Increased signal was seen in the T2 weighted sequences (fig 1). A diagnosis of cortical dysplasia was considered and the patient was referred to our centre for surgical evaluation. Repeat MRI five months later no longer showed the lesion (fig 2). Retrospectively, it became apparent that the abnormality was due to transient cortical oedema associated with focal status epilepticus and not a fixed structural pathology of the cortex.

Reversible cortical abnormalities have been shown by MRI in generalised and partial status epilepticus.¹⁻³ The appearance may be misdiagnosed as a neoplasm or ischaemic stroke if the transient nature and temporal relation to status epilepticus is not recognised.^{6,7} The unusual linear and pericortical extent of the reversible signal abnormality in our patient led to the initial

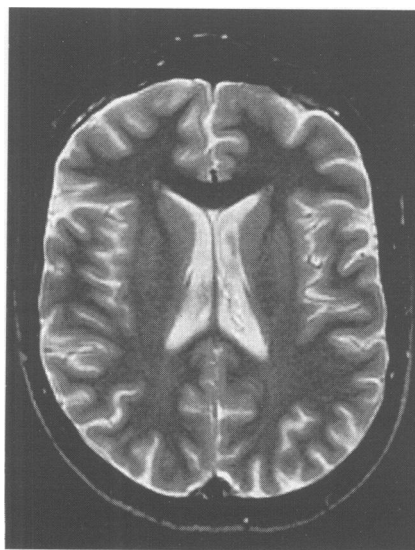


Figure 2 Follow up MRI five months later shows resolution of area of focal oedema present in fig 1.

misdiagnosis of a migrational disorder and the patient was referred for evaluation for surgery for epilepsy. Further investigation showed a mitochondrial disorder in our patient and the transient cortical oedema may indeed be secondary to altered cerebral energy metabolism and the pathogenetic mechanisms causing severe seizures in this condition.^{4,5} This case report illustrates that transient functional MRI abnormalities may mimic fixed structural lesions.

We gratefully thank Professor Einhäupl and Dr Ludolph, Universitätsklinikum Charité, Berlin; Dr Findeis and Dr Hecker, Hoffnungstaler Anstalten, Lobetal; and Dr Zierske, Universitätsklinik und Poliklinik für Epileptologie, Bonn for providing valuable diagnostic and imaging information.

INGRID TUXHORN
HANS HOLTHAUSEN
ALOIS EBNER
*Epilepsy Centre Bethel,
Department of Presurgical Diagnostics, Mara I,
Maraweg 21,
D-33617 Bielefeld, Germany*
SOHEYL NOACHTAR
*Neurologische Klinik und Poliklinik,
Klinikum Großhadern,
Ludwig-Maximilians-Universität,
Marchioninistraße 15,
D-81377 München, Germany*

- 1 Callahan D, Noetzel M. Prolonged absence status epilepticus associated with carbamazepine therapy, increased intracranial pressure, and transient MRI abnormalities. *Neurology* 1992;42:2198-201.
- 2 Sammaritano M, Andermann F, Melanson D, et al. Prolonged focal cerebral edema associated with partial status epilepticus. *Epilepsia* 1985;26:334-9.
- 3 Kramer RE, Lüders H, Lesser RP, et al. Transient focal abnormalities of neuroimaging studies during focal status epilepticus. *Epilepsia* 1987;28:528-32.
- 4 Rosen L, Phillips S, Enzmann D. Magnetic resonance imaging in MELAS syndrome. *Neuroradiology* 1990;32:168-71.
- 5 Abe K, Inui T, Hirono N, Mezaki T, Kobayashi Y, Kameyama M. Fluctuating MR images with mitochondrial encephalopathy, lactic acidosis, stroke-like syndrome (MELAS). *Neuroradiology* 1990;32:77.
- 6 Montagna P, Gallassi R, Medori R, et al. MELAS syndrome: characteristic migrainous and epileptic features and maternal transmission. *Neurology* 1988;38:751-4.
- 7 Dvorkin GS, Andermann F, Carpenter S, et al. Classical migraine, intractable epilepsy and multiple strokes: a syndrome related to mitochondrial encephalomyopathy. In: Andermann F, Lugaresi E, eds. *Migraine and epilepsy*. Stoneham: Butterworth Publishers, 1987:203-32.

Absence of SCA1 mutation in idiopathic cerebellar ataxia

Idiopathic cerebellar ataxia refers to a group of sporadically occurring cerebellar degenerations of unknown aetiology, which are clinically characterised by progressive ataxia with an onset in adult life.¹ Neuro-pathological and clinical studies suggest that there are at least two types of idiopathic cerebellar ataxia. One group of patients presents with additional non-cerebellar symptoms, such as parkinsonism, autonomic failure, and pyramidal symptoms (idiopathic cerebellar ataxia-P). The underlying pathology in many of these patients is olivopontocerebellar atrophy.² Those patients with idiopathic cerebellar ataxia-P who develop severe autonomic failure are subsumed under the broader category of multiple system atrophy.³ The other group of patients is clinically characterised by a pure