

SHORT REPORT

## Functional experiential hallucinosis after radiotherapy for nasopharyngeal carcinoma

Linda C W Lam, S F Leung, L Y Chow

**Abstract**

**Objective**—To consider the relation between functional experiential hallucinosis and brain injury induced by radiotherapy.

**Methods**—Single case report.

**Results**—A female patient presented with a four year history of functional experiential hallucinosis after two courses of radiotherapy for nasopharyngeal carcinoma. Brain MRI showed hyperintense changes over the left temporal lobe.

**Conclusion**— It is proposed that the hallucinosis was causally related to temporal lobe injury, a documented late complication of radiotherapy for nasopharyngeal carcinoma.

(*J Neurol Neurosurg Psychiatry* 1998;64:259–261)

Keywords: organic hallucinosis; radiotherapy; nasopharyngeal carcinoma

Hallucinatory experiences have been reported in some psychiatric and medical conditions. Organic hallucinosis refers to the occurrence of hallucinations in clear consciousness with identifiable physical aetiologies. A special form of hallucinosis, experiential hallucinosis (re-enactment of previous experience in the absence of external stimuli), had been reported by Penfield and Perot in artificial electrical stimulation of the temporal lobes.<sup>1</sup> Although such experiential phenomena have not been well replicated by later authors,<sup>2–4</sup> abnormalities in the temporal lobes, thalamus, and brainstem area were reported to be associated with the occurrence of experiential hallucinosis.<sup>5–7</sup>

Functional hallucinosis, hallucinations occurring in the presence of a simultaneous stimulus, is uncommon. The potential importance is yet to be identified.<sup>8</sup> We report on a patient who developed functional experiential hallucinosis after a second course of radiotherapy for nasopharyngeal carcinoma. The possible mechanism of experiential hallucinosis and the role of suspected brain pathology are discussed.

**Case history**

A 39 year old female manufacturing worker experienced auditory hallucinosis after radiotherapy for nasopharyngeal carcinoma. She came from a background with a strong predis-

position for mental illness. Her father and two younger brothers, both with a history of psychotic disorders, committed suicide. Two other surviving brothers were also suspected of being mentally ill. One was described as having fluctuating mood states with alternating periods of elation and depression; the other was reported to be socially withdrawn with persecutory ideation. Both refused psychiatric assessment and no formal psychiatric diagnosis had been made. Our patient was apparently well with no abnormal psychological experiences and psychiatric history.

She presented in 1987 with a few months history of bloodstained postnasal discharge and a left upper neck mass. Subsequent investigations led to the diagnosis of nasopharyngeal carcinoma. Staging CT showed that the primary tumour had extended to the paranasopharyngeal region but there was no skull base or intracranial involvement. She was treated with two courses of neoadjuvant chemotherapy consisting of 1g/m<sup>2</sup> 5-fluorouracil from day 1 to 5 repeated three weeks apart followed by a full course of external radiotherapy. The superior margin of the radiation portals included the inferior portions of the temporal lobes which received a dose of about 56Gy in 29 fractions over 43 days. On completion of treatment there was no evidence of residual disease.

At a follow up visit two and a half years later, recurrent cancer at the nasal cavity was diagnosed. The recurrent tumour extended to the pterygomaxillary fissure, but there was otherwise no skull base or intracranial involvement. A second course of external radiotherapy was given, and a tiny portion of the inferior-most part of the right temporal lobe received a dose of 60Gy in 30 fractions over 40 days. The tumour had regressed completely on completion of treatment. Follow up CT of the nasopharynx and the brain six months later did not show any evidence of disease.

Eighteen months after the second course of radiotherapy, she started to have occasional strange experiences of hearing noises and voices that she had heard before, when she turned on the washing machine at home. The voices were of similar themes, but dissimilar in content. The details were unclear and described as excerpts of broadcasting television programmes with the same background music, which started as soon as the washing machine

**Department of Psychiatry**  
L C W Lam  
L Y Chow

**Department of Clinical Oncology, Chinese University of Hong Kong**  
S F Leung

Correspondence to:  
Dr Linda CW Lam,  
Department of Psychiatry,  
11/F, Prince of Wales  
Hospital, Shatin, Hong  
Kong. Fax 00852 26462284.

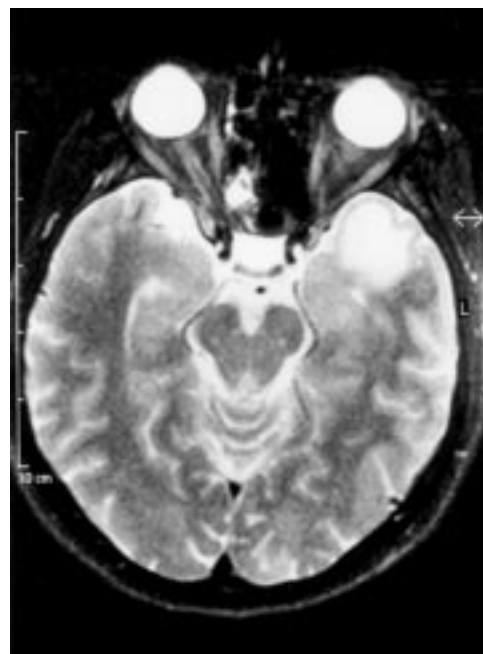
Received 9 January 1997 and  
in revised form 18 April  
1997

Accepted 9 July 1997

was on. The duration normally lasted some 10 minutes and stopped when the washing machine was turned off. Occasionally, the noises from the exhaust fan also elicited similar background voices from the television. She did not experience any other abnormal voices outside her flat or when the machines were off. On the first few occasions, she was convinced that the voices were real and looked for the source. The patient was fully alert when she heard the voices; she could recollect the whole experience and differentiate the background machinery noises and the superimposed voices. Distinct symptoms of seizure attacks such as aura, clouding of consciousness, convulsion, abnormal movements, incontinence, or tongue biting had never been experienced. No other abnormal perceptual experience, preoccupation, and psychotic experience was elicited. The patient also complained of forgetfulness for the past two years. She thought that her old memory was as good as before but she forgot new things easily. She remained in close contact with her friends and relatives.

Mental state examination disclosed that the patient was forthcoming and cooperative. Affective response was well preserved. No formal thought disorder and active psychotic feature could be elicited during repeated interviews. She was aware of the “imaginary” nature of the voices and doubted whether she was mentally ill. However, she thought that her problem might be different from that of her brothers because she did not feel being plotted against and was not emotionally disturbed by the voices. Cognitive examination showed that she was fully oriented. The Rey auditory verbal learning test was performed. Out of a list of 15 items recalled on five trials, she could recall five, seven, eight, eight, and eight items consecutively. In the recognition task performed after a delay of 20 minutes, she could recognise 10 out of 15 items. Her performance was about 1–2 SD below the average values.<sup>9</sup> The learning phase apparently plateaued off early as she could not recall more than eight items after the third trial. A formal test on autobiographical memory was not available. Comprehensive clinical interview disclosed that she could recite most of her personal information and medical history, a significant proportion of which was confirmed subsequently by the attending oncologist. Physical examination disclosed no significant hearing deficit or communication difficulty during ordinary conversation.

Repeat CT at three years, four years, and five years after the second course of radiotherapy showed no evidence of recurrence of nasopharyngeal carcinoma or cerebral abnormality. Brain MRI six years after the second course of radiotherapy showed no definite evidence of tumour recurrence, but hyperintense changes were detected in the left temporal lobe on a T2 weighted sequence (figure). EEG performed around the same time showed paroxysmal runs of diffuse delta activities with no definite abnormal focus. Sleep polysomnography was not carried out.



MRI showing left temporal hyperintense changes.

### Discussion

Experiential phenomena typically comprise past experience re-enacted in a person's mind with compelling vividness that could be described as “interpretive”.<sup>4</sup> The most commonly described perceptual experiential phenomena involve both visual and auditory forms. The contents are usually familiar, although specific details may not be identifiable. Artificial electrical stimulation of the cerebral cortex by Penfield and Perot activated research interest into the mechanism of experiential phenomena and its relation with temporal lobe functions.<sup>1</sup>

Our patient reported experience of auditory hallucinosis with characteristics of experiential phenomenon. The modality was specifically auditory, the perception was vivid. Although the details were fragmentary, the content was familiar and recognised as past encounters of excerpts from television programmes. These characteristic experiential phenomena were implicated in epilepsy, especially those associated with temporal lobe disorders. As the patient had received two courses of external radiotherapy for the treatment of nasopharyngeal carcinoma with the inferiormost parts of the temporal lobe included in the irradiation zone, she was at risk of developing temporal lobe injury. The cumulative radiation dose was sufficient to cause changes in the temporal lobes evident on imaging.<sup>10</sup> Although CT monitoring was unrevealing, the hyperintensity of the left temporal lobe detected by MRI and the slow activities in the EEG suggested that subtle brain pathology had occurred. The latent period between onset of hallucinosis and radiotherapy was also compatible with the timing of onset of post-irradiation cerebral injury.<sup>11</sup> We therefore postulate that the abnormal psychological experience was actually a manifestation of underlying damage to the temporal lobes. The impaired performance in memory

tests also hinted at the presence of underlying brain disorder, especially in the mesial temporal and diencephalic structures. Although autobiographical memory may be affected as a result of anterior temporal lobe pathology, subtle impairment is often very difficult to ascertain. Regarding the differential diagnosis, temporal lobe epilepsy with perceptual disturbance could be considered. The patient presented with isolated auditory hallucinations in the absence of other associated features of seizure attack, so the diagnosis of organic hallucinosis seems to be more appropriate. Other psychiatric disorders characterised by the presence of hallucination were also considered. Our patient had no other psychiatric symptoms to suggest the diagnosis of schizophrenia or mood disorder. However, with a strong family history of psychotic illness, constitutional susceptibility may be an important factor predisposing to the development of hallucinatory experience when brain insult occurs.

Several hypotheses have been put forward to explain the mechanism of experiential phenomena, which include removal of inhibitory control from higher centres proposed by Jackson<sup>12</sup> and abnormal electrical discharges initiating activation of the physiological mechanisms and a replay of past experience represented in the temporal cortex proposed by Penfield.<sup>1</sup> Halgren *et al* suggest that affect laden material is channelled into consciousness when inhibitory control from limbic structures has been disrupted by epileptic discharges.<sup>2</sup> Gloor *et al*, based on the concepts of parallel distributed processing and neural networks, proposed that these phenomena are positive expressions of temporal lobe and limbic functions.<sup>3</sup> Epileptic activities or electrical stimulation of the temporal lobes induce an elaborate pattern of excitation and inhibition in a widely distributed neuronal network, which is potentially capable of producing a specific matrix representing the substrate of a given experience. With the neural network model, Gloor *et al*<sup>3</sup> proposed that activation of a fragment of the network is capable of reproducing the representation of a total experience. Our patient described precise experience of hallucinosis with simultaneous perception of elementary noises from the washing machine. The noises might be a triggering stimulus that erroneously initiated patterns of representation of the “voices” that were experienced.

The abnormal psychic experience reported by our patient accents the importance of atten-

tion to neuropsychiatric symptoms of patients after treatment of nasopharyngeal carcinoma. It is the only commonly occurring extracranial malignancy of which cerebral tissues are often irradiated during treatment. With increasing awareness for diagnosing the disease at its early stage, and with an increasing number of long term survivors, delayed effects of radiation to the temporal lobes are being recognised. However, diagnosis is mostly radiological and neuropsychiatric manifestations are seldom reported.<sup>13 14</sup> Our patient presented initially with mental symptoms, whereas radiological evidence of temporal lobe abnormalities only showed up four years later. Psychiatric manifestations may represent the herald and could be a useful clinical indicator for radiation induced temporal lobe injury. This opens another dimension for the study of the potential complications of temporal lobe injury after treatment of nasopharyngeal carcinoma by radiotherapy.

- 1 Penfield W, Perot P. The brain's record of auditory and visual experience. A final summary and discussion. *Brain* 1963;**86**:595–696.
- 2 Halgren E, Walter RD, Cherlow DG, *et al*. Mental phenomenon evoked by human electrical stimulation of the human hippocampal formation and amygdala. *Brain* 1978;**101**:83–117.
- 3 Gloor P, Olivier A, Quesney LF, *et al*. The role of the limbic system in experiential phenomena of temporal lobe epilepsy. *Annals of Neurology*, 1982;**12**:129–144.
- 4 Gloor P. Experiential phenomena of temporal lobe epilepsy. *Brain* 1990;**113**:1673–1694.
- 5 Feiberg WM, Rapsak SZ. Peduncular hallucinosis after paramedian thalamic infarction. *Neurology* 1989;**39**:1535–6.
- 6 Catafau JS, Rubio F, Seera JP. Peduncular hallucinosis associated with posterior thalamic infarction. *J Neurol* 1992;**239**:89–90.
- 7 Noda S, Mizoguchi M, Yamamoto A. Thalamic experiential hallucinosis. *J Neurol Neurosurg Psychiatry* 1993;**56**:1224–6.
- 8 Sims A. *Symptoms in the mind—an introduction to descriptive psychopathology*, 2nd ed. London: Saunders, 1995:75–100.
- 9 Geffen G, Hoar KJ, O'Hanlon AP, *et al*. Performance measures of 16- to 86-year-old males and females on the Auditory Verbal Learning Test. *Clinical Neuropsychologist* 1990;**4**:45–63.
- 10 Lee AWM, Ng SH, Ho JHC, *et al*. Clinical diagnosis of late temporal lobe necrosis following radiation therapy for nasopharyngeal carcinoma. *Cancer* 1988;**61**:1535–42.
- 11 Leung SF, KreeL L, Tsao SY. Asymptomatic temporal lobe injury after radiotherapy for nasopharyngeal carcinoma: incidence and determinants. *Br J Radiol* 1992;**65**:710–4.
- 12 Jackson JH. Lectures on the diagnosis of epilepsy. Lecture III. *Medical Times and Gazette*, 1879;**1**:141–3. (Reprinted in: J Taylor, ed. *Selected writings of John Hughlings Jackson*. Vol 1. *On epilepsy and epileptiform convulsions*. New York: Basic Books, 1958:295–307.)
- 13 Parkin AJ, Hunkin NM. Memory loss following radiotherapy for nasopharyngeal carcinoma—an unusual presentation of amnesia. *Br J Clin Psychol* 1991;**30**:349–57.
- 14 Chu CC, Huang CC, Chen HJ. Kliver Bucy syndrome: report of a case with nasopharyngeal cancer after irradiation and chemotherapy. *Chinese Medical Journal (Taipei)* 1994;**54**:432–5.