LESSON OF THE MONTH

Ataxia with isolated vitamin E deficiency presenting as mutation negative Friedreich's ataxia

S R Hammans, C R Kennedy

Abstract

Ataxia with vitamin E deficiency is an autosomal recessive condition associated with a defect in the α-tocopherol transfer protein. Clinically it manifests as a progressive ataxia with a phenotype resembling that of Friedreich's ataxia. There is some evidence that progression of neurological symptoms is prevented by vitamin E therapy. A patient is described who was given a clinical diagnosis of Friedreich's ataxia. Molecular genetic analysis showed the absence of the frataxin gene expansion. Subsequent vitamin E assay showed deficiency and a diagnosis of ataxia with vitamin E deficiency was made. It is recommended that all patients with ataxia of unknown cause should have vitamin E deficiency excluded. When a diagnosis of Friedreich's ataxia is considered patients should have frataxin analysis in addition. Further, neurologists should be aware that ataxia with vitamin E deficiency may present as "mutation negative" Friedreich's ataxia.

(*J Neurol Neurosurg Psychiatry* 1998;**64**:368–370)

Keywords: Friedreich's ataxia; ataxia with isolated vitamin E deficiency; tocopherol

During 1996 Campuzano *et al* identified the molecular genetic basis of Friedreich's ataxia.[1] Analysis of a series of 79 unrelated patients showed that 95% of disease alleles carried an expanded GAA repeat in the first intron of a gene, since termed frataxin. This allows a simple molecular diagnostic test in most patients, now widely available. The phenotype is wider than previously defined clinically,[2 3] but nearly all patients with typical clinical features of Friedreich's ataxia are homozygous or heterozygous for the mutation. A few patients fall into a new category of neurological referral—those with a clinical diagnosis of "mutation negative" Friedreich's ataxia. Perhaps the most important alternative diagnosis is ataxia with isolated vitamin E deficiency.

Case report

A 16 year old girl was referred with a previous clinical diagnosis of Friedreich's ataxia. Her parents first thought her to be clumsy at the age of 6. Her unsteadiness worsened and her family practitioner was consulted when she was 8. After further progression a diagnosis of Friedreich's ataxia was made at the age of 13. There was no relevant family history, no parental consanguinity, and no gastrointestinal symptoms. On examination she had a mild thoracic scoliosis, titubation of the head, gait and limb ataxia, areflexia, upgoing plantar responses, and dysarthria. Nerve conduction studies showed sensory action potentials close to the lower limit of normal (sural SAP 6 μV, median 8 μV) but were otherwise unremarkable. Evoked potentials elicited from the posterior tibial nerve were bilaterally delayed; visual and brainstem auditory evoked potentials were normal. The figure shows her electrocardiogram. She fulfilled the clinical criteria for diagnosis of Friedreich's ataxia suggested by Harding.[2]

When it became available, molecular genetic analysis of the frataxin gene was performed; no abnormal triplet expansion was found. Assay of vitamin E concentrations measured 2.9 and 5.3 μmol/l (normal range 11.6–37.1 μmol/l) on separate occasions; lipids were otherwise normal. A diagnosis of ataxia with isolated vitamin E deficiency was made and α-tocopheryl acetate therapy was started at 800 mg/day. Vitamin E concentrations returned to the normal range after eight weeks of treatment, but there was no objective change in her neurological state.

Discussion

Secondary vitamin E deficiency (precipitated by abetalipoproteinaemia or other fat malabsorptive states) is known to be associated with neurological manifestations including ataxia. In 1981 isolated vitamin E deficiency was described,[4] and this was followed by other reports. In these patients, without gastrointestinal disturbance, onset of symptoms typically occurs between 4 and 18 years of age, with progressive ataxia, areflexia, sensory loss, and pyramidal signs, and sometimes with cardiomyopathy.[5 6] Typically ataxia with isolated vitamin E deficiency masquerades as Friedreich's ataxia, with many patients fulfilling Harding's clinical criteria for Friedreich's ataxia. Clinical differences between the two disorders are subtle. However, most patients with ataxia with isolated vitamin E deficiency have preserved or slightly reduced sensory nerve action

Wessex Neurological Centre, Southampton General Hospital, Southampton, UK
S R Hammans
C R Kennedy

Correspondence to:
Dr S R Hammans, Wessex Neurological Centre, Southampton General Hospital, Southampton SO9 6YD, UK.

Received 8 July 1997 and in revised form 15 September 1997
Accepted 26 September 1997

J Neurol Neurosurg Psychiatry: first published as 10.1136/jnnp.64.3.368 on 1 March 1998. Downloaded from http://jnnp.bmj.com/ on October 17, 2021 by guest. Protected by copyright.

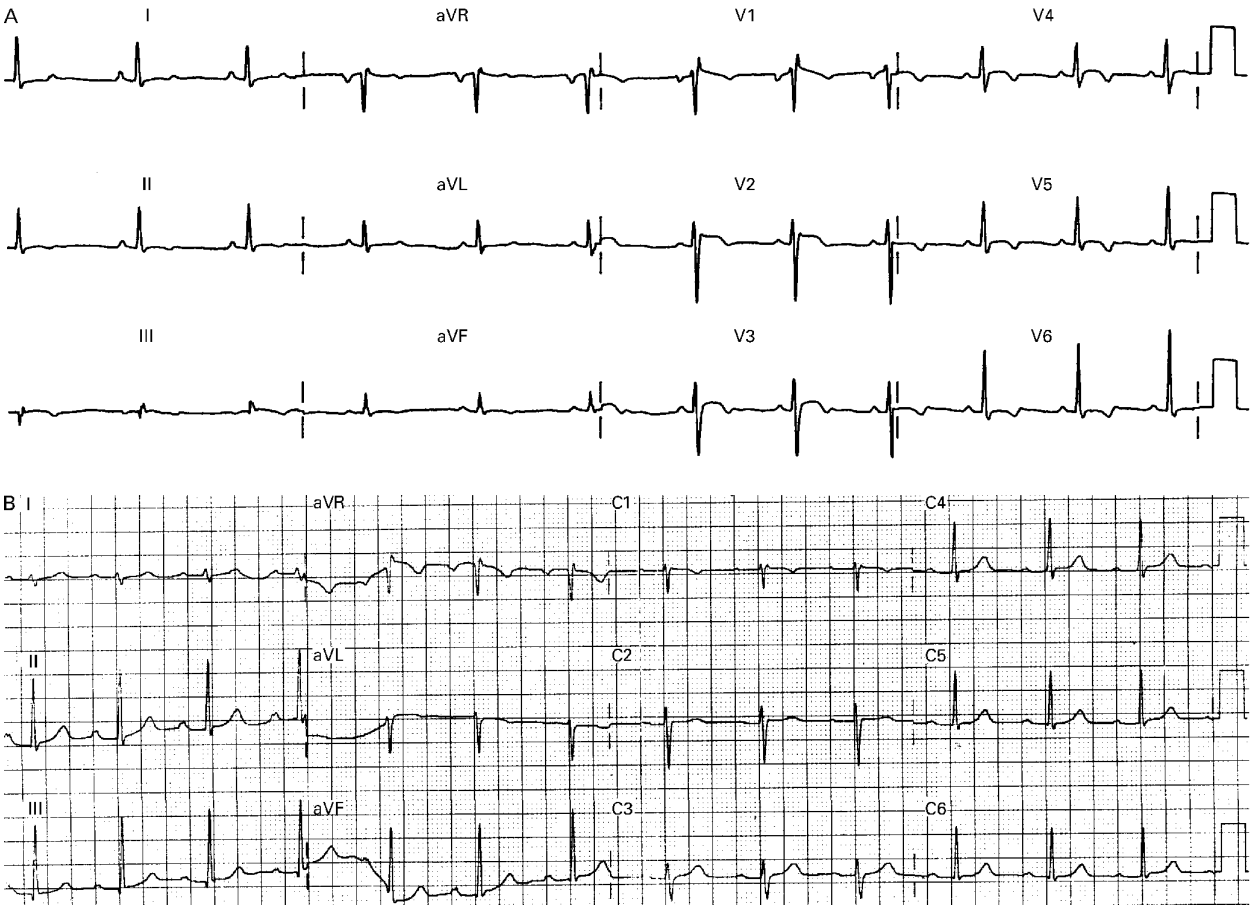

(A) Electrocardiogram showing the typical repolarisation changes in a patient with Friedreich's ataxia. (B) Electrocardiogram of our patient with ataxia with vitamin E deficiency with no repolarisation changes. The P-R interval is at the upper limit of normal (0.2 s).

potentials; By contrast, of 26 patients described by Harding 24 had at least one sensory action potential absent (usually all were absent).[2 6] Prominent titubation and hyperkinetic movements favour ataxia with isolated vitamin E deficiency, and some patients with this disease develop a pigmentary retinopathy which is not a clinical feature of Friedreich's ataxia.[6] Although a cardiomyopathy may occur in ataxia with isolated vitamin E deficiency, a systematic comparison with the characteristic cardiomyopathy of Friedreich's ataxia is still awaited.

Whereas ataxia with isolated vitamin E deficiency is relatively common in the Mediterranean basin, it seems to be rare in northern Europe. In 1995 Ouahchi *et al* identified mutations in the α-tocopherol transfer protein (α-TTP) on chromosome 8 in patients with ataxia with isolated vitamin E deficiency.[7] Patients with this disease absorb dietary α-tocopherol, and incorporate it into chylomicrons normally. Abnormal α-TTP function prevents transfer of α-tocopherol to very low density lipoproteins secreted by the liver, and therefore impairs delivery to peripheral tissues. Patients have low plasma vitamin E and show abnormally rapid clearance of tocopherol from plasma.[8] They require about 800 mg/day of α-tocopheryl acetate to return plasma vitamin E concentrations to those seen in normal subjects taking an equivalent supplement. Even after prolonged supplementation, cessation of therapy results in a profound decline in plasma tocopherol concentrations within 72 hours, suggesting that supplementation may need to be continued indefinitely. The clinical effects of α-tocopheryl acetate therapy have not been widely studied. Amiel *et al* followed up a family with ataxia with isolated vitamin E deficiency on supplementation for five years.[9] Some improvement was noted in a mildly affected patient, but only a small benefit in a patient with more advanced disability. Two presymptomatic siblings on supplementation remained asymptomatic. Two patients, one on therapy for 15 months[10] and one for seven months,[11] showed minor improvement. Further follow up data are awaited to determine long term prognosis on supplementation. Nevertheless, the limited data available to date suggest that oral supplementation is advisable in both symptomatic and presymptomatic patients and may prevent progression of disability.

We suggest that all patients with progressive ataxia of unknown cause should have vitamin E assayed. This should be performed with frataxin studies in patients in whom the diagnosis of Friedreich's ataxia is considered. Further, any patient with a clinical diagnosis of Friedreich's ataxia with negative mutation analysis should have vitamin E measured. The widespread use of frataxin analysis may identify similar patients to ours. Awareness of ataxia with isolated vitamin E deficiency with early and precise diagnosis will allow the best opportunity for successful vitamin E supplementation.

J Neurol Neurosurg Psychiatry: first published as 10.1136/jnnp.64.3.368 on 1 March 1998. Downloaded from http://jnnp.bmj.com/ on October 17, 2021 by guest. Protected by copyright.

1 Campuzano V, Montermini L, Molto MD, *et al*. Friedreich's ataxia: autosomal recessive disease caused by an intronic GAA triplet repeat expansion. *Science* 1996;**271**:1423–7.
2 Harding AE. Friedreich's ataxia: a clinical and genetic study of 90 families with an analysis of early diagnostic criteria and intrafamilial clustering of clinical features. *Brain* 1981; **104**:589–620.
3 Durr A, Cossee M, Agid Y, *et al*. Clinical and genetic abnormalities in patients with Friedreich's ataxia. *N Engl J Med* 1996;**335**:1169–75.
4 Burck U, Goebel HH, Kuhlendahl HD, *et al*. Neuromyopathy and vitamin E deficency in man. *Neuropaediatrics* 1981; **12**:267–78.
5 Ben Hamida M, Belal S, Sirugo G, *et al*. Friedreich's ataxia phenotype not linked to chromosome 9 and associated with selective autosomal recessive vitamin E deficiency in two inbred Tunisian families. *Neurology* 1993;**43**:2179–83.
6 Belal S, Hentati F, Ben Hamida C, *et al*. Friedreich's ataxia-vitamin E responsive type. *Clin Neurosci* 1995;**3**:39–42.
7 Ouahchi K, Arita M, Kayden H, *et al*. Ataxia with isolated vitamin E deficiency is caused by mutations in the α-tocopherol transfer protein. *Nat Genet* 1995;**9**:141–5.
8 Traber MG, Sokol RJ, Burton GW, *et al*. Impaired ability of patients with familial isolated vitamin E deficiency to incorporate α-tocopherol into lipoproteins secreted by the liver. *J Clin Invest* 1990;**85**:397–407.
9 Amiel J, Maziel JC, Beucler I, *et al*. Familial isolated vitamin deficiency. Extensive study of a large family with a 5-year therapeutic follow up. *J Inher Metab Dis* 1995;**18**: 333–40.
10 Harding AE, Matthews S, Jones S, *et al*. Spinocerebellar degeneration associated with a selective defect of vitamin E absorption. *N Engl J Med* 1985;**313**:32–35.
11 Gotoda T, Arita M, Arai H, *et al*. Adult-onset spinocerebellar dysfunction caused by a mutation in the gene for the α-tocopherol- transfer protein. *N Engl J Med* 1995;**333**: 1313–8.

J Neurol Neurosurg Psychiatry: first published as 10.1136/jnnp.64.3.368 on 1 March 1998. Downloaded from http://jnnp.bmj.com/ on October 17, 2021 by guest. Protected by copyright.