

Functional magnetic resonance imaging of human brain activity in a verbal fluency task

R Schlösser, M Hutchinson, S Joseffer, H Rusinek, A Saarimaki, J Stevenson, S L Dewey, J D Brodie

Abstract

Objectives—Functional MRI (fMRI) holds the promise of non-invasive mapping of human brain function in both health and disease. Yet its sensitivity and reliability for mapping higher cognitive function are still being determined. Using verbal fluency as a task, the objective was to ascertain the consistency of fMRI on a conventional scanner for determining the anatomic substrate of language between subjects and between sexes. Comparison was made with previous PET studies.

Methods—Using a 1.5 Tesla magnet and an echoplanar pulse sequence, whole brain fMRI was obtained from 12 normal right handed subjects (6 males and 6 females) as they performed a verbal fluency task.

Results—A broadly consistent pattern of response was seen across subjects. Areas showing activation changes included the left prefrontal cortex and right cerebellum, in agreement with previous PET ^{15}O - H_2O studies. In addition, significantly decreased responses were seen in the posterior cingulate and over an extensive area of mesial and dorsolateral parietal and superior temporal cortices. The male cohort showed a slight asymmetry of parietal deactivation, with more involvement on the right, whereas the female cohort showed a small region of activation in the right orbitofrontal cortex. There were individual task related regional changes in all 12 subjects with the area showing the most significant change being the left prefrontal cortex in all cases.

Conclusions—Magnetic resonance scanners of conventional field strength can provide functional brain mapping data with a sensitivity at least that of PET. Activation was seen in left prefrontal and right cerebellar regions, as with PET. However, decremental responses were seen over a much larger area of the posterior cortex than had been anticipated by prior studies. The ability to see a response in each subject individually suggests that fMRI may be useful in the preinterventional mapping of pathological states, and offers a non-invasive alternative to the Wada test for assessment of hemispheric dominance. There were no gross differences in the pattern of activation between male and female subjects.

Keywords: verbal fluency; sex; functional magnetic resonance imaging (fMRI)

Verbal fluency tasks are sensitive indicators of function in the frontal cortex.¹ In the past decade, brain imaging techniques have made possible the in vivo visualisation of areas engaged in language. PET studies using the flow tracer ^{15}O - H_2O in verbal fluency tasks have consistently shown activation of the dorsolateral prefrontal cortex as well as variable deactivation in temporal areas and in the posterior cingulate.^{2,3} Temporal areas have also been activated in other studies of word generation and retrieval.^{4,5} Additionally, cerebellar activation during silent speech ideation has been found in studies of verbal activation.⁶ More recently, verbal fluency tasks have been investigated using functional MRI (fMRI). Activation of the left frontal cortex (including Broca's region, premotor cortex, and dorsolateral prefrontal cortex) in normal subjects has been examined in this way.⁷ For patient groups, significantly lower activation of the left frontal cortex and higher activation of the left temporal areas have been reported.⁸ Although the feasibility of imaging cortical activation during a word generation task has been shown, most studies have included only a limited number of slices⁷⁻⁹ requiring the use of a priori assumptions about the loci of activation.¹⁰ An early study by Rueckert *et al*, using echoplanar pulse sequences and a related word generation paradigm in six subjects with a 4T multislice fMRI instrument and region of interest analysis strategy, showed the feasibility of observing cortical representations of word generation.¹¹

The first aim of the present study, therefore, was to determine the feasibility of whole brain fMRI for language mapping on a clinical scanner. A second, related, aim was to investigate the consistency of activation in terms of cortical localisation. Thirdly, the question of whether sex differences exist in the functional organisation of the brain was explored. We sought to investigate a long held hypothesis^{12,13} which argues that language functions are more lateralised in male than in female subjects. Attempts to show this to date have been inconclusive.

Subjects and methods

SUBJECTS

Six male and six female right handed, native English speaking normal volunteers were recruited from the student population of New York University Medical Center. The subjects were homogeneous for age (mean age 23, range

Department of
Psychiatry
R Schlösser
S Joseffer
J D Brodie

Department of
Neurology
M Hutchinson

Department of
Radiology
H Rusinek
J Stevenson

General Clinical
Research Center, New
York University
Medical Center, 550 1st
Avenue, New York,
USA
A Saarimaki

Chemistry
Department,
Brookhaven National,
Laboratory, Upton,
New York 10973, USA
S L Dewey

Correspondence to:
Dr Jonathan D Brodie,
Department of Psychiatry,
NYU Medical Center, 550
First Avenue, New York, NY
10016, USA. Telephone 001
212 263 6365.

Received 23 April 1997 and
in final revised form 2
October 1997
Accepted 8 October 1997

(J Neurol Neurosurg Psychiatry 1998;64:492-498)

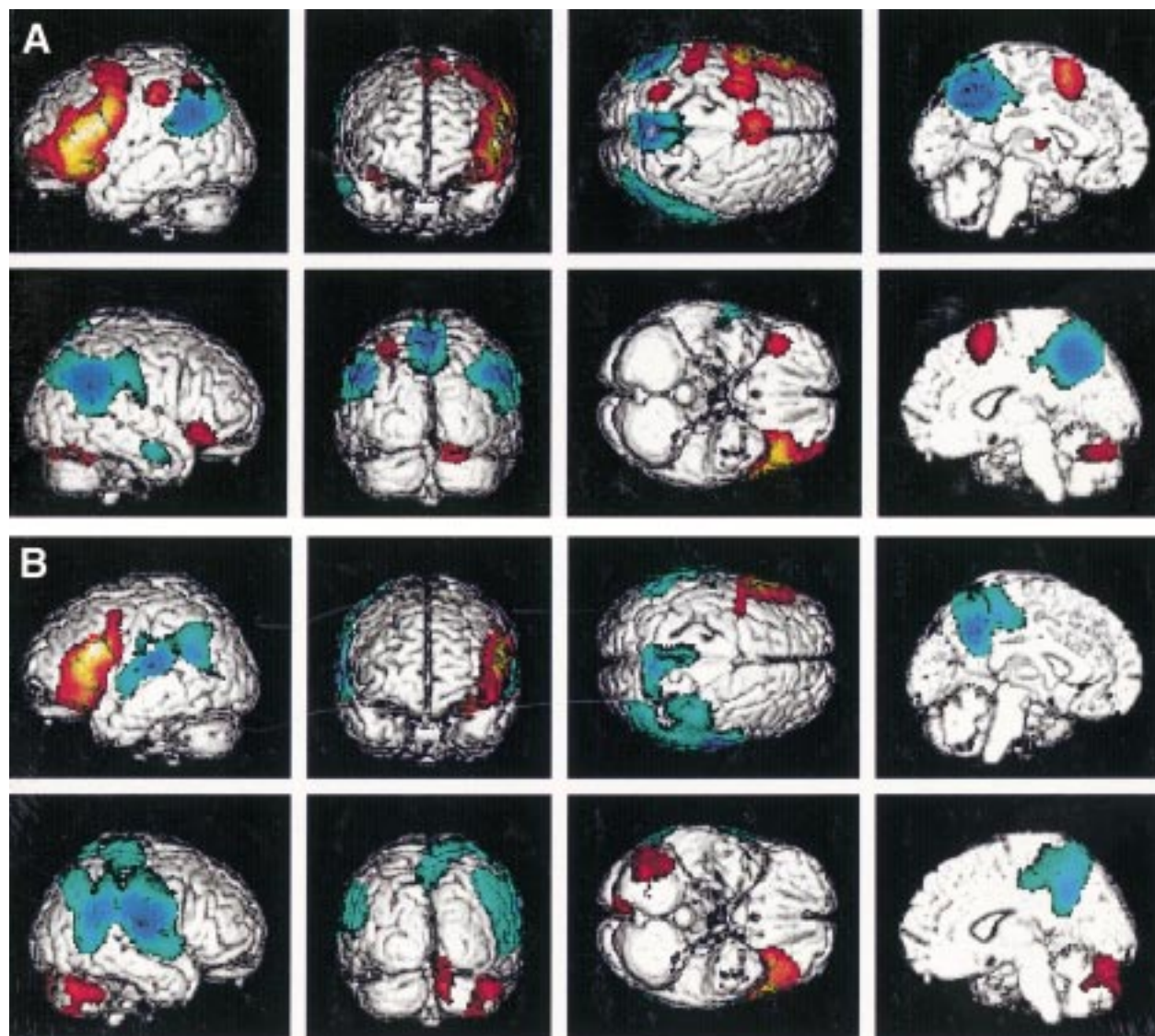


Figure 1 (A) Activation/deactivation changes in the verbal fluency task for the female cohort: combined data from the six female subjects showing areas of change in verbal fluency compared with a baseline task of forward counting. Red scale represents increments and blue scale decrements in activation. Each individual brain was transformed into standard Talairach coordinates and SPM analysis applied to the grouped data in this standard space. The results are displayed on a cortical rendering of the standard Talairach brain, and are represented as a probability map that the observed changes could have arisen by chance. Shown in colour are those areas for probability $p < 0.001$ in height (uncorrected) and $p < 0.05$ in extent (corrected). (B) Activation/deactivation changes in the verbal fluency task for the male cohort: significance and colour scale are the same as in (A).

22–26) and years of education. Handedness was examined by a modified version of the Edinburgh handedness inventory. The study was performed according to the guidelines of the internal review board of New York University Medical Center and all subjects gave written informed consent.

METHODS

The functional studies were performed on a 1.5 Tesla SIEMENS Magnetom (Vision) using echoplanar imaging sequences and head coils. Head immobilisation was established by head pads and a firm chin strap to immobilise the head in flexion-extension. Sixteen transverse slices of 6 mm thickness and 1.5 mm gap were obtained. Functional images were acquired with TR=5 seconds, matrix size 128×128, field of view=20 mm. Slice thickness was mainly determined by technical constraints (largely computer memory related) which did not allow

the acquired data set to exceed a 128×128×16×100 spatiotemporal matrix. As we intended to depict functional connectivity and therefore needed simultaneous imaging of the whole brain, we decided to use a slice thickness of 6 mm with a 1.5 mm gap.

Previous studies have investigated the difference between silent and audible language tasks. Significantly more activated pixels and fewer artifacts were detected with silent word generation than with word generation aloud,¹⁴ presumably because there was less head motion. Verbal fluency therefore, was tested by silent performance of a verbal fluency task. During each scan, a series of 100 sequential acquisitions were obtained. Whole brain (16 slice) images were collected every five seconds. Each study was divided into 10 epochs of 50 seconds each, resulting in a total study length of eight minutes and 20 seconds. The five baseline and five activation conditions were arranged in an

alternating sequence, starting with baseline. During the baseline condition, subjects were asked to count forward, starting with the number 1, at a rate of about one a second. During activation epochs, volunteers generated words starting with letters that were spoken to them over the intercom. The letters for the five activation conditions were F,A,S,T, and N, respectively. Word generation and counting were performed at a self paced rate without vocalisation. To ensure compliance, each subject was debriefed after the scan and asked to give examples of words that they had generated in each category.

DATA ANALYSIS

The data were analysed with statistical parametric mapping (SPM96 from the Wellcome Department of Cognitive Neurology, London, UK) implemented in MATLAB (Mathworks Inc, Sherborn MA, USA) on a SUN Sparc 5 workstation. Statistical parametric maps are representations of spatially extended processes that characterise regionally specific effects in imaging.^{15, 16} All fMRI was coregistered to correct for head movement.¹⁷ Transformation into a standard stereotactic anatomical space^{17, 18} was performed to compensate for differences in brain size and shape. To improve signal to noise ratio and to correct for interindividual differences in the anatomy of the brain, the images were smoothed with a 15 mm FWHM Gaussian kernel. The choice of the appropriate smoothing kernel is largely empirical as it is dependent on the extent of activation.¹⁹ The function of smoothing is to increase the signal to noise ratio by reducing the noise. If the activated area is large it is best demonstrated with a large kernel. If the activated area is small, however, a large kernel will reduce the apparent signal. We examined 18 smoothing kernels between 2 mm and 20 mm for the grouped data, and chose 15 mm as the kernel that best showed both activation and decremental responses. The dimensions of the normalised brain voxel are 2×2×4 mm; this normalisation allows for the localisation of significant regions in terms of standard stereotactic coordinates. Temporal smoothing with a 2.8 second Gaussian kernel served as a high frequency filter. Additional high pass filtering with a cut off of 0.5 cycles/minute was performed.

A global normalisation of the data was rendered through an analysis of covariance. The expected response function of the fMRI signal over the time of the experiment was modelled by a delayed box car function. The condition effects were estimated according to the general linear model at each voxel.¹⁹ The resulting set of voxel values for each contrast constitutes a statistical parametric map of the t statistic $SPM(t)$. The $SPM(t)$ was transformed to the unit normal distribution ($SPM\{Z\}$) and thresholded at $Z=3.09$ (uncorrected). The resulting foci were then characterised in terms of spatial extent (k) and peak height (u). The significance of each region was estimated using distribution approximations from the theory of Gaussian fields. This characterisation is in terms of the probability that a region of the

observed number of voxels (or greater) could have occurred by chance (extent threshold), or that the peak height found (or higher) could have occurred by chance (height threshold) over the entire volume analysed.^{20, 21} We did not set up a factorial design to test for group×condition interactions as the current statistical implementation of SPM does not allow for this kind of analysis. The results of the two group analyses, as well as the individual data, were displayed as cortical surface renderings on a standard stereotactic brain using the SPM96 cortical rendering algorithm.

Results

Figure 1 displays the probability maps of the group average of six female brains (fig 1 A) and six male brains (fig 1 B). Regions showing significantly increased activation during word generation are displayed in red scale, whereas regions showing significantly decreased activation are shown in blue scale. In both groups, areas of significant activation include the left prefrontal cortex and right cerebellum. Significant decreases in activation are seen in mesial and dorsolateral parietal cortex bilaterally. It is in the context of these areas of significant activation that slight sex differences present themselves; the male cohort's decremental activations extending downward to the superior temporal gyrus bilaterally and the female cohort displaying significant increases of activation in small areas of the left dorsal parietal and right orbitofrontal cortices.

Visual inspection of figures 2 and 3 discloses a relatively stable localisation of the broad areas of involvement (left prefrontal and bilateral parietal cortex) across subjects. This contrasts with a large between subject variability in the statistical significance of the signal changes. The area showing the most significant task dependent change in all 12 of these right handed subjects is the left prefrontal cortex. Considerable between subject variance can be seen for right frontal activation in the female group. Only two subjects show significant activation in this area in a single subject analysis, and these two subjects seem to weight the contribution to the right frontal activation found in the female cohort.

Discussion

By demonstrating a robust response to a verbal fluency task in each of 12 normal subjects, we have shown the potential for reliable brain mapping of the functional organisation of language on a conventional MRI scanner. The task related signal changes seen in the association cortex using echoplanar imaging were of the order of 1%—that is, of a similar magnitude to the changes seen when using non-echoplanar (spin echo) sequences for detecting activation of the primary visual cortex,²² where activation was detected only when assiduous efforts were made to constrain the head in flexion-extension.

Flexion-extension movement of the head due to respiration is an important physiological source of noise, as it imposes random differences in spin excitation histories and

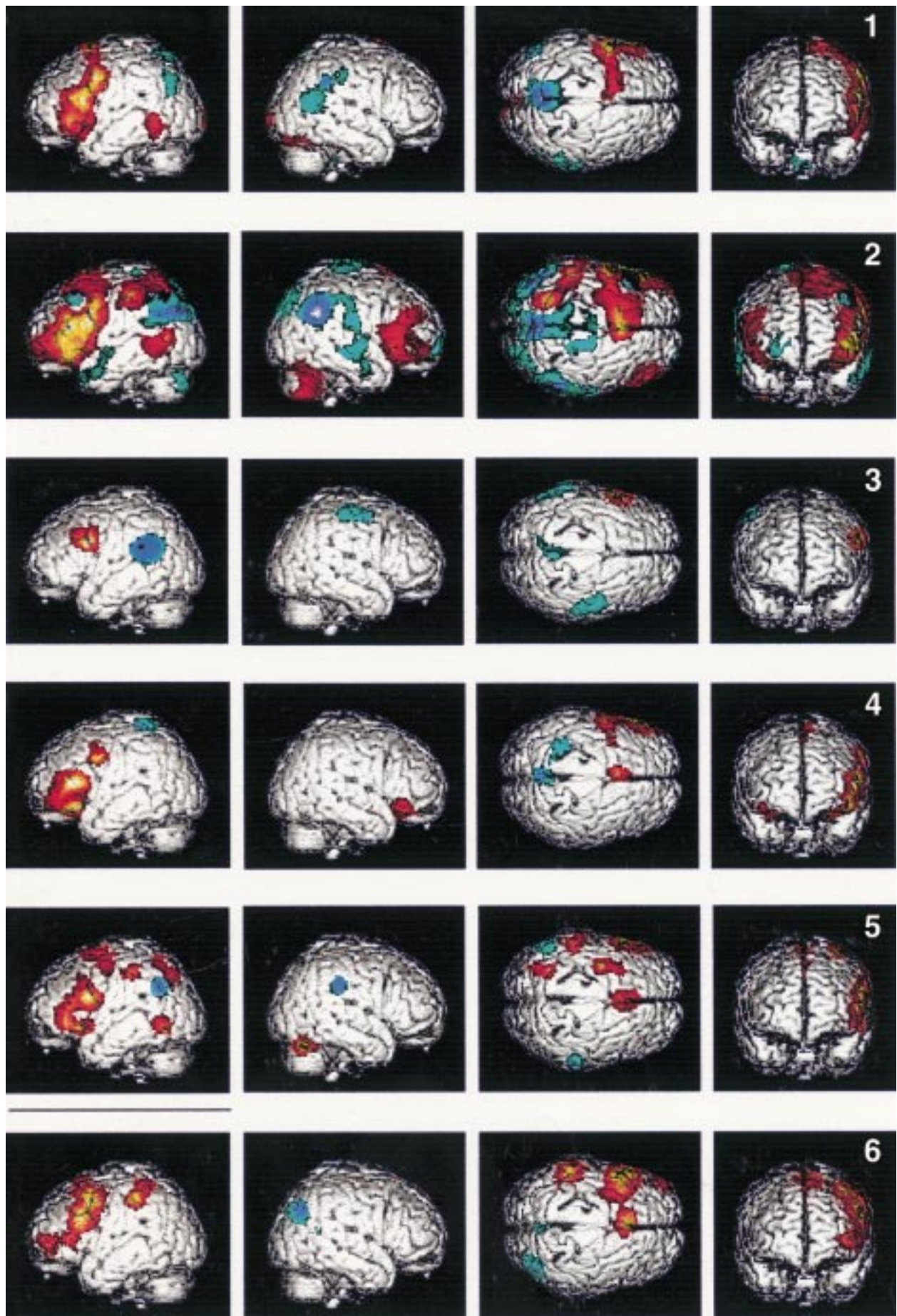


Figure 2 Individual cortical renderings for the female cohort: note the difference in significance represented by the colour scale. Subjects 3 and 6 were evaluated at a height threshold of $p < 0.01$ (uncorrected), all other subjects at $p < 0.001$ (uncorrected).

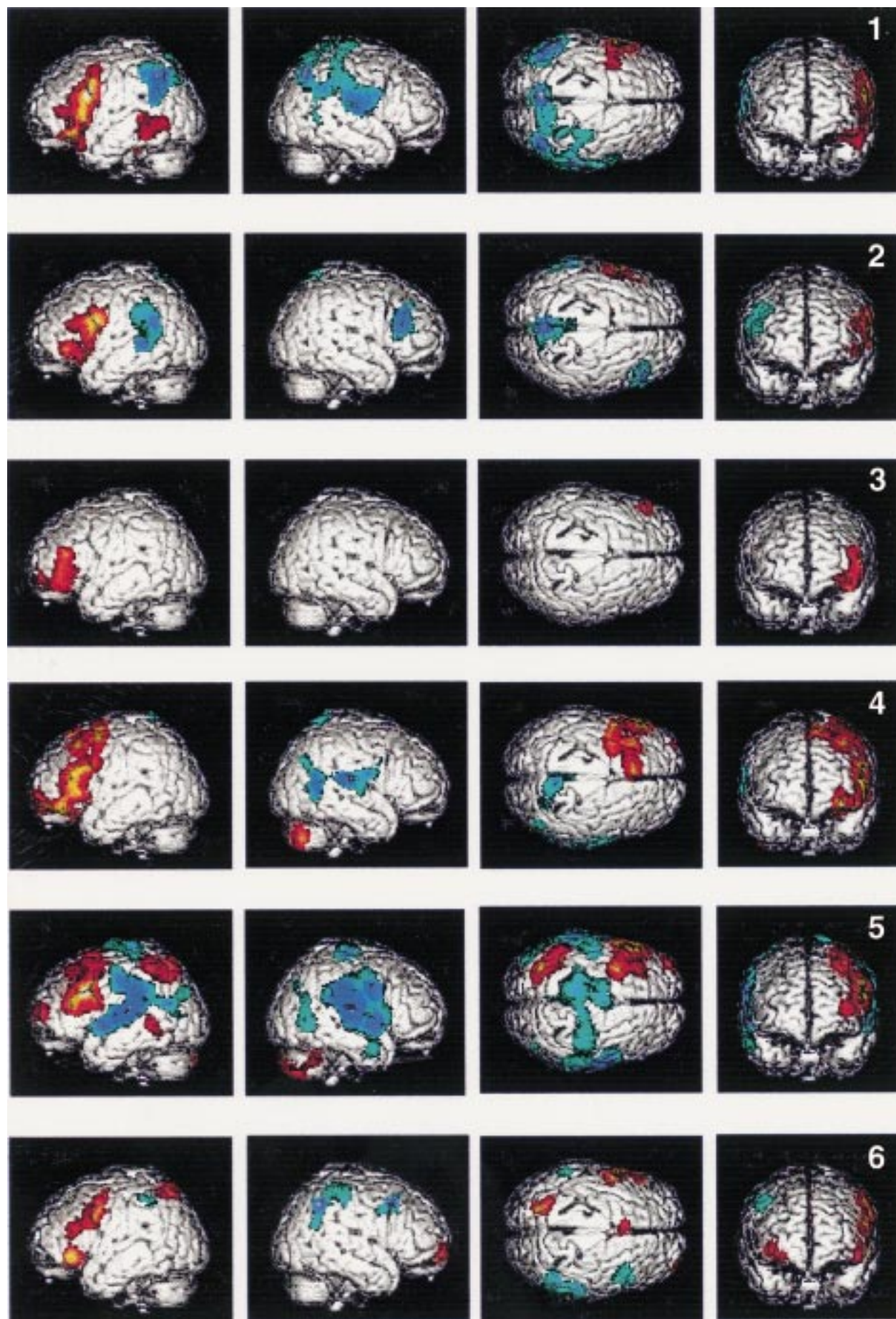


Figure 3 Individual cortical renderings for the male cohort. Subjects 2 and 3 were evaluated at a height threshold of $p < 0.01$ (uncorrected), all other subjects: $p < 0.001$ (uncorrected).

Table 1 Female subjects (n=6), p values, and statistics

| Area | Cluster level | | | Voxel level | | | x (mm) | y (mm) | z (mm) |
|---------------------------------------|---------------|------|------|-------------|------|-----|--------|--------|--------|
| | p | k | Z | p | Z | Z | | | |
| Increases in activation: | | | | | | | | | |
| Left prefrontal cortex | 0.000 | 9522 | 7.75 | 0.000 | 7.75 | -52 | 30 | 12 | |
| | | | | 0.000 | 7.73 | -48 | 8 | 26 | |
| | | | | 0.000 | 7.64 | -48 | 14 | 20 | |
| Mesial frontal cortex (SMA) | 0.000 | 1168 | 7.20 | 0.000 | 7.20 | -4 | 14 | 56 | |
| Left dorsolateral parietal cortex | 0.008 | 541 | 5.12 | 0.003 | 5.12 | -50 | -30 | 44 | |
| | | | | 0.090 | 4.34 | -42 | -34 | 42 | |
| Right orbitofrontal cortex | 0.010 | 450 | 5.03 | 0.005 | 5.03 | 38 | 24 | -8 | |
| Left dorsal parietal cortex | 0.011 | 370 | 5.01 | 0.006 | 5.01 | -24 | -56 | 52 | |
| Right cerebellum | 0.007 | 631 | 4.54 | 0.042 | 4.54 | 24 | -70 | -24 | |
| | | | | 0.113 | 4.28 | 22 | -62 | -22 | |
| | | | | 0.348 | 3.93 | 32 | -56 | -26 | |
| Decreases in activation: | | | | | | | | | |
| Left and right mesial parietal cortex | 0.000 | 5853 | 7.29 | 0.000 | 7.29 | 4 | -54 | 48 | |
| | | | | 0.000 | 5.91 | -8 | -44 | 44 | |
| | | | | 0.028 | 4.64 | -10 | -36 | 50 | |
| Left dorsolateral parietal cortex | 0.000 | 2896 | 6.61 | 0.000 | 6.61 | -50 | -64 | 36 | |
| | | | | 0.000 | 6.20 | -44 | -50 | 28 | |
| | | | | 0.000 | 6.00 | -44 | -58 | 30 | |
| Right dorsolateral parietal cortex | 0.000 | 5574 | 5.71 | 0.000 | 5.71 | 54 | -60 | 34 | |
| | | | | 0.000 | 5.67 | 58 | -52 | 24 | |
| | | | | 0.000 | 5.62 | 46 | -48 | 26 | |
| Right middle temporal gyrus | 0.034 | 394 | 4.18 | 0.160 | 4.18 | 64 | -4 | -24 | |
| | | | | 0.327 | 3.95 | 54 | -14 | -20 | |
| | | | | 0.333 | 3.94 | 64 | 2 | -30 | |

p=Corrected p values for spatial extent (cluster level p value) and peak height (voxel level p value) of the activation: all areas exceeding the corrected cluster level threshold of 0.05 are displayed; k=number of voxels in cluster; Z=z score; x, y, z=localisation according to the standard Talairach coordinates.

introduces systematic coherence into the data. The slice thickness (6 mm) was chosen to acquire data from the entire brain. Larger slice thickness might create partial volume effects with white matter and could exacerbate susceptibility induced image artifacts. The use of a relatively large gap (1.5 mm) has the advantage of minimising excitation from adja-

cent slices, but may reduce the precision of image alignment.

The lack of direct control for task performance is a problem common to many fMRI studies, in which direct feedback could compromise the quality of the acquired data set. Task compliance in this study was confirmed by debriefing all subjects immediately after the

Table 2 Male subjects (n=6), p values, and statistics

| Area | Cluster level | | | Voxel level | | | x (mm) | y (mm) | z (mm) |
|---|---------------|------|------|-------------|------|-----|--------|--------|--------|
| | p | k | Z | p | Z | Z | | | |
| Increases in activation: | | | | | | | | | |
| Left prefrontal cortex | 0.000 | 7129 | 7.63 | 0.000 | 7.63 | -48 | 14 | 26 | |
| | | | | 0.000 | 7.36 | -46 | 28 | 20 | |
| | | | | 0.000 | 5.90 | -6 | 18 | 50 | |
| Left dorsal parietal cortex | 0.003 | 875 | 5.28 | 0.001 | 5.28 | -24 | -66 | 58 | |
| | | | | 0.002 | 5.16 | -24 | -58 | 54 | |
| | | | | 0.188 | 4.11 | -28 | -48 | 54 | |
| Right cerebellum | 0.038 | 390 | 3.85 | 0.399 | 3.85 | 38 | -56 | -38 | |
| | | | | 0.459 | 3.79 | 48 | -64 | -34 | |
| | | | | 0.817 | 3.46 | 34 | -76 | -50 | |
| Decreases in activation: | | | | | | | | | |
| Right mesial parietal cortex | 0.000 | 9748 | 6.82 | 0.000 | 6.82 | 66 | -16 | 12 | |
| | | | | 0.000 | 6.42 | 66 | -16 | 24 | |
| | | | | 0.000 | 6.32 | 64 | -18 | 32 | |
| Left inferior parietal/superior temporal cortex | 0.000 | 4852 | 6.60 | 0.000 | 6.60 | -6 | -46 | 46 | |
| | | | | 0.000 | 6.59 | -4 | -38 | 48 | |
| | | | | 0.000 | 6.57 | -2 | -48 | 38 | |
| Right/left dorsolateral parietal cortex | 0.000 | 3228 | 5.44 | 0.001 | 5.44 | -54 | -56 | 24 | |
| | | | | 0.003 | 5.10 | -56 | -54 | 36 | |
| | | | | 0.009 | 4.89 | -68 | -32 | 30 | |

p=Corrected p values for spatial extent (cluster level p value) and peak height (voxel level p value) of the activation: all areas exceeding the corrected cluster level threshold of 0.05 are displayed; k=number of voxels in cluster; Z=z score; x, y, z=localisation according to the standard Talairach coordinates.

study and by showing that the region specific acquired signal in all subjects followed the box car design of the instructions. Previous studies have shown that silent word generation produces a signal that is apparently greater than when the task is verbalised.¹⁴ This might be due to the fact that verbalisation decreases significance by increasing noise through task correlated head motion.²³ Although an independent measure of verbal fluency and its relation to signal characteristics is highly desirable, simple vocalisation might not be such an obvious choice considering the complexity of brain involvement in the mechanics of speech production.

Despite the inherent limitations of the current technique, the consistency of left prefrontal cortical activation across subjects is noteworthy and is in broad agreement with previously published PET studies using SPM methodology.²⁴ That the full extent of the activation found in the current study was not suggested by this previous work is a confirmation of the sensitivity of fMRI at conventional field strength.

In addition, we found decremental responses in mesial and dorsolateral parietal cortex bilaterally during the activation task. Areas of deactivation were also seen in previous PET studies, represented in the posterior cingulate gyrus and bilateral superior temporal gyrus.³ Whereas we cannot say that the posterior cingulate is not involved, our results suggest a much broader posterior area of deactivation than was previously detected.³ We are currently investigating the physiological basis for this apparent suppression. Interestingly, in the male cohort, this area descends to include the superior temporal gyrus, in agreement with the prior PET studies in which four right handed male subjects were used. However, this area did not seem to be involved in the female cohort, although a small area of decremental response can be seen in the right middle temporal gyrus (fig 2).

Apart from the small differences between the two groups, tables 1 and 2 and figures 2 and 3 disclose an impressive consistency of activation areas across all subjects (the functional anatomy is conserved). As also reported by Binder *et al*,²⁵ the robustness of localisation of the response across subjects suggests that fMRI using a simple language task may provide a non-invasive alternative to Wada testing of language lateralisation in presurgical patients. In contrast, the significance of the response in terms of the height of the statistical parametric map shows a pronounced variation across subjects (the degree of response is not conserved).

Sex differences have been postulated in the functional organisation of language at the level of phonological processing.²⁶ In our study, we could find only slight differences between men and women. The female cohort showed a small area of activation in the right orbitofrontal cortex and mesial frontal cortex not seen in the male cohort. On the other hand, the male cohort showed a decremental response in the posterior superior temporal gyrus as well as an asymmetry in the parietal decrement, with a greater area of involvement of the right parietal

convexity, compared with the left. The significance of these slight group differences is unclear, and it is emphasised that the two cohorts show similar patterns, characterised by left prefrontal and right cerebellar activation, as well as bilateral dorsolateral and mesial parietal deactivation. Overall, the similarity of the patterns of the two cohorts is quite striking, which supports the popular notion that verbal fluency is likely not to be the factor to best discriminate performance based on sex.

The efforts reported in this paper were supported in part by grants MH 47277, MH 49165, and NCR RR MO1 RR-0096 from the NIH, a Stanley Fellowship Award to SJ, and Schl 400/1-1 from the DFG. We are particularly grateful for the expert assistance of Wynne Schiffer.

- Janowsky JS, Shimamura AP, Squire LR. Source memory impairment in patients with frontal lobe lesions. *Neuropsychologia* 1989;27:1043-56.
- Friston KJ, Frith CD, Liddle PF, *et al*. Investigating a network model of word generation with positron emission tomography. *Proc R Soc Lond B Biol Sci* 1991;244:101-6.
- Frith CD, Friston KJ, Liddle PF, *et al*. A PET study of word finding. *Neuropsychologia* 1991;29:1137-48.
- Wise R, Chollet F, Hadar U, *et al*. Distribution of cortical neural networks involved in word comprehension and word retrieval. *Brain* 1991;114:1803-17.
- Parks RW, Loewenstein DA, Dodrill KL, *et al*. Cerebral metabolic effects of a verbal fluency test: a PET scan study. *J Clin Exp Neuropsychol* 1988;10:565-75.
- Decety JH, Sijholm E, Ryding G, *et al*. The cerebellum participates in mental activity: tomographic measurements of regional cerebral blood flow. *Brain Res* 1990;535:313-7.
- Cuenod CA, Bookheimer SY, Hertz-Pannier L, *et al*. Functional MRI during word generation, using conventional equipment: a potential tool for language localisation in the clinical environment. *Neurology* 1995;45:1821-7.
- Yurgelun-Todd DA, Waternaux CM, Cohen BM, *et al*. Functional magnetic resonance imaging of schizophrenic patients and comparison subjects during word production. *Am J Psychiatry* 1996;153:200-5.
- McCarthy G, Blamire AM, Rothman DL, *et al*. Echo-planar magnetic resonance imaging studies of frontal cortex activation during word generation in humans. *Proc Natl Acad Sci U S A* 1993;90:4952-6.
- Hinke RM, Hu X, Stillman AK, *et al*. Functional magnetic resonance imaging of Broca's area during internal speech. *Neuroreport* 1993;4:675-8.
- Rueckert L, Appollonio I, Grafman J, *et al*. Magnetic resonance imaging functional activation of left frontal cortex during covert word production. *J Neuroimaging* 1994;4:67-70.
- LeVay S. *The sexual brain*. Cambridge, MA: MIT Press, 1993.
- Kimura D. Sex differences in the brain. *Sci Am* 1992;267:118-25.
- Yetkin FZ, Hammeke TA, Swanson SJ, *et al*. A comparison of functional MR activation patterns during silent and audible language tasks. *AJNR Am J Neuroradiol* 1994;16:1087-92.
- Friston KJ, Frith CD, Liddle PF, *et al*. Comparing functional (PET) images: the assessment of significant change. *J Cereb Blood Flow Metab* 1991;11:690-9.
- Worsley KJ, Evans AC, Marrett S, *et al*. A three-dimensional statistical analysis for CBF activation studies in human brain. *J Cereb Blood Flow Metab* 1992;12:900-18.
- Friston KJ, Ashburner J, Frith CD, *et al*. Spatial registration and normalization of images. *Human Brain Mapping* 1995;2:1-25.
- Talairach J, Tournoux P. *Co-planar stereotaxic atlas of the human brain*. Stuttgart: Thieme, 1988.
- Friston KJ, Holmes AP, Worsley KJ, *et al*. Statistical parametric maps in functional imaging: a general linear approach. *Human Brain Mapping* 1995;2:189-280.
- Friston KJ, Holmes A, Poline J-B, *et al*. Detecting activations in PET and fMRI: levels of inference and power. *Neuroimage* 1995;4:223-35.
- Friston KJ, Worsley KJ, Frackowiak RSJ, *et al*. Assessing the significance of focal activations using their spatial extent. *Human Brain Mapping* 1994;1:214-20.
- Hutchinson M, Rusinek H, Nenov VI, *et al*. Segmentation analysis in functional MRI: activation sensitivity and grey matter specificity of RARE and FLASH. *J Magn Reson Imaging* 1997;7:361-4.
- Friston KJ, Williams S, Howard R, *et al*. Movement-related effects in fMRI time-series. *Magn Reson Med* 1996;35:346-55.
- Frith CD, Friston K, Liddle PF, *et al*. Willed action and the prefrontal cortex in man: a study with PET. *Proc R Soc Lond B Biol Sci* 1991;244:241-6.
- Binder JR, Swanson SJ, Hammeke TA, *et al*. Determination of language dominance using functional MRI: a comparison with the Wada test. *Neurology* 1996;46:978-84.
- Shaywitz BA, Shaywitz SE, Pugh KR, *et al*. Sex differences in the functional organisation of the brain for language. *Nature* 1995;373:607-9.