

LETTERS TO THE EDITOR

Cerebral metabolism during vegetative state and after recovery to consciousness

One way to approach the study of consciousness is to explore lesional cases in which impairment of consciousness is the prominent clinical sign. Vegetative state is such a condition wherein awareness is abolished whereas arousal persists. It can be diagnosed clinically soon after a brain injury and may be reversible (as in the following case report) or progress to a persistent vegetative state or death. The distinction between vegetative state and persistent vegetative state is that the second is defined as a vegetative state that has continued or endured for at least 1 month.¹ We present a patient who developed a vegetative state after carbon monoxide poisoning and in whom we had the opportunity to measure brain glucose metabolism distribution during the vegetative state and after recovery to consciousness. Using [¹⁸F]fluorodeoxyglucose (FDG) PET and statistical parametric mapping (SPM) we compared both patient's sets to a normal control population. Our findings offer an insight into the neural correlates of "awareness", pointing to a critical role for posterior associative cortices in consciousness.

A 40 year old right handed woman attempted suicide through CO intoxication and was found unconscious. She was treated with hyperbaric oxygen but evolved to a vegetative state diagnosed according to the following criteria:¹ (1) spontaneous eye opening without evidence of awareness of the environment; (2) no evidence of reproducible voluntary behavioural responses to any stimuli; (3) no evidence of language comprehension or expression; (4) intermittent wakefulness and behaviourally assessed sleep-wake cycles; (5) normal cardiorespiratory function and blood pressure control; (6) preserved pupillary, oculocephalic, corneal, and vestibulo-ocular reflexes. Brain MRI performed 14 days after admission was normal. Electroencephalography showed a 6 Hz basal activity with more pronounced slowing on the left parietal regions. Auditory evoked potentials were normal. Somaesthetic evoked potentials of the median nerve showed

normal latency and amplitude of P14 and N20 potentials without any late cortical components. After remaining in a vegetative state for 19 days the patient regained consciousness. Her sequelae consisted of a bilateral spastic paresis of upper and lower limbs. Neuropsychological testing 1 month after admission showed an attention deficit with moderate impairment of short term memory. One year after the accident she showed a spastic gait with altered fine motor function, most prominent on the right, a slurred speech, and minor short term memory disturbances. FDG-PET was performed during the vegetative state (day 15 after admission) and after recovery to consciousness (day 37).

The control population consisted of 48 drug free, healthy volunteers, aged from 18 to 76 years (mean: 42 (SD 21) years).

The study was approved by the ethics committee of the University of Liège. Informed consent was obtained by the husband of the patient and for all control subjects. Five to 10 mCi FDG was injected intravenously; PET data were obtained on a Siemens CTI 951 R 16/31 scanner in bidimensional mode. Arterial blood samples were drawn during the whole procedure and cerebral metabolic glucose rates (CMRGlucose) were calculated for all subjects. PET data were analysed using SPM software (SPM96 version; Welcome Department of Cognitive Neurology, Institute of Neurology, London, UK).² The use of SPM to assess between subject (rather than within subject) variability is unlikely to alter the relevance of our results given their high degree of significance. Data from each subject were normalised to a standard stereotactic space and then smoothed with a 16 mm full width half maximum isotropic kernel. The analysis identified brain regions where glucose metabolism was significantly lower in each patient scan compared with the control group. The resulting foci were characterised in terms of peak height over the entire volume analysed at a threshold of corrected $p < 0.05$.²

During the vegetative state, average grey matter glucose metabolism was 38% lower than in controls (4.5 v 7.3 (SD 1.4) mg/100 g/min). No substantial change in mean CMRGlucose was found after recovery (4.7 mg/100 g/min). During the vegetative state, significant regional CMRGlucose decreases were found in the left and right superior parietal lobule; the left inferior parietal lobule; the precuneus; the left superior occipital, superior and middle temporal gyri; and the premotor and postcentral and precentral cortex (figure, yellow colour). After recovery, metabolic impairment was confined to the

left and right precentral and postcentral gyri and premotor cortices (figure, blue colour).

This case report offers an insight into the neural correlates of human consciousness (at least, external awareness as it can be assessed at the patient's bedside). Given that global glucose utilisation levels remained essentially the same, the recovery of consciousness seems related to a modification of the regional distribution of brain function rather than to the global resumption of cerebral metabolism. The main decreases in metabolism seen during the vegetative state but not after recovery were found in parietal areas, including the precuneus. This is in agreement with postmortem findings in persistent vegetative state, in which involvement of the association cortices is reported as a critical neuroanatomical substrate³ and with PET studies in postanoxic syndrome, in which the parieto-occipital cortex showed the most consistent impairment.⁴ The functions of these areas are manifold: lateral parietal areas are involved in spatial perception and attention, working memory, mental imagery, and language, whereas the precuneus is activated in episodic memory retrieval, modulation of visual perception by mental imagery, and attention.² Our data point to a critical role for these posterior associative cortices in the emergence of conscious experience.

STEVEN LAUREYS
CHRISTIAN LEMAIRE
PIERRE MAQUET

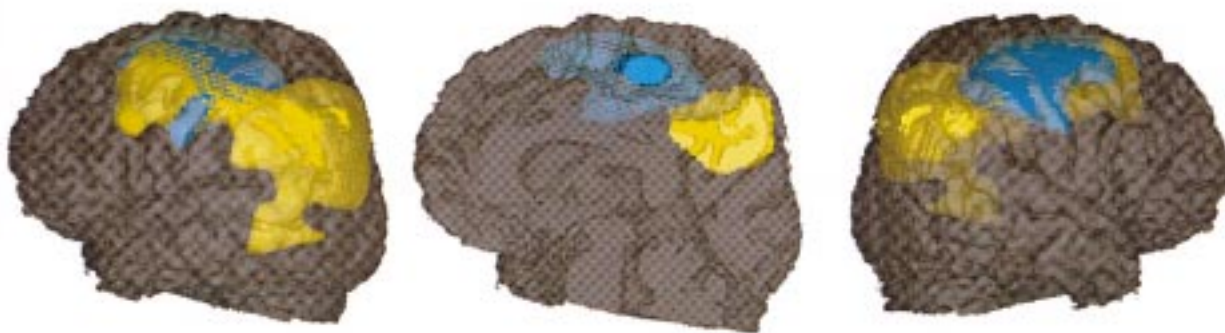
Cyclotron Research Centre, University of Liège, Sart Tilman, 4000 Liège, Belgium

CHRISTOPHE PHILLIPS
Institute of Cognitive Neurology, University College London, Alexandra House, 17 Queens Square, London WC1N3AR, England, UK

GEORGE FRANCK
Department of Neurology, CHU Liège Sart, Tilman B-35, 4000 Liège, Belgium

Correspondence to: Dr Pierre Maquet, Cyclotron Research Centre (B30), University of Liège, Sart Tilman, 4000 Liège, Belgium Telephone 0032 43 66 36 87; fax 0032 43 66 29 46; email maquet@pet.crc.ac.be

- 1 The Multi-Society Task Force on PVS. Medical aspects of the persistent vegetative state (1). *N Engl J Med* 1994;330:1499-508.
- 2 Frackowiak RSJ, Friston KJ, Frith CD, et al. *Human brain function*. San Diego: Academic Press, 1997.
- 3 Kinney HC, Samuels MA. Neuropathology of the persistent vegetative state: a review. *J Neuropathol Exp Neurol* 1994;53:548-58.
- 4 De Volder AG, Goffinet AM, Bol A, et al. Brain glucose metabolism in postanoxic syndrome. Positron emission tomographic study. *Arch Neurol* 1990;47:197-204.



Localisation of voxels in which cerebral glucose metabolism was impaired during vegetative state (in yellow) and after recovery to consciousness (in blue), compared with the control population. SPM_Z threshold was set at voxel level corrected $p < 0.05$ and projected on the patient's coregistered MRI, normalised to the stereotaxic space of Talairach.

Electrical inexcitability of nerves and muscles in severe infantile spinal muscular atrophy

Spinal muscular atrophy (SMA) is one of the most common fatal autosomal recessive disorders, characterised by progressive degeneration of anterior horn cells. Before the advent of genetic testing, the diagnosis of SMA was based on clinical, histopathological, and electrophysiological features. In 1992, the International SMA Consortium defined diagnostic criteria of proximal SMA based on clinical findings.¹ In SMA type I (severe; Werdnig-Hoffmann disease), affected persons have onset of symptoms before 6 months of age and are never able to sit without support. Electromyography demonstrates denervation features. In early 1995, the candidate gene, the survival motor neuron (SMN) gene, was identified, making the confirmation of SMA by DNA analysis possible.²

With the availability of a genetic test for SMA, many investigators are refining the diagnostic criteria published by the Consortium. Studies involving hundreds of patients with proximal SMA have disclosed a subset of patients who fulfill at least one exclusion criterion defined by the Consortium.³ We identified an infant with severe SMA who fulfilled two exclusion criteria and also showed inexcitability of all nerves as well as muscles. This report will further delineate the wide range of phenotypes for this particular gene mutation.

A 2945 g male infant was born at term. First fetal movements were noted at 13 weeks of gestation. Chorionic villus sampling at 10 weeks of gestation disclosed normal chromosomes. Decreased fetal movement and polyhydramnios were noted at about 34 weeks of gestation. At delivery, the infant was cyanotic with no respiratory effort and was subsequently intubated. On physical examination, the infant had no spontaneous movements. He opened his eyes with brief fixation but no following. Tongue fasciculations were present. Other cranial nerves seemed intact. Mild flexion contractures of both elbows, knees, and ankles were noted. Tone was flaccid in both upper and lower limbs, and there was no movement response to painful stimulus. Deep tendon reflexes were absent.

Brain MRI disclosed mild diffuse cortical and deep atrophy. His EMG was severely abnormal, with widespread fibrillations and absent voluntary motor units except in the genioglossus, where mildly neurogenic motor units with decreased recruitment were seen. Stimulation of the median, ulnar, tibial, and peroneal nerves with a maximal stimulus resulted in no clinical or electrical response. The biceps brachii and rectus femoris muscles were electrically inexcitable by direct needle stimulation. Median, ulnar, and sural sensory potentials were not obtainable. DNA testing showed a homozygous deletion of exons 7 and 8 in the telomeric SMN gene, confirming the diagnosis of SMA. The infant expired at 3 weeks of age, and the parents declined postmortem examination.

Typical EMG studies in those with SMA show fibrillations and fasciculations at rest and an increased mean duration and amplitude of motor units. Motor nerve conduction velocities may be slowed but are usually normal. Korinthenberg *et al* reported inexcitability of motor nerves in three siblings, each of whom died from SMA before 1 month of age.⁴ In addition to a homozygous deletion of

exons 7 and 8 of the telomeric SMN gene, all three siblings showed a large deletion in the region that includes all alleles of the multicopy markers Ag1-CA and C212, localised at the 5' end of the two SMN gene copies. It has been postulated that the severity of disease may be correlated to the extent of a deletion involving the SMN gene and the multicopy markers.³⁻⁵ The infant in our report with SMA type I showed electrical inexcitability of motor nerves as well as the characteristic alteration of the SMN gene.

Although it has been known for some time from histological studies that sensory systems are involved in SMA, electrophysiological sensory findings have been previously reported only once.⁴ Sensory nerve conduction velocity was tested in an infant with severe SMA and showed no recordable potential, but the infant in our report also exhibited universal absence of sensory potentials. In both cases, DNA analysis disclosed the 5q deletion. It is unclear whether this finding represents a distinct entity or merely the severe end of classic Werdnig-Hoffmann disease. The diagnostic criteria produced by the International SMA Consortium currently lists "abnormal sensory nerve action potentials" as an exclusion criterion.¹ Our finding of absent sensory potentials in a 5q deletion established case of SMA indicates further need for revision of the Consortium criteria.

Studies involving large series of patients with SMA have identified cases of SMA variants.³ These patients were diagnosed as infantile SMA by the presence of proximal weakness and atrophy, hypotonia, and evidence of neurogenic alterations in EMG and muscle biopsy. In addition, these patients also exhibited one of the exclusion criteria defined by the Consortium—for example, diaphragmatic weakness, involvement of the CNS, or arthrogryposis. Although these patients did not show the typical SMN deletion and were therefore probably not linked to chromosome 5q, they could have had point mutations. The infant in our report showed no respiratory effort after birth, indicating diaphragmatic weakness. He did, however, possess the characteristic SMN gene alterations. This finding suggests that diaphragmatic weakness should be reconsidered as an exclusion criterion by the Consortium.

Review of the literature disclosed no previous reports of electrically inexcitable muscles in SMA. This phenomenon is known to occur in a few other neuromuscular conditions such as periodic paralysis and critical illness polyneuropathy. Fibrillations, as seen in the infant in our report, are commonly seen in acute denervation and are thought to be caused by perturbation of the sarcolemmal membrane, rendering it unstable. One possibility may be that the severe denervation in SMA type I can result in abnormal function of the membrane to make it electrically inexcitable. Further electrophysiological studies at the cellular level are required to delineate this interesting finding.

ALICE A KUO

Department of Pediatrics

STEFAN-M PULST
DAWN S ELIASHIV
CAMERON R ADAMS

Division of Neurophysiology, Cedars-Sinai Medical Center, Los Angeles, CA, USA

Correspondence to: Dr Cameron R Adams, Department of Neurophysiology, Cedars-Sinai Medical Center, 8631 West Third Street, Room 1145, East Tower, Los Angeles, CA 90048, USA.

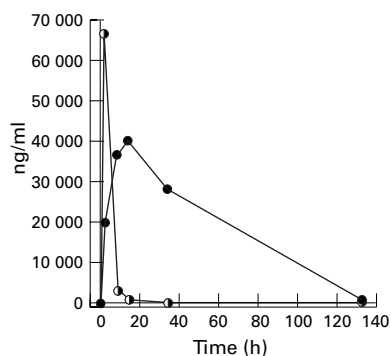
- 1 The International SMA consortium. Meeting report. *Neuromusc Disord* 1992;2:423-8.
- 2 Lefebvre S, Burglen L, Reboullet S, *et al*. Identification and characterization of spinal muscular atrophy-determining gene. *Cell* 1995;80:155-65.
- 3 Zerres K, Wirth B, and Rudnik-Schoneborn S. Spinal muscular atrophy-clinical and genetic correlations. *Neuromusc Disord* 1997;7:202-7.
- 4 Korinthenberg R, Sauer M, Ketelsen UP, *et al*. Congenital axonal neuropathy caused by deletions in the spinal muscular atrophy region. *Ann Neurol* 1997;42:364-8.
- 5 Wirth B, Hahnen E, Morgan K, *et al*. Allelic association and deletions in autosomal recessive proximal spinal muscular atrophy: association of marker genotype with disease severity and candidate cDNAs. *Hum Mol Gen* 1995;4:1273-84.

Acute overdosage and intoxication with carbidopa/levodopa can be detected in the subacute stage by measurement of 3-*o*-methyldopa

Although the effects of a chronic overdosage with levodopa are well known, few cases of acute intoxication have been described.^{1,2} A particular problem in establishing a diagnosis of levodopa overdosage is the relatively short half life in the circulation of levodopa.^{3,4} If there is a delay in bringing an acutely intoxicated patient to hospital, perhaps due to late discovery, the blood concentration of levodopa could already be normal (corresponding to the peak levodopa concentration in Parkinson's disease therapy) after 6-8 hours. Depending on the extent of the overdosage, the time could be even shorter. This report describes the clinical effects and the plasma concentrations of levodopa and specific metabolites over a period of 132.5 hours after ingestion of 30 tablets of carbidopa/levodopa (50 mg/200 mg tablets).

A 76 year old patient had a pre-existing mild akinetic rigid Parkinson's syndrome, which had been treated for the past 1.5 years with 3x1 tablets of carbidopa/levodopa (50 mg/200 mg) a day without a substantial response. The weight of the patient was 74 kg. A known chronic obstructive airway disease was treated with a home oxygen appliance. At about 8.30 pm, the patient had attempted suicide by taking 30 tablets of carbidopa/levodopa. About 9.00 pm he appeared psychically altered, crying without reason, anxious, and depressed. After about 30 minutes he was increasingly inadequate, agitated, and subeuphoric, and was experiencing visual hallucinations; he was restless, tossing and turning, and getting out of bed. He did not represent peak dose dyskinesia or other extrapyramidal clinical features. At 10.00 pm he showed bilaterally maximally dilated pupils. The muscle stretch reflexes were lively, there were no pyramidal tract signs, and he did not show any signs of Parkinson's syndrome or dyskinesia. Arterial hypertension and sinus tachycardia could be registered.

After an empty box of Striaton (carbidopa/levodopa, 50 mg/200 mg) was found in the patient's flat, 1 g of carbon was given by stomach tube after gastric lavage. Cranial CT was carried out before the diagnosis of intoxication had been made; it showed a pronounced subcortical arteriosclerotic encephalopathy with reduced brain volume. The patient was moved to the medical intensive care unit and observed for 24 hours. The ECG showed a P pulmonale, but no other unusual features. Echocardiography showed normal right and left ventricular function with suspicion of right ventricular hypertro-



Time course of the measured concentrations of levodopa (half filled circles) and 3-*o*-methylidopa (full circles) after an overdose of levodopa (6000 mg). The peak of 3-*o*-MD appears after a delay, and the concentration falls very slowly, corresponding to a half life in plasma of 16.7 hours.

phy. Blood was taken for the measurement of levodopa and metabolites 2.5 hours after ingestion, and again after 9, 14.5, 34, and 132.5 hours. Using high performance liquid chromatography with electrochemical detection, we measured the plasma concentrations of levodopa, 3-*o*-methylidopa, dihydroxyphenylacetic acid, homovanillic acid, noradrenaline, adrenaline, and dopamine. The time course of the concentrations of levodopa and 3-*o*-methylidopa are shown in the figure.

After 24 hours the patient was moved from the intensive care unit to a normal medical ward. At this point no neuropsychiatric signs of levodopa intoxication could be detected. Clinically, the most prominent symptoms of levodopa overdosage are confusion, agitation, sleeplessness, and excessive motor activity. The initial levodopa concentration in our patient was 66 763 ng/ml, the concentrations of DOPAC, homovanillic acid, noradrenaline, adrenaline, and dopamine were raised 2.5 hours after ingestion and rapidly returned to normal. A very noticeable feature of this case was the maximal bilateral mydriasis, with absent light reaction, at the time of the maximal intoxication with a 30-fold increase in plasma levodopa concentration. To our knowledge, this association of a levodopa intoxication with maximally dilated, light unresponsive pupils and without signs of dyskinesia has not previously been reported. It can be assumed that the effect is caused by the peripheral conversion of levodopa into noradrenaline, which stimulates α -adrenergic receptors in the dilator iris. There is no indication from animal experiments of a specific activation of dopamine receptors.⁵ The arterial hypertension measured initially can also be attributed to the high systemic concentrations of noradrenaline, and the tachycardia to the raised concentrations of adrenaline and dopamine. As seen in the figure, the only indicator which can show a levodopa intoxication in the subacute stage is the concentration of 3-*o*-methylidopa. The metabolite 3-*o*-methylidopa results from the *o*-methylation of levodopa, which explains the delayed peak of the 3-*o*-methylidopa concentration. The half-life of 3-*o*-methylidopa in plasma was calculated at 16.7 hours in this patient. On the other hand, the plasma half life of levodopa was 111 minutes; this is slightly longer than normal, and can be explained by assuming a rate limited metabolism of levodopa when the substrate concentration for the enzymes metabolising it is raised.

Distribution into muscles rather than metabolism may largely determine the plasma half life of levodopa and explain why this was only slightly altered with overdose. The measured peak concentration of 66 763 ng/ml is about 30 times higher than the peak concentration to be expected after taking one tablet of carbidopa/levodopa (50 mg/200 mg). It is apparent that the 30 tablets did not interfere with absorption or lead to a gastrointestinal paralysis due to the high dose of levodopa; the relation between amount ingested and plasma concentration seems to be linear, at least in this dose range.

We conclude from these findings that in cases of suspected levodopa intoxication some hours previously, it could be important to measure the concentration of 3-*o*-methylidopa, so as not to overlook an overdosage with levodopa, which may be due to a suicide attempt. In addition to the diagnostic uncertainty in relation to the immediate treatment of the patient, this would also have an effect on further psychiatric and psychological therapy.

H J STUERENBURG
B G H SCHOSER

Neurological Department, University Hospital
Hamburg-Eppendorf, Hamburg, Germany

Correspondence to: Dr Hans Joerg Stuerenburg, Neurological Department, Universitätskrankenhaus Eppendorf Martinistrasse 52, 20246 Hamburg, Germany. Telephone 0049 40 4717 4832; fax 0049 40 4717 5086; email stuerenburg@uke.uni-hamburg.de

- 1 Hoehn MM, Rutledge CO. Acute overdose with levodopa. Clinical and biochemical consequences. *Neurology* 1975;25:792-794.
- 2 Sporer KA. Carbidopa-levodopa overdose. *Am J Emerg Med* 1991;9:47-8.
- 3 Contin M, Riva R, Martinelli P, et al. Longitudinal monitoring of the levodopa concentration-effect relationship in Parkinson's disease. *Neurology* 1994;44:1287-92.
- 4 Bredberg E, Lennernas H, Paalzow L. Pharmacokinetics of levodopa and carbidopa in rats following different routes of administration. *Pharm Res* 1994;11:549-55.
- 5 Korczyn AD, Keren O. The effect of L-dopa on pupillary diameter in mice. *Experimentia* 1982;38:481-2.

The use of olanzapine for movement disorder in Huntington's disease: a first case report

Movement disorder is a prominent feature of Huntington's disease and consists of involuntary and voluntary components as well as associated bradykinesia. Pharmacological treatment is problematic because of the side effects of the drugs used, which may further compromise cognitive functioning and mobility. Patients are often not subjectively aware of their movements but can be considerably disabled by them and carers are often distressed and enquire about treatment options. If drug treatment is considered it is important to achieve the maximum improvement in movements with the minimum of negative side effects. This paper describes the effect of olanzapine on movements when other treatment options had been ineffective or limited by side effects.

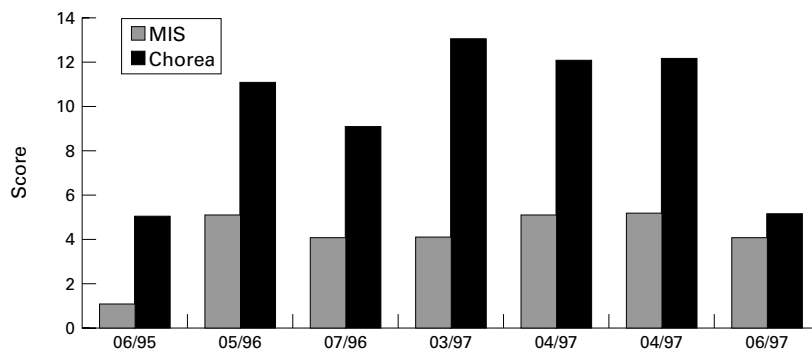
Huntington's disease is a hereditary progressive neurodegenerative disorder. It consists of a triad of symptoms comprising motor, psychological, and cognitive abnormalities. The motor component consists of involuntary choreiform movements and increasing difficulties with voluntary movement. The degree of the involuntary movements is variable but in some patients can be

very marked. Progression over time of the movement disorder in Huntington's disease can be monitored using the quantitative neurological examination (QNE). This measure has three subscales, an eye movement scale, a motor impairment scale (MIS) quantifying voluntary movement, and a chorea scale measuring involuntary movement.^{1,2}

Pharmacological control of the symptoms has been shown to be effective with dopamine antagonists,^{3,4} but their use is limited because of the side effects. Clinically the most problematic of these are sedation, cognitive slowing, increased mobility problems, and hypotension. The inability of traditional dopamine antagonists to improve functional capacity, despite ameliorating chorea, is possibly due to suppression of voluntary motor activity.^{4,5} Tardive dyskinesia has occasionally been reported in patients with Huntington's disease treated with these drugs.^{5,6} The atypical antipsychotic clozapine has been shown to be effective in improving the movement disorder. However, in a double blind randomised trial of clozapine which included patients who were already receiving traditional antipsychotic medication and a group who had not received drug treatments for their movement disorder, chorea was reduced in those who were antipsychotic naive only and the authors concluded that clozapine was of little additional benefit in Huntington's disease.⁷ Olanzapine is a new atypical antipsychotic drug. It is a thienodibenzodiazepine structurally very similar to clozapine. Unlike clozapine it is not associated with the potentially serious side effect of agranulocytosis and therefore frequent blood monitoring is not necessary.

This report describes the progress of a man who has Huntington's disease. He developed a marked movement disorder and was unable to tolerate both sulpiride and risperidone but had symptomatic improvement when treated with olanzapine.

He is a man in his early 50s who had a confirmatory genetic test for Huntington's disease in 1994, after the development of clinically obvious motor symptoms. It is likely that the onset of symptoms had occurred a few years previously as he had experienced difficulties in concentration and attention at work, attributed at the time to stress, leading to the loss of employment. In addition his family, watching family videos of a few years earlier, thought that there was evidence of early signs of his movement disorder. However there was no known family history of Huntington's disease which might have led to an earlier diagnosis. By May 1995 his involuntary movements were becoming more noticeable, although control of voluntary movement was good. A trial of sulpiride commencing at 200 mg twice daily and increasing over 1 week to 800 mg daily was undertaken with a subsequent decrease in the frequency and extent of involuntary movement recorded in case notes; unfortunately the QNE was not repeated at this time. However, the patient experienced a subjective slowing of his cognitive processes, concurrently became depressed, and decided to stop the treatment within 3 weeks. Paroxetine, a selective serotonin reuptake inhibitor antidepressant, was started at a dose of 20 mg a day, which led to an improvement in his low mood. His involuntary movements continued to cause difficulties in his daily living. He was unable to sit comfortably in a chair and when out he felt that he was disturbing others by knocking into them. He agreed to a trial of



Quantitative neurological examination scores showing the progress of the movement disorder. 06/95: before trial sulpiride, no medication; 05/96: before risperidone, 20 mg paroxetine daily; 07/96: 1 mg risperidone four times daily and 20 mg paroxetine daily; 03/97: before retrial sulpiride, 20 mg paroxetine daily; 04/97: 400 mg sulpiride in the mornings 600 mg at night and 20 mg paroxetine; 04/97: before olanzapine, 140 mg lofepramine daily; 06/97: 5 mg olanzapine at night, 140 mg lofepramine daily.

risperidone. This was started at a dose of 1mg twice daily, increasing to a dose of 1mg four times a day over a period of 2 weeks, stopped after a brief period. He developed hypotension (blood pressure 100/60 mm Hg), complaining of dizziness after the initial dose. His blood pressure remained stable, although low, after this and as there was improvement in his movements the drug was continued. However, he decided to stop the risperidone after 4 months because of his subjective experience of slowed thinking and occasional dizziness. A repeated trial of sulpiride was carried out in March 1997. Sulpiride was started at a dose of 200 mg twice a day and increased to a total daily dose of 1000 mg over 2 weeks. He was on sulpiride for 4 weeks with no improvement in his movements, so it was discontinued. The patient continued to experience low mood and after the discontinuation of sulpiride, his antidepressant drug was changed to lofepramine commencing at 70 mg once a day and increasing after a few days to 140 mg daily. There were no changes noted in his movements during this change.

Although the patient was subjectively unaware of the extent of his movements his everyday life continued to be affected. The social venues he felt able to attend were becoming more limited and activities he wanted to pursue such as travelling abroad by air were problematic. A trial of olanzapine was then instituted. He was started on 5 mg a day in the morning. There was a marked improvement in his involuntary movements within 1 week but once again he experienced slowed thinking. However, adjusting the time of medication to the evening led to an improvement in this. Six months later the improvement in his involuntary movements is maintained. Serial quantitative neurological examination scores are illustrated in figure 1.

In the absence of a cure for Huntington's disease, it is very important that any interven-

tions considered enhance the quality of life of the patient and improve overall functioning. It may not always be in the best interests of the patient to use drug treatments for the movement disorder. In those patients who have severe movements, however, a trial of treatment may be appropriate and continued if a clear benefit has been achieved. Neurological monitoring and the patient's own perception of the effect of the drug must be taken into account.

The mechanism by which olanzapine may have beneficial effects is unclear. Olanzapine has been shown to have high affinity for a large number of receptors including D1, D2, D4, 5HT_{2A}, 5HT_{2C}, 5HT₃, α -1-adrenergic, histamine H₁, and 5 muscarinic receptors. This binding profile is similar to clozapine, another atypical antipsychotic drug, but substantially different to the conventional antipsychotic haloperidol.⁷ Preferential loss of D2 projection neurons which are involved in a feedback loop normally active in the suppression of involuntary movements is thought to be the pathophysiological basis of chorea in patients with Huntington's disease.⁸ The D2 antagonist properties of olanzapine may explain its possible benefits in the improvement of chorea. However, the effect at other receptors such as D4 may also be important, as D4 receptor density has been shown to be raised in Huntington's disease, therefore the D4/D2 ratio of activity may also be relevant. Differences in binding profile across a range of receptors may explain clinical differences in outcome when comparing different antipsychotic drugs.

This case report indicates that olanzapine may be a useful addition to the treatments for movement disorder, for some patients, and controlled trials of its use in Huntington's disease would be welcome.

HEATHER C DIPPLE

Department of Psychiatry, Leicestershire Mental Health Service Trust, Huntington's Disease Service, Mill Lodge, Mill Lane, Kegworth, Derby DE74 2EJ, UK. Telephone 0044 1509 670774.

- 1 Folstein SE, Jensen B, Leigh RJ, *et al.* The measurement of abnormal movements: methods developed for Huntington's disease. *Neurobehavior Toxicol Teratol* 1983;5:605-9.
- 2 Folstein S. *Huntington's disease: a disorder of families*. Baltimore: John Hopkins University Press 1989.
- 3 Quinn N, Marsden CD. A double blind trial of sulpiride in Huntington's disease and tardive dyskinesia. *J Neurol Neurosurg Psychiatry* 1984; 47:844-7.
- 4 Girotti F, Carella F, Scigliano G, *et al.* Effect of neuroleptic treatment on involuntary movements and motor performances in Huntington's Disease. *J Neurol Neurosurg Psychiatry* 1984;47:848-52.
- 5 Schoulson I. Care of patients and families with Huntington's disease. In: Marsden CD, Fahn, eds. *Movement disorders*. London: Butterworth, 1982:277-90.
- 6 Schott K, Ried S, Stevens I, *et al.* Neuroleptically induced dystonia in Huntington's disease: a case report. *Eur Neurol* 1989;29:39-40.
- 7 Bymaster FP, Calligaro DO, Falcone JF, *et al.* Radioreceptor binding profile of the atypical antipsychotic olanzapine. *Neuropsychopharmacology* 1996;14:87-96.
- 8 van Vugt JP, Siesling S, Vergeer M, *et al.* Clozapine versus placebo in Huntington's disease: a double blind study. *J Neurol Neurosurg Psychiatry* 1997;63:35-9.

Transient hiccups after posteroventral pallidotomy for Parkinson's disease

Hiccup is defined as an abrupt intermittent, involuntary, contraction of the diaphragmatic and external (inspiratory) intercostal muscles, with inhibition of expiratory intercostal activity. This results in a sudden inspiration, abruptly opposed by closure of the glottis.¹ Hiccup may result from various structural or functional disorders of the medulla, the afferent or efferent nerves to the respiratory muscles, and the gastrointestinal tract.^{2,3} Newson Davis performed a study of hiccup with electrophysiological techniques and concluded that hiccup is served by a supraspinal mechanism distinct from that generating rhythmic breathing.³ The principal site of interaction of the hiccup discharge with other descending drives to the respiratory motoneuron is at the spinal level. Neurogenic hiccup is particularly associated with structural lesions of the medulla oblongata.

Since 1994 we have performed 66 pallidotomies for Parkinson's disease in 60 patients. So far, we have seen transient hiccups in seven patients after the operation (table). Our target coordinates for the posteroventral globus pallidus at the border of the medial and lateral segments are 2-3 mm anterior to the midcommissural point, 5 mm below the intercommissural line, and 22 mm lateral to the midline of the third ventricle. Ventriculography was performed for target

Patient characteristics

Patient	Age at surgery	Sex	Years with PD	H and Y* staging On/off	UPDRS off† prepallidotomy/postpallidotomy	Pallidotomy side	Transient side effects	Medication additional to levodopa
1	66	M	8	2/5	57/NP‡	R	Slight facial paresis, swallowing problems, drooling	Tryptizol, temazepam, alprazolam, apomorphine
2	43	F	7	2/2.5	22/7	L	Slight dysarthria	Trihexifenidyl
3	49	M	15	2/3	55/15	L	Facial paresis	Pergolide, amantadine
4	50	M	12	2/2	45/22	L	Slight dysarthria	Selegeline, biperideen
5	53	M	14	2.5/4	69/36	R	Facial paresis, hypophonia	Pergolide, selegeline
6	55	M	13	2.5/3	48/27	L	Facial paresis, aphasia	Selegeline, biperideen
7	61	F	15	2.5/4	55/NP	R		Clozapine, temazepam, cisapride

*H and Y=Hoehn and Yahr; †UPDRS off=unified Parkinson's disease rating scale part 3 (motor examination), in a standardised off state, 12 hours without antiparkinson medication; ‡NP=not performed.

localisation. Patients started with a short schedule of corticosteroids (5 days) the night before surgery.

The hiccups started immediately after the operation or the next day, were intermittent, and the bouts of hiccup of six patients, with a duration of hours, resolved within 3 days after the procedure. One patient complained of yawning more often and frequent bouts of hiccup for 6 months.

Five patients were men. All patients were right handed. The mean age at surgery was 54 years and the mean duration of Parkinson's disease was 12 years. All patients were taking levodopa. In four patients the hiccups appeared after a left sided pallidotomy. Patient 2 had a right sided thalamotomy 4 years before the pallidotomy. Patient 5 underwent a left sided pallidotomy 10 months before the right sided pallidotomy which caused the hiccups. The pallidotomies improved parkinsonism in the "off" state (table), contralateral dyskinesias, and pain accompanying Parkinson's disease. Six patients had transient adverse events: four patients had a transient facial paresis postoperatively and two a slight transient dysarthria (table). Two patients had choreatic movements after the pallidotomy at the contralateral side which resolved spontaneously within 2 hours and is associated with a favourable surgical outcome.⁴

Postoperative MR scans were obtained in the first six patients, and showed that in five patients the lesions were located in the posterior part of the globus pallidus pars externa (GPe) and interna (figure). In patient 5 the lesion was situated slightly more anterior in the GPe and putamen. In patient 3 there was a small separate lesion more dorsal, probably an infarct.

We never encountered hiccups in 150 other stereotactic procedures for Parkinson's disease, such as thalamotomies or deep brain stimulation electrode implantation in the thalamus and therefore it is unlikely that medication or positive contrast medium ventriculography with Iohexol evoked the hiccups.

A possible cause for the transient hiccups could be the lesion in the ventral medial seg-

ment of the globus pallidus or pressure, due to oedema, on an adjacent structure like the internal capsule or putamen. We could not find other reports of hiccups as an adverse event after functional stereotactic surgical interventions, nor after lesions of other aetiology involving the striatum.⁵ Based on our experience we hypothesise that the globus pallidus or a neighbouring structure may be involved in a supramedullary system involved in triggering hiccups.

R M A DE BIE
J D SPEELMAN
Department of Neurology

P R SCHUURMAN
D A BOSCH
Department of Neurosurgery, Academic Medical
Center, University of Amsterdam, The Netherlands

Correspondence to: Dr R M A de Bie, Department of Neurology, Academic Medical Center, PO Box 22700, 1100 DE Amsterdam, The Netherlands. Telephone 0031 20 566 3856; fax 0031 20 679 1438; email R.M.deBie@amc.uva.nl

- 1 Newson Davis J. An experimental study of hiccup. *Brain* 1970;93:851-72.
- 2 Howard RS. Persistent hiccups. *British Medical Journal* 1992;305:1237-8.
- 3 Newson Davis J. Pathological interoseptive responses in respiratory muscles and the mechanism of hiccup. In: Desmedt J, ed. *New developments in electromyography and clinical neurophysiology*. Vol 3. Basel: Karger, 1973:751-60.
- 4 Merello M, Cammarota A, Betti O, et al. Involuntary movements during thermolesion predict a better outcome after microelectrode guided posterovenral pallidotomy. *J Neurol Neurosurg Psychiatry* 1997;63:210-13
- 5 Bathia KP, Marsden CD. The behavioral and motor consequences of focal lesions of the basal ganglia in man. *Brain* 1994;117:859-76.

Psychological adjustment and self reported coping in stroke survivors with and without emotionalism

Emotionalism after stroke is common, occurring in 10%-20% of a community sample.¹ Psychological factors in its cause or maintenance have not been studied; research has tended to concentrate instead on location of the stroke lesion. We suspect that one reason for this neglect of psychological aspects of

emotionalism is that most people do not make a distinction between emotionalism, and pathological crying and laughing. As a result all disorders of emotionality after stroke are stereotyped as being related to brain damage and therefore psychologically meaningless.

None the less, many patients with emotionalism describe their crying as provoked by emotionally congruent experiences, which makes the tearfulness seem understandable.¹ In two previous studies^{1,2} we have shown that stroke patients with emotionalism have more symptoms of psychological disorder than do patients without emotionalism. In the present study, we explored further the psychological characteristics of stroke patients with emotionalism. Our aim was to determine whether they differed from patients without emotionalism in their psychological reactions to stroke, or in the coping strategies they reported.

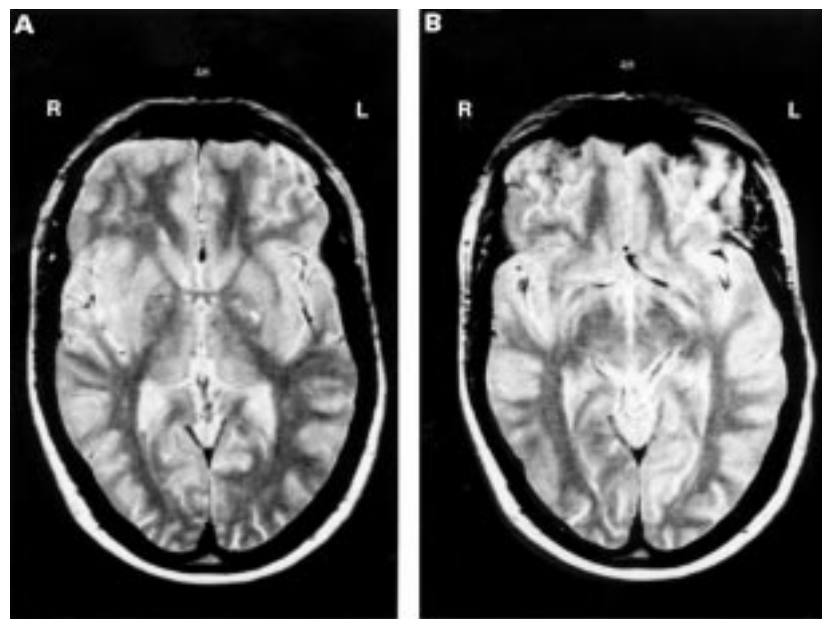
Post-traumatic stress disorder is also characterised by recurrent episodes of intrusive and uncontrollable emotion, and we were therefore interested in whether patients with emotionalism also experienced the intrusive thoughts typical of post-traumatic stress disorder. Because emotionalism is often described as uncontrollable, we were interested in the possibility that patients were more generally helpless, passive, or avoidant in their responses to stroke. Again, because of the reported uncontrollability of emotionalism, we postulated that patients with emotionalism would report a more external locus of control³ than those without emotionalism.

Participants were adults admitted to local general hospitals after stroke, and were interviewed within 1 month of admission. Exclusions were due to poor physical health, cognitive impairment, communication difficulties, or lack of consent. Approval for the study was obtained from the local research ethics committees.

All participants completed a standardised measure of distress—the general health questionnaire, GHQ-12⁴; a widely used measure of intrusive thoughts of the sort encountered in post-traumatic stress disorder—the impact of events rating scale⁵; a measure of cognitive coping—the mental adjustment to stroke scale (O'Rourke S, Dennis M, MacHale S, Slattery J. The development of the mental adjustment to stroke scale: reliability, patient outcome and associations with mood and social activity, manuscript in preparation); and a measure of beliefs about responsibility for recovery from illness—the recovery locus of control scale.³ All the measures are self report questionnaires.

A total of 177 stroke patients were screened, of whom 112 were excluded. The 65 participants (29 men, 36 women) had a mean age of 71.8 years (range 43 to 88 years). Nineteen (29.2%) patients met our criterion for emotionalism,¹ a rate similar to that found in other studies. Their scores on the study measures are compared with the scores of patients without emotionalism in the table.

It might be that these associations with emotionalism were accounted for by the greater general levels of distress experienced by those with emotionalism. We therefore undertook analysis of covariance with GHQ-12 and presence of emotionalism as the covariates, and each of the other test items in turn as the independent variable. The results showed an association, after adjustment for GHQ-12 score, between emotionalism and the impact of events subscales intrusion



Five months after left sided pallidotomy, MRI of patient 6: (A) transversal slice at the level of the anterior commissure and (B) 6 mm more ventral.

Comparison of stroke survivors with and without emotionalism, assessed in hospital 1 month after stroke

	No emotionalism (n=45) Mean (SD)	Emotionalism (n=19) Mean (SD)
GHQ-12*	3.2 (2.4)	5.3 (3.5)
Recovery locus of control scale	33.2 (3.3)	34.2 (3.7)
Impact of events scale intrusion subscale**	2.9 (4.6)	9.2 (6.6)
Impact of events scale avoidance subscale*	4.7 (4.6)	9.9 (6.1)
MASS Fighting spirit subscale	49.1 (4.0)	48.8 (5.2)
MASS Anxious preoccupation subscale**	22.2 (2.8)	25.2 (4.0)
MASS Fatalism subscale*	20.0 (1.9)	21.3 (2.2)
MASS Avoidance subscale	1.7 (0.8)	1.9 (0.8)
MASS Helplessness/hopelessness subscale**	10.9 (2.5)	14.1 (3.5)

MASS = Mental adjustment to stroke scale.

*p<0.05; **p<0.01, t tests.

($F=15.33$, $p<0.001$), and avoidance ($F=11.84$, $p=0.001$); the mental adjustment to stroke scale subscales helplessness/hopelessness ($F=11.71$, $p=0.001$) and anxious preoccupation ($F=8.05$, $p=0.006$). The associations with fatalism ($F=14.79$, $p=0.052$) and avoidance ($F=0.06$, $p=0.80$) on the mental adjustment to stroke scale were no longer significant after adjustment for GHQ-12 score.

This study confirms earlier work by showing that stroke survivors with emotionalism have more other mood symptoms (here rated by the GHQ-12) than do those without emotionalism. It goes further however, in showing that they also have intrusive thoughts about their stroke, of a sort similar to those reported by people with post-traumatic stress disorder. This unpleasant remembering is probably responsible for their higher ratings on anxious preoccupation. It is compatible with our finding in a previous study² that irritability is associated with emotionalism, as irritability is a common response to threatening intrusive memories of the sort encountered in post-traumatic stress disorder. It may not be that emotionalism is a direct manifestation of post-traumatic stress disorder, although that condition has been described after stroke,⁶ but the analogy raises the possibility that an abnormality in processing emotionally important stimuli may be one of the causes of emotionalism. If correct it suggests possible treatment strategies along the lines of those used in post-traumatic stress disorder.

A corollary is our finding of increased feelings of helplessness and hopelessness, coupled with avoidance—at least as a cognitive coping strategy reported on one of our measures. Avoidant coping may perpetuate the symptom of emotionalism, by preventing habituation to the social stimuli which provoke it. Alternatively it may lead to a reduction in social support, exacerbating coexistent mood disturbance. Thus, it may be that avoidant coping is not an integral part of emotionalism, but rather that it is an important maintaining factor.

We predicted that patients with emotionalism would have more “external” scores on the locus of control measure, reflecting their sense of lack of personal control over crying. They did not, perhaps because the emotional expression, although not apparently controllable by internal resources, is none the less perceived as having psychological meaning, so that responsibility for it it cannot readily be devolved to others.

Our study used a relatively weak between-groups design, the number of patients was not large, and we cannot be sure that all confounders were dealt with. None the less, our results suggest that future research into emotionalism could profitably concentrate not just on seeking its biological correlates, but

should also explore the psychological factors which might contribute to its cause or continuation.

We thank those patients who participated in the study and the staff of local hospitals and the Leeds Stroke Database for their invaluable help. We also thank Dr Louise Dye for her statistical advice. This study was completed as part of work for the degree of DClinPsychol at Leeds University (SE).

STEVEN ECCLES
ALLAN HOUSE

Division of Psychiatry and Behavioural Sciences in
Relation to Medicine, University of Leeds, Leeds, UK

PETER KNAPP

Stroke Outcome Study, Research School of Medicine,
Leeds, UK

Correspondence to: Dr Allan House, Division of
Psychiatry and Behavioural Sciences in Relation to
Medicine, University of Leeds, 15 Hyde Terrace,
Leeds LS2 9LT, UK.

- House A, Dennis M, Molneaux A, et al. Emotionalism after stroke *BMJ* 1989;298:991–4.
- Calvert T, Knapp P, House A. Psychological associations with emotionalism after stroke. *J Neurol Neurosurg Psychiatry* 1998;65:928–9
- Partridge C, Johnston M. Perceived control of recovery from physical disability: measurement and prediction. *Br J Clin Psychol* 1989;28:535–9.
- Goldberg D. General health questionnaire (GHQ-12). In: *Compendium of Health Psychology Assessments*. Windsor: NFER-Nelson, 1992.
- Horowitz MJ, Wilner N, Alvarez W. Impact of events scale as a measure of subjective stress. *Psychosom Med* 1979;41:209–18.
- Sembi S, Tarrier N, O'Neill P, et al. Does post-traumatic stress disorder occur after stroke: a preliminary study. *International Journal of Geriatric Psychiatry* 1998;13:315–22.

Paraneoplastic stiff limb syndrome

Stiff man syndrome (SMS) is a rare, severe progressive motor disorder characterised by painful spasms, symmetric axial muscle rigidity, and uncontrollable contractions leading to distorted posturing. The disorder has been associated with the autoantigens, glutamic acid decarboxylase (GAD), and amphiphysin, which are cytoplasmic proteins in neurons of the CNS. A large series of patients with SMS found that most have autoantibodies against GAD,¹ whereas amphiphysin is presumably the predominant autoantigen in paraneoplastic SMS.² Recently, Brown *et al*³ presented four patients with a stiff leg syndrome marked by progressive rigidity and spasms of the lower extremities. This group of patients tested negative for anti-GAD antibody by immunoprecipitation and demonstrated distinct electrophysiological features. By contrast, another report described two patients with stiff leg syndrome who tested positive for anti-GAD antibody.⁴ Finally, in presenting a group of 13 patients, Barker *et al*⁵ proposed that the nomenclature

“stiff limb syndrome” refers to the focal form of SMS when one or more distal limbs are involved; two of their patients were also anti-GAD antibody positive, but none were tested for antibodies to amphiphysin or identified as having an underlying neoplasm. We present a patient clinically consistent with the stiff limb syndrome who was found to have autoantibody to GAD and breast cancer.

A 68 year old woman presented with a 1 month history of painful spasms in her legs. Cramps were associated with tactile stimuli and emotional upset. Within weeks, inversion began at the left and then right ankle, making ambulation difficult. Her medical history was significant for Graves' disease treated with thyroidectomy and radiation therapy, and hyperlipidaemia. She was a chronic smoker. General examination was noteworthy for lymphadenopathy in the right axilla. Her mental status was worse during periods of lower extremity spasms, during which she became anxious, diaphoretic, and tachycardic. Cranial nerve and motor evaluations were unremarkable, but assessment of the left leg, due to painful spasms elicited by light touch, was difficult. Inversion and plantar-flexion were essentially fixed at the left ankle but could be overcome on the right. Deep tendon reflexes were 3+ in the upper and lower extremities, with sustained clonus at the right ankle. Sensory examination, with the exception of hyperaesthesia in the distal lower extremities, and coordination testing were grossly normal. No hyperlordosis or myoclonus was noted. Gait was limited due to ankle posturing.

The laboratory evaluation was noteworthy for a CSF with increased IgG indices (2.5, 3.4; normal, 0.2–0.8) and oligoclonal bands (5, 5) but no pleocytosis. Serological testing for anti-Hu, anti-Yo, and anti-Ri antibodies was unremarkable, and the haemoglobin A1C was 6.6 (5.6–7.7)%. Skin biopsy at three sites on the patient's leg showed diminished epidermal nerve fibre density and terminal axonal swelling distally, consistent with a small fibre sensory neuropathy.⁶ The patient would not tolerate EMG. Magnetic resonance images of the brain and the entire spinal cord were normal. Fine needle aspiration of a soft tissue right axillary mass showed metastatic adenocarcinoma. On an open surgical procedure, infiltrating duct carcinoma of the breast was identified. Anti-GAD autoantibodies were positive by immunocytochemical assay and immunoprecipitation, but antibodies to amphiphysin were not detected by immunocytochemistry, immunoprecipitation, or western blotting (Dr P De Camilli, Yale University).

Ongoing therapy with clonazepam and a trial of oral dexamethasone did not improve the lower extremity symptoms. The patient's ankle posturing continued a slow progression to marked inversion, with spontaneous extension of hallux longus. The patient died 18 months after symptom onset. Gross necropsy attributed the cause of death to aspiration pneumonia. Neuropathological evaluation showed a grossly normal brain and spinal cord. Microscopically, the lumbar cord had mild reactive gliosis in the anterior horns but no evidence of inflammation. Sections of the frontal cortex, pons, and medulla showed mild diffuse reactive astrocytosis.

Stiff man syndrome is increasingly recognised as a heterogeneous disorder.⁷ Other case reports have documented patients with “focal” disease involving either lower^{3–5} or upper extremity posturing,⁸ which contrast

with the “diffuse” axial and subsequent proximal muscle distribution of the classic disorder.⁹ Our patient differs from those reported with stiff leg syndrome in that an occult malignancy was present. Unfortunately, we were unable to obtain electrophysiological studies for comparison. The search for a paraneoplastic process was based on the findings of axillary lymphadenopathy and an abnormal CSF. Our patient is only the second reported patient with paraneoplastic SMS associated with anti-GAD antibody; the other had upper limb rigidity in the setting of breast cancer and additionally mounted an immune response to amphiphysin.⁸

Paraneoplastic processes can affect any component of the nervous system and, occasionally, multiple levels, as in the syndrome of sensory neuronopathy–encephalomyelitis. Our patient’s findings were not entirely consistent with criteria for classic SMS⁹ in that an apparent encephalopathy and a small fibre neuropathy were identified—for example, her dysautonomia (tachycardia and relative hypertension) during spasms may have been a manifestation of involvement of small fibres. The role of autoantibodies in the pathogenesis of SMS and cancer is unclear.^{2,7,8} Via its probable function in endocytosis,¹⁰ amphiphysin has been postulated to play a part in the regulation of growth factor internalisation; however, the absence of an autoimmune response to this autoantigen in our patient suggests that other mechanisms of oncogenesis in SMS exist. Given anecdotal evidence of improvement in paraneoplastic SMS after treating the underlying malignancy,⁸ we suggest that all patients with SMS, diffuse or focal, be screened for occult cancer.

ISAAC E SILVERMAN
Department of Neurology, Johns Hopkins University,
Baltimore, USA

Correspondence to: Dr I E Silverman, Johns Hopkins Hospital, Pathology 509, 600 North Wolfe Street, Baltimore, MD 21287, USA. Telephone 001

410 955 6626; fax 001 410 614 1008; email iesilver@jhmi.edu


- 1 Solimena M, Folli F, Aparisi R, et al. Autoantibodies to gaba-ergic neurons and pancreatic β cells in stiff-man syndrome. *N Engl J Med* 1990;322:1555–60.
- 2 Folli F, Solimena M, Coficelli R, et al. Autoantibodies to a 128-kd synaptic protein in three women with the stiff-man syndrome and breast cancer. *N Engl J Med* 1993;328:546–51.
- 3 Brown P, Rothwell JC, Marsden CD. The stiff leg syndrome. *J Neurol Neurosurg Psychiatry* 1997;62:31–7.
- 4 Saiz A, Graus F, Valdeoriola F, et al. Stiff-leg syndrome: a focal form of stiff-man syndrome. *Ann Neurol* 1998;43:400–3.
- 5 Barker RA, Revesz T, Thom M, et al. Review of 23 patients affected by the stiff man syndrome: clinical subdivision into stiff trunk (man) syndrome, stiff limb syndrome, and progressive encephalomyelitis with rigidity. *J Neurol Neurosurg Psychiatry* 1998;65:633–40.
- 6 McCarthy BG, Hsieh S-T, Stocks A, et al. Cutaneous innervation in sensory neuropathies: evaluation by skin biopsy. *Neurology* 1995;45:1848–55.
- 7 Kissel JT, Elble RJ. Stiff-person syndrome: stiff opposition to a simple explanation. *Neurology* 1998;51:11–14.
- 8 Rosin L, De Camilli P, Butler M, et al. Stiff-man syndrome in a woman with breast cancer: an uncommon central nervous system paraneoplastic syndrome. *Neurology* 1998;50:94–8.
- 9 Lorisch TR, Thorsteinsson G, Howard FM. Stiff-man syndrome updated. *Mayo Clin Proc* 1989;64:629–36.
- 10 David C, McPherson PS, Mundigl O, et al. A role of amphiphysin in synaptic vesicle endocytosis suggested by its binding to dynamin in nerve terminals. *Proc Natl Acad Sci USA* 1996;93:331–5.

Tetrodotoxin intoxication in a uraemic patient

Tetrodotoxin intoxication results from ingesting puffer fish or other animals containing the toxin. Clinical presentation is mainly acute motor weakness and respiratory paralysis. Death is common in the worst affected victims. Although the severity of the symptoms generally depends on the amount of toxin ingested, it may be influenced by the

victim’s medical condition, as described in this report. The patient was a 52 year old uraemic woman. The uraemia was of undefined aetiology. Over the past 3 years she has received regular haemodialysis. One day both she and her husband, a healthy 55 year old man, ate a fish soup. About 4 hours after the meal she developed a headache and a lingual and circumoral tingling sensation and numbness at the distal parts of all four limbs. She was dizzy and unsteady, had difficulty in swallowing, and became very weak. She was taken to the emergency service and was placed on machine assisted ventilation as respiratory distress and cyanosis developed. Her husband remained asymptomatic throughout this time.

The patient’s condition kept on deteriorating, developing eventually into a comatous-like state with no spontaneous or reflexive eye opening or limb movement within 30 minutes of intubation. On neurological examination, the pupillary light reflex was absent and oculocephalic manoeuvre elicited no ocular movements. All four limbs were areflexic and Babinski’s signs were absent. Brain CT and laboratory studies of arterial blood gas (under assisted ventilation), electrolytes, liver function, blood glucose, and CSF study were unremarkable. An examination of renal function indicated chronic renal insufficiency with mild azotaemia (urea nitrogen 70 mg/dl, creatinine 9.1 mg/dl). An EEG, recorded 18 hours after the onset of symptoms when the neurological condition was unchanged, showed posterior dominant alpha waves intermixing with trains of short duration, diffuse theta waves. When brief noxious stimuli were applied to the sternum, they were replaced transiently by beta activities. The findings suggested that the profound neurological dysfunction might be peripheral in origin. The patient was given a course of haemodialysis according to the set schedule for uraemia at 21 hours after onset of the symptoms. Her condition improved dramati-



Changes in the symptoms of poisoning in relation to each course of haemodialysis. Scales in the vertical axis represent the arbitrary measurements of severity of each symptom; the numbers indicating day(s) after onset; ↓= haemodialysis.

cally within an hour. She could open her eyes and she communicated and answered questions correctly by blinking. Pupillary reflex recovered and voluntary eye movements were limited only at the extreme lateral gaze. Muscle power was grade 3 and 4 in the proximal and distal parts of the four limbs. Tendon reflexes were still absent. She was taken off mechanical ventilation the next day. Her clinical condition continued to improve and her symptoms subsided in a stepwise pattern, in response to each course of haemodialysis (figure). When recalling, she could remember certain events such as the recording of the EEG, but was "too weak to move" at that time. She regained her initial strength by the time she was discharged on day 16.

When analysing the remains of the cooked fish (identified as *Yongeichthys nebulosus*), tetrodotoxin was demonstrated by thin layer chromatography, high performance liquid chromatography, and cellulose acetate membrane electrophoresis. Toxicity was assayed by using Institute of Cancer Research strain adult male mice and the toxicity score was 25 mouse units (MU)/g in fish muscle (1 MU=0.178 µg in the ICR strain mouse).¹

Tetrodotoxin exerts its effect through binding with and blocking the voltage dependent sodium channel.² The voltage clamp experiments showed that tetrodotoxin diminished the early sodium inward current responsible for the depolarisation of excitatory membrane. The gating properties of the sodium channel, such as the activation and inactivation mechanism, are not altered—that is, the sodium channel is not permanently damaged and its function recovers when the bound toxin is released. In uraemia, ion conductance through the sodium channel is also impaired. Sodium permeability through excitatory membranes is reduced and small inward sodium current and reduced action potential amplitudes are noted in experimental uraemic neuropathy.³ By contrast with the effects of tetrodotoxin, uraemia changes the basic property of the sodium channel by an increased inactivation and an impaired activation mechanism. The excitability of peripheral nerves will be more significantly depressed when these two conditions combine. The synergistic effect of uraemia and tetrodotoxin is obvious in this incident in which the patient and her husband ingested roughly an equal amount of tetrodotoxin (about 200 µg, calculated from toxic score times the weight of ingested fish). The amount is about 10% of the estimated lethal dose in humans—2200 µg/60 kg body weight⁴ (body weights of the patient and her husband were 54.5 and 62 kg respectively)—and caused no clinical evidence of poisoning in the healthy person. It was of interest that the CNS was relatively spared from the toxicity as the EEG showed a posterior dominant, promptly reactive alpha rhythm and the patient retained consciousness when the symptoms were at their most severe.

One of the most striking clinical features in our patient was the response to haemodialysis. Despite the small amount of toxin ingested, the dramatic improvement of her clinical condition was most likely attributed to the rapid elimination of absorbed toxin in the course of haemodialysis, rather than spontaneous recovery. The physical and chemical properties of tetrodotoxin are also supportive to this hypothesis.⁵ It has a low molecular weight (C₁₁H₁₇N₃O₈), is water soluble, and is not significantly bound to protein—all these features are often found in toxins

amenable to haemodialysis. Traditionally, the management of tetrodotoxin intoxication is mainly supportive, such as gastric lavage to remove unabsorbed toxin and machine assisted ventilation when respiration is severely affected. We suggest that haemodialysis may be an effective method in the treatment of tetrodotoxin intoxication.

MIN-YU LAN

SHUNG-LON LAI

SHUN-SHENG CHEN

Department of Neurology, Kaohsiung Medical College,

Kaohsiung City, Taiwan

DENG-FWU HWANG

Department of Food Science, National Taiwan Ocean

University, Keelung City,

Taiwan

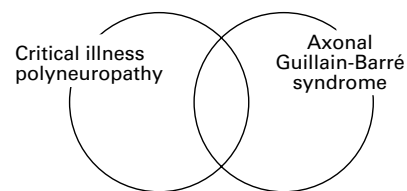
Correspondence to: Dr Shun-Sheng Chen, Department of Neurology, Kaohsiung Medical College Hospital, 100 Shih-Chung 1st Road, Kaohsiung City 807, Taiwan. Telephone 00886 7 3121101 ext 6771; fax 00886 7 3234237; email sheng@mail.nsysu.edu.tw

- Hwang DF, Jeng SS. Bioassay of tetrodotoxin using ICR mouse strain. *J Chinese Biochem Soc* 1991;20:80–6.
- Takata M, Moore JW, Kao CY, et al. Blockage of sodium conductance increase in lobster giant axon by tarichatoxin (tetrodotoxin). *J Gen Physiol* 1966;49:977–88.
- Brismar T, Tegnér R. Experimental uremic neuropathy. Part 2. Sodium permeability decrease and inactivation in potential clamped nerve fibers. *J Neurol Sci* 1984;65:37–45.
- Tani I. Toxicological studies of puffers in Japan. *Teikoku-Toshō (Tokyo)* 1945:103.
- Kao CY. Tetrodotoxin, saxitoxin and their significance in the study of excitation phenomena. *Pharmacol Rev* 1966;18:997–1049.

Relation between critical illness polyneuropathy and axonal Guillain-Barré syndrome

The clinical entity critical illness polyneuropathy occurs almost exclusively in patients in critical care units and has been characterised as a complication of sepsis and multiple organ failure.^{1,2} Critical illness polyneuropathy may be a common cause of the difficulty in weaning patients from the ventilator, particularly those who show intractable ventilator dependence. All the measures used to prevent or treat sepsis and multiple organ failure are the main methods now used to deal with critical illness polyneuropathy. Knowledge of this type of polyneuropathy is of help in making decisions about respirator techniques, nursing care, prognosis, and overall management. Moreover, recognition of critical illness polyneuropathy indicates the need for physiotherapy, rehabilitation, and other supportive measures as the patient recovers. Bolton *et al*³ have made an important positive contribution to the care of patients with critical illness polyneuropathy. The actual aetiology, however, has yet to be determined. The pathogenesis needs to be clarified to treat patients more effectively.

Critical illness polyneuropathy invariably occurs at the peak of critical illness and sepsis, but in Guillain-Barré syndrome there is a brief period of recovery after a relatively minor illness or inoculation. Except for differences in the predisposing causes, as Bolton *et al*³ reported, it is difficult to distinguish critical illness polyneuropathy from Guillain-Barré syndrome on purely clinical grounds. In both, polyneuropathy runs a monophasic course, the onset being relatively acute but with subsequent improvement in most instances. The clinical features also are similar; evidence of muscle weakness in all



four limbs, occasional involvement of facial muscles and frequent involvement of the muscles of respiration, the depression or absence of deep tendon reflexes, and some evidence of distal sensory impairment.

The first step by Bolton *et al*³ in determining exact aetiology was to differentiate critical illness polyneuropathy from Guillain-Barré syndrome. In reviewing the patients with critical illness polyneuropathy and Guillain-Barré syndrome who were studied in their EMG laboratory, they found marked differences between the two types of polyneuropathy. Patients with Guillain-Barré syndrome had greater slowing of the speed of impulse conduction, and, in the initial stages, abnormal spontaneous activity in the muscle was absent, indicative of a predominantly demyelinating polyneuropathy. The CSF was only mildly increased in patients with critical illness polyneuropathy, but it was much increased in patients with Guillain-Barré syndrome. Comprehensive studies done at necropsy and nerve biopsies of patients with critical illness polyneuropathy showed the presence of primary axonal degeneration of the motor and sensory fibres, mainly distally, with no evidence of inflammation.² Zochodne *et al* (including Bolton) therefore concluded that the two types of polyneuropathies most probably are separate entities.

Guillain and colleagues enumerated the clinical and spinal fluid features of one form of acute flaccid paralysis without regard for the underlying physiology or pathology. Classic pathological studies of Guillain-Barré syndrome, however, have identified prominent demyelination and inflammatory infiltrates in the spinal roots and nerves. Guillain-Barré syndrome often has been considered to be synonymous with the pathological designation of acute inflammatory demyelinating polyneuropathy, and physiological abnormalities consistent with demyelination have been taken as supportive evidence for the diagnosis of Guillain-Barré syndrome. Feasby *et al* (with Bolton)³ first called attention to patients who were clinically considered as having Guillain-Barré syndrome, but who were characterised electrophysiologically as having early axonal degeneration of the motor and sensory nerve fibres. The evidence included a rapid fall in compound muscle action potentials and sensory nerve action potentials, and no evidence of demyelination. Such patients often had severe paralysis and made a slow recovery, presumably reflecting the need to regenerate axons rather than remyelination. Pathological findings are consistent with axonal degeneration without demyelination. Feasby *et al*³ termed this pattern *axonal Guillain-Barré syndrome* and suggested that there is a fundamental difference in the underlying pathophysiology, resulting in primary axonal damage rather than demyelination. Griffin *et al*⁴ then confirmed the existence of the acute motor-sensory axonal neuropathy (AMSAN) pattern of Guillain-Barré syndrome described by Feasby *et al*.³

Infection caused by the gram negative bacterium *Campylobacter jejuni*, a leading cause

of acute diarrhoea, commonly precedes the development of Guillain-Barré syndrome.⁵ There is a close association between axonal Guillain-Barré syndrome and antecedent *C jejuni* infection.⁵ The antecedent infectious symptom was diarrhoea in three of five patients with axonal Guillain-Barré syndrome described by Feasby *et al.*³ Observations by Griffin *et al.*⁴ confirmed that AMSAN follows *C jejuni* infection. Serum samples from patients with axonal Guillain-Barré syndrome subsequent to *C jejuni* enteritis often have IgG class autoantibodies to gangliosides GM1, GM1b, GD1a, or GalNAc-GD1a in the acute phase of the illness,⁶ and there is molecular mimicry between these gangliosides and the lipopolysaccharides of *C jejuni* isolates from patients with Guillain-Barré syndrome.⁶ This ganglioside mimicry may trigger high production of the IgG anti-ganglioside antibodies, and these autoantibodies may cause motor nerve dysfunction in patients with GBS.

Interestingly, Hagensee *et al.*⁷ reported a case of "*C jejuni* bacteremia and subsequent Guillain-Barré syndrome" that occurred in a patient with chronic graft versus host disease after allogeneic bone marrow transplantation. Because there was acute flaccid paralysis associated with sepsis, some physicians might have diagnosed critical illness polyneuropathy. Conversely, the existence of this case strongly suggests that some diagnoses of critical illness polyneuropathy should actually be axonal Guillain-Barré syndrome or AMSAN. Our hypothesis of the nosological relation between critical illness polyneuropathy and axonal Guillain-Barré syndrome is shown in the figure. Serum IgG antibodies against GM1, GM1b, GD1a, or GalNAc-GD1a could be used as immunological markers for axonal Guillain-Barré syndrome.⁶ To examine the aetiology of critical illness polyneuropathy and its nosological relation to axonal Guillain-Barré syndrome, it is necessary to investigate whether patients with critical illness polyneuropathy have anti-ganglioside antibodies during the acute phase of the illness.

NOBUHIRO YUKI
KOICHI HIRATA

Department of Neurology,
Dokkyo University School of Medicine, Japan

Correspondence to: Dr Nobuhiro Yuki, Department of Neurology, Dokkyo University School of Medicine, Kitakobayashi 880, Mibu, Shimotsuga, Tochigi 321-0293, Japan.

- 1 Bolton CF, Laverty DA, Brown JD, *et al.* Critically ill polyneuropathy. Electrophysiological studies and differentiation from Guillain-Barré syndrome. *J Neurol Neurosurg Psychiatry* 1986;49:563-7.
- 2 Zochodne DW, Bolton CF, Wells GA, *et al.* Critical illness polyneuropathy. A complication of sepsis and multiple organ failure. *Brain* 1987;110:819-42.
- 3 Feasby TE, Gilbert JJ, Brown WF, *et al.* An acute axonal form of Guillain-Barré polyneuropathy. *Brain* 1986;109:1115-26.
- 4 Griffin JW, Li CY, Ho TW, *et al.* Pathology of motor-sensory axonal Guillain-Barré syndrome. *Ann Neurol* 1996;39:17-28.
- 5 Rees JH, Soudain SE, Gregson NA, *et al.* Campylobacter jejuni infection and Guillain-Barré syndrome. *N Engl J Med* 1995;333:1374-9.
- 6 Yuki N. Anti-ganglioside antibody and neuropathy. Review of our research. *J Periph Nerv Syst* 1998;3:3-18.
- 7 Hagensee ME, Benyunes M, Miller JA, *et al.* Campylobacter jejuni bacteremia and Guillain-Barré syndrome in a patient with GVHD after allogeneic BMT. *Bone Marrow Transplant* 1994;13:349-51.

Repetitive transcranial magnetic stimulation in the treatment of chronic negative schizophrenia: a pilot study

Recently, a new technology known as repetitive transcranial magnetic stimulation (RTMS) has been developed.¹ In 1994, the use of magnetic stimulation in clinical psychiatry was suggested.² Since then, it has been used in the study or treatment of obsessive-compulsive disorder, conversion disorder, schizophrenia, and particularly, depression.³

Our pilot study aimed to assess the possible adverse effects of this treatment in chronic schizophrenic patients with severe negative symptoms; to evaluate if direct RTMS of the prefrontal cortex might improve negative symptoms or cognitive impairments⁴ in patients with chronic schizophrenia; and thirdly, to note if RTMS might modify the deficit in prefrontal cortical activity, often referred to as hypofrontality, long established in schizophrenia,⁵ specially under conditions of task activation.

Six right handed patients with chronic schizophrenia were identified at the outpatient psychiatric service of the Hospital Clínic of Barcelona. There were two men and four women (mean age 39).

Exclusion criteria included alcohol or substance abuse dependence disorder in the past 5 years, focal neurological findings, systemic neurological illness, taking cerebral metabolic activator or vasodilator medications, electroconvulsive therapy within 6 months, and significant abnormal findings on laboratory examination.

All patients were taking neuroleptic drugs, but a stable dose for at least 3 months was required. All patients were studied off benzodiazepines for at least 1 week before beginning the treatment. During the RTMS, psychotropic medications were continued at the initial dosage.

All patients were admitted to hospital. Inpatients underwent the UKU side effects scale,⁶ the positive and negative syndrome scale (PANSS), and a neuropsychological battery, the day before beginning the treatment and at the end of the treatment. The UKU scale was also administered after each session.

An equivalent neuropsychological battery was used on both occasions, which consisted of the block design subtest of the Wechsler adult intelligence scale, the trail making tests A and B, the FAS verbal fluency test, and two subtests of the Wechsler memory scale (the visual memory reproduction and the verbal paired associates subtests).

A brain SPECT study was performed using a rotating dual head gamma camera, fitted with high resolution fanbeam collimators. Two ^{99m}Tc-HMPAO SPECT scans with cognitive activation, such as the Wisconsin card sorting test (WCST), were performed on each patient (24 hours before the beginning of the treatment and 24 hours after the last session).

RTMS was given with a Mag Pro magnetic stimulator, 5 days a week, during 2 weeks, at a dosage of 20 Hz for 2 seconds, once per minute for 20 minutes at 80% motor threshold. The motor threshold was determined by visualisation of finger movement. A butterfly magnetic coil was placed tangential to the orbital area, on the C₃ and C₄ EEG point.

An important finding of this study was that RTMS may be given to stable schizophrenic patients without exacerbating their psycho-

Table Neuropsychological tests and PANSS scores

Test		Mean (SD)	
Block design	Pre	49 (11.95)	NS
	Post	50 (8.69)	
Trail making test A	Pre	38.3 (9.83)	NS
	Post	42.6 (14.1)	
Trail making test B	Pre	38.3 (4.5)	NS
	Post	41 (10.03)	
Immediate visual reproduction	Pre	50.5 (4.82)	NS
	Post	54.8 (11.2)	
Delayed visual reproduction	Pre	46.19 (8.23)	p<0.05
	Post	53.8 (12.64)	
Immediate verbal paired associates	Pre	54 (7.46)	NS
	Post	59.5 (10.03)	
Delayed verbal paired associates	Pre	8.8 (1.1)	NS.
	Post	8.8 (1.17)	
PANSS-PG	Pre	37.67 (11.15)	NS
	Post	36.5 (11.47)	
PANSS-N	Pre	31.67 (8.26)	p<0.02
	Post	27.83 (8.47)	
PANSS-P	Pre	16.83 (7.28)	NS
	Post	15.33 (7.55)	

Pre=pretreatment; Post=post-treatment; PANSS=positive and negative syndrome scale; PG=general psychopathology scale; N=negative scale; P=positive scale.

ses. All patients tolerated the RTMS well, with minimal side effects (mild headache and tinnitus).

Initial SPECT of one patient was reported to be normal, showing no evidence of hypofrontality. The remainder of the patients showed hypofrontality on the initial neuroimaging. The results after RTMS indicated no change in the hypofrontality.

Negative symptoms showed a general decrease for all patients (table). Significance (p<0.02) was noted on the PANSS negative symptoms subscale. These patients seemed to be more sociable than when originally seen. Nevertheless, clinical effects of the RTMS were subtle and difficult to distinguish from those derived from the supportive environment of the psychiatric ward.

With regard to the neuropsychological battery, we found a general improvement in all post-treatment scores (table), but only delayed visual memory achieved significance (p<0.05). This feature might be basically explained by improvement of attention, specifically of the maintenance of attention, which allows the correct function of the working memory. Thus, although there are methodological limitations regarding the power of our conclusions, it is certain that there has been an improvement in the attentional capability.

We found that all patients (except one, who was always within the normal range) diminished their number of perseverative answers and errors on WCST (items characteristically altered in schizophrenia) after the RTMS. However, significance was not achieved on any WCST scores.

Two patients who initially did not perform any categories on WCST, after the treatment, achieved one category, a possible indication of improvement of their abstract thinking. This change leads us to consider a research strategy previously reported, in which the WCST is used as a screening test for selecting schizophrenic patients. Those initially achieving low category scores would be compared to higher category scorers in an effort to identify a subgroup most likely to benefit from RTMS.

Taking into account these mild improvements together, and the lack of changes in

hypofrontality after treatment, we are considering extending the treatment course to 20 sessions, each at 30 Hz for 1 second, at 90% of motor threshold. It was also suggested that other positions of the coil and other kinds of coils might give better results.

The clinical change in our cohort after the RTMS could be attributed to both the treatment and the supportive environment of the psychiatric ward, and even to enhance compliance to medication during hospital admission. We are aware that the small sample size and lack of controls compel a very careful interpretation of the results. Nevertheless, in the light of these, we suggest further controlled studies of the efficacy of RTMS in negative symptoms of schizophrenia, not only as an add on technique but also as a sole therapeutic procedure. Research on RTMS also requires some controlled studies aimed to the complexity of the methodology (dosage, duration, and localisation), as this form of intervention may prove to be an economical and convenient therapy in treating several psychiatric disorders.

E COHEN

M BERNARDO

J MASANA

F J ARRUFAT

V NAVARRO

Department of Psychiatry

J VALLS-SOLÉ

Department of Neurophysiology

T BOGET

N BARRANTES

S CATARINEU

M FONT

Department of Psychology

F J LOMEÑA

Department of Nuclear Medicine,

Institut d'Investigacions Biomèdiques August Pi i Sunyer, Hospital Clínic i Provincial, Universitat de Barcelona, Spain

Correspondence to: Dr M Bernardo, Servicio de Psiquiatría, Hospital Clínic i Provincial, Villarroel 170, 08036 Barcelona, Spain. Telephone 00343 2275400, ext 2405; fax 00 343 2275477; email bernardo@medicina.ub.es

- 1 Barker AT, Jalinous R, Freeston IL. Non-invasive magnetic stimulation of the human motor cortex. *Lancet* 1985;i:1106-7.
- 2 George MS, Wassermann EM. Rapid-rate transcranial magnetic stimulation and ECT. *Convuls Ther* 1994;10:251-4.
- 3 Pascual-Leone A, Catalá MD, Pascual-Leone AP. Lateralized effect of RTMS on the prefrontal cortex on mood. *Neurology* 1996;46:499-502.
- 4 Elliot R, Sahakian B. The neuropsychology of schizophrenia: relations with clinical and neurobiological dimensions. *Psychol Med* 1995;25:581-94.
- 5 Wolkin A, Sanfilippo M, Wolf AP, et al. Negative symptoms and hypofrontality in chronic schizophrenia. *Arch Gen Psychiatry* 1992;49:959-65.
- 6 Lingjaerde O, Ahlfors UG, Bech P, et al. The UKU side effects scale. *Acta Psychiatr Scand* 1987;76(suppl 334):1-100.

CORRESPONDENCE

Sensory alien hand syndrome

The case report by Ay *et al*¹ of alien hand syndrome and review of the literature neglected the intriguing issue of why in every case so far reported the patient seems to be terrified of

the alien limb. Not believing that you are any more in control of a limb is not likely to be a pleasant experience.

Those with alien hand syndrome seem to jump to extremely negative conclusions concerning the intent of the limb. Typically, as in the report of Ay *et al*, the common belief is that the limb has deeply malevolent intentions towards the victim.

It is this aspect of alien hand syndrome that I suggest also needs incorporating into its neurological explanations, and which provides a clue as to why our everyday experience of being in charge of our bodies, and so initiating all personal action, itself has a neurological basis. In other words, while the brain is the seat of all our actions and experiences, there is also a part of our nervous system which is responsible for our belief that we have free will over our behaviour. Patients with alien hand syndrome think that they are no longer in control of a limb because the part of the brain that gives us the sensation of control over our bodies has been damaged. When that happens, our limbs seem to act independently of us.

Research² conducted in the 1980s has found that the same electrical brain wave changes that characteristically precede all limb movements, occur several 100 ms before we seem to consciously decide to move a limb. If our conscious decision to act is preceded by brain changes that anticipate action, then our "decision" to choose how to behave or "freedom", as in free will, is in fact illusory. Our choices have in a sense been decided beforehand by our brains.

Spence³ asserts that evidence such as this, combined with phenomena such as alien hand syndrome, means that philosophers have to reconsider whether we have free will. He argues that these data suggest that our sense of agency is illusory and it follows that most of us share in common the useful delusion that we have free will. Patients with alien hand syndrome have lost this experience in relation to a particular limb. There is a sense then that those who experience the syndrome are closer to the reality of how much we are responsible for our actions than the rest of us. This is because they have lost the function of the part of the brain that normally works to make us think that we have conscious freedom of will. They develop the experience, therefore, of becoming mere remote spectators to the actions of their bodies.

Defenders of human "free will" argue what happens before the brain itself decides to act is still unknown, and there may be a role for our own autonomy there. But even these free will guardians concede the neurological research indicates that whatever happens before the brain is roused, must occur below our conscious awareness.

Yet in alien hand syndrome the patient thinks that the hand has hostile motivations; it is invariably the case that the patient not only thinks that the limb is "not self" but finds that the limb behaves towards the self in a destructive and aggressive manner. This could be explained by the suggestion that if we lose our conscious sense of voluntary control over our bodies, our minds have to come up with an explanation for the location of action of our movements. We decide that if ourselves are not in control, then someone or something else must be; therefore, we no longer have a sense of the limb belonging to us.

Because to lose control over our bodies is one of the most terrifying experiences, our

attempt to explain this finding occurs in the context of fear. It may be that our apprehension leads us to misinterpret innocent reflexive acts of our hands, such as scratching or rubbing, as malevolently inspired. Plus it could be that our interpretation of spiteful possession in turn inspires the hand itself, only this is beyond our conscious awareness.

It may therefore be that we need to believe in our own free will and personal control over our acts, because if we did not, we might find the experience of our bodies acting as if we merely came along for the ride, too frightening. Also, we may no longer believe that our bodies or its relevant parts belong to us. All neurologists who have reported alien hand syndrome remark on how psychologically disturbing the symptom is for the patient. Psychiatrists would be interested in the parallels between alien hand syndrome and the "passivity phenomena" of schizophrenia, plus the fact that the two diseases may share corpus callosum pathology,⁴ could go some way to explaining why schizophrenic symptoms are frightening to the patient. So it seems we know that our limbs belong to us because they obey us. When they seem to stop responding to our wills, we conclude that our limbs are no longer our own, and try to fend them off. Hence it would seem that one of the prices we had to pay for conscious awareness of ourselves to evolve as a function of the brain, is the delusion that we are responsible for all our actions. If we had conscious awareness of ourselves, but no sense of free will, our bodies would feel alien to us. The philosophical importance of alien hand syndrome is that it shows emphatically via neurology that it is possible to drive a wedge between consciousness and the experience of free will. The brain had to develop the sensation of free will after developing consciousness, because being without the sensation of free will produces extremely negative emotional experiences. So the fact that every case so far reported of alien hand syndrome imputes negative intent to the alien limb might not be an incidental finding, but a core aspect of the disorder.

R PERSAUD

The Maudsley Hospital, Croydon Mental Health Services, Westways Rehabilitation Unit, 49 St James's Road, West Croydon, Surrey CR9 2RR, UK. Telephone 0044 181 700 8512; fax 0044 181 700 8504; email rajendra@btinternet.com

- 1 Ay H, Buonanno FS, Price BH, et al. Sensory alien hand syndrome: case report and review of the literature. *J Neurol Neurosurg Psychiatry* 1998;65:366-9.
- 2 Libet B, Gleason CA, Wright EW. Time of conscious intention to act in relations to onset of cerebral activity: readiness-potential. *Brain* 1983;106:623-42.
- 3 Spence SA. Free will in the light of neuropsychiatry. *Philosophy Psychol Psychiatry* 1996;3:75-90.
- 4 Crow TJ. Schizophrenia as a transcallosal misconnection syndrome. *Schizophr Res* 1998;30:111-4.

The authors reply:

We appreciate Persaud's comments regarding the alien hand syndrome, "the perceived malevolence of the affected limb towards its victim, and the question of whether with loss of the conscious sense of voluntary control over our bodies, our minds... decide that if ourselves are not in control then someone or something else must be". We would offer that the value of our particular case is that it was due to a central deafferentation—therefore the term "sensory alien hand syndrome". As

opposed to the idea that “we know our limbs belong to us because they obey us”, we know that our limbs belong to us because they provide us with sensory input that is recognised as self. Many patients with movement disorders or paralysis lose control of their limbs but still have no difficulty in realising them as self. Indeed even in “phantom limb” there is sense of self due to central processes in the absence of a limb. Our patient, as do others with anosognosia and primary abnormalities of central sensory systems, shows perhaps that it is central sensory processes that are the key to identifying “self”. We know our limbs not because they obey us but because there is a pattern of sensory activation that accompanies our own limb movements. When this pattern never reaches specific cortical regions, then the limb is not perceived as self; called “amorphosynthesis” by Denny-Brown and Banker.¹ Self stimulation by the centrally deafferented limb in “sensory” or “posterior” alien hand syndrome, or kinaesthetic stimuli due to movement of the limb as in the “anterior” or “motor” alien hand syndrome, is perceived as due to another person or thing without critical questioning. This raises the most interesting question of what brain region is deafferented in the anterior alien hand syndrome where the sensory processing is intact.

It is not our clinical experience nor the conclusions based on published reports that all patients suffering with alien hand syndrome are terrified by the effected limb. In one author's experience (BHP), two patients with alien hand syndrome and related intermanual conflict were irritated by but not terrified by their opposing limbs simultaneously vying for a cigarette or book. Another patient was amused but rather indifferent to his affected left side. The most terrifying situation we have heard is when the patient identified his affected left side as belonging to his mother in law! A patient reported by Heilman's group² with persistent alien hand syndrome referred to it as “my little sister”. Similar to our experience, they suggest that a predisposing personality type may be necessary given that most patients with colossal infarcts or tumours do not emphasise this complaint.

Unlike our case of limited duration, the persistence of alien hand syndrome seems dependent on mesial frontal dysfunction. These patients rarely deny that the affected limb belongs to them. Instead, they understand it in terms of their “anarchic hand”. Hence, although the initial syndrome may result in disjointed and terrifying perceptions, it seems that the brain quickly re-establishes its control by presently unknown adaptive capacities. Furthermore, why it almost exclusively involves the left body side in right handed people remains unknown. Studying this syndrome in greater detail may yield additional insights into the pathophysiology of denial and misidentification.

HAKAN AY
FERDINANDO S BUONANNO
DEAN A LE
WALTER J KOROSHETZ

Department of Neurology, Stroke Service,
Massachusetts General Hospital, Harvard Medical
School, 32 Fruit Street, Boston MA 02114, USA

BRUCE H PRICE
Department of Neurology, McLean Hospital, 115 Mill
Street, Belmont MA 02178-9106, USA

1 Denny-Brown D, Banker B. Amorphosynthesis from left parietal lesion. *Arch Neurol Psychiatry* 1954;71:302.

2 Heilman KM, Valenstein E, eds. *Clinical neuropsychology 3rd ed.* New York: Oxford University Press 1993:361.

Vasomotor reactivity is exhausted in transient ischaemic attacks with limb shaking

The article of Baumgartner and Baumgartner entitled “Vasomotor reactivity is exhausted in transient ischaemic attacks with limb shaking” provides interesting new information regarding the nature of involuntary limb movements contralateral to haemodynamic failure from severe carotid artery occlusive disease. The authors evoke an “exhausted cerebral vasoreactivity in the hemispheres opposite the involuntary limb movements”. In their report, involuntary movements affected only the limbs, and displayed no tonic contraction, tonic-clonic jerking, or Jacksonian march and no epileptic activity during or between the attacks. These findings led the authors to strongly argue against seizures as the cause of limb shaking in these transient ischaemic events.

In contradistinction, a 72 year old right handed man was admitted to our hospital with a 3 month history of episodic weakness and numbness of the right arm. The patient then had six discrete stereotypic episodes of right arm weakness and clumsiness that were also associated with difficulty in speaking. Several episodes of dysarthria, numbness and weakness of the right arm and leg (MRC grade 4/5) were seen, unrelated to posture, some of which occurred when the patient was supine. Most episodes were characterised by slight tremulousness and asterixis-like movements of the outstretched right arm. There was a return to baseline functioning between events.² Video/EEG monitoring, however, showed low voltage spikes in the left central-parietal head regions contralateral to the facial twitching and the right arm and right leg weakness. Although ongoing clinical and EEG seizure activity stopped after 2 mg intravenous lorazepam, they reoccurred after loading with phenytoin. Because angiography disclosed a greater than 95% stenosis of the left internal carotid artery (while the patient was treated with phenytoin at a concentration of 16.5 mg/l), the patient was anticoagulated with heparin, but episodes continued. It was only after a left carotid endarterectomy that all episodes of weakness, tremulousness, and EEG epileptiform activity stopped. They have not recurred over the past 5 years.

The literature includes several cases of focal motor inhibitory seizures causing weakness.^{3,4} Although it is impossible to prove a negative, it could be argued that although no epileptiform or other evidence of seizure activity is present in a particular case, the abolition of ongoing clinical and EEG evidence of inhibitory motor activity by intravenous diazepam argues in favour, at least in part, of an ictal contribution. The fact that in virtually all reported cases, abnormal movements are more definitively resolved by carotid endarterectomy, argues for an underlying ischaemic aetiology that induces focal seizures. There are few reports that clearly delineate the interaction and association of inhibitory focal motor seizures and transient ischaemic attacks, as there are few sequential trials of antiseizure drugs or anticoagulation (under EEG monitoring) and finally carotid endarterectomy. Several authors support the concept of an inhibition of motor function in parietal and secondary somatosensory re-

gions by seizure activity which then interrupts the sensory feedback loop to motor integration with inhibition of subcortical and cortical areas.⁵

PETER W KAPLAN
Johns Hopkins Bayview Medical Center, 4940 Eastern
Avenue, Baltimore, MD 21224, USA

- 1 Baumgartner RW, Baumgartner I. Vasomotor reactivity is exhausted in transient ischaemic attacks with limb shaking. *J Neurol Neurosurg Psychiatry* 1998;65:561-4.
- 2 Kaplan PW. Focal seizures resembling transient ischemic attacks due to subclinical ischemia. *Cerebrovasc Dis* 1993;3:241-3.
- 3 Lee H, Lerner A. Transient inhibitory seizures mimicking crescendo TIAs. *Neurology* 1990;40:165-6.
- 4 Tinuper P, Aguglia U, Laudadio S, et al. Prolonged ictal paralysis: electroencephalographic confirmation of its epileptic nature. *Clin Electroenceph* 1987;18:12-14.
- 5 Luders H, Lesser RP, Dinner DS, et al. The secondary sensory area in humans: evoked potential and electrical stimulation studies. *Ann Neurol* 1985;18:177-84.

Baumgartner and Baumgartner reply:

We are grateful for the response of Kaplan to our short report. We agree that somatic inhibitory seizures may mimic transient ischaemic attacks (TIAs). Such TIAs are associated with negative symptoms such as sensorimotor deficits and difficulty with speaking, EEG evidence of seizure activity, and ceasing of the TIAs after the administration of an anticonvulsant drug.^{1,2} Limb shaking TIAs, however, differ from TIAs related to inhibitory seizures in several ways. (1) They are associated with positive phenomena (limb shaking), and the involuntary movements do not affect the facial muscles. (2) Patients with attacks of shaking movements of the limbs have no EEG evidence of epileptic activity, and involuntary movements do not stop after administration of anticonvulsive therapy. (3) Although the patient presented by Kaplan had a 95% stenosis of the left internal carotid artery, it is unclear whether haemodynamic failure was present or not, because no studies evaluating the haemodynamic reserve of the homolateral hemisphere were presented. This is in accordance with the finding that the involuntary movements as well as the sensorimotor deficits of Kaplans' patient were not related to posture. (4) The pathogenesis is thought to be due to disinhibition of subcortical control mechanisms as a result of ischaemia.

In our opinion, it is not clear whether the asterixis-like movements of the outstretched right arm of Kaplan's patient are due to epileptic seizures, because unilateral asterixis of the outstretched arm has been reported with contralateral vascular lesions affecting almost all cerebral structures involved in motion control including ischaemia in the territory of the middle cerebral artery.³

RALF W BAUMGARTNER
Department of Neurology, University Hospital of
Zürich, Switzerland

IRIS BAUMGARTNER
Division of Angiology, University Hospital of Bern,
Switzerland

Correspondence to: Dr Ralf W Baumgartner, Neurologische Klinik, Frauenklinikstrasse 26, CH-8091 Zürich, Switzerland. Telephone 0041 1 255 56 86; fax 0041 1 255 43 80; email Strusb@neuro.unizh.ch

1 Kaplan PW. Focal seizures resembling transient ischemic attacks due to subclinical ischemia. *Cerebrovasc Dis* 1993;3:241-3.

- 2 Lee H, Lerner A. Transient inhibitory seizures mimicking crescendo TIAs. *Neurology* 1990;40: 165-6.
- 3 Melo TP, Bogousslavsky J. Specific neurologic manifestations of stroke. In: Ginsberg MD, Bogousslavsky J, eds. *Cerebrovascular disease. Pathophysiology, diagnosis, and management*. Vol 2. Malden, MA: Blackwell Science, 1998:961-85.

BOOK REVIEWS

Neurology for the MRCP Part II. By DAVID SMITH. (Pp164, £15.99). Published by Arnold, London 1998. ISBN 034069175.

To the MRCP candidate neurology is one of the more daunting specialties. The unfamiliar nerve conduction study and the frankly mysterious EEG can distress an otherwise well rounded senior house officer. Despite the fact that much of neurology is commonly seen on a general medical ward—strokes, dementias and so forth—the general perception is of an unimaginable list of eponymous syndromes and obscure signs. Rather than dwell on the last, in this book Dr Smith tries to address the commoner complaints as examination style questions each with a “simple clinical lesson”. The “grey case” section, for instance, includes questions on multiple sclerosis, cluster headache, and HSV encephalitis, while broadening the topics to include postinfective demyelination, chronic hemiparesis, and acute haemorrhagic encephalomyelitis. There is, however, a tendency for the discussion after each question to be rather brief. A fuller explanation, with more allowance for the reader's ignorance, would have been appreciated. The data interpretation section is somewhat better, covering CSF, EEG, and other data extremely well. Perhaps a little too well; would an MRCP candidate really be expected to recognise the characteristic EEG of Creutzfeldt-Jakob disease? I surely hope not. Finally, the slide tests are disappointing. If anything, neurology lends itself best to this section of the written examination but it is let down by the poor quality of some of the images in this book. This is especially unfortunate, as other images in the same section are remarkably impressive. The Sturge-Weber skull radiograph and central pontine myelinolysis MRI are beautiful. In summary, this is a creditable first edition. I look forward to the second.

STEFAN MARCINIAK

An Atlas of Multiple Sclerosis. Edited by Charles M Poser. (Pp 134, £48.00/\$85.00). Published by Parthenon Publishing, Carnforth 1998. ISBN 1-85070-946-7.

This book, after a short introduction to some of the fundamental features of the disease goes on to provide some 117 illustrations of aspects of the disease from Cruveilhier's plates to histopathological specimens and also a heavy leaning to imaging particularly magnetic resonance scanning, as might be expected. There is no doubting the aesthetic impact of this short book. In addition, the fact that these illustrations emanate from a well established figure in the multiple sclerosis world and are likely to be a representative set

of personal teaching slides from a successful academic career all vouch for the provenance and informative nature of the atlas. However the place of such a book within a neurologist's library has to be questioned. There are a plethora of high quality textbooks devoted to all aspects of multiple sclerosis, all well illustrated and most in colour. They provide in depth analysis of all aspects of the disease and although their illustrations tend to be smaller this is where I would choose to put my money. It may be that the circulation of this book will be higher than expected as it is likely to be a popular choice for some pharmaceutical companies.

NEIL ROBERTSON

Calvarial and Dural Reconstruction.

Edited by SETTI R RENGACHARY and EDWARD C BENZEL. (Pp 200). Published by AANS, Illinois 1998. ISBN 1-879284-63-4.

This monograph is the latest to be produced by the American Association of Neurological Surgeons as part of its *Neurosurgical Topics* series. It begins by tracing the history of calvarial reconstruction from ancient times. There follows a discussion of the different autologous donor sites and synthetic materials currently available for repair of calvarial and facial defects. The merits, disadvantages, and contraindications of each are considered. Dural substitutes are then dealt with in similar fashion. Specific problems, such as scalp reconstruction, the management of comminuted frontal sinus fractures, and reconstruction of the anterior skull base are the subject of separate chapters. The final part of the book is devoted to craniosynostosis. A review of current knowledge on pathogenesis is followed by a good account of some of the more common techniques used to treat single suture synostosis. Understandably, in a book of this type there is space only for an overview of the treatment and complications of multi-suture involvement, but the chapter provides well chosen references for further reading.

The reconstruction of traumatic and post-surgical calvarial defects occupies the bulk of this volume, and is dealt with very effectively. Operative techniques and the relative merits of various materials are covered in a clear and concise manner. By contrast, the section on aural substitutes is a little disappointing because it does not provide the reader with reasoned argument on how to select the most appropriate graft from the sometimes bewildering variety of autologous, synthetic, and xenograft materials which are available when vascularised pericranial tissue is not an option.

Craniosynostosis is a topic which is covered very well in standard paediatric neurosurgical texts and it is not worth buying this book for that section alone. However, the account of techniques for repair of calvarial defects is excellent and merits the inclusion of this text in a departmental library.

ROBERT MACFARLANE

Echoenhancers and Transcranial Color Duplex Sonography.

Edited by ULRICH BOGDAHN, GEORG BECKER, and FELIX SCHLACHETZKI. (Pp 420). Published by Blackwell Science, Oxford 1998. ISBN 0-632-04856-5.

Transcranial colour duplex sonography is an ultrasound technique which is becoming

increasingly available for the non-invasive imaging of intracranial structures, particularly the basal cerebral arteries. There are now four principal components to the technique: B mode ultrasound which can be used to image the brain parenchyma; colour coded Doppler which provides a colour image of the basal vessels; spectral analysis of pulsed wave Doppler which is used to derive blood flow velocities; and latterly “power” Doppler which is also used for vascular imaging following analysis of the amplitude rather than the frequency of the reflected ultrasound beam. In addition, echocontrast agents are now available which can increase the signal to noise ratio and thus help overcome some of the detrimental acoustic effects of the skull.

This volume of 400 pages and liberal colour diagrams and prints is edited by three exponents of the technique. Thirty one chapters written by a further 20 contributors cover topics from the history of transcranial ultrasound, through the physics of Doppler ultrasound to potential clinical applications. The book is helpfully split into two sections with the theoretical aspects described in the first half and clinical aspects in the second.

This is certainly a specialised book and will really only appeal to those interested in, or wishing to develop, expertise in transcranial colour coded ultrasound. For such readers the technical chapters on instrumentation, signal processing, echocontrast agents, harmonic imaging etc will certainly provide a complete understanding of the principles behind the technique. I think that some of the errors made in the interpretation of vascular ultrasound examinations are due to an incomplete understanding of the physics of Doppler ultrasound, hence the attention paid to this area is commendable.

The clinical section covers the examination technique, normal reference values, the main categories of cerebrovascular disease, and also contains chapters on areas which may be less immediately suitable for ultrasound study. For example, the findings in head trauma, tumours, psychiatric disorders, and movement disorders are the subject of separate chapters. Although I have no problem with enthusiasm for this technique a little pragmatism would not go amiss. A more balanced discussion of the limitations as well as potentials of the technique could have been applied.

As with any book with multiple authors there is some variation in style and overlap, particularly in the introductions and conclusions of the chapters. Nevertheless, it is a comprehensive current review of transcranial colour coded sonography. Although the reader must decide exactly how this technique fits into clinical practice the book will certainly stimulate some ideas.

PETER MARTIN

Spinal Cord Diseases-Diagnosis and Treatment.

Edited by GORDON L ENGLER, JONATHAN COLE, and W LOUIS MERTON. (Pp 675, US\$195). Published by Marcel Dekker, New York, 1998. ISBN 0-8247-9489-3.

This is volume 47 of a series entitled *Neurological Disease and Therapy*, series editor W C Koller. This volume is edited by an American surgeon and two British neurophysiologists. Most of the 45 contributors are American or British, almost half of whom, including Dr Cole, are from Southampton. The book begins with a pathophysiological

introduction setting the scene for the five main disease sections covering developmental/genetic disease, spinal injury, infection, tumour, and the effect of neurological and systemic disease on the spinal cord. This chapter covers a wide area from multiple sclerosis to motor neuron disease to vascular disease to metabolic diseases. Then follows a section on investigation considering imaging, neurophysiology, and urodynamics. Finally, there is a miscellaneous section covering clinically important entities such as pain, sexual problems, and terminal care associated with spinal cord disease but also including a highly specialised chapter on the role of omental transfer in spinal cord injury.

This is an ambitious attempt at being comprehensive. The editors themselves worry that the emphasis favours surgical conditions. Although this might be the case, many surgical cases present to the neurologist or rheumatologist, care for spinal disease often falling between several specialties. Therefore, it is of benefit to the clinician to have all aspects of spinal disease in one volume. The standard and style of the individual chapters varies, that on motor neuron disease being up to date and topical, malignancies being covered in depth. That on sexual problems associated with spinal cord disease is excellent, particularly practical and a must for both doctors dealing with spinal disease and for patients themselves who are often uninformed (our fault, not theirs). The chapter on decompression illness will be food for thought for many doctors who enjoy recreational diving, for although studies have not yet shown adverse effects on the quality of life in those who dive frequently but without incident, the evidence for cumulative neurological damage from neurophysiological, imaging, and pathological studies is compelling.

The quality of illustration is high. Perhaps not surprisingly, this is particularly evident in the imaging section (where there is a rather spectacular sagittal T2 weighted MRI of an intramedullary arteriovenous malformation). In addition to imaging many of the chapters also make good use of schematic diagrams and line drawings to enhance the text.

Drs Engler, Cole, and Merton end their preface by commenting that "Our main hope, however, is that the chapters will read as a series of views on the spinal cord and its disease, so that a surgeon may learn about current practice as well as the wide range of conditions affecting the cord that are outside the field of surgery". While I agree that educating surgeons is an admirable aim, I think that the authors rather undersell themselves and that this book's main strength, as I have said above, is that it will appeal to all disciplines that deal with spinal cord disease, bringing together neurological, rheumatological, and surgical disease that is often covered in separate textbooks.

GILLIAN HALL

Neurologic Disease in Women. Edited by Peter Kaplan. (Pp 480 \$150). Published by Demos, New York 1998. ISBN 1-888799-153.

This is the second time that I have been asked to review a book on this topic. The first time I approached the task with some scepticism—were neurological diseases in women really so different from those in men that they warranted their own text book? But I rapidly became a convert to the cause, being reminded that there are issues specific to females that influence both disease, investigation, and treatment (pregnancy, breast feeding, menopause, to name the most obvious) and that not all neurological diseases attack the sexes equally. There are also wider socio-economic and legal issues that play a part in the complete disease picture which many of us neglect too often but which this book is careful to address (see below). Leaving content aside for a moment, this is a beautifully presented book; clearly headed and with wide use of well constructed tables. It encourages one to read on. It seems up to date and well referenced.

The contributors (40 in total) are exclusively American, and east coast American at that with only occasional forays westward. The text is divided into three sections. The first, entitled *General Issues in Women* includes an anatomical chapter considering the sex differences of regional brain structure and function. More novel for this type of text, it contains two thoughtful chapters considering women's health within the context of their lifestyles and women's health and its relation with the law. This chapter considers issues such as coercive approaches to preventing foetal harm, those relating to informed consent to medical treatment, and difficult choices with neurological implications. The law and the case examples are exclusively American but the issues are universal. This opening section leaves no doubt that this is a book that has taken female issues extremely seriously.

The second section looks at neurological diseases as they affect females at different life stages, from birth through menarche, pregnancy, and menopause, to the elderly woman. As well as considering genetic diseases that strike at a particular age, these chapters consider the influence of changing physiology and hormonal balance on neurological disease. The third section is the most conventional. Each chapter considers a neurological disease representing these diseases with emphasis on their effect on women and there is, by necessity, some overlap between this and the previous section. As a non-American, I would feel more comfortable to believe that the high number of female patients with peripheral nerve injuries secondary to physical beatings, knife wounds, or gunshot wounds reflected the country of origin of this book!

If pushed to criticise, the indexing could be more complete and certain conditions considered in more detail, in particular, paraneoplastic conditions associated with breast and gynaecological malignancies. However, that aside, I think this a rather special book and not only a good addition to any neurological library but a useful purchase for anyone interested in female medical issues.

GILLIAN HALL

The reader may be interested in the following:

Neuro-Oncology for Nursing. Edited by DOUGLAS GUERRERO. (Pp 330, £24.50). Published by Whurr Publishers Ltd, London 1998. ISBN 1-86156-087-7.

A Research Portfolio on Chronic Fatigue. Edited by ROBIN FOX. (Pp 72, £14.95). Published by The Royal Society of Medicine Press Ltd, London 1998. ISBN 1 85315 367 2.

CORRECTION

Hanna PA, Jankovic J, Vincent A. Comparison of mouse bioassay and immunoprecipitation assay for botulinum toxin antibodies. *J Neurol Neurosurg Psychiatry* 1999;**66**:612–16.

During the editorial process the descriptions of the histograms in figure 4 (p 614) were wrongly ascribed. The corrected figure is reproduced below.

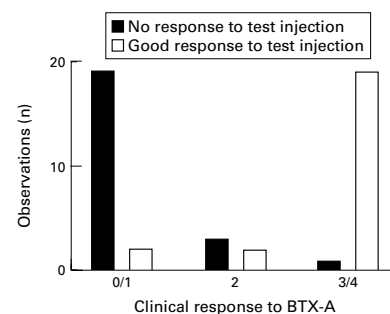


Figure 4 Correlation of clinical response (grade 0 or 1 response indicates non-responders, grade 2 response indicates reduced response, and grade 3 or 4 are responders) with response to test injections.