

Blink reflex R2 changes and localisation of lesions in the lower brainstem (Wallenberg's syndrome): an electrophysiological and MRI study

S Fitzek, C Fitzek, J Marx, H Speckter, P P Urban, F Thömke, P Stoeter, H C Hopf

Abstract

Objectives—Pathways of late blink reflexes are detected by high resolution MRI. Electronically matched stroke lesions superimposed to an anatomical atlas show the suspected course.

Methods—Fifteen patients with infarction of the lower brainstem, MRI lesions and electrically elicited blink reflexes were examined. The involved structures in patients with R2 and R2c blink reflex changes were identified by biplane high resolution MRI with individual slices matched to an anatomical atlas at 10 different levels using digital postprocessing methods.

Results—The blink reflexes were normal in five of 15 patients (33%) and showed loss or delay of R2 and R2c to stimulation ipsilaterally to lesion (R2-i and R2c-i) in eight (53%). Loss or delay of R2-i/R2c-i was seen in lesions covering the entire trigeminal spinal tract and nucleus (TSTN) at at least one level. These infarctions were located more dorsally within the medulla. Patients with normal blink reflexes showed lesions sparing or involving the TSTN only partially. They more often had incomplete Wallenberg's syndromes and MRI lesions were located more ventrally.

Conclusions—Using digital postprocessing MRI methods it was possible to identify central pathways of late blink reflex in patients with Wallenberg's syndrome. This method is suggested as a new approach to identify incompletely understood functional structures of the brainstem.

(J Neurol Neurosurg Psychiatry 1999;67:630-636)

Keywords: Lower brainstem; medullary infarction; blink reflex; magnetic resonance imaging

The diagnostic value of the blink reflex is well established in patients with peripheral¹⁻³ and brainstem lesions.⁴ However, the central pathways are still a debatable issue. The R1 loop probably runs from the trigeminal entrance zone at the lateral midpons to the ipsilateral facial nucleus, passing through or close to the trigeminal principal sensory nucleus.^{5,6} The R2 loop is thought to run with the descending trigeminal spinal tract to the caudal portion of the spinal trigeminal nucleus.⁷⁻⁹ From there fibres bilateral and medial to the trigeminal spinal tract and nucleus (TSTN) ascend to the facial nucleus^{9,10} with the contralateral fibres

likely to be closer to the midline.¹¹ Recent studies report a clinical and electrophysiological topographic correlation based on MRI.¹²⁻¹⁵ However, routine MRI does not allow precise identification of damaged structures and pathways and fails in giving a direct proof of correlation between functional deficit and anatomical structures. In our approach we used digital image processing methods in 15 patients with infarction of the lower brainstem. The MRI lesions were matched to the anatomical atlas of Schaltenbrand and Wahren¹ and localisation of the lesions were correlated with the structure of the descending trigeminal spinal tract and nucleus.

Methods

BLINK REFLEX

The blink reflex was evoked by stimulation of the supraorbital nerve. Stimuli of 0.1 ms duration and 3-20 mA intensity were applied percutaneously at intervals of 10-20 s. The orbicularis oculi muscle responses were recorded by surface electrodes with the active electrode over the lower lid halfway between the inner and outer edges of the orbit and reference electrode over the ipsilateral temple. Five successive trials were evaluated and the mean latencies calculated. Normal values from our laboratory were reported previously.¹⁶ The blink reflex was considered abnormal based on the following criteria: R1-i and R1-c (R1 to stimulation ipsilaterally and contralaterally to lesion): loss of R1, latencies above 12.0 ms, or side differences of 1.2 ms or more. R2-i and R2-c (R2 to stimulation ipsilaterally and contralaterally to lesion): loss of R2, latencies above 42.4 ms, or side differences of 5 ms or more. R2c-i and R2c-c (R2c to stimulation ipsilaterally and contralaterally to lesion): loss of R2c, latencies above 44.4 ms, or side differences of 7 ms or more.

Blink reflex responses were usually recorded within the first week after admission (median 5.5 days, range 2-19 days). With the exception of patient 5, who had a central type facial pain after infarction, all patients had acute strokes. The median time between onset of symptoms and first blink reflex recording was 11 days (range 3-22 days, and 2 years in patient 5). Early follow up examinations (10 days to 5 weeks after infarction) were performed with seven patients, late follow up (5 to 7 months after infarction) with five patients.

MRI

All patients except patient 10 had biplanar high resolution T2 weighted imaging of the brain-

Department of
Neurology
University of Mainz,
Germany
S Fitzek
J Marx
P P Urban
F Thömke
H C Hopf

Institute of
Neuroradiology,
University of Mainz,
Germany
C Fitzek
H Speckter
P Stoeter

Department of
Neurology, University
of Jena, Germany
S Fitzek

Correspondence to:
Dr Sabine Fitzek,
Department of Neurology,
University of Jena,
Philosophenweg 3, D-07740
Jena, Germany.

Received 5 January 1999 and
in revised form
15 April 1999
Accepted 9 June 1999

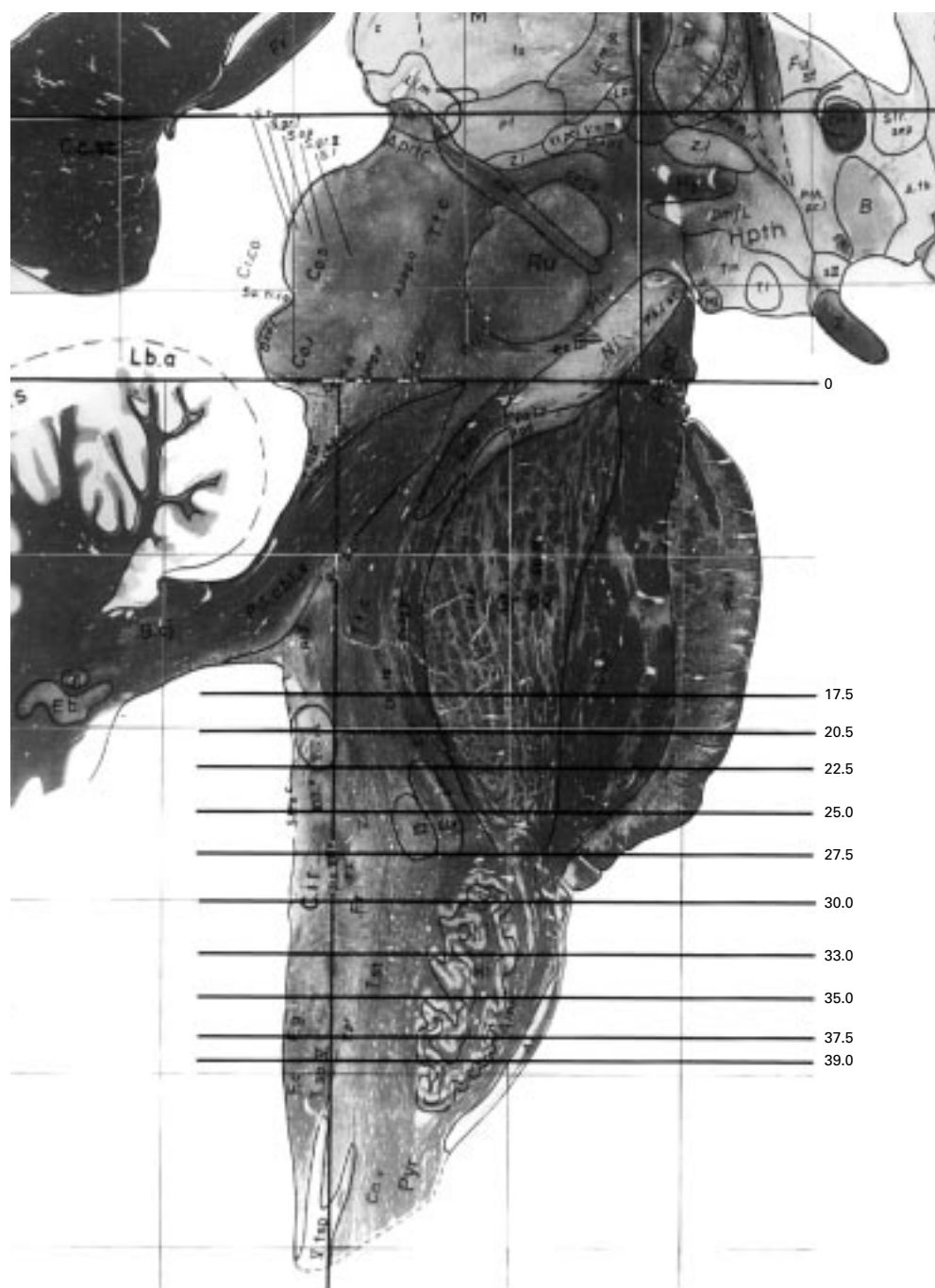


Figure 1 Sagittal view of brainstem demonstrating anatomical slices of the atlas of Schaltenbrand³ and Wahren¹ into which lesions had been projected. The zero point was set at the pontomesencephalic junction. The number of the level represents the distance in mm from the pontomesencephalic junction.

stem showing the location of the infarction. Brain MRIs were obtained in each patient within the first 2 weeks, except patient 5. In nine patients (1,3,6–9, 11, 14, 15) we followed a fixed protocol:

(1) EPI-T2 weighted and EPI-diffusion weighted imaging (DWI) within 24 hours after onset of symptoms: 1.5 T Magnetom Vision, TR 4000 ms, TE 103 ms, $b=1150$ s/mm² to identify the acute brainstem infarction. Scanning time per slice was 250 ms.

(2) High resolution T2 weighted imaging (slice thickness 3 mm) in the axial and sagittal

planes and T1 weighted imaging before and after intravenous administration of the contrast medium.

The slice orientation was parallel (sagittal sections) and perpendicular (axial sections) to the sagittal brainstem cuts of the Schaltenbrand atlas.

DIGITAL IMAGING POSTPROCESSING

The area of infarction was identified by two neuroradiologists (CF, PS) and one neurologist (SF). The individual slices were normalised (according to their T2 weighted and T1

Table 1 Wallenberg's syndrome was assumed if at least four of the six clinical signs of table 1 were present

- (1) Ipsilateral Horner's sign
- (2) Ipsilateral impairment of facial pain and/or temperature sensation
- (3) Palsy of cranial nerve IX or X
- (4) Contralateral impairment of pain and temperature sensation over trunk and limbs
- (5) Ipsilateral limb dysmetria
- (6) Astasia and gait ataxia

weighted brainstem outlines) and projected into 10 levels of the anatomical atlas of Schaltenbrand and Wahren.¹ The zero point was set at the pontomesencephalic junction and the number of the level represents the distance in mm from the zero point (fig 1). We used the sagittal or coronal slices (except patient 10) for normalising in the z axis and for determination of the best fitting of the Schaltenbrand plates. The axial plates were used for in plane normalisation. The sagittal and coronal normalisation was checked by setting the exit zone of the cranial nerves in projection to the Schaltenbrand plates. All right sided lesions were flipped to the left side for easier comparison. We then were able to study each lesion at every level in their relation to the anatomical structures determined by the Schaltenbrand atlas. Furthermore we could work out differences of locations of lesions in groups of patients corresponding to the electrophysiological findings: groups of slices of patients with normal (patients 1–5) and abnormal R2-i/R2c-i (patients 6–13) were matched to correlate the electrophysiological findings with brainstem topography. For post-processing we used Unix and NT-workstations

and Numaris, Photoshop, Photopaint, and AFNI¹⁷ software.

CLASSIFICATION OF THE CLINICAL CONDITION

As was proposed by others,¹⁸ Wallenberg's syndrome was assumed if at least four of six clinical signs in table 1 were present. Wallenberg's syndrome occurred complete, incomplete, and with additional symptoms. Skew deviation, which can be expected in 45% of patients with lateral medullary lesions,¹⁸ was listed as an "additional sign" in table 2 but did not lead to classification "Wallenberg's syndrome with additional symptoms".

STATISTICAL ANALYSES

For correlation analysis we used Fisher's exact test, and to compare distributions the Mann-Whitney test were applied. Statistical significance was set at $p < 0.05$. Statistical analysis were made with SPSS® software.

Results

GENERAL CHARACTERISTICS

Of the 15 patients, 12 were men (mean age 63 years; range 49–74) and three were women (mean age 63 years; range 42–87). Sonography or MRI angiography demonstrated occlusion of the ipsilateral vertebral artery in five patients (1, 3, 9–11) and stenosis in three patients (8, 12, 15). In two patients sonography demonstrated macroangiopathy of the internal carotid artery but no vertebral stenosis or occlusion. Patient 7 had Wegener's granulomatosis and in four patients (2, 4, 5, 14) aetiology of infarction remained unclear.

Table 2 Neurological disturbances, blink reflex responses, outcome, and associated lesions of 15 patients with infarction of the lower brain stem. Patients with normal blink reflexes (1–5) more often had an incomplete Wallenberg's syndrome (WS) than patients with loss or delay of R2-i/R2c-i (no 6–13). According to the outcome there was no significant difference between the two groups

Patient	WS signs*	Additional signs	Blink reflex†	Outcome‡	Associated lesions
1	1, 2, 3, 4, 5, 6 Complete	Contralateral. hemiparesis	Normal	5	PCA, cerebellum, and supratentorial vascular encephalopathy
2	2, 3, 6 Incomplete	No	Normal	2	No
3	1, 2, 3, 4, 6 Complete	Transient ipsilat. Facial weakness with sparing the upper face, skew deviation	Normal	3	Old lesions: MCA, basal ganglia, cerebellum
4	1, 3, 4 Incomplete	No	Normal	2	No
5	3, 4 incomplete	No	Normal	x	No
6	1, 2, 3, 5, 6 complete	Ipsilateral facial weakness with sparing the upper face	R1-i slightly delayed (12,1 ms), loss of R2-i /R2c-i	5	Old lesion: MCA
7	1, 2, 4, 6 complete	Skew deviation	R2-i side difference (not significant), R2c-i side difference	1	No
8	1, 2, 3, 4, 6 complete	Skew deviation	R2-i/R2c-i side difference	3	No
9	1, 2, 3, 4, 5, 6 complete	No	R2-i/R2c-i delayed	3	Cerebellum
10	1, 2, 3, 4, 5, 6 complete	No	Loss of R2-i/R2c-i	4	Cerebellum
11	1, 2, 3, 4, 5, 6 complete	Transient ipsilateral facial weakness with sparing the upper face	R2-i/R2c-i delayed	4	Cerebellum
12	1, 2, 3, 4, 5, 6 complete	No	Loss of R2-i/R2c-i, loss of R2c-c	4	Cerebellum
13	1, 3, 5, 6 complete	Skew deviation	Loss of R2-i/R2c-i	4	Cerebellum
14	2, 6 incomplete	Ipsilateral facial weakness of peripheral type, skew deviation	R2-i delayed, R2c-c side difference (not significant)	3	No
15	1, 2, 3, 4, 5, 6 complete	Ipsilateral facial weakness with sparing the upper face, skew deviation	Loss of R2-i/R2c-i, loss of R2-c/R2c-c	6	Old lesion: basal ganglia

*1=Ipsilateral Horner's sign; 2=ipsilateral impairment of facial pain and/or temperature sensation; 3=palsy of cranial nerve IX and/or X; 4=contralateral impairment of pain and temperature sensation over trunk and limbs; 5=ipsilateral limb dysmetria; 6=astasia and gait ataxia.

†R1-i=R1 to stimulation ipsilaterally to lesion; R1-c=R1 to stimulation contralaterally to lesion; R2-i=R2 to stimulation ipsilaterally to lesion; R2-c=R2 to stimulation contralaterally to lesion; R2c-i=R2c to stimulation ipsilaterally to lesion; R2c-c=R2c to stimulation contralaterally to lesion.

‡Outcome at time of discharge from neurological ward (modified Rankin scale): 0=no symptoms at all; 1=no significant disability despite symptoms; 2=slight disability; unable to carry out all previous activities but able to look after own affairs without assistance; 3=moderate disability; requiring some help; but able to walk without assistance; 4=moderately severe disability; unable to walk without assistance; and unable to attend to own bodily needs without assistance; 5=severe disability; bedridden; incontinent; and requiring constant nursing care and attention; 6=death; x=no acute infarction

Table 3 Location of lesions of patients with normal blink reflexes (1–5) and loss or delay of R2-i/R2c-i (6–13) and connection to the spinal tract and the nucleus of the trigeminal nerve. The number of the level represents the distance in mm from ponto-mesencephalic junction, corresponding to the slices of the anatomical atlas. Lesions of patients with abnormal R2-i/R2c-i involved the entire spinal tract and nucleus of trigeminal nerve at at least one level

Level	Anatomical landmarks	Patients with normal blink reflex					Patients with loss or delay of R2-i/R2c-i							
		1	2	3	4	5	6	7	8	9	10	11	12	13
17.5	Cerebellar vermis impressing fourth ventricle, nucl n VII						○							
20.5	Top of oliva superior						○						○	
22.5	Pontomedullary junction, entry zone of n VII and n VIII						●						○	
25.0	Top of inferior olive, top of foramina luschke			○			●			○		●		
27.5	Nucl n IX, nucl n XII			○			●	●	○	○		○	●	●
30.0	Hilus olivae, nucl n X			○	○	○	○	●	●	●	●	●	●	●
33.0		○		○	○		○	●	○	○	●	●	●	
35.0	Nucl gracilis, nucl cuneatus	○									○			
37.5		○								●				
39.0	Bottom of oliva inferior, decussatio lemniscus medialis	○	○											

○ Infarction reached the slice level without covering the trigeminal spinal tract and nucleus (TSTN); ○= partial contact with the TSTN; ●= full or approximate full contact with the TSTN.

NEUROLOGICAL SIGNS AND OUTCOME

Of the 15 patients, 11 met the criteria of complete Wallenberg's syndrome (1, 3, 6–13, 15)—that is, showing at least four of the six signs listed in table 1. There were four patients (2, 4, 5, 14) with an incomplete Wallenberg's syndrome (less than four of the six signs) and seven patients (1, 3, 6, 11, 12, 14, 15) who had Wallenberg's syndrome with additional signs (according to table 2). Three out of five patients with normal blink reflexes (1–5) had incomplete Wallenberg's syndrome but none of the eight patients (6–13) showed loss or delay of R2-i/R2c-i ($p < 0.04$). There was no statistical difference regarding additional signs and outcome between these two blink reflex pattern groups (table 2). In six patients (3, 7, 8, 13, 14, 15) ipsiversive skew deviation (ipsilateral eye lowermost) was seen clinically, ipsilateral facial paresis in five patients (3, 6, 11, 14, 15). In four patients facial paresis was incomplete (3, 6, 11, 15) with sparing of the upper portion of the face and it was transient in two patients (3, 11). Patient 14 showed clinical signs of peripheral type facial paresis.

BLINK REFLEX RESPONSES

The R1 responses were normal in all patients with the exception of patient 6 who had a Wal-

enberg's syndrome with additional facial palsy and showed a mild abnormal R1 latency ipsilaterally to the infarction. Brain MRI of this patient showed a large infarction up to the middle of the pons.

At the initial examination 10 out of 15 patients (67%) showed loss or delay of R2 and/or R2c responses (6–15) and five (33%) had normal latencies (1–5). Ipsilateral loss or delay of R2 and R2c (R2-i/R2c-i) occurred in eight out of 15 (53%) patients (6–13). In patient 7, initially normal R2-i evolved into abnormal latencies at follow up and were regarded abnormal in retrospect.

Of three patients with R2c-c abnormalities (12, 14, 15) one developed the blink reflex pattern of infranuclear facial palsy at follow up (14) with MRI showing a lesion covering the exit zone of the facial nerve. The other two patients showed lesions extending more ventrally and approaching the midline at levels 33.0, 25.0, and 22.5, involving the lateral reticular formation. Twelve patients with normal R2c-c showed lesions sparing the paramedian area (2, 5, 6, 7, 8, 13) or not covering the entire region of reticular formation (1, 3, 4, 9, 10, 11). In patient 13, an abnormal R2c-c

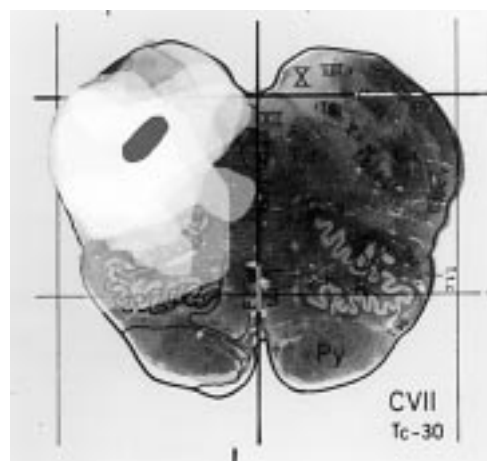


Figure 2 Superimposed MRI slices of three patients with normal blink reflexes and seven patients with abnormal R2-i/R2c-i.

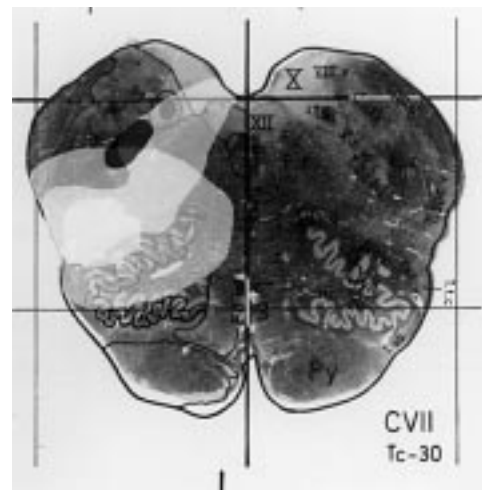


Figure 3 Superimposed MRI slices of three patients with normal blink reflexes at level 30.0. Lesions of patients with normal blink reflexes were located more ventrally compared with patients with abnormal blink R2-i/R2c-i.

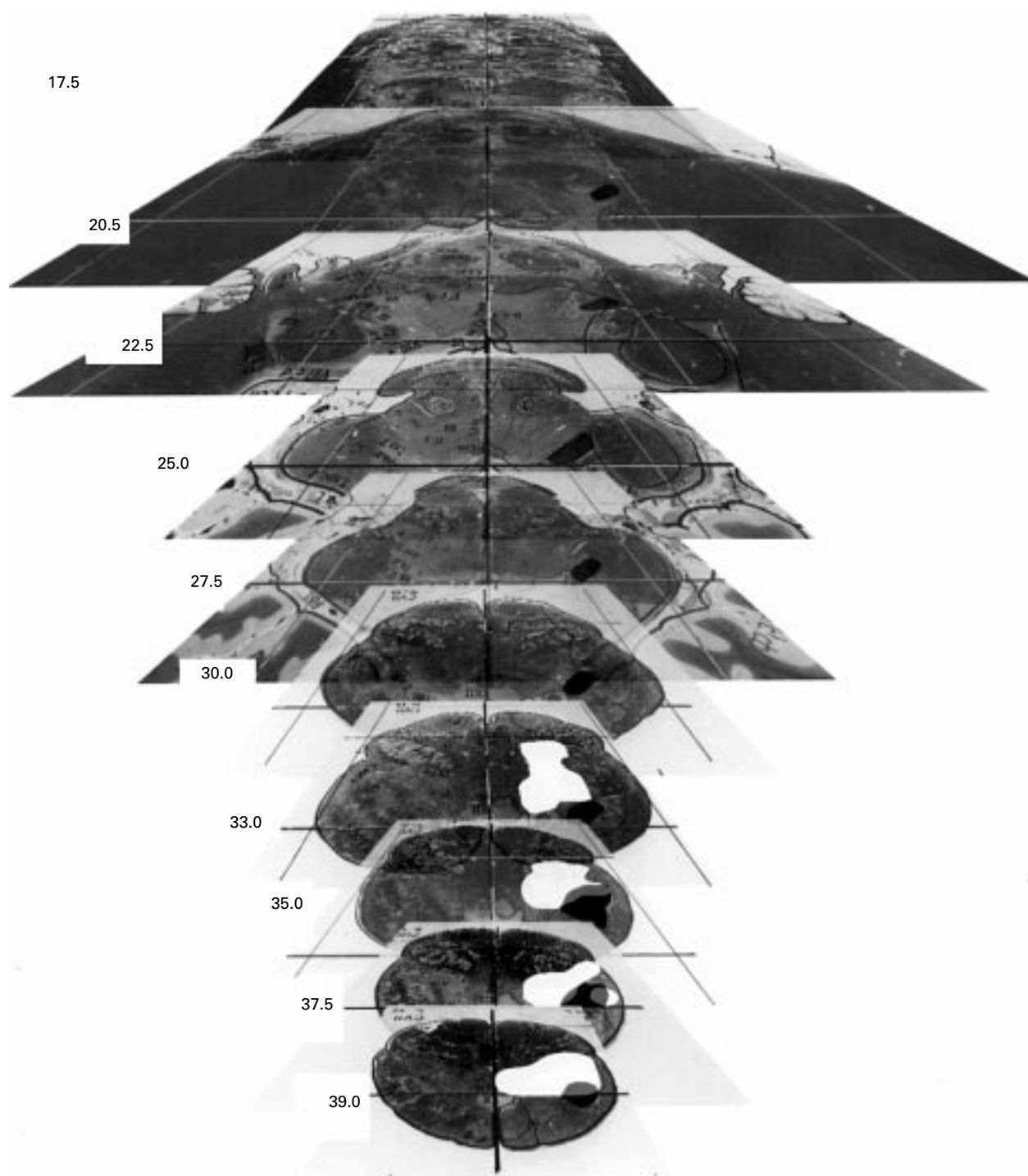


Figure 4 Infarctions of patient 1 projected into an anatomical atlas. The trigeminal spinal tract and nucleus was marked black, lesion white, and contact with lesion grey.

developed during follow up but this may have been due to another recent ischaemia.

Early follow up over 10 days to 5 weeks was performed with seven patients. R2-i and R2c-i latencies were unchanged in three patients with normal latencies at first examination (2, 3, 4) and in four patients with loss or delay of R2-i/R2c-i (8, 11–13). Each R2c-c either improved to normal (patient 12) or worsened (patient 13). At late follow up over 5 to 7 months only one out of five patients reached a normal blink reflex (patient 13). The pattern was unchanged

in three patients and patient 14 developed the pattern of infranuclear facial palsy.

MRI LESIONS

The area visualised by superimposition of the lesions of patients with normal blink reflex responses was located more ventrally than in patients with abnormal blink R2-i/R2c-i (figs 2 and 3). Lesions of patients with abnormal reflexes completely cover the TSTN at one or more levels, whereas lesions of patients with normal reflexes only partially involve it (table 3, fig 4 and fig 5). At level 30.0 (upper medulla)




Figure 5 Infarctions of patient 10 projected into an anatomical atlas. The trigeminal spinal tract and nucleus was marked black, lesion white, and contact with lesion grey.

six out of seven patients with abnormal blink R2-i/R2c-i latencies (6–13) and none of five patients with normal reflexes (1–5) had lesions including the entire TSTN ($p < 0.02$). Each patient with abnormal R2-i/R2c-i responses had at least one lesion involving level 27.5 or 30.0 (upper medulla). The craniocaudal extension of lesions in patients with normal (1–5) and abnormal R2-i and R2c-i (6–13), as measured from sagittal or coronal MRI slices (1–9, 11–13) or estimated from transverse slices (10), was not significantly different. The

mean extensions were 6.2 mm and 8.6 mm in the normal and abnormal blink reflex groups, respectively.

Discussion

More than half (58%) of our patients with infarction of the lower brainstem had absent or delayed R2/R2c blink reflex responses ipsilaterally to the lesion, as has been reported by others.^{9 15 19} Chia and Shen found normal blink reflexes in all 13 patients with Wallenberg's syndrome.¹³ It has been argued that this

resulted from examination up to 5 months after infarction because blink reflex responses improve over 7 months.¹⁵ But this was not confirmed by others,¹⁹ and our late follow up after 5 or 7 months showed normal reflexes in only one out of five patients. We found normal blink reflexes with incomplete Wallenberg's syndrome, suggesting a smaller lesion and functional deficit whereas patients with abnormal R2-i and R2c-i showed clinical signs of complete Wallenberg's syndrome. Therefore abnormal R2-i and R2c-i responses commonly indicate larger lesions.

Based on postmortem and MRI findings in individual patients it is supposed that the central afferent blink reflex loop follows the descending spinal trigeminal tract to the caudal spinal trigeminal nucleus,^{7,9,20} although a course outside the dorsolateral medulla has been discussed.¹³ We found loss or delay of the ipsilateral R2 only with lesions involving the entire TSTN at at least one level, which supports the current understanding of the descending blink reflex R2 pathway.

At the initial examination we saw only two patients with abnormal blink reflex responses to stimulation contralaterally to the lesion (12,15). Patient 12 showed transient loss of R2c-c associated with loss of R2-i and R2c-i, a pattern attributed to lesions of larger medial extension, also injuring the ascending trigemino-facial projections from the contralateral side. They are thought to pass through the lateral reticular formation medially and, depending on slice level, also ventrally to the TSTN.^{9,10} The lesion of patient 12 involved medial ipsilateral and contralateral structures at level 33.0. The other patient (15) showed a bilateral loss of R2/R2c. This pattern has not been reported so far. From current understanding it may be attributed to a medial lesion impairing the ascending projections bilaterally. In our patient with two lesions such lesion was demonstrated in the lower medulla at level 39.0. Impairment of R2-i, R2c-i, and R2c-c may also be due to the more rostral lateral medullary lesion extending to the medial and ventral areas of the medulla. However, the loss of R2-c cannot be attributed to the more rostral of the two lesions, indicating that the reflex loop descends as caudally as level 39.0 (area of the bottom of the inferior olive). The impairment of R2c-c in patients with lesions approaching the midline (12, 15) and the normal responses in patients sparing the paramedian area (2, 5, 6, 7, 8) confirms the view of others that the ascending limb mediating R2c runs closer to the midline than R2.¹¹

It was stated that the additional loss or delay of contralateral blink reflex responses (R2c-c) is not a predictor of early fatal complication in patients with Wallenberg's syndrome.²¹ However, among our 15 patients the only one who died had bilateral abnormal R2/R2c responses (15).

In agreement with the literature^{9,10,15,21} the initial R1 component was normal in 14 out of

15 patients. Only one patient (6) with additional facial paresis had a slightly delayed R1-i. The infarction extended beyond the Wallenberg's syndrome area to the level of the facial nerve exit from the brainstem. R1 abnormalities obviously indicate involvement of pontine structures and are not attributable to dorsolateral medullary lesions. There were three other patients with incomplete ipsilateral facial paresis (3, 11, 15) sparing the upper portion of the face which may occur from lesions at the pontomedullary junction impairing the supranuclear fibres after crossing the midline.²² In patient 14 infranuclear facial and abnormal facial nerve excitability indicates infranuclear fibre impairment.

This project was supported by the DFG (Deutsche Forschungsgemeinschaft), Ho 293/10-1 and approved by the ethics committee of University of Mainz, 837.259.94 (469)-29.12.94.

- Schaltenbrand G, Wahren W. *Atlas for stereotaxy of the human brain, 2nd ed.* Stuttgart: Thieme Verlag, 1977.
- Goor C, Ongerboer de Visser BW. Jaw and blind reflexes in trigeminal nerve lesions. An electrodiagnostic study. *Neurology* 1976;26:95-7.
- Celik M, Forta H. Electrophysiological investigations and prognosis in idiopathic facial palsy. *Electromyogr Clin Neurophysiol* 1997;37:311-5.
- Hopf HC. Topodiagnostic value of brain stem reflexes. *Muscle Nerve* 1994;17:475-84.
- Kimura J. Electrically elicited blink reflex in diagnosis of multiple sclerosis. Review of 260 patients over a seven-year period. *Brain* 1975;98:413-26.
- Ongerboer de Visser BW. Comparative study of corneal and blink reflex latencies in patients with segmental or with cerebral lesions. *Adv Neurol* 1983;39:757-72.
- Hirakao MS, M. Neural mechanisms of the corneal and blinking reflex in cats. *Brain Res* 1977;125:265-75.
- Fisher CM, Karnes WE, Kubik CS. Lateral medullary infarction: the pattern of vascular occlusion. *J Neuropathol Exp Neurol* 1961;20:323-79.
- Ongerboer de Visser BW, Kuypers HG. Late blink reflex changes in lateral medullary lesions. An electrophysiological and neuro-anatomical study of Wallenberg's syndrome. *Brain* 1978;101:285-94.
- Aramideh M, Ongerboer de Visser BW, Koelman JH, et al. The late blink reflex response abnormality due to lesion of the lateral tegmental field. *Brain* 1997;120:1685-92.
- Tackmann W, Ertlin T, Barth R. Blink reflexes elicited by electrical, acoustic and visual stimuli. Their relation to visual-evoked potentials and auditory brain stem evoked potentials in the diagnosis of multiple sclerosis. *Eur Neurol* 1982;21:210-16.
- Sacco RL, Fredro L, Bello JA, et al. Wallenberg's lateral medullary syndrome. Clinical-magnetic resonance imaging correlations. *Arch Neurol* 1993;50:609-14.
- Chia LG, Shen WC. Wallenberg's lateral medullary syndrome with loss of pain and temperature sensation on the contralateral face: clinical, MRI and electrophysiological studies. *J Neurol* 1993;240:462-7.
- Vuilleumier P, Bogousslavsky J, Regli F. Infarction of the lower brainstem. *Brain* 1995;118:1013-25.
- Valls-Solé J, Vila M, Obach V, et al. Brain stem reflexes in patients with Wallenberg's syndrome: correlation with clinical and magnetic resonance imaging (MRI). *Muscle Nerve* 1996;19:93-9.
- Hopf HC, Thömke F, Gutman L. Midbrain versus pontine medial longitudinal fasciculus lesions: the utilization of masseter and blink reflexes. *Muscle Nerve* 1991;14:326-30.
- Cox RW. AFNI-Software for analysis and visualisation of fMRI neuro images. *Comput Biomed Res* 1996;29:162-73.
- Dieterich M, Brandt T. Wallenberg's syndrome: lateralropulsion, cyclorotation, and subjective visual vertical in 36 patients. *Ann Neurol* 1992;31:399-408.
- Meincke U, Ferbert A. Blink reflex in patients with an ischemic lesion of the brainstem verified by MRI. *J Neurol* 1993;241:37-44.
- Kimura J, Lyon LW. Ocularis oculi reflex in the Wallenberg syndrome: alteration of the late reflex by lesions of the spinal tract and nucleus of the trigeminal nerve. *J Neurol Neurosurg Psychiatry* 1972;35:228-33.
- Vila N, Valls Solé J, Obach V, et al. Blink reflex in patients with Wallenberg's syndrome. *J Neurol* 1997;244:30-4.
- Currier RD, Giles CL, Dejong RN. Some comments on Wallenberg's lateral medullary syndrome. *Neurology* 1961; 11:778-91.