

SHORT REPORT

Psychiatric inpatients and chromosome deletions within 22q11.2

Seiichi Sugama, Tomoo Namihira, Rumiko Matsuoka, Naoki Taira, Yoshikatsu Eto, Kihei Maekawa

Abstract

Velocardiofacial syndrome (VCFS) is a congenital disorder characterised by multiple dysmorphisms, cleft palate, cardiac anomalies, and learning disabilities due to a microdeletion of chromosome 22q11.2. Although VCFS is often associated with psychiatric symptoms, its prevalence among psychiatric patients is unknown.

A total of 326 patients admitted in September and October 1997 to a Japanese psychiatric hospital were screened for the clinical features of VCFS. Twelve patients with minor facial dysmorphia were identified; chromosomal analysis with fluorescent in situ hybridisation (FISH) was performed in six patients who, further assessment suggested, were most likely to have VCFS.

Chromosome 22q11.2 deletion was identified in a 41 year old woman who had symptoms of schizophrenia but no major dysmorphia, such as cardiovascular anomalies and cleft palate. Her behavioural and neuropsychological profiles were similar to those previously reported in VCFS. She was hemizygous for the FISH probe N25 (GDB locus D22S75) and also for probes N72H9 (D22S181), sc11.1a, C443 (D22S941), sc4.1 (D22S134), sc11.1b, N19B3 (D22S264), N122B5 (D22S934), and N77F7 (D22S939). The size of the deletion was about 3 Mb.

Our patient had only some features of VCFS including a square nasal root, hypernasal speech, and hypoparathyroidism. She did, however, have the common larger deletion of type A. This finding suggests that psychiatric symptoms in VCFS can occur without major developmental symptoms such as cardiovascular anomalies and cleft palate. Additional patients with schizophrenia may have subtle features of VCFS which are unrecognised on routine medical examinations.

(J Neurol Neurosurg Psychiatry 1999;67:803-806)

Keywords: psychiatric symptoms; schizophrenia; chromosome 22q11.2 deletion; velocardiofacial syndrome

Velocardiofacial syndrome (VCFS) was initially described by Shprintzen *et al* in 1978 as a

multiple congenital malformation syndrome.¹ Its major features are a cleft palate or velopharyngeal insufficiency, cardiac anomalies, and facial dysmorphism.^{1,2} Most patients with VCFS have a submicroscopic deletion in chromosome 22q11.2.² In addition to somatic manifestations, several behavioural disorders have been reported in patients with VCFS during early childhood including separation-anxiety disorders, attention deficit disorders, and obsessive-compulsive disorders.³ As they reach adolescence, about 30% of these patients display psychotic symptoms.^{3,4} For this reason, VCFS has interested medical geneticists as well as neurologists and psychiatrists.

Recently, two of 100 randomly selected inpatients with schizophrenia were found to have deletions within the VCFS region.⁵ We investigated psychiatric inpatients in one prefecture of Japan to determine the prevalence of unidentified VCFS.

Patients and methods

A total of 326 psychiatric inpatients who had been admitted in September and October 1997 to Amekudai Hospital, a psychiatric hospital in Okinawa Prefecture, were reviewed. Patients' diagnoses based on the Diagnostic and Statistical Manual of Mental Disorders, fourth edition, were as follows: schizophrenia (268 patients), alcohol induced psychotic disorder (two), psychotic disorder due to epilepsy (seven), schizoaffective disorder (seven), alcohol induced persisting dementia (five), vascular dementia (28), dementia of the Alzheimer's type (two), and others (seven).

After being given a short explanation and presentation about the typical appearance of patients with VCFS by clinical geneticists, two authors (SS and TN) attempted to screen the admitted patients for VCFS. Patients were identified as possibly having VCFS if they displayed any of the following features: velopharyngeal insufficiency, cleft palate, hypernasal speech, congenital heart disease, or facial dysmorphism (long face, ear anomalies, malar flatness, narrow orbital fissures, square nasal root, and narrow alar base, small mouth, retrognathia).^{1,2} In patients who were identified as possibly having VCFS, studies for the 22q11.2 microdeletion were performed with fluorescence in situ

Department of
Psychiatry, Amekudai
Hospital, Okinawa,
Japan
S Sugama
T Namihira
N Taira

Department of
Pediatrics, The Heart
Institute of Japan,
Tokyo Women's
Medical University,
Tokyo, Japan
R Matsuoka

Department of
Pediatrics, Tokyo Jikei
University School of
Medicine, Tokyo, Japan
S Sugama
Y Eto
K Maekawa

Institute of DNA
Medicine, Tokyo Jikei
University School of
Medicine, Tokyo, Japan
S Sugama
Y Eto

Correspondence to:
Seiichi Sugama, Department
of Pediatrics, Tokyo Jikei
University School of
Medicine, Tokyo,
Nishi-Shinbashi, Minato-ku,
Tokyo 105-8461, Japan.
Telephone 0081 3 3433
1111; fax 0081 3 3435 8665.

Received 2 February 1999
and in revised form
21 May 1999
Accepted 9 June 1999

hybridisation (FISH) using cosmid probe N25 (Oncor, Gaithersburg, MD, USA).⁵

Results

Twelve patients with schizophrenia were identified on the basis of minor facial anomalies as possibly having VCFS. None of the patients had a cleft palate, velopharyngeal insufficiency, or congenital heart disease, and none had all of the above mentioned facial dysmorphia of VCFS. Of the 12 patients, 12 had a square nasal root, five had minor ear anomalies, one had a small mouth and one had hypernasal speech. These patients were re-examined, with specific emphasis on a history of hypocalcaemia, easy infectivity, and learning disabilities. We also asked a clinical geneticist to examine photographs of these patients to assess the likelihood of their having VCFS. Because Shprintzen⁶ and Matsuoka *et al*⁷ have emphasised that a distinct facies is usually associated with 22q 11.2 deletion, we paid particular attention to facial anomalies, especially those of the nose. As a result of this further assessment, FISH analysis was performed in six of the 12 patients. A deletion of 22q11.2 consistent with the VCFS region was identified in a 41 year old female patient who had a square nasal root, a small mouth, and a hypernasal voice. She was further examined with eight cosmid probes of the 22q11.2 region and was found to be hemizygous for the FISH probe N25 (GDB locus D22S75) and also for probes N72H9 (D22S181), sc11.1a, C443 (D22S941), sc4.1 (D22S134), sc11.1b, N19B3 (D22S264), N122B5 (D22S934), and N77F7 (D22S939). The size of the deletion was about 3 Mb (figure).

The patient was born at term (birth weight, 2700 g) after an uneventful pregnancy. She had no history of feeding problems such as regurgitation, or symptoms of hypocalcaemia in early infancy. Neuromental development was normal except for slightly delayed language development. She had a history of mild asthma and otitis media. Otherwise, she was physically healthy as a child. There was no known consanguinity in previous generations. The patient was the first of four children: one brother is severely handicapped with epilepsy of unknown aetiology. Her parents and two other siblings are alive and well, and no other family members or close relatives are clinically affected. She was a slow learner and finished regular school with the lowest levels of achievement. The patient was described as shy, fearful, inflexible, and clinging but did not exhibit any behavioural problems. At the age of 13 she became easily irritable and emotionally labile. She was easily angered by small sounds, such as coughing by a family member. At the age of 22, she showed marked behavioural changes with hallucinations and delusions. Schizophrenia was diagnosed, and antipsychotic medication was started.

When examined at the age of 41, she occasionally had auditory and visual hallucinations and paranoid delusions. She has been treated with chlorpromazine (50 mg daily) and

haloperidol (3 mg daily) with relatively good control of psychotic symptoms.

PHYSICAL EXAMINATION

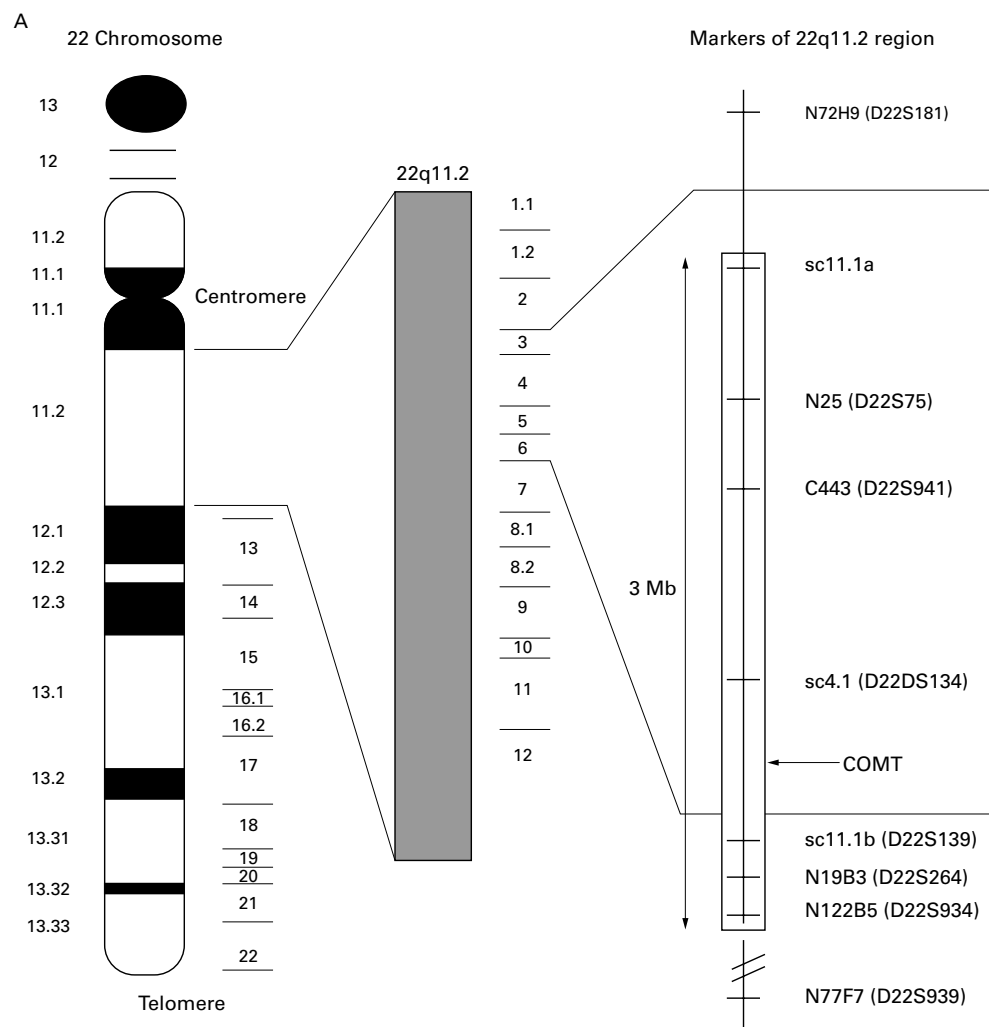
Physical examination showed no somatic dysmorphism except a square nasal root and small mouth. She did not have a high arched palate, bifid uvula, cleft palate, abnormal ears, or slender limbs. Her height was 148 cm and weight was 62 kg. No evidence of cardiac disease was found on radiography or ECG. Her voice was hypernasal. Results of a neurological examination were normal except for saccadic smooth pursuit eye movements.

She was disinhibited, over friendly and was no longer shy and withdrawn. The Wechsler adult intelligence scale yielded a verbal intelligence quotient (IQ) of 70, a performance IQ of 60, and a full scale IQ of 63. She was found to have relatively weak visuospatial perception. Results of routine laboratory examinations were within the normal range except for serum concentrations of calcium, phosphorus, and parathyroid hormone indicating hypoparathyroidism. Brain CT showed premature bilateral pallidal calcification, which suggests deposition of calcium related to hypoparathyroidism.

Discussion

Several authors have reported deletions of 22q11.2 in patients with psychiatric symptoms.^{3-5, 8} Because of the seemingly high frequency of VCFS deletions in these patients, we investigated psychiatric inpatients to determine the prevalence of unidentified VCFS. We found only one patient with VCFS among 326 psychiatric inpatients. This patient had auditory and visual hallucinations and delusions, symptoms commonly found in patients with schizophrenia. The prevalence of VCFS was lower in our study than in previous reports.^{3-5, 8} A possible reason is that most patients had received a diagnosis of schizophrenia, whereas ongoing studies of adolescent patients with VCFS suggest that they often have bipolar disorders.^{4, 9} Another possible reason is that some patients with schizophrenia may have subtle features of VCFS which were overlooked or may have undetectable mutations. Schizophrenia has been considered a neurodevelopmental disorder.¹⁰ Interestingly, patients with VCFS and those with schizophrenia have similar craniofacial dysmorphia, such as a long face, narrow orbital fissure, narrow nasal width, and a small mouth.¹⁰ In retrospect, we should have performed FISH analysis in patients who had even mildly dysmorphic features.

Golding-Kushner *et al*¹¹ have reported that premorbid features of children with VCFS include extremes of disinhibited and impulsive behaviour and serious and shy behaviour. Interestingly, the present patient was shy and withdrawn in childhood and became disinhibited and over friendly in adulthood. Her neuropsychological profile, including the verbal IQ being higher than the performance IQ, was similar to that previously reported in VCFS.¹¹ VCFS is linked to a hemizygous interstitial deletion of chromosome 22q11.2, probably includ-



B

	Probes									
		N72H9	sc 11.1a	N25	C443	sc4.1	sc 11.1b	N19 -B13	N122 -B5	N77 -F7
Present patient	Age/sex									

3 Mb

(A) FISH analysis using eight probes of regions of chromosome 22q11.2. (B) The patient is hemizygous for the FISH probe N25 and also for probes N72H9, sc11.1a, C443, sc4.1, sc11.1b, N19B3, N122B5, and N77F7, which are indicated by grey boxes. The size of the deletion was about 3 Mb. The patient had an A type deletion (grey) on the telomeric side.⁵

ing 20 to 30 genes in that area. The high prevalence of psychiatric symptoms in patients with VCFS suggest that a locus in chromosome 22q11–13 may be a cause of psychiatric symptoms.⁵ One candidate gene that has been mapped to this region is that for catechol-*o*-methyl transferase,⁹ which plays an important part in catecholamine metabolism. As yet, no correlation has been found between the extent of the deletion and phenotypic expression among patients with VCFS with or without schizophrenia.⁵ In a study of patients with conotruncal anomaly face syndrome

(del22q11.2 syndrome) Matsuoka *et al*⁷ found that 93% of 162 patients had a 2.5 to 3 Mb deletion with a distal breakpoint (type A), 3% had a 2 to 2.5 Mb deletion with an intermediate breakpoint (type B), and 4% had a 2 Mb deletion with a more proximal breakpoint (type C). All patients with cardiovascular diseases and psychiatric symptoms had type A deletions.⁷ Although our patient had the common larger deletion of type A, she bore only some facial features of the syndrome and lacked major somatic anomalies, such as cardiovascular anomalies and cleft palate.¹ These findings suggest that psychi-

atric symptoms in VCFS can arise in the absence of major somatic anomalies. Further studies are needed to evaluate other possible reasons for the variable expression of psychiatric symptoms in VCFS including (1) the presence of polymorphisms in hemizygous genes, (2) interaction of the deleted region with other polymorphic loci elsewhere in the genome, (3) interaction with environmental factors (variable expression has been seen in monozygotic twins (R Matsuoka, personal communication)), and (4) that a deletion of a region nearer the telomere predisposes to psychiatric symptoms.

We thank Dr Hiroshi Kawame and Kenji Kurosawa, clinical geneticists, Department of Pediatrics, Tokyo Jikei University School of Medicine, for their valuable suggestions.

- 1 Shprintzen RJ, Goldberg RB, Lewin ML, et al. A new syndrome involving cleft palate, cardiac anomalies, typical facies, and learning disabilities: velo-cardio-facial syndrome. *Cleft Palate Journal* 1978;15:56–62.
- 2 Driscoll DA, Spinner NB, Budarf ML, et al. Deletions and microdeletions of 22q 11.2 in velo-cardio-facial syndrome. *Am J Med Genet* 1992;44:261–8.
- 3 Shprintzen RJ, Goldberg R, Golding-Kushner KJ, et al. Late-onset psychosis in the velo-cardio-facial syndrome. *Am J Med Genet* 1992;42:141–2.
- 4 Papolos DF, Faedda GL, Veit S, et al. Bipolar spectrum disorders in patients diagnosed with velo-cardio-facial syndrome: does hemizygous deletion of chromosome 22q11 result in bipolar affective disorder? *Am J Psychiatry* 1996;153:1541–7.
- 5 Karayiorgou M, Morris MA, Morrow B, et al. Schizophrenia susceptibility associated with interstitial deletions of chromosome 22q11. *Proc Natl Acad Sci USA* 1995;92:7612–6.
- 6 Shprintzen RJ. Velocardiofacial syndrome and Digeorge sequence. *J Med Genet* 1994;31:423–4.
- 7 Matsuoka R, Kimura M, Scambler PJ, et al. Molecular and clinical study of 183 patients with conotruncal anomaly face syndrome. *Hum Genet* 1998;103:70–80.
- 8 Gothelf D, Frisch A, Munitz H, et al. Velocardiofacial manifestations and microdeletions in schizophrenic inpatients. *Am J Med Genet* 1997;72:455–61.
- 9 Lachman HM, Morrow B, Shprintzen R, et al. Association of codon 108/158 catechol-o-methyltransferase gene polymorphism with the psychiatric manifestations of velo-cardio-facial syndrome. *Am J Med Genet* 1996;67:468–72.
- 10 Lane A, Kinsella A, Murphy P, et al. The anthropometric assessment of dysmorphic features in schizophrenia as an index of its developmental origins. *Psychol Med* 1997;27:1155–64.
- 11 Golding-Kushner KJ, Weller G, Shprintzen RJ. Velo-cardio-facial syndrome: language and psychological profiles. *J Craniofaci Genet Dev Biol* 1985;5:259–66.