
 EDITORIAL

Assessment and treatment of dizziness

“There can be few physicians so dedicated to their art that they do not experience a slight decline in spirits when they learn that their patient’s complaint is giddiness. This frequently means that after exhaustive enquiry it will still not be entirely clear what it is that the patient feels wrong and even less so why he feels it.”

From W B Matthews. *Practical Neurology*. Oxford, Blackwell, 1963.

These words are not quite as true today as when Bryan Matthews wrote them nearly 40 years ago. There is now cause for cautious optimism. Recent clinical and scientific developments in the study of the vestibular system have made the clinician’s task a little easier. We now know more about the diagnosis and even the treatment of conditions such as benign paroxysmal positioning vertigo, Menière’s disease, acute vestibular neuritis, migrainous vertigo, and bilateral vestibulopathy than we did in 1963 and our purpose here is to introduce the clinician to facts worth knowing.

(A) The patient who has repeated attacks of vertigo, but is seen while well

IS IT VERTIGO ?

”Doctor I get dizzy”. This is of course one of the most common problems encountered in office practice and the one to which Matthews was alluding. The clinician’s first job is to sort out whether the dizzy patient is having attacks of vertigo, or attacks of some other paroxysmal symptom. So what is vertigo and what are its mechanisms and clinical characteristics ?

The first point about vertigo is that it is an illusion of rotation and that it is always due to asymmetry of neural activity between the left and right vestibular nuclei. This is true whether the vertigo is induced by being spun around and then suddenly stopped, whether it is induced by having cold water squirted in one ear, whether it is induced by otoconial particles rumbling up and down a semicircular canal duct, or whether it is induced by infarction of one vestibular nucleus. The second point is that vertigo is always temporary. Even after the vestibular nerve on one side has been surgically severed, the terrible vertigo and nystagmus that follow will always abate within a few days, not because the vestibular nerve has reanastomosed but because profound neurochemical changes have taken place in the brainstem during the process of vestibular compensation.

The third point is that vertigo is always made worse by head movement, just as angina is always made worse by exertion. If you don’t believe this, then try the following: spin yourself around about 10 times (standing or sitting, it doesn’t matter) and then stop and throw your head backwards, quickly.

Convinced? One can be reasonably sure then that the patient who is happy to move around while dizzy does not have vertigo, and that the patient who is dizzy all the time and whose dizziness is not made better by keeping still, either hasn’t got vertigo or hasn’t got the story right. Now that we are sure that our patient has vertigo the next question to answer is whether the vertigo attacks are spontaneous or positional. But before we go on to answer that let us consider briefly the diagnosis of other common paroxysmal disorders such as syncope, seizure, hypoglycaemia, and hyperventilation.

Obviously patients with aural vertigo should not lose consciousness but it is surprising how few people can give a confident and convincing answer to the simple question: “Did it feel like you were losing your balance or like you were losing consciousness ? Did it feel like you were going to pass out or fall over ?” Patients with vertigo might actually lose consciousness if they have been vomiting a lot, or if they had an otolithic drop attack and a head injury on the way down. Witness descriptions are not much help in identifying vertigo, but can be essential in identifying seizures and syncope. (Convulsive syncope is of course more complicated.) Tilt table testing, particularly with lots of invasive instrumentation, is, according to some, too sensitive and insufficiently specific to help much with the diagnosis of vasovagal (now renamed “neurocardiogenic”) syncope.^{1 2} Cardiac syncope can, particularly in a patient without heart disease, be a difficult diagnosis. An event monitor which the patient wears for several weeks is more useful, particularly for picking up intermittent heart block, than a 24 hour Holter monitor which is best at disclosing the asymptomatic arrhythmias. A cardiac electrophysiological study is good at picking up the sort of tachyarrhythmias that can cause syncope and is less irksome than an endless sequence of inconclusive indirect investigations. Video-EEG monitoring has proved helpful in the diagnosis of seizures but is not easily available to everyone. Measurement of blood glucose during an attack, possible with a finger-prick glucometer, is the easiest and most direct way to make the diagnosis of hypoglycaemia, something that is easy to miss in the patient who is not being treated for diabetes.

Whereas panic attacks, especially with hyperventilation, commonly cause a sense of dizziness that is not actually

vertigo, patients with recurrent undiagnosed vertigo can develop panic attacks particularly if the vertigo attacks are reassuringly put down to "... just a little anxiety". This is one of those unusual situations in which patients do as they are told: they go on to develop anxiety, panic, and even agoraphobia.³ "Phobic postural vertigo" is a variant of this problem in which patients, often with obsessive-compulsive personalities, complain of a mild subjective disturbance of balance while standing or walking, with momentary illusions of motion.⁴ The symptoms usually occur in specific places or in specific situations, and are associated with a distressing anxiety. Many cases follow a clear, well documented peripheral vestibulopathy. Not everyone likes the name "phobic postural vertigo",⁵ although we all see these patients, and typically they do well with simple non-judgmental support and an accurate non-patronising explanation.⁶

BENIGN PAROXYSMAL POSITIONING VERTIGO (BPPV)

Benign paroxysmal positioning vertigo (BPPV) is the single most common cause of vertigo seen in office practice and many patients give a story that is clear enough for a telephone diagnosis. "Doctor, whenever I turn in bed at night, or I hang the washing on the line or look under my car..." They don't even have to say that they are dizzy! In most patients the BPPV will occur in bouts lasting several weeks and will then spontaneously remit, only to return weeks, months, or even years later. The patient with repeated bouts of vertigo over several decades with no

abnormalities on examination, has BPPV. Recently, it has become clear that the cause of BPPV is the movement of stray otoconial particles within the duct of the posterior semicircular canal and that it is possible to remove these and so to put the patient into immediate remission basically by rolling the patient slowly by 180 degrees, from the most provocative position towards the normal side.

The positioning test, as described by Bárány, perfected by Dix and popularised by Hallpike, is the cornerstone of diagnosis and now of treatment. The idea of the test is to make any otoconia in the posterior semicircular canal move and so provoke vertigo and nystagmus. Eventually Brandt and Daroff⁷ and then Semont *et al*⁸ and Epley⁹ realised that making the otoconia move within the duct also allows them to be removed from the duct. But if you can't provoke the BPPV, you can't fix it.

Consider a patient with left posterior semicircular canal BPPV, seated on a bed. In this position the posterior semicircular canal is gravitationally vertical, and its ampulla is its lowermost part; any otoconia in the duct will have come to rest next to the cupula (fig 1-start). The patient's head is now turned to the left and the patient is suddenly pitched backwards (in the plane of the posterior semicircular canal) until the head is hanging over the end of the bed so that the lowermost point becomes the midpoint of the posterior semicircular canal duct rather than the ampulla. The otoconia will now fall down from the cupula and come to rest at the midpoint of the duct. As they fall away from the cupula they create a negative fluid pressure and so pull on

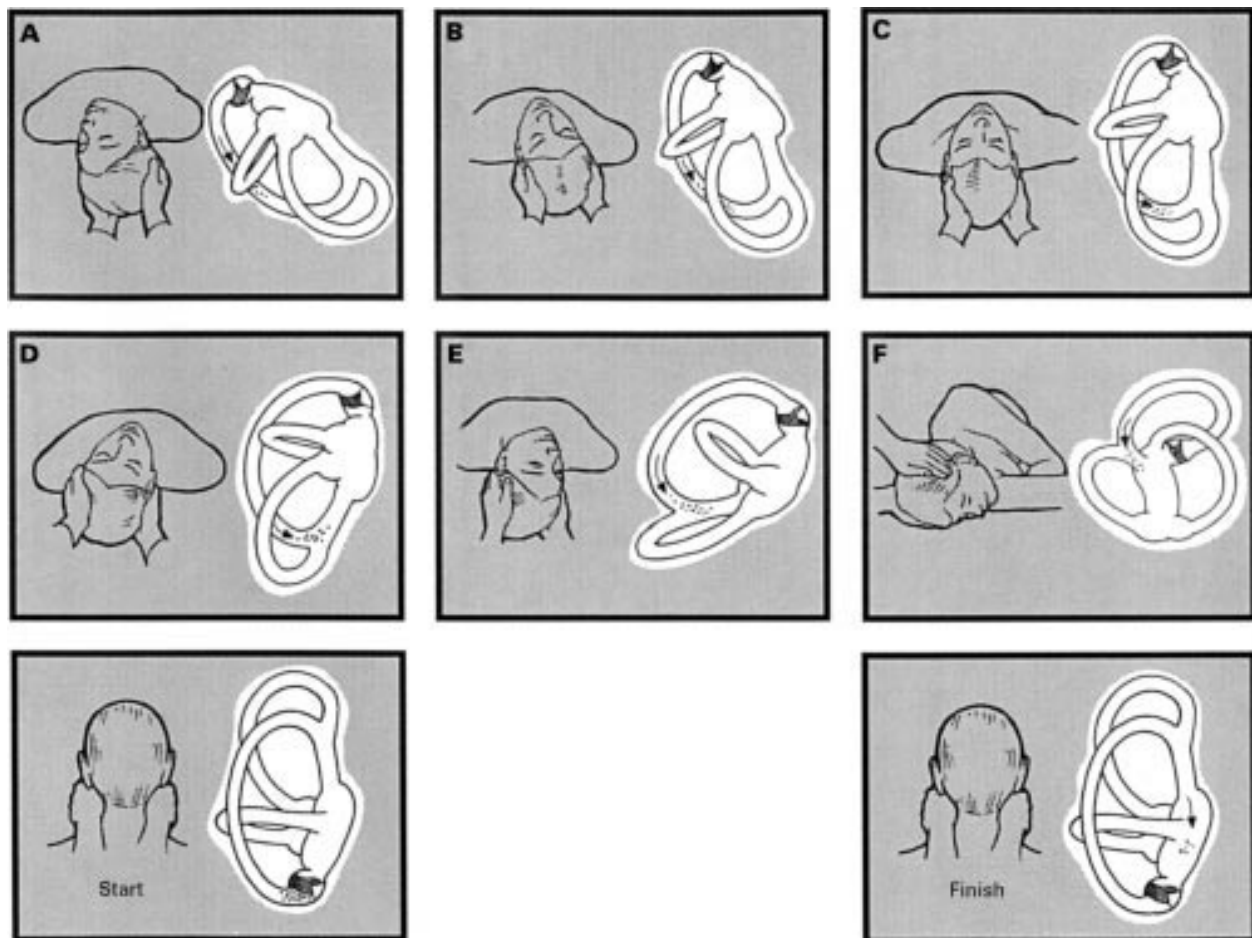


Figure 1 The Epley particle repositioning manoeuvre for left posterior semicircular canal BPPV. The patient is rapidly reclined into the left Dix-Hallpike position (A) and remains in that position until both the vertigo and nystagmus have well and truly disappeared and the otoconial particles have settled into the lowest portion of the posterior semicircular canal duct. The patient's head is slowly turned by 90 degrees into the right Dix-Hallpike position (B-E) so that the particles are guided into the common crus. Then the patient slowly rolls onto the right shoulder and the head is turned another 90 degrees so that the particles fall via the common crus back into the vestibule. (Based on a figure from Harvey *et al*¹¹).

the cupula producing an ampullofugal deflection which is excitatory for primary afferents of the posterior semicircular canal. As a result there is not only a brief—20 seconds or so—paroxysm of vertigo, but also of a nystagmus with upbeat and counterclockwise fast phases—the patient's point of view.¹⁰ That is, the rotation axis of the nystagmus is at 90 degrees to the plane of the stimulated semicircular canal, in this case the left posterior canal. If the patient is now slowly rotated by 180 degrees in towards his right, until the right side of his face is touching the bed, the posterior semicircular canal will have been inverted (fig 1 F) so that the common crus, which joins the anterior and posterior semicircular canals, is now the lowermost point. At this stage the otoconia should move further along the semicircular canal duct and produce another, but this time less severe, paroxysm of vertigo and of counterclockwise upbeat nystagmus. The patient, still face down, now stands up and the otoconia will continue along the common crus back into the vestibule. This is in essence the particle repositioning or perhaps better termed “liberatory” manoeuvre as described by Epley. It will stop the BPPV attacks in about four out of five patients.¹¹ Those who are resistant to repeated repositioning manoeuvres can be cured by surgical occlusion of the posterior semicircular canal.¹² Post-traumatic cases in particular can be bilateral but it is sometimes difficult to tell bilateral BPPV from unilateral BPPV with a vigorous off direction (ampullopetal) nystagmus on turning toward the unaffected side.¹³

In most patients with BPPV there are no other symptoms and there is no demonstrable abnormality of vestibular or auditory function. In a few it follows acute vestibular neuritis or occurs during the course of a progressive inner ear disease (for example, Menière's disease, Cogan's syndrome). Very rarely is a clinical picture identical to typical BPPV produced by a posterior fossa problem such as a tumour, malformation, or degeneration and BPPV is common enough for a patient to have both.

Lateral semicircular canal BPPV is a variant first described by Pagnini *et al* and by McClure in which the nystagmus is horizontal and usually beats toward the lowermost ear indicating that the otoconia in the duct are falling toward the cupula.¹⁴ The discovery of the existence and then of the mechanism of this uncommon condition had an importance far beyond the few patients who have it; it led to the elucidation of the mechanism and of the treatment of the much more common semicircular posterior canal BPPV. Treatment of lateral semicircular canal BPPV is less reliable than of semicircular posterior canal BPPV and largely consists of rotating the recumbent patient 360 degrees from the bad side towards the good side and then having the patient sleep only on the good side so that the otoconia can find their way out of the lateral semicircular canal back into the vestibule.¹⁵

RECURRENT SPONTANEOUS VERTIGO: IS IT MENIÈRE'S DISEASE OR IS IT MIGRAINE?

The patient with repeated attacks of spontaneous vertigo each lasting an hour or more, most likely has either Menière's disease or migraine. The presumed pathophysiological basis of Menière's disease is episodic endolymphatic hypertension which produces devastating attacks of spontaneous vertigo with nausea and vomiting, together with a low frequency hearing loss, a low frequency tinnitus, and a sense of fullness or blockage in the affected ear.^{16 17}

The vertigo attacks usually last for a few hours, but the tinnitus and hearing loss might continue for days. The attacks might occur days, months, or even years apart. After the first few attacks of vertigo vestibular and cochlear function recover, so that the caloric test and the pure tone audiogram will both be normal. Later, after many more

attacks of vertigo a permanent loss of auditory and of vestibular function becomes apparent even in between attacks. Whereas Menière's disease can remit permanently at any stage, if it does progress then in the late stages the patient is still subject to attacks of spontaneous vertigo but also has the added misery of continual tinnitus in a deaf ear that distorts and recruits. Strict dietary sodium restriction aiming for a urinary sodium less than 50 mmol/day is the most effective medical therapy (there has been no proper clinical trial), more effective and less troublesome than diuretics. Surgery can stop the vertigo attacks but can't restore the hearing. Endolymphatic sac surgery of various sorts is generally popular, sometimes effective, and should not destroy any auditory or vestibular function. A surgical, or more simply, a transtympanic gentamicin labyrinthectomy will stop the vertigo but won't save the hearing, whereas an intracranial vestibular nerve section will also stop the vertigo attacks and save whatever hearing remains.

A common clinical problem is the patient who presents with repeated attacks of spontaneous vertigo, but is unaware of any temporary deafness, tinnitus, or fullness in one ear at the time of a vertigo attack, and who has no clinical abnormalities, a normal audiogram, and a normal caloric test. (Note: it is not easy to evaluate a dizzy patient without access to reliable, reproducible caloric testing.) Could this patient have Menière's disease? The answer is, of course, yes. The patient might in fact have had a temporary low frequency hearing loss during the vertigo attack but would not have noticed it. Patients often don't notice a slight hearing loss in one ear, particularly if the loss is mainly below 1.5 kHz, the centre of the speech spectrum, and particularly during an attack of vertigo and vomiting when they are too busy being dizzy to worry about a little deafness in one ear. There are also patients who have repeated spontaneous vertigo attacks for many years before they develop a unilateral tinnitus and hearing loss so that the diagnosis of Menière's disease finally becomes obvious. But on the other hand such a patient could also have vestibular migraine.

Those who have migraine headaches have more vertigo than those who don't.¹⁸ Some migraineurs will sometimes have vertigo as their migrainous aura, and will then go on to develop a typical hemicranial headache with nausea and vomiting. Attacks such as these have been called basilar migraine, although Bickerstaff¹⁹ probably meant something much more dramatic when he coined the phrase. Other migraineurs will have repeated attacks of spontaneous vertigo, apart from the attacks of headache, typically lasting less than an hour, with nausea and even vomiting, but without any hearing disturbance or headache at the time.²⁰ The potential mechanism by which migraine might produce vertigo attacks is as open and as contentious as the mechanism of migraine itself. Nevertheless, vertigo attacks in migraineurs often respond to medications used to treat migraine headaches such as an ergot, a triptan, or even aspirin and in some patients the vertigo attacks can be prevented by regular treatment with a β -blocker, a calcium channel blocker, a tricyclic, valproate, acetazolamide, or methysergide.²¹ As transient neurological events of obscure origin, in the absence of migraine headaches, are common enough in young people,²² it is likely that the same mechanism, whether that is migrainous or not, can also cause vertigo attacks in patients who have never had migraine headaches.

DIAGNOSES THAT ARE UNLIKELY TO BE CORRECT IN A PATIENT PRESENTING WITH VERTIGO

Certain diagnoses should be made with caution in any patient who has repeated vertigo attacks, and with great

caution in a patient who has only had vertigo attacks and has no fixed loss of auditory or vestibular function and no neurological symptoms or signs. Acute otitis media does not cause vertigo unless there is a suppurative labyrinthitis. Chronic otitis media can, very rarely, produce a Menière-like picture due to secondary endolymphatic hydrops. A post-traumatic, postoperative, or cholesteatoma associated perilymph fistula can occasionally produce some vertigo, always with a hearing loss. Acoustic neuroma very rarely produces attacks of spontaneous vertigo, and maybe never in a patient who has no fixed unilateral or asymmetric abnormalities of auditory or vestibular function. Microvascular loop compression is a validated cause of paroxysmal symptoms related to the trigeminal and facial nerves, but the evidence that microvascular compression of the vestibular nerve causes paroxysmal vestibular symptoms, or any symptoms at all, is unconvincing. The anterior inferior cerebellar artery normally loops into the internal auditory canal and is not a bona fide cause of symptoms. Whereas frequent brief attacks of vertigo accompanied by unilateral hyperacusis or tinnitus can respond to treatment with carbamazepine and have been called “vestibular paroxysmia”²³ there is scant evidence for symptomatic microvascular compression in these patients. Transient vertebral ischaemia is a difficult clinical diagnosis at any time but very unlikely to be correct in a patient who has only attacks consisting only of vertigo.

(B) The patient who is having a first ever attack of acute spontaneous vertigo

This is the patient who quite suddenly develops, for the first time ever, such intense spontaneous vertigo, nausea, and vomiting that she or he cannot get to see a doctor, and requires either a home visit (where such things still happen) or a visit to an emergency department. Most general practitioners and emergency physicians will guess, usually correctly, that the patient has “labyrinthitis”, although some will call it a “middle ear infection” and prescribe an antibiotic as well as prochlorperazine by mouth. (How a vomiting patient is meant to take this is rarely explained. The 25 mg rectal suppositories are on the other hand, quite useful.) Few, however, will be able to elicit the essential clinical signs of labyrinthitis, which is regrettable as these are simple, stereotyped, and necessary to distinguish “labyrinthitis” from the more sinister cerebellar infarction without ordering an urgent MRI on every patient with a first attack of acute spontaneous vertigo.

ACUTE VESTIBULAR NEURITIS

Sudden, spontaneous, isolated, unilateral, total, or subtotal loss of peripheral vestibular function is a common and dramatic event. It is usually ascribed to viral infection or to a parainfectious event and has been called “labyrinthitis”, “vestibular neuritis”, “vestibular neuronitis”, and “neuro-labyrinthitis”. The evidence for viral infection is slim and some prefer to call it “acute unilateral peripheral vestibulopathy”.²⁴

In patients with combined superior and inferior vestibular neuritis the clinical signs are the same as those that occur after a labyrinthectomy or a vestibular neurectomy. There is a horizontal-torsional spontaneous nystagmus with the slow phases towards the affected ear—that is, quick phases towards the unaffected ear. The nystagmus is always strictly unidirectional. Bidirectional gaze evoked nystagmus excludes the diagnosis. The nystagmus is, to some extent, always suppressed by visual fixation, and for that reason it might be missed on the standard clinical examination. When some means are used to view the eyes in the absence of visual fixation such as ophthalmoscopy with the other eye covered,²⁵ or Frenzel glasses, the nystag-

mus will be evident in the primary position. The head impulse test (fig 2) is invariably positive and shows absent lateral semicircular canal function on the affected side.²⁶ The patient, although unsteady, can stand without support with the eyes open but rotates toward the side of the lesion when trying to march on the spot with the eyes closed—called a positive Fukuda or Unterberger test by the cognoscenti. There is an ocular tilt reaction, always toward the affected side, but this is rarely obvious clinically: there might be a head tilt toward the affected side and sometimes a vertical diplopia, with the higher image coming from the eye on the side of the affected ear. However, the cardinal sign of the ocular tilt reaction, a conjugate torsional offset of the eyeballs toward the affected side can only be seen with indirect ophthalmoscopy or with fundus photography. Nevertheless it can be inferred by testing the subjective visual horizontal, an easy test that can be done in any clinical neurophysiology department.²⁷ In some patients the disorder only affects the superior vestibular nerve and spares the inferior division of the vestibular nerve²⁸ so that the patient with vestibular neuritis is able to develop BPPV presumably as a consequence of otoconia being shed from the utricle into the duct of the posterior semicircular canal.

CEREBELLAR INFARCTION

The main differential diagnosis of acute vestibular neuritis is cerebellar infarction. There are several ways to tell the difference clinically. Firstly, there is the head impulse test. In the clinical context of the first ever attacks of acute spontaneous vertigo, if the head impulse test is positive then the patient has acute vestibular neuritis and if the head impulse test is negative, then the patient definitely does not have acute vestibular neuritis affecting the superior vestibular nerve and might have a cerebellar infarct. Secondly, with a cerebellar infarct the nystagmus might be bilateral, might be vertical, and will not be well suppressed by visual fixation—that is, it will be obvious even without Frenzel glasses. Thirdly, a patient with a cerebellar infarct usually cannot stand without support even with the eyes open, whereas the patient with acute vestibular neuritis usually can. If it is not possible to be sure clinically that the patient has acute vestibular neuritis, it is usually because the examining clinician is insufficiently familiar with the technique of the head impulse test to show that it is convincingly positive. In that case imaging will be required, and as many acute cerebellar infarcts are missed by CT, this means MRI. None the less, cerebellar infarction is worth diagnosing, because about a third of cases will develop acute, potentially lethal, posterior fossa brain oedema requiring emergency neurosurgical decompression, and secondly, because most cases are due to cardiogenic embolism and will require long term oral anticoagulation to prevent recurrences.²⁹ Although brainstem infarction and brainstem multiple sclerosis might produce an attack with predominantly vertigo and nystagmus, particularly if the plaque involves the 8th nerve root entry zone³⁰ there will generally be other, albeit subtle signs to indicate that the process is in the brainstem and not in the labyrinth.

LATE COMPLICATIONS

The patient who has an attack of acute spontaneous vertigo and is seen at home by his general practitioner and treated as having labyrinthitis will only see a neurologist if complications occur. So if the patient has actually had vestibular neuritis, there is a 1 in 5 chance that he will present later with attacks of typical posterior semicircular canal BPPV or with imbalance due to inadequate vestibular function. If the patient has had a small embolic infarct in the cerebellum, he might not present until he has had another one, this time perhaps not in the cerebellum but elsewhere.

(C) The patient who is off balance

There are many reasons for a patient to be off balance while standing or walking, a symptom which many patients will insist on calling “dizziness”. Whereas it is true that the older the patient the less likely that a single diagnosis can be made to account for the problem, there are some diagnoses that tend to be forgotten.

The first is bilateral loss of vestibular function which causes ataxia and oscillopsia but not vertigo.³¹ In the absence of any significant and relevant hearing loss it can cause some diagnostic difficulties because an aural cause might not be considered in the differential diagnosis of imbalance. The patient will be able to walk perfectly well heel to toe and the only easily demonstrable abnormality will be an inability to stand, with the eyes closed, but only when trying to do so on a soft, yielding surface such as a mattress or two pillows—a sort of Romberg’s test. The head impulse test will be positive to the left, right, up, and down and caloric and rotational tests will show bilaterally absent or severely impaired lateral semicircular canal vestibulo-ocular reflexes. Sometimes patients with severe unilateral loss of vestibular function will present with the same symptoms.³² The most common known cause of bilateral vestibular loss without hearing loss is gentamicin toxicity.³³ Systemic gentamicin is rarely cochleotoxic in humans, but as far as the vestibular system is concerned there is no safe dose, and any patient who notices imbalance after a hospital admission has gentamicin vestibulotoxicity until proved otherwise. As the patient might not be aware of having been given gentamicin it might be necessary to requisition the hospital’s records.

A few patients have bilateral vestibular loss and normal hearing on a hereditary basis,³⁴ sometimes in combination with a spinocerebellar ataxia.³⁵ Although it will be difficult to recognise a bilateral vestibulopathy in a patient with a cerebellar ataxia from examining stance and gait, the compensatory eye movements in response to slow head turning

are pathognomonic. As smooth pursuit is absent due to the cerebellar ataxia and the vestibulo-ocular reflex is absent due to the peripheral vestibulopathy, even in response to slow head rotations the patient will be unable to make smooth compensatory eye movements to maintain fixation and can only produce a series of saccades.

Patients with normal pressure hydrocephalus often have imbalance as the cardinal feature of their presentation and it is easy enough to discount ventriculomegaly in the presence of some cortical atrophy. Nevertheless, there are patients with big ventricles whose gait improves after ventricular shunting.³⁶

Posterior fossa tumours, particularly those within the fourth ventricle, are still a trap particularly if the patient has only had CT imaging. The sole complaint might be of a vague imbalance and perhaps some positional vertigo with no clinical abnormalities.³⁷ This type of presentation deserves MRI. Early progressive supranuclear palsy can present with imbalance and a tendency to fall, well before any eye signs have developed.³⁸ The only clue might be some axial rigidity and a somewhat impassive countenance. Primary orthostatic tremor typically causes no problem with walking but a feeling of imbalance while standing. The patient might not have noticed the fine high frequency tremor, which might only be obvious with surface EMG.³⁹

(D) Conclusions and take home message

With some knowledge, some resources, and considerable patience it is now possible to make a reasonable diagnosis and to offer reasonable treatment to most patients presenting with vertigo or some other balance disorder.

IN THE PATIENT WITH REPEATED ATTACKS OF VERTIGO

- (1) Always do a positional test.
- (2) Learn to do the particle repositioning manoeuvre.
- (3) Always order an audiogram.

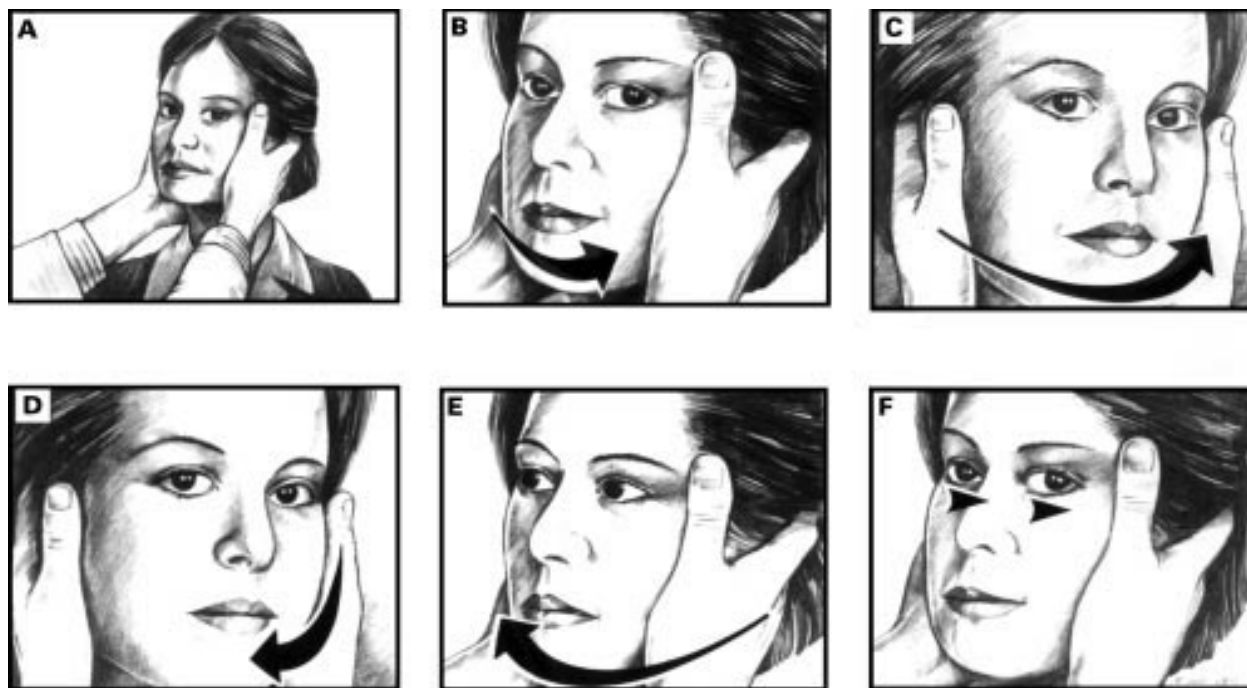


Figure 2 The head impulse test. The examiner turns the patient’s head as rapidly as possible about 15 degrees to one side and observes the ability of the patient to keep fixating on a distant target. The patient illustrated has a right peripheral vestibular lesion with a severe loss of right lateral semicircular canal function. While the examiner turns the patient’s head to toward the normal left side (top row) the patient is able to keep fixating on target. By contrast, when the examiner turns the patient’s head to the right the vestibulo-ocular reflex fails and the patient cannot keep fixating on target (E) so that she needs to make a voluntary rapid eye movement—that is, a saccade, back to target (F) after the head impulse has finished; this can be easily observed by the examiner. It is essential that the head is turned as rapidly as possible otherwise smooth pursuit eye movements will compensate for the head turn. (Based on a figure from Halmagyi and Curthoys.²⁶)

- (4) Try migraine treatment.
- (5) Forget about vertebrobasilar insufficiency as a cause of isolated vertigo.

IN THE PATIENT HAVING A FIRST EVER ATTACK OF ACUTE SPONTANEOUS VERTIGO

- (1) Learn to do the head-impulse test.
- (2) Always think of cerebellar infarction.

IN THE PATIENT WHO IS OFF BALANCE

- (1) Think of gentamicin vestibulotoxicity.
- (2) Think of normal pressure hydrocephalus.
- (3) Beware of the posterior fossa tumour.
- (4) Think of orthostatic tremor.

The support of the National Health and Medical Research Council and of the Garnett Passe and Rodney Williams Memorial Foundation are gratefully acknowledged.

This review is dedicated to the indelible memory of Volker Henn and Andreas Böhmer—two outstanding clinician-scientists, two unfailing colleagues, and two dear friends. The world is a poorer place without them.

G M HALMAGYI
P D CREMER

Institute of Clinical Neurosciences, Royal Prince Alfred Hospital and the University of Sydney, Sydney, Australia

Correspondence to: Professor G M Halmagyi, Department of Neurology, Royal Prince Alfred Hospital, Camperdown, NSW 2050, Sydney, Australia email michael@icn.usyd.edu.au

- 1 Abboud FM. Neurocardiogenic syncope. *N Engl J Med* 1993;328:1117–20.
- 2 Stevens PM. Cardiovascular dynamics during orthostasis and the influence of intravascular instrumentation. *Am J Cardiol* 1966;17:211–8.
- 3 Jacob, RG, Furman JM, Durrant JD, et al. Panic, agoraphobia and vestibular dysfunction. *Am J Psychiatry* 1996;153:503–12.
- 4 Brandt T. Phobic postural vertigo. *Neurology* 1996;46:1515–9.
- 5 Bronstein AM, Gresty MA, Luxon LM, et al. Phobic postural vertigo [letter and reply]. *Neurology* 1997;49:1480–1.
- 6 Kapfhammer HP, Mayer C, Hock U, et al. Course of illness in phobic postural vertigo. *Acta Neurol Scand* 1997;95:23–8.
- 7 Brandt T, Daroff RB. Physical therapy for benign paroxysmal positioning vertigo. *Arch Otolaryngol* 1980;106:484–5.
- 8 Semont A, Freyss G, Vitte E. Curing BPPV with a liberatory maneuver. *Adv Otorhinolaryngol* 1988;42:290–3.
- 9 Epley J. The canalith repositioning procedure for treatment of BPPV. *Otolaryngol Head Neck Surg* 1992;107:399–404.
- 10 Fetter M, Sievering F. Three-dimensional eye movement analysis in BPPV and nystagmus. *Acta Otolaryngol (Stockh)* 1995;115:353–7.
- 11 Harvey SA, Hain TC, Adamiec LC. Modified liberatory maneuver: effective treatment for benign paroxysmal positional vertigo. *Laryngoscope* 1994;104:1206–12.
- 12 Pohl DV. Surgical treatment of benign positional vertigo. In: Baloh RW, Halmagyi GM, eds. *Disorders of the vestibular system*. New York: Oxford University Press, 1996:563–74.

- 13 Steddin S, Brandt T. Unilateral mimicking bilateral benign paroxysmal positioning vertigo. *Arch Otolaryngol Head Neck Surg* 1994;120:1339–41.
- 14 Baloh RW. Benign positional vertigo. In: Baloh RW, Halmagyi GM, eds. *Disorders of the vestibular system*. New York, Oxford University Press 1996:328–39.
- 15 Nuti D, Agus G, Barbieri M-T, et al. The management of horizontal canal paroxysmal positional vertigo. *Acta Otolaryngol (Stockh)* 1998;118:455–60.
- 16 Andrews JC, Honrubia V. Meniere's disease. In: Baloh RW, Halmagyi GM, eds. *Disorders of the vestibular system*. New York, Oxford University Press, 1996:300–19.
- 17 Gibson WPR, Arenberg IK. Pathophysiologic theories in the etiology of Meniere's disease. *Otolaryngol Clin North Am* 1997;30:961–8.
- 18 Harker L. Migraine associated vertigo. In: Baloh RW, Halmagyi GM, eds. *Disorders of the vestibular system*. New York: Oxford University Press, 1996:407–17.
- 19 Bickerstaff E. Basilar artery migraine. *Lancet* 1961;i:15–17.
- 20 Baloh RW. Neurotology of migraine. *Headache* 1997;37:615–21.
- 21 Bikhazi P, Jackson C, Ruckenstein MJ. Efficacy of antimigrainous therapy in the treatment of migraine-associated dizziness. *Am J Otol* 1997;18:350–4.
- 22 Levy D. Transient CNS deficits: a common benign syndrome in young adults. *Neurology* 1988;38:831–6.
- 23 Brandt Th, Dieterich M. Vestibular paroxysmia: vascular compression of the eighth nerve? *Lancet* 1994;i:798–9.
- 24 Böhmer A. Acute unilateral peripheral vestibulopathy. In: Baloh RW, Halmagyi GM, eds. *Disorders of the vestibular system*. New York: Oxford University Press, 1996:318–27.
- 25 Zee DS. Ophthalmoscopy in examination of patients with vestibular disorders. *Ann Neurol* 1978;3:373–4.
- 26 Halmagyi GM, Curthoys IS. A clinical sign of canal paresis. *Arch Neurol* 1988;45:737–9.
- 27 Halmagyi GM, Colebatch JG, Curthoys IS. New tests of vestibular function. *Baillieres Clin Neurol* 1994;3:485–500.
- 28 Fetter M, Dichgans J. Vestibular neuritis spares the inferior division of the vestibular nerve. *Brain* 1996;119:755–63.
- 29 Amarenco P. The spectrum of cerebellar infarctions. *Neurology* 1991;41:973–9.
- 30 Bronstein AM, Rudge P. Vestibular disorders due to multiple sclerosis, Arnold-Chiari malformations and basal ganglia disorders. In: Baloh RW, Halmagyi GM, eds. *Disorders of the vestibular system*. New York: Oxford University Press, 1996:476–95.
- 31 Hess K. Vestibulotoxic drugs and other causes of bilateral vestibulopathy. In: Baloh RW, Halmagyi GM, eds. *Disorders of the vestibular system*. New York: Oxford University Press, 1996:360–73.
- 32 Waterston JA, Halmagyi G M. Unilateral vestibulotoxicity due to systemic gentamicin therapy. *Acta Otolaryngol (Stockh)* 1998;118:474–8.
- 33 Halmagyi GM, Fattore CM, Curthoys IS, et al. Gentamicin vestibulotoxicity. *Otolaryngol Head Neck Surg* 1994;111:571–4.
- 34 Baloh RW, Jacobson K, Fife T. Familial vestibulopathy: a new dominantly inherited syndrome. *Neurology* 1994;44:20–5.
- 35 Rinne T, Bronstein AM, Rudge P, et al. Bilateral loss of vestibular function: clinical findings in 53 patients. *J Neurol* 1998;245:314–21.
- 36 Vanneste JAL. Three decades of normal pressure hydrocephalus: are we wiser now? *J Neurol Neurosurg Psychiatry* 1994;57:1021–5.
- 37 Hirose G, Halmagyi GM. Brain tumors and balance disorders. In: Baloh RW, Halmagyi GM, eds. *Disorders of the vestibular system*. New York: Oxford University Press, 1996:446–60.
- 38 Litvan I, Agid Y, Calne D, et al. Clinical research criteria for the diagnosis of progressive supranuclear palsy (Steele-Richardson-Olszewski syndrome). *Neurology* 1996;47:1–9.
- 39 Boroojerdi B, Ferbert A, Foltys H, et al. Evidence for a non-orthostatic origin of orthostatic tremor. *J Neurol Neurosurg Psychiatry* 1999;66:284–8.

EDITORIAL COMMENTARY

Who should treat psychiatric disorders in neurology patients?

Few neurologists doubt that a significant proportion of the patients who consult them have a psychiatric disorder of at least moderate severity. It is well established that conditions such as epilepsy, Parkinson's disease, multiple sclerosis, and cerebrovascular disease are associated with an increased vulnerability to anxiety disorders, affective disorders, and psychoses.¹ The predisposition probably results both from the functional disability associated with the neurological condition and also from disturbance of intracerebral neurotransmitter pathways. In addition to those with established organic disease neurologists are consulted by a considerable number of somatising patients,

those with little or no organic pathology but who have various neurological symptoms masking an underlying psychiatric disorder.²

The paper by Carson *et al*³ on pages 202–206 of this volume indicates the extent of this phenomenon in general neurological outpatient practice and confirms previous studies in this area. Only a minority of all patients with an emotional disorder were considered by their general practitioner or neurologist to require some form of psychological or psychiatric treatment. The exception was the group with unexplained symptoms, in over half of whom the neurologist thought that such treatment was required.

In a previous survey of neurological inpatients the prevalence of psychiatric morbidity, estimated by a standardised two stage assessment, was 39%, of which 72% was not recognised by the neurologists.⁴ Patients were divided on whether they wished to discuss their mood with the clinician. Fifty five per cent thought that such an inquiry would have been unhelpful. Reasons given included the lack of privacy of hospital wards and the inability to see the consultant without the presence of an accompanying entourage of junior doctors and other professional staff. However, few patients with an emotional disorder expressed a need for psychiatric or psychological treatment, raising the question of what is the most appropriate management for their problems.

Neurologists, in keeping with other clinicians, must by now be bored by critical comments from psychiatrists that they fail to recognise psychiatric disorders in their patients. The study of Carson *et al* indicates that even when the disorders are recognised, patients are reluctant to embark on any form of psychological treatment. They resist psychiatric referral for various reasons, including the perceived stigma of psychiatric illness and also because of their conviction that their symptoms are due to a physical rather than a psychological process. It is likely that for most patients, such as those identified in this study, management of their psychiatric problems will have to be undertaken jointly by the neurologist and general practitioner. This particularly applies to those patients whose emotional disorders coexist with an underlying neurological disorder. The fledgling specialty of liaison psychiatry does not have the resources to deal with the numbers of patients Carson *et al* have identified. For practical reasons only those patients with complex and treatment resistant conditions

should be referred. The psychiatrist needs to have a close working relationship with neurological colleagues and particular experience of assessing patients with neurological symptoms.

Patients who somatise are much more likely to accept psychiatric treatment if an attempt is made to modify the way they perceive their symptoms. The simple techniques of cognitive behaviour therapy can help the patient reattribute the symptoms and recognise them as being linked with an underlying emotional problem which requires appropriate intervention. It has been demonstrated that the techniques of reattribution can be taught to general practitioners⁵ and when applied in practice they can reduce the levels of psychopathology. The acquisition of cognitive behaviour therapy skills will facilitate the management of such patients in the general practice surgery and neurology clinic.

G G LLOYD

Department of Liaison Psychiatry, Royal Free Hospital,
London NW3 2QG, UK

- 1 Ron MA. Psychiatric manifestations of demonstrable brain damage. In: MA Ron, A S David, eds. *Disorders of brain and mind*. Cambridge: Cambridge University Press, 1998:177–95.
- 2 Lloyd GG. Acute behaviour disturbances. *J Neurol Neurosurg Psychiatry* 1993;56:1149–56.
- 3 Carson AJ, Ringbauer B, MacKenzie L, *et al*. Neurological disease, emotional disorder, and disability: they are related: a study of 300 consecutive new referrals to a neurology outpatient department. *J Neurol Neurosurg Psychiatry* 2000;68:202–6.
- 4 Bridges KW, Goldberg DP. Psychiatric illness in in-patients with neurological disorders: patients' views on discussion of emotional problems with neurologists. *BMJ* 1984;289:656–8.
- 5 Gask L, Goldberg D, Porter R, *et al*. The treatment of somatisation: evaluation of a teaching package with general practitioners. *J Psychosom Res* 1989; 33:697–703.

REVIEW SERIES

Neurological aspects of tropical disease

The set of six review articles *Neurological aspects of tropical disease* published in this and subsequent issues of *the Journal* is an attempt to highlight some of the important neurological diseases in the tropics. We make no apologies for choosing six infectious diseases, as we think that such diseases still represent the major burden of disease in the developing world. We cannot hope to provide a comprehensive review of the subject and the selection of what to include may not be everyone's choice. All the authors are currently (or were until very recently) involved in clinical practice or in research in the conditions that they review. In the United Kingdom, tropical medicine has traditionally been the preserve of specialists, usually allied to departments of infectious diseases. There are strong historical and contemporary reasons for this and on balance the discipline has been well served by the arrangement. However, the subspecialties in internal medicine in the developed world have progressed so much over the past few years that it is almost impossible for the true generalist (the tropical medicine specialist) to maintain an up to date grasp of each specialty. Such knowledge is critical in tropical medicine.

Although a patient may present with malaria or tetanus the management challenges are often those of the paediatrician, the renal physician, the cardiologist, or the neurologist. The development of subspecialties in paediatrics has lagged behind those in adult medicine. For example there are only a handful of paediatricians who have been trained in paediatric neurology and developmental medicine working in sub-Saharan Africa, besides South Africa. The impact of infectious diseases and nutritional deficiencies has only become evident recently.

We hope that this series will achieve three things. The first is to provide a contemporary review of neurological infectious diseases important in the tropics. The increased mobility of people and globalisation of disease means that neurologists world wide may be asked to see such patients in their own practice. We hope that the reviews will be helpful in guiding management in that setting. Access to medical information is still difficult in much of the tropical world. Our second hope is that *the Journal* will make this series available to areas of the world where it is not usually read.

Our third hope is that these articles may stimulate neurologists, paediatricians, and psychiatrists (and those in training in these specialties) in the United Kingdom and beyond to become more actively involved in clinical practice and research in neurological diseases in the tropical world. There is no doubt that infectious diseases will continue to be a major cause of morbidity and mortality in the tropics and hence the emphasis in this series on such diseases. However, the Global Burden of Disease Study has predicted that patterns of disease will change dramatically by the year 2020 with an increase in the incidence of non-communicable diseases. There is very little reliable information on the burden of psychiatric conditions,

epilepsy, cerebrovascular disease, or other diseases affecting the nervous system in the tropical world. As the specialty of tropical medicine evolves to become a specialty of medicine in the tropics the interaction with other disciplines such as neurology, developmental medicine, psychiatry, and rehabilitation should become increasingly important.

JEREMY FARRAR

*Wellcome Trust Clinical Research Group, Centre for Tropical Diseases,
190 Ben Ham Tu, Quan 5, Ho Chi Minh City, Vietnam*

CHARLES NEWTON

*Department of Paediatric Neurosciences and International Child Health,
PO Box 230, Kilifi, Kenya*