

LESSON OF THE MONTH

A case of paraneoplastic syndrome accompanied by two types of cancer

K Miyamoto, T Kato, H Watanabe, E Miyamoto, S Suzuki

J Neurol Neurosurg Psychiatry 2002;**72**:408–409

A case of paraneoplastic syndrome accompanied by two types of cancer is reported. The patient was a 62 year old man who progressively developed cerebellar ataxia, especially an abnormal gait. The anti-Hu antibody titre was high. A small tumour was detected in the middle lobe of the right lung and was surgically treated. The histology was adenocarcinoma. After lobectomy, however, the ataxia deteriorated, and plasma exchange, 250 ml/kg/day, was conducted for 6 days. After plasma exchange, the anti-Hu antibody titre decreased and the ataxia temporarily ceased to progress. A week after the last plasma exchange, a mass appeared in the anterior cervical region and rapidly increased in size. The biopsy of the neck tumour disclosed a small cell carcinoma. Five months later small cell carcinoma appeared in the left lung. This case shows the importance of searching for small cell carcinoma when anti-Hu antibodies are detected. It is assumed that plasma exchange removed not only a pathogenic factor of ataxia but also a factor which inhibited the growth of the small cell carcinoma. It is recommended that plasmapheresis should be performed with caution in paraneoplastic syndrome when the origin of a tumour is obscure.

Paraneoplastic syndrome results from the remote neurological effects of cancer. The main clinical features are encephalomyelitis, cerebellar cortical degeneration, peripheral neuropathy, opsoclonus-myoclonus, and retinopathy. Several autoantibodies reacting with both neuronal antigens and tumours have been detected. Anti-Hu antibody causes peripheral neuropathy, limbic encephalopathy, cerebellar ataxia, and autonomic dysfunction.^{1–3} Most patients with positive anti-Hu antibody titres have small cell lung cancer. Treatment with steroids, plasmapheresis, and immunosuppressive therapy does not usually improve the neurological signs.

We report a case of a 62 year old man with paraneoplastic syndrome in whom two types of lung cancer, small cell and adenocarcinoma, were detected.

CASE REPORT

A 62 year old man presented with a 4 month history of progressive gait disturbance. He had smoked 20 cigarettes a day for 40 years. There was no family history of a similar disorder. The physical examination was normal. Neurological examination showed no dementia or cranial nerve dysfunction, normal muscle strength and deep tendon reflexes, and a normal sensory system. Cerebellar dysfunction was prominent, including ataxic speech, bilateral clumsiness in finger to nose and heel to knee testing, and wide based gait.

Laboratory findings were normal, except for a high titre of anti-Hu antibodies (0.73 U, normal <0.07 U). A CSF examination and head MRI, with and without contrast, were normal.

Both plain radiography and CT of the chest showed a small mass in the right middle lobe, and adenocarcinoma was diagnosed from the biopsy (fig 1). After a right middle lobectomy, however, the anti-Hu antibody titre increased to 0.89 U, and cerebellar ataxia continued to worsen although there were no signs of tumour recurrence or metastasis. We performed plasma exchange, 250 ml/kg/day, for 6 days. After plasma exchange, the anti-Hu antibody titre declined to 0.25 U, and ataxia temporarily ceased to progress. A week after the last plasma exchange, a mass appeared abruptly in the anterior cervical region and rapidly increased in size. The mass was biopsied and small cell carcinoma was confirmed (fig 1). Examination of the whole body did not show any small cell carcinoma at this time. The anti-Hu antibody titre then increased again (0.52 U) and cerebellar ataxia also worsened. Five months after the neck tumour biopsy, we found small cell carcinoma in the left lung which we considered to be the origin of the neck metastasis. The patient died from complications of the second tumour.

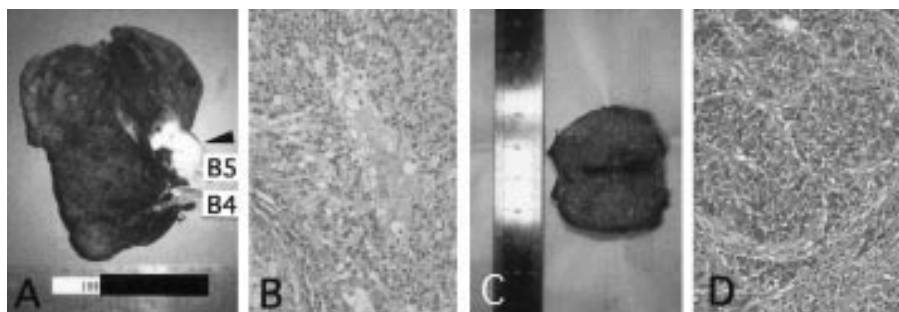


Figure 1 Adenocarcinoma and small cell carcinoma. A mass in the right middle lung was surgically removed. (A) The mass was in the hilus (arrowhead), and (B) light microscopic examination showed that it was an adenocarcinoma. (C) The cervical mass was biopsied, and (D) the histology was a small cell carcinoma. (B and D originally $\times 100$.)

DISCUSSION

We present here a patient with paraneoplastic syndrome with anti-Hu antibodies, in whom first adenocarcinoma was found in the lung, and then small cell carcinoma appeared in the neck and lung after plasma exchange. The small cell carcinoma was found 2 years after the patient first noticed ataxia.

Paraneoplastic syndrome with high titres of anti-Hu antibody is seen in most cases of small cell lung cancer.¹ In a few cases, however, anti-Hu syndrome is accompanied by prostate cancer, adrenal cancer, neuroblastoma, and sarcoma. In the present case, we first suspected that lung adenocarcinoma was the cause of the paraneoplastic syndrome. However, the anti-Hu antibody titre did not decrease after resection of the adenocarcinoma, but, rather, increased in parallel with the growth of the small cell carcinoma. Lung adenocarcinoma which reacts with anti-Hu antibody is very rare.¹ Thus, there is little possibility that the lung adenocarcinoma caused the paraneoplastic syndrome in this case. It is likely that a minute small cell carcinoma, which could not be detected at first, might have existed from the beginning of the neurological symptoms, giving rise to the paraneoplastic syndrome. Auf *et al* reported on an anti-Hu antibody positive patient with combined mammary adenocarcinoma and small cell lung cancer.⁴ The patient showed a subacute predominantly sensory neuropathy, and the authors attributed the neuropathy to the anti-Hu antibody produced against the small cell lung carcinoma. Our case is unique in that both of the cancers originated in the lung. In anti-Hu antibody associated paraneoplastic syndrome, it is important to search for small cell carcinoma.

There is no established therapy that significantly and continuously improves the neurological signs of anti-Hu associated paraneoplastic syndrome. Treatment of paraneoplastic syndrome with plasmapheresis has been reported,^{5,6} but the results are not encouraging. In our case, plasma exchange resulted in a temporary halt in the progression of ataxia, but a second tumour appeared immediately and grew rapidly after plasma exchange. There have been no reports of tumour growth after plasma exchange. We assume that plasma exchange removes not only the pathogenic factors of cerebellar ataxia but also factors which inhibit tumour growth, such

as TNF- α , IFN- γ , IL-1, IL-2, IL-6, and IL-12.⁷ Plasma concentrations of these cytokines are decreased by plasmapheresis.^{8,9} We recommend that plasmapheresis should be performed very cautiously to avoid the potential growth of tumours in paraneoplastic syndrome, especially when the origin of a tumour is obscure. Further investigation is needed to confirm our finding.

Authors' affiliations

K Miyamoto, Department of Immunology, National Institution, NCNP, Kodaira, Tokyo 187-8502, Japan
T Kato, **E Miyamoto**, **S Suzuki**, Department of Neurology, Osaka Red Cross Hospital, Tennoji-ku, Osaka 570-0027, Japan
H Watanabe, Department of Thoracic Surgery, Osaka Red Cross Hospital, Tennoji-ku, Osaka 570-0027, Japan

Correspondence to: Dr K Miyamoto, Department of Immunology, National Institution, NCNP, Kodaira, Tokyo 187-8502, Japan; miyamo@ncnp.go.jp

Received 21 August 2001

In revised form 5 October 2001

Accepted 12 October 2001

REFERENCES

- 1 **Dalmau J**, Graus F, Rosenblum MK, *et al*. Anti-Hu associated paraneoplastic encephalomyelitis/sensory neuropathy. A clinical study of 71 patients. *Medicine* 1992;**71**:75-103.
- 2 **Dalmau J**, Furneaux HM, Gralla RJ, *et al*. Detection of anti-Hu antibody in the serum of patients with small cell lung cancer: a quantitative western blot analysis. *Ann Neurol* 1990;**27**:544-552.
- 3 **Darnell RB**, Deangelis LM. Regression of small-cell lung carcinoma in patients with paraneoplastic neuronal antibodies. *Lancet* 1993;**341**:21-2.
- 4 **Auf G**, Benyahia B, Orzel B, *et al*. Subacute neuropathy, multiple cancers, and Sjogren's syndrome: contribution of anti-Hu antibody. *Rev Neurol (Paris)* 2001;**157**:219-21.
- 5 **Graus F**, Vega F, Delattre JY, *et al*. Plasmapheresis and antineoplastic treatment in CNS paraneoplastic syndromes with antineuronal autoantibodies. *Neurology* 1992;**42**:536-40.
- 6 **Graus F**, Abos J, Roquer J, *et al*. Effect of plasmapheresis on serum and CSF autoantibody levels in CNS paraneoplastic syndromes. *Neurology* 1990;**40**:1621-3.
- 7 **Chydzewska E**, Mroz RM. Cytokines in lung cancer. *Rocz Akad Med Bialymst* 1997;**42**(suppl 1):8-22.
- 8 **Skerrett D**, Mor E, Curtiss S, *et al*. Plasmapheresis in primary dysfunction of hepatic transplants. *J Clin Apheresis* 1996;**11**:10-13.
- 9 **Gardlund B**, Sjolín J, Nilsson A, *et al*. Plasma levels of cytokines in primary septic shock in humans: correlation with disease severity. *J Infect Dis* 1995;**172**:296-301.