

SHORT REPORT

Isolated corpus callosal infarction secondary to pericallosal artery disease presenting as alien hand syndrome

N C Suwanwela, N Leelacheavasit

J Neurol Neurosurg Psychiatry 2002;**72**:533–536

Two patients are described with the callosal type of alien hand syndrome. Both presented with abnormal feelings in the left upper limb and intermanual conflict without clinical evidence of callosal apraxia or frontal lobe dysfunction such as motor deficit or reflexive grasping. Imaging studies disclosed subacute infarction in the body and splenium of the corpus callosum due to pericallosal artery disease. These patients were unique in their presentation as a callosal type of alien hand syndrome secondary to ischaemic stroke.

Alien hand syndrome is a fascinating but controversial clinical entity. Brion and Jedynek, in 1972, first described three patients with tumour of the corpus callosum who failed to recognise ownership of one hand when it was placed into the other hand behind the back and introduced the concept of the alien hand (*la main étrangère*).¹ Subsequently, the term has been applied to a motor phenomena of apparently purposeful actions of one hand against the patient's intention.² Perception disturbance, which makes this syndrome unique, is always verbally expressed, even expression of astonishment at the autonomous activities of the alien hand may occur. Neuroimaging and pathological studies demonstrated that the frontal lobe and corpus callosum are the most common anatomical lesions responsible for this distinctive phenomenon.^{3,4} Here, we describe the clinical, neuroanatomical, and radiological findings of two patients who presented with the callosal type of alien hand syndrome. The isolated manifestation of intermanual conflict without evidence of callosal apraxia and forced grasping makes our patients substantially different from those previously described. On neuroradiological studies, both patients had infarction restricted to the corpus callosum secondary to stenosis of the supracallosal segment of the pericallosal artery.

CASE REPORTS

Patient 1

This patient was a 54 year old right handed Thai man who presented with abnormal feelings in his arms. His medical history included diabetes mellitus and hypertension which had been poorly controlled. The symptoms had started while he was sitting, when he suddenly experienced transient weakness of the lower limbs, which lasted for only 5 minutes. Ten hours later, he noticed some strange feelings in his arms. For example, when he crossed his arms behind his back, he felt as if the right hand was touched by a foreign hand. The feeling disappeared when he placed both hands in the front. When he reached into his pocket with his left hand, he felt as if there was another, non-existing, hand touching it. When he

held a paper with both hands, the left hand would try to pull the paper against the right. Some actions indicating mirror movement were also seen. For example, when he moved his right hand backwards, he felt that the left hand was pulled back in the same manner. On examination, he was alert. Motor power of the arms and legs was full. There was no pinprick sensory loss or inattention, on double simultaneous stimulation test. Proprioceptive sense was normal. He could not identify his left hand fingers or objects placed in his left hand with his eyes closed, but was able to do so under visual observation. There was no apraxia of the left hand on verbal command, in imitation, and in actual object use. Frontal lobe releasing signs such as reflexive grasping, palmomental reflex, and snout reflex were absent.

Brain MRI on admission showed lesions with hypointensity on T1 weighted and hypersignal intensity on T2 weighted and FLAIR images in the body and splenium of the corpus callosum. There was no associated frontal lobe lesion. The diffusion weighted study showed increased signal intensity of the involved area (fig 1 A and B). Magnetic resonance angiography of the cerebral vessels showed a variation of the anterior cerebral artery, with only a single trunk of pericallosal branches. Stenosis and irregularity of the supracallosal segment of the right pericallosal artery which could have been responsible for the callosal infarction was also demonstrated (fig 1 C).

Case 2

This patient was a 50 year old right handed Thai woman with a history of diabetes mellitus, dyslipidaemia, and coronary artery disease. She was admitted for coronary artery bypass grafting. The operation went uneventfully without any immediate complications. On the 7th day postoperatively, she was noted by nursing staff to have mild slurring of speech. She also complained of loss of bimanual coordination. For example, she could not tie a rope by herself as the left hand would not help the right and at times even tried to inhibit the action. When she held a piece of paper with both hands, each hand would pull against each other. She also reported that the left hand would not release the telephone when she wanted to use it with her right hand. The intermanual conflict was so pronounced that she felt as if the left hand was under someone else's control. On neurological examination, she was alert and oriented. There was only mildly dysarthric speech. No evidence of motor aphasia was demonstrated. Hypaesthesia of the left side of her body and face was also noted. The motor power and tone were normal. She was able to release objects held in the left hand when asked by the examiner. Forced grasping and other frontal release signs were absent. Apraxia was absent, both on verbal command and pantomime of object use. There was no tactile agnosia, agraphia, or alexia. Stereognosis was normal. Other general physical examination was within normal limits. Regarding the aetiology of stroke, there

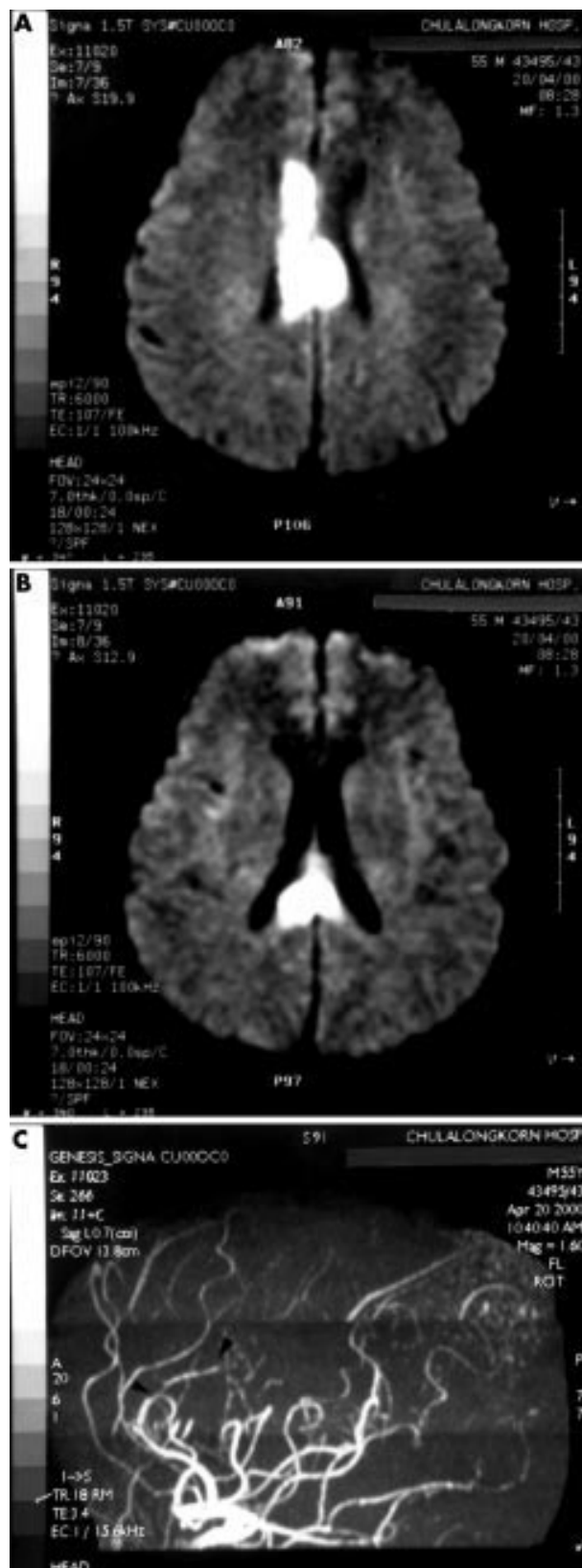


Figure 1 (A and B) Axial diffusion weighted images of patient 1 show a high signal intensity lesion compatible with acute infarction in the body and splenium of the corpus callosum. (C) Magnetic resonance angiography shows irregularity and narrowing of the supracallosal branch of the pericallosal artery (arrows).

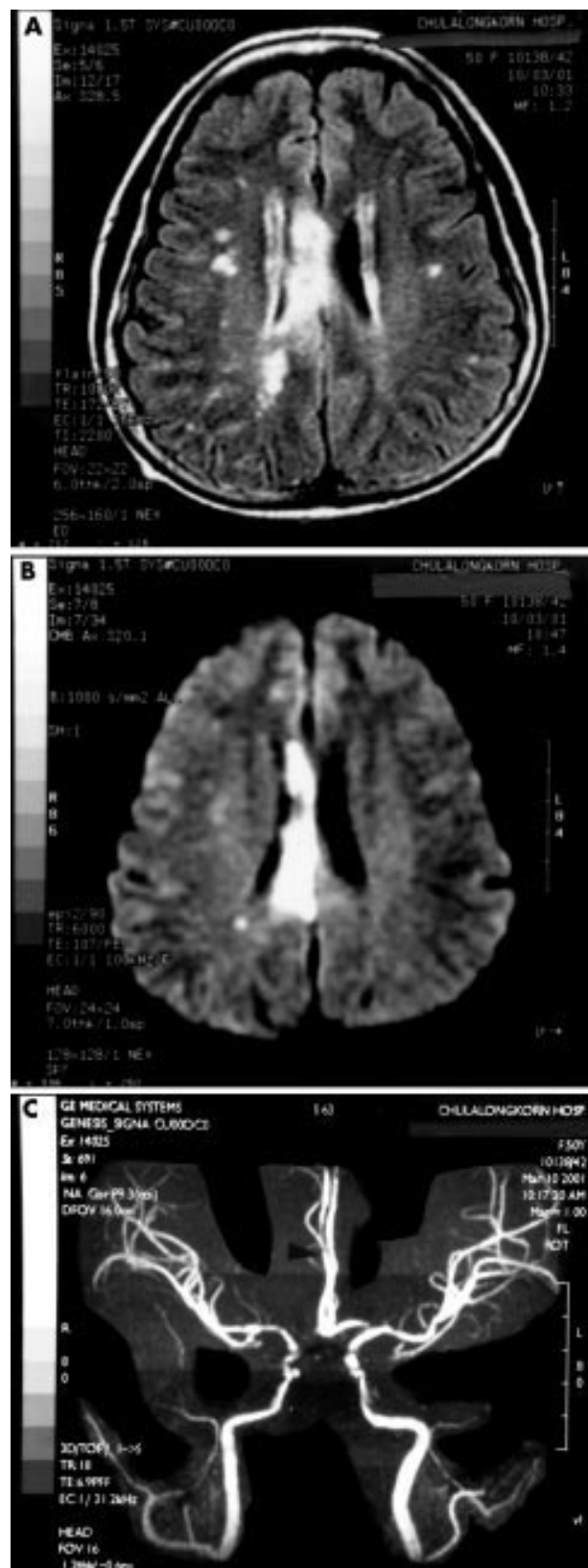

Figure 2 (A) Axial FLAIR image of patient 2 demonstrates a high signal intensity lesion in the body of the corpus callosum and multiple small lesions in the subcortical white matter. (B) Diffusion image shows high signal intensity lesion in the body of the corpus callosum indicating acute infarction. The multiple old lacunar infarctions in the frontal and parietal subcortical white matter seen in FLAIR are not demonstrated. (C) Magnetic resonance angiography demonstrates multiple sites of atherosclerotic narrowing of the intracranial vessels; both cavernous part of the internal carotid arteries and both middle cerebral arteries. Narrowing of the right pericallosal artery is also shown (arrow).

was no atrial fibrillation. An ECG showed a moderate aortic regurgitation without intracardiac clot. All of the neurological symptoms disappeared within 48 hours.

Brain MRI showed a region of low signal intensity in the right side of the body of the corpus callosum on the T1 weighted image and high signal intensity in the same area on T2 weighted and FLAIR images (fig 2 A). Diffusion weighted images also showed increased signal intensity at the same region (fig 2 B). Evidence of old lacunar infarction in the frontal and parietal subcortical white matter was noted in the T2 weighted and FLAIR images but not on the diffusion studies. There was no evidence of a frontal lobe lesion. Magnetic resonance angiography showed an absence of the A1 segment of the right anterior cerebral artery. Atherosclerotic narrowing of the cavernous portion of both internal carotid arteries and the proximal part of both middle cerebral arteries were noted. There was a significant stenosis of the supracallosal segment of the right pericallosal artery (fig 2 C).

DISCUSSION

The term "alien hand syndrome" has been used to describe two distinctive phenomena. Originally, it was proposed by Brion and Jedynak as a sensory phenomenon characterised by the denial of ownership of one hand despite no sensory loss when it was held by the other hand behind the back, secondary to lesions of the parietal lobe and posterior part of corpus callosum.¹ Subsequently, the same term has become more recognised as a psychomotor disorder characterised by the patient's perception of alienation coexisting with observable involuntary, but seemingly purposeful, movement of the affected limb.³⁻⁶ Motor phenomena of the alien hand syndrome vary from simple to complex and apparently purposeful movements. Recently, the term "anarchic hand" has been proposed to distinguish the motor phenomena of alien hand syndrome from the original description of sensory misperception.⁶ Both patients in this report presented with a predominantly motor type of alien hand syndrome. However, an associated sensory phenomenon similar to that originally described by Brion and Jedynak was shown in the first case.¹

Two types of predominantly motor alien hand syndrome were proposed by Della Sala *et al* in 1991.⁷ The first type is an acute or transient form due to callosal lesions. The other more common form is a chronic condition resulting from both callosal and additional mesial frontal lesions. Feinberg *et al* reviewed the clinical characteristics and neuroanatomy of 20 reported cases of alien hand syndrome and categorised the alien hand syndrome into two distinct syndromes.⁸ The "frontal alien hand syndrome" results from damage to the supplementary motor area, anterior cingulate gyrus, medial prefrontal cortex of the dominant hemisphere, and anterior corpus callosum. The symptoms of frontal alien hand syndrome always occur in the dominant hand, with prominent motor phenomena including reflexive grasping, groping, and compulsive manipulation of tools. The second type or "callosal alien hand syndrome" requires only a callosal lesion and is characterised primarily by intermanual conflict and the non-dominant hand is usually affected. Clinically, our patients fulfilled the criteria for the callosal type of alien hand syndrome. The feeling of alienation, including intermanual conflict and mirror movement, was found in the left upper limb in both cases. Neuroimaging studies confirmed the responsible lesions for the interhemispheric motor disconnection syndrome in the corpus callosum. However, both patients did not manifest the profound callosal apraxia which has been previously reported with lesions in the body of the corpus callosum.^{6,8}

Many medical and surgical conditions can cause alien hand syndrome.⁹⁻¹⁷ For patients with alien hand syndrome secondary to ischaemic stroke, the anterior cerebral artery is almost always the affected vessel.^{7,13-17} Anterior cerebral artery infarction

is responsible for less than 3% of all ischaemic strokes,¹⁵ and alien hand syndrome is considered to be an uncommon manifestation.¹⁵ Among reported patients, the alien hand syndrome after anterior cerebral artery infarction is clinically frontal type with prominent reflexive grasping of the dominant hand and motor deficits suggesting frontal lobe dysfunction.^{7,13-17} The responsible anatomical lesions are generally located in the corpus callosum and the neighbouring frontal lobe especially in the supplementary motor area. According to Giroud and Dumas, alien hand syndrome was found in only two out of eight patients with callosal infarction and both of these had hemiparesis and forced grasping which is characteristic of frontal alien hand syndrome.¹⁵ Our two patients each displayed the characteristic pattern of callosal alien hand syndrome. Their symptoms appeared in the non-dominant upper limbs and there was no obvious motor deficit or reflexive grasping.

These patients are unique in their manifestations and the imaging findings. Both demonstrated isolated corpus callosal lesions without evidence of cortical involvement on MRI during the acute phase. However, they initially displayed symptoms consistent with frontal lobe dysfunction. The first patient reported a transient weakness of both lower limbs whereas the second case had mild dysarthria. Therefore, it is possible that these patients sustained some degree of cortical damage in addition to the callosal lesion. Temporary ischaemia of the frontal lobe resulting in limited area of residual infarction on MRI may explain this phenomena. We were able to show the responsible vascular lesions at the pericallosal branch of anterior cerebral artery by magnetic resonance angiography. To our knowledge, there have been no previous reports documenting pericallosal artery disease as a cause of alien hand syndrome. In the first patient, variation of the pericallosal artery as a single trunk supplying both sides of the corpus callosum causing bilateral infarction was shown on MRI.¹⁸ The second patient had lesions in the right pericallosal artery resulting in infarction of the right side of the corpus callosum.

Authors' affiliations

N C Suwanwela, N Leelacheavasil, Neurological Unit, Department of Medicine, Faculty of Medicine, Chulalongkorn University, Bangkok 10330, Thailand

Correspondence to: Dr N C Suwanwela, Neurological Unit, Department of Medicine, Faculty of Medicine, Chulalongkorn University, Bangkok 10330, Thailand; fmednsu@md2.md.chula.ac.th

Received 19 June 2001

In revised form 17 September 2001

Accepted 5 November 2001

REFERENCES

- 1 **Brion S, Jedynak C-P.** Troubles du transfert interhémisphérique (callosal disconnection). A propos de trois observations de tumeurs du corps calleux. Le signe de la main étrangère. *Rev Neurol (Paris)* 1972; **126**:257-66.
- 2 **Goldberg G, Mayer N, Togliola JU.** Medial frontal cortex infarction and the alien hand sign. *Arch Neurol* 1981; **38**:683-6.
- 3 **Banks G, Short P, Martinez J, et al.** The alien hand syndrome: clinical and post mortem findings. *Arch Neurol* 1989; **46**:456-9.
- 4 **Benson DF, Geschwind N.** The aphasias and related disturbances. In: Baker AB, Joynt RJ, ed. *Clinical neurology*. Philadelphia:Harper and Row 1985:1-85.
- 5 **Doody RS, Jankovic J.** The alien hand and related signs. *J Neurol Neurosurg Psychiatry* 1992; **55**:806-10.
- 6 **Geschwind DH, Iacoboni M, Mega MS, et al.** Alien hand syndrome: Interhemispheric motor disconnection due to a lesion in the midbody of the corpus callosum. *Neurology* 1995; **45**:802-8.
- 7 **Della Sala S, Marchetti C, Spinner H.** Right sided anarchic (alien) hand: a longitudinal study. *Neuropsychologia* 1991; **29**:1113-27.
- 8 **Feinberg TE, Schindler RJ, Flanagan NG, et al.** Two alien hand syndromes. *Neurology* 1992; **42**:19-24.

- 9 **Jeeves MA**, Simpson DA, Geffen G. Functional consequences of the transcallosal removal of intraventricular tumors. *J Neurol Neurosurg Psychiatry* 1979;**42**:134–42.
- 10 **Leiguarda R**, Starkstein S, Bethier M. Anterior callosal hemorrhage: a partial interhemispheric disconnection syndrome. *Brain* 1989;**112**:1019–37.
- 11 **Fisher CM**. Alien hand phenomenon: a review with the addition of six personal cases. *Can J Neurol Sci* 2000;**27**:192–203.
- 12 **Gibb WRG**, Luther PJ, Marsden CD. Corticobasal degeneration. *Brain* 1989;**112**:1171–92.
- 13 **McNabb AV**, Carroll WM, Mastaglia FL. "Alien hand" and loss of bimanual coordination after dominant anterior cerebral artery infarction. *J Neurol Neurosurg Psychiatry* 1988;**51**:218–22.
- 14 **Chan JL**, Ross ED. Left hand mirror writing following right anterior cerebral artery infarction: evidence for non-mirror transformation of motor programs by right supplementary motor area. *Neurology* 1988;**38**:59–63.
- 15 **Giroud M**, Dumas R. Clinical and topographical range of callosal infarction: a clinical and radiological correlation study. *J Neurol Neurosurg Psychiatry* 1995;**59**:238–42.
- 16 **Hanakita J**, Nishi S. Left alien sign and mirror writing after left anterior cerebral artery infarction. *Surg Neurol* 1991;**35**:290–3.
- 17 **Baptista AG**. Studies on the arteries of the brain II. The anterior cerebral artery: some anatomic features and their clinical implications. *Neurology* 1963;**13**:825.

NEUROLOGY IN LITERATURE

A RAYMOND CHANDLER TRIO

The big sleep: Hamish Hamilton 1939

Her hand holding the empty gun began to shake violently. The gun fell out of it. Her mouth began to shake. Her whole face went to pieces. Then her head screwed up towards her left ear and froth showed on her lips. Her breath made a whining sound. She swayed.

Farewell my lovely: Hamish Hamilton 1940

But naturally there are certain elements which would like to show me in a bad light. Psychiatrists, sex specialists, neurologists and nasty little men with rubber hammers and shelves loaded with the literature of aberrations.

The high window: Hamish Hamilton 1943

Her mouth was in a tight line at the corners, but the middle part of her upper lip kept lifting off her teeth, upwards and outwards as if fine threads attached to the edge of the lip were pulling it. It would go up so far that it didn't seem possible, and then the entire lower part of her face would go into a spasm and when the spasm was over her mouth would be tight shut, and then the process would slowly start all over again. In addition to this there was something wrong with her neck. So that very slowly her head was drawn around to the left about forty-five degrees. It would stop there, her neck would twitch, and her head would slide back the way it had come.

Curiously Carmen Sternwood's epilepsy as described in *The big sleep* does not appear in the film starring Humphrey Bogart and Lauren Bacall. Nor indeed does the recent remake of *Farewell my lovely* refer to the rather deprecatory remarks made by Jules Anthon in that book regarding neurologists. Jules Anthon is described as a psychic consultant. Reading the book one has to say he seems to be more troubled by aberrations than most neurologists that I have met.

The description of Merle Davis' movement disorder appears in *The high window*. Reading between the lines one is probably meant to infer that the movements were due to psychological stress. The description of the facial component of her movement disorder is intriguing and one that I perhaps would not immediately identify. It does not really fit with the clinical features of Meige's syndrome. The neck movements are more straightforward in suggesting a spasmodic torticollis. The book doesn't indicate the eventual outcome of the problem although the psychological issues are probably eventually settled.

G D Perkin

Imperial College School of Medicine, Charing Cross hospital, Fulham Palace Road, London W6 8RF, UK