

## PHYSICAL SIGNS

# Diagnostic value of nystagmus: spontaneous and induced ocular oscillations

A Serra, R J Leigh

Research over the past 20 years has provided a clearer understanding of the pathogenesis of most forms of nystagmus and other ocular oscillations. To the clinician, these advances translate into greater accuracy of nystagmus as a diagnostic sign. However, to capitalise on these advances, it is important to systematically examine eye movements and interpret the findings with reference to pathophysiology. In this review we describe a scheme for examining the patient with nystagmus and interpreting common ocular oscillations; some examples are provided as video clips.



Video clips relating to this paper are available on the journal web site ([www.jnnp.com](http://www.jnnp.com))

Enough is now known about nystagmus to make it a valuable clinical finding, provided that it is characterised systematically, and interpreted in the context of the general neurological evaluation. Nystagmus may be defined as repetitive, to and fro, involuntary eye movements that are initiated by slow drifts. Nystagmus may consist mainly of sinusoidal slow phase oscillations (pendular nystagmus) or, more commonly, of an alternation of slow drift and corrective quick phase (jerk nystagmus). Common waveforms are schematised in figure 1. Thus, each slow phase takes the eye away from the preferred direction of gaze and the corrective quick phase (a saccade) brings the eye back towards the visual target. Although nystagmus is often described by the direction of its quick phases (for example, down-beat nystagmus), it is the slow phase that reflects the underlying disorder. Nystagmus should be differentiated from saccadic intrusions and oscillations, in which rapid movements (saccades) take the eye away from the target (fig 1).

Modern classifications of nystagmus are based on current knowledge of the neurobiology of eye movements,<sup>1</sup> and disorders of the three mechanisms that normally hold gaze still (visual fixation, the vestibulo-ocular reflex, and the eccentric gaze holding mechanism).<sup>2</sup> However, at the bedside, the clinician must rely on the observed characteristics of nystagmus and a systematic examination of eye movements to deduce the significance of any ocular oscillations. Here we describe how to elicit nystagmus and saccadic oscillations, and then summarise the general significance of common forms of nystagmus. To realise the full diagnostic value of nystagmus requires a broader discussion of pathophysiology, which can be found in standard neuro-ophthalmological textbooks.<sup>2-4</sup> Some brief video examples of common forms of nystagmus have

*J Neurol Neurosurg Psychiatry* 2002;**73**:615-618

been posted at the journal web site, and others are available in a text/CD.<sup>2</sup>

### HISTORY

Inquire about the duration of the nystagmus, whether it interferes with vision or causes oscillopsia (illusory motion of the visual world), and whether it is accompanied by other neurological symptoms. In general, oscillopsia is a feature of acquired, not congenital, nystagmus. Ask if associated visual symptoms are worse when viewing far or near objects, during specific directions of gaze (for example, downgaze), or when the patient is in motion (which implies a vestibular disorder). Try to determine if the nystagmus is congenital by asking about "jumping eyes," strabismus, eye patching, or eye operations since childhood. Check the patient's current medications for agents with effects on the brain (for example, anticonvulsants). If the patient habitually tilts or turns the head, determine whether these findings are evident on old photographs, which would suggest congenital nystagmus.

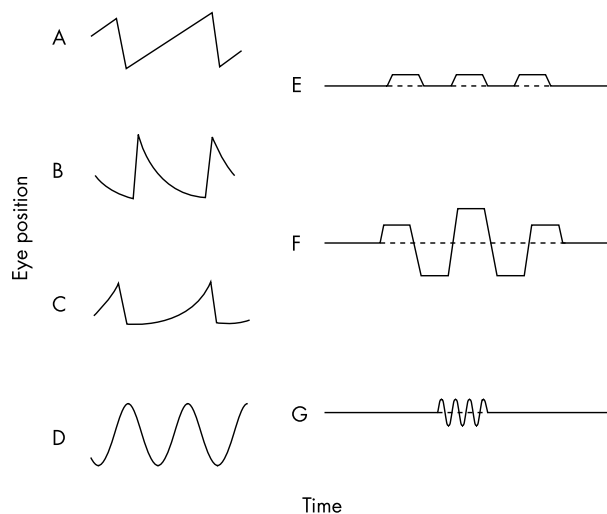
### EXAMINATION

Before starting an evaluation of nystagmus, note any abnormality of head posture, examine the visual system (acuity, fields, colour, stereopsis), optic nerves, lids, pupils, and look for signs of ocular albinism. Several congenital forms of nystagmus are associated with disorders of the visual system.<sup>2-4</sup>

Before examining for nystagmus, determine whether there is a full range of the movements of each eye, and note any static deviation (strabismus). Then observe the stability of gaze as the patient attempts to fix upon a stationary target (such as the letter X) at a viewing distance greater than 2 m. With the patient's eyes close to central position, determine whether there is any nystagmus. For each eye, note the directions in which the nystagmus occurs: horizontal, vertical, torsional (rotational around the line of sight), or mixed. Compare the nystagmus in each eye, and note whether the direction or size of movement differs, or if there is any asynchrony. If the size of the oscillations differs in each eye, it is referred to as dissociated nystagmus. If the direction of the oscillations in each eye differs, it is called disconjugate or disjunctive nystagmus. Cover each eye in turn to check for latent nystagmus (see video "Latent\_Nystagmus"). Some nystagmus is intermittent and requires sustained observation over several minutes. Low amplitude nystagmus may only be detected during ophthalmoscopy<sup>5</sup>; note that the direction of horizontal or vertical nystagmus is inverted when viewed through the

See end of article for authors' affiliations

Dr R J Leigh, Department of Neurology, University Hospitals, 11100 Euclid Avenue, Cleveland, Ohio, 44106-5000, USA; [rjl4@po.cwru.edu](mailto:rjl4@po.cwru.edu)



**Figure 1** Schematic representation of common waveforms of nystagmus and saccadic intrusions. (A) Constant velocity drift of the eyes, with corrective quick phases, typical of peripheral or central vestibular disease. (B) Drift of the eyes back from an eccentric orbital position toward the midline (gaze evoked nystagmus). The drift shows a negative exponential time course, with decreasing velocity. This waveform reflects an unsustained eye position signal caused by an impaired gaze holding mechanism. (C) Drift of the eyes away from the central position with a positive exponential time course (increasing velocity). This waveform is encountered in the horizontal plane in congenital nystagmus. (D) Pendular nystagmus, which is encountered as a type of congenital nystagmus and with acquired disease. (E) Square wave jerks—small saccades away from and back to the position of the target, with an intersaccadic interval of about 200 ms. (F) Macrosaccadic oscillations—hypermetric saccades about the position of the fixation, with an intersaccadic interval of about 200 ms. (G) A burst of saccades without an intersaccadic interval (ocular flutter), typically at a frequency of 10–15 cycles per second. Adapted from Leigh and Zee (1999).<sup>2</sup>

ophthalmoscope. Repeat each of these observations as the eyes are brought into right, left, up, and down gaze, and during sustained convergence.

A description of the direction of rotation of the nystagmus in each gaze angle will often indicate the coordinate system to which the nystagmus conforms. Thus, nystagmus that appears horizontal in the straight ahead position of gaze but torsional on looking far up is rotating around a rostral-caudal axis relative to the head, characteristic of vestibular nystagmus. However, if on upward gaze the nystagmus still appears “horizontal” to the observer, then the eye is rotating around an eye fixed axis, characteristic of congenital nystagmus (see video “Congenital\_Nystagmus”).

Always examine the effect on nystagmus of removing fixation; nystagmus attributable to peripheral vestibular imbalance may only be apparent under these circumstances. The best way is to observe the nystagmus behind Frenzel goggles (high positive lenses with small lights), which prevent fixation of objects and also provide the examiner with a magnified, illuminated view of the patient’s eyes. If not available, another technique consists of transiently covering the fixating eye during ophthalmoscopy in an otherwise dark room, and noting the effects on retinal motion in the eye being viewed.<sup>5</sup>

Evaluation of nystagmus is incomplete without a systematic examination of each functional class of eye movements—vestibular, saccades, smooth pursuit, and vergence; selective defects may indicate the nature of the underlying disorder. For example, dissociated nystagmus (greater in the abducting eye) on looking to the right occurs when the adducting left eye cannot be put on target because of an internuclear ophthalmoplegia. It is also important to note the effects of each type of eye movement (such as convergence) on the nystagmus, as

well as a 15 second period of head shaking in the horizontal or vertical planes (observe the nystagmus after head shaking through Frenzel goggles).<sup>2,6</sup> Placing the patient into head hanging positions may increase some forms of nystagmus (for example, downbeat). Nystagmus that is present only when induced by positional testing is a feature of benign paroxysmal positional vertigo, which is discussed elsewhere.<sup>2,7</sup>

It is possible to induce nystagmus in normal subjects with optokinetic or vestibular stimuli. Under natural circumstances, visual (optokinetic) and vestibular nystagmus acts to hold images steadily on the retina during self rotation. In clinical practice, it is convenient to induce nystagmus with an “optokinetic” drum or tape, which presents a moving pattern of stripes. This stimulus mainly tests smooth pursuit tracking (slow phases) and automatic saccades (quick phases). The patient is instructed to follow the stripes as they move either horizontally or vertically. The clinician looks for an asymmetry of responses. For example, with an infarction of right posterior cerebral cortex that affects secondary visual areas concerned with motion processing, the response will be reduced as the stripes move to the patient’s right (impaired ipsilateral smooth pursuit) and less corrective quick phases will be triggered—that is, there will be less nystagmus as the stripes move to the patient’s right compared with moving to the left.

Nystagmus can also be induced with vestibular stimuli.<sup>2,7</sup> A simple method is to rotate, by hand, the patient in an office chair for 45 seconds, then stop the chair so that induced nystagmus can be viewed. Vestibular nystagmus can also be induced by irrigating the external auditory canal with cool or warm water, which produces a convection current in the endolymph of the labyrinth. In clinical practice, the minimal ice water caloric test is most convenient.<sup>2,8</sup> After verifying that the tympanic membrane is intact, the patient’s head is elevated 30 degrees relative to earth horizontal, to place the lateral semicircular canal in a vertical position. Ideally, eye movements should be observed behind Frenzel goggles. A normal response, consisting of a nystagmus beating away from the stimulated ear, can be elicited with as little as 0.2 ml of ice cold water. The caloric test is a sensitive indicator of loss of unilateral vestibular function.

## INTERPRETATION OF FINDINGS

### Nystagmus occurring when the eyes are close to central position

An important first step is to determine whether removing visual fixation increases the nystagmus. Mixed horizontal-torsional jerk nystagmus that suppresses with fixation is usually attributable to a peripheral vestibular imbalance and is accompanied by vertigo (for example, viral labyrinthitis).<sup>2,7</sup> Peripheral vestibular nystagmus (fig 1A) commonly beats away from the side of lesion, and increases when the eyes are turned in the direction of the quick phases (Alexander’s law). Horizontal nystagmus (jerk or pendular) that is accentuated by the visual effort of fixation, as well as by attention or anxiety, is commonly congenital. Congenital nystagmus usually remains horizontal in all gaze angles, may be suppressed during convergence (see video, “Congenital\_Nystagmus”), and is sometimes associated with anomalous head positions, head oscillations and strabismus.<sup>4</sup> A characteristic sign of congenital nystagmus is that during testing with a horizontal optokinetic stimulus, the quick phases may be directed in the same direction as drum motion—“optokinetic inversion.” Horizontal nystagmus that changes direction when the eyes are alternately covered (beating away from the covered eye) is usually “latent nystagmus”, which is associated with lack of normal binocular development (absent stereopsis), and childhood strabismus (see video, “Latent\_Nystagmus”).<sup>4</sup> Latent nystagmus is often manifest when neither eye is occluded, because the patient chooses to fixate with one eye. These congenital variants of nystagmus are usually evident from the

examination and history of lifelong eye problems. However, sometimes it is necessary to record eye movements, because most waveforms of congenital nystagmus are diagnostic, especially increasing velocity waveforms (fig 1C) with superimposed “foveation periods,” when the eyes are momentarily still.<sup>4</sup> The diagnostic significance of these congenital forms of nystagmus to the neurologist are that they usually require no further evaluation. Horizontal nystagmus that regularly reverses direction about every two minutes is periodic alternating nystagmus (PAN); it is associated with disease of the midline cerebellum (nodulus and uvula).<sup>2</sup> To identify this oscillation, which is usually unaffected by visual fixation, an observation of a few minutes is required, and the examiner should also look for periodic alternating head turns that may be associated. A congenital variant of PAN, which is not related with cerebellar disease, usually does not reverse direction at regular intervals.<sup>4</sup>

Vertical jerk nystagmus (downbeat or upbeat), as well as purely torsional jerk nystagmus, with the eye near to central position is usually attributable to a central involvement of the vestibular pathways. Both downbeat and upbeat nystagmus are poorly suppressed by visual fixation and may be exacerbated by simply placing the patient in a head hanging position; they may also be increased, suppressed, or inverted by convergence.<sup>2</sup> Typically downbeat nystagmus is best evoked on looking down and laterally (see video “Downbeat\_Nystagmus”), whereas upbeat nystagmus generally increases on looking up. Downbeat nystagmus is usually encountered with lesions of the vestibulocerebellum, craniocervical anomalies, and drug intoxications; it is also a feature of the calcium channelopathy, episodic ataxia type II.<sup>9</sup> Upbeat nystagmus is less well localised, being mainly reported with lesions in the medulla,<sup>6</sup> or close to the superior cerebellar peduncle (see video “Upbeat\_Nystagmus”).<sup>2</sup> Pure torsional nystagmus with the eye close to central position is uncommon and is usually associated with medullary lesions, such as syringobulbia and lateral medullary infarction (Wallenberg’s syndrome).<sup>2</sup><sup>10</sup> It is often accompanied by ocular tilt reaction or unilateral internuclear ophthalmoplegia.<sup>11</sup>

Acquired pendular nystagmus has a quasi-sinusoidal waveform (fig 1D),<sup>12</sup> and often shows trajectories that are oblique, elliptical, or circular, depending on the size and temporal relation between horizontal and vertical components. Congenital pendular nystagmus is usually horizontal in direction. Acquired pendular nystagmus may be conjugate, disconjugate (dissimilar trajectories of each eye), or dissociated (different size of oscillations in each eye). It occurs most commonly in association with disorders of central myelin, especially multiple sclerosis (see video, “Pendular\_Nystagmus”),<sup>12</sup><sup>13</sup> and after brain stem stroke as part of the syndrome of oculopalatal tremor (“myoclonus”).<sup>2</sup>

Pendular oscillations that are about 180° out of phase in the horizontal plane causes a type of convergent-divergent nystagmus, which occurs in some patients with cerebral Whipple’s disease, sometimes with associated oscillatory movements of the jaw, face, or limbs (oculomasticatory myorhythmia) and vertical gaze palsy.<sup>14</sup> Pendular convergent-divergent nystagmus has also been reported in patients with multiple sclerosis and brain stem stroke.<sup>15</sup> Convergence-divergence nystagmus should be differentiated from conjugate nystagmus that is affected (suppressed, increased, or inverted) by convergence, a feature of a variety of acquired forms of nystagmus (for example, downbeat, upbeat nystagmus). Congenital nystagmus is often suppressed during convergence.<sup>4</sup>

Seesaw nystagmus (pendular or jerk) consists of elevation and intorsion of one eye and synchronous depression and extorsion of the other eye in the first half cycle, followed by change in direction during the next half cycle. To appreciate the seesaw nature of the oscillation, it often helps to look at the bridge of the patient’s nose. Pendular seesaw nystagmus

occurs with disorders that interfere with crossing axons at the optic chiasm and cause bitemporal hemianopia, such as pituitary tumours, as well as a variant of congenital nystagmus (see video “Seesaw\_Nystagmus”).<sup>4</sup> Jerk seesaw nystagmus is reported in patients with lesions in the region of the interstitial nucleus of Cajal.<sup>16</sup>

### Nystagmus induced by moving the eyes to an eccentric position—gaze evoked nystagmus

The commonest form of nystagmus encountered in clinical practice occurs only when the eyes are moved into eccentric gaze, especially in lateral and up gaze (fig 1B). This gaze evoked nystagmus has quick phases that are directed away from central position (see video, “Gaze&Rebound\_Nystagmus”). Holding the eyes in such eccentric positions requires a tonic contraction of the extraocular muscles, which is achieved by a sustained discharge of motoneurons.<sup>17</sup> This ability is impaired by cerebellar and brainstem disorders as well as a number of intoxications.<sup>2</sup> Thus, the finding of nystagmus on lateral or upgaze may be clinically important. Firstly, however, it is important to differentiate between pathological gaze evoked nystagmus and its variant, called end point nystagmus, frequently reported in normal subjects. The latter is usually unsustained, of low frequency and amplitude, and not accompanied by other ocular motor abnormalities. Pathological gaze evoked nystagmus may be attributable to a peripheral process,<sup>2</sup> being a sign of extraocular muscle weakness, for example, in patients with myasthenia gravis (“fatigue nystagmus”). It also occurs as a result of central disorders that involve the gaze holding neural network, which includes the nucleus prepositus hypoglossi and medial vestibular nucleus for horizontal gaze,<sup>17</sup> the interstitial nucleus of Cajal for vertical gaze,<sup>18</sup> and the vestibulocerebellum,<sup>2</sup> which optimises gaze holding. Structural lesions affecting this gaze holding network may cause gaze evoked nystagmus, because the eyes tend to drift back to central position (fig 1B). Most commonly, gaze evoked nystagmus is encountered as a side effect of medications, including sedatives and anticonvulsants, or with drug intoxications (for example, alcohol). When patients with gaze evoked nystagmus attempt to hold eccentric gaze for a number of seconds, and then return their eyes to the central position, a transient rebound nystagmus, with quick phases opposite to the direction of the prior eccentric gaze, may occur (see video “Gaze&Rebound\_Nystagmus”). Such rebound nystagmus is prominent in patients with disease affecting the vestibular cerebellum.<sup>19</sup>

When nystagmus on lateral gaze is greater in the abducting eye, the cause may be internuclear ophthalmoplegia, and saccades should be tested, looking for slowing of the adducting eye. In most cases, dissociated nystagmus is a manifestation of the brain’s attempt, with a series of saccades, to put the fovea of the weak, adducting eye on target.<sup>2</sup> Tumours of the cerebellopontine angle may cause a combination of low frequency, large amplitude horizontal nystagmus looking ipsilaterally, because of defective gaze holding, and a high frequency, small amplitude nystagmus on looking contralaterally because of vestibular imbalance (Bruns’ nystagmus).

One form of nystagmus induced by upgaze is convergence-retraction nystagmus. It occurs with dorsal midbrain lesions (for example, pineal tumours). Convergence-retraction nystagmus may be elicited either by asking the patient to make an upward saccade, or by using a handheld optokinetic drum or tape, moving the stripes down. In some cases the convergent movements appear to be opposed vergence movements,<sup>20</sup> but in others it consists of opposed, asynchronous saccades.<sup>21</sup>

Nystagmus (either jerk or pendular, binocular or monocular) occurs commonly in patients with visual impairment or loss, who cannot accurately direct their gaze. In such patients, both horizontal and vertical components are present, and the

direction of nystagmus fluctuates during a period of observation. Their nystagmus probably reflects an uncalibrated ocular motor system.<sup>22</sup>

### Saccadic intrusions and oscillations

Several types of inappropriate saccadic movements may intrude upon steady fixation; more common variants are schematised in figure 1E–G. Because saccadic intrusions are rapid and brief, it is usually necessary to measure eye and target position and eye velocity to identify accurately the saccadic abnormality.

Square wave jerks (fig 1E) occur in healthy subjects,<sup>23</sup> but are a prominent finding in progressive supranuclear palsy and some spinocerebellar atrophies (especially Friedreich's ataxia).<sup>3</sup> They are small, conjugate saccades, ranging from 0.5 to 5.0 degrees in size, which take the eye away from the fixation position and then return it there after a period of about 200 ms. They may be most evident during smooth pursuit, and are easily detected during ophthalmoscopy.

Macrosaccadic oscillations (fig 1F) usually consist of horizontal saccades that occur in bursts, building up and then decreasing in amplitude, with intersaccadic intervals of about 200 ms.<sup>4</sup> These oscillations are usually induced by a gaze shift. They are a sign of midline cerebellar disease (affecting the fastigial nucleus), including spinocerebellar degenerations (see video, "Macrosaccadic\_oscillations"),<sup>24</sup> but have also been reported with pontine lesions.<sup>25</sup>

Saccadic pulses are brief intrusions that take the eye movement away from the fixation position, with a rapid drift back. They are reported in patients with internuclear ophthalmoplegia.<sup>26</sup> There is a continuum between saccadic pulses and saccadic oscillations without an intersaccadic interval (fig 1G). The latter may occur in the horizontal plane, ocular flutter,<sup>27</sup> or may consist of saccadic oscillations with horizontal, vertical, and torsional components, opsoclonus (see video, "Opsoclonus"). The frequency of oscillations is usually typically 10 to 15 cycles per second, being higher with smaller size movements. Flutter and opsoclonus are often brought out by eye lid closure or during gaze shifts between far and distant targets.<sup>28</sup> Most cases of flutter and opsoclonus conform to four main diagnostic groups: parainfectious brainstem encephalitis (including multiple sclerosis),<sup>27</sup> paraneoplastic syndromes, metabolic-toxic states, or idiopathic. Differentiation between these disorders depends on the general neurological findings and laboratory testing.<sup>29</sup>

### ACKNOWLEDGEMENTS

This research was supported by USPHS grant EY06717, the Office of Research and Development, Medical Research Service, Department of Veterans Affairs, and the Evenor Armington Fund (to R J Leigh).

### Authors' affiliations

**A Serra**, Department of Neurology, Department of Veterans Affairs Medical Center and University Hospitals, Case Western Reserve University, Cleveland, Ohio, USA and Institute of Clinical Neurology-University of Sassari, Sassari, Italy

**R J Leigh**, Departments of Neurology, Biomedical Engineering, and Neuroscience, Department of Veterans Affairs Medical Center and University Hospitals, Case Western Reserve University

### REFERENCES

- Kaminski HJ**, Leigh RJ, eds. The neurobiology of eye movements: from molecules to behavior. *Ann N Y Acad Sci* 2002;**956**:1–615.
- Leigh RJ**, Zee DS. *The neurology of eye movements*, 3rd ed. Book/CD. New York: Oxford University Press, 1999.
- Averbuch-Heller L**, Leigh RJ. Nystagmus and related ocular motility disorders. In: Miller NR, Newman N, eds. *Walsh and Hoyt's clinical neuro-ophthalmology*. 5th edn. Vol 1. Baltimore: Williams and Wilkins, 1998:1461–505.
- Dell'Osso LF**, Daroff RB. Nystagmus and saccadic intrusions and oscillations. In: Glaser JS, ed. *Neuro-ophthalmology*. 3rd edn. Philadelphia: Lippincott, Williams and Wilkins, 1999:369–401.
- Zee DS**. Ophthalmoscopy in examination of patients with vestibular disorders. *Ann Neurol* 1978;**3**:373–4.
- Minigar A**, Sheremata WA, Tusa RJ. Perverted head shaking nystagmus: a possible mechanism. *Neurology* 2001;**57**: 887–9.
- Halmagyi GM**, Cremer PD. Assessment and treatment of dizziness. *J Neurol Neurosurg Psychiatry* 2000;**68**:129–34.
- Nelson JR**. The minimal ice water caloric test. *Neurology* 1969;**19**:577–85.
- Baloh RW**, Jen JC. Genetics of familial episodic vertigo and ataxia. In: Kaminski HJ, Leigh RJ, eds. The neurobiology of eye movements: from molecules to behavior. *Ann N Y Acad Sci* 2002;**956**:338–45.
- Morrow MJ**, Sharpe JA. Torsional nystagmus in the lateral medullary syndrome. *Ann Neurol* 1988;**24**:390–8.
- Averbuch-Heller L**, Rottach KG, Zivotofsky AZ, et al. Torsional eye movements in patients with skew deviation and spasmodic torticollis: responses to static and dynamic head roll. *Neurology* 1997;**48**:506–14.
- Averbuch-Heller L**, Zivotofsky AZ, Das VE, et al. Investigations of the pathogenesis of acquired pendular nystagmus. *Brain* 1995;**118**:369–78.
- Das VE**, Oruganti P, Kramer PD, et al. Experimental tests of a neural-network model for ocular oscillations caused by disease of central myelin. *Exp Brain Res* 2000;**133**:189–97.
- Schwartz MA**, Selhorst JB, Ochs AL, et al. Oculomotor myorhythmia: a unique movement disorder occurring in Whipple's disease. *Ann Neurol* 1986;**20**:677–83.
- Averbuch-Heller L**, Zivotofsky AZ, Remler BF, et al. Convergent-divergent pendular nystagmus: possible role of the vergence system. *Neurology* 1995;**45**:509–15.
- Halmagyi GM**, Aw ST, Dehaene I, et al. Jerk-waveform see-saw nystagmus due to unilateral meso-diencephalic lesion. *Brain* 1994;**117**:775–88.
- Arnold DB**, Robinson DA. The oculomotor integrator: testing of a neural network model. *Exp Brain Res* 1997;**113**:57–74.
- Helmchen C**, Rambold H, Fuhry L, et al. Deficits in vertical and torsional eye movements after uni- and bilateral muscimol inactivation of the interstitial nucleus of Cajal of the alert monkey. *Exp Brain Res* 1998;**119**:436–52.
- Bondar RL**, Sharpe JA, Lewis AJ. Rebound nystagmus in olivocerebellar atrophy: a clinicopathological correlation. *Ann Neurol* 1984;**15**:474–7.
- Rambold H**, Kompf D, Helmchen C. Convergence retraction nystagmus: a disorder of vergence? *Ann Neurol* 2001;**50**: 677–81.
- Ochs AL**, Stark L, Hoyt WF, et al. Opposed adducting saccades in convergence-retraction nystagmus. A patient with sylvian aqueduct syndrome. *Brain* 1979;**102**:479–508.
- Leigh RJ**, Thurston SE, Tomsak RL, et al. Effect of monocular visual loss upon stability of fixation. *Invest Ophthalmol Vis Sci* 1989; **30**:288–92.
- Shallo-Hoffmann J**, Sandler B, Mühlendyck H. Normal square wave jerks in differing age groups. *Invest Ophthalmol Vis Sci* 1990;**31**:1649–52.
- Swartz BE**, Burmeister M, Somers JT, et al. A form of inherited cerebellar ataxia with saccadic intrusions, increase saccadic speed, sensory neuropathy and myoclonus. In: Kaminski HJ, Leigh RJ, eds. The neurobiology of eye movements: from molecules to behavior. *Ann N Y Acad Sci* 2002;**956**:441–4.
- Averbuch-Heller L**, Kori AA, Rottach KG, et al. Dysfunction of pontine omnipause neurons causes impaired fixation: macrosaccadic oscillations with a unilateral pontine lesion. *Neuro-ophthalmology* 1996;**16**:99–106.
- Herishanu YO**, Sharpe JA. Saccadic intrusions in internuclear ophthalmoplegia. *Ann Neurol* 1983;**14**:67–72.
- Schon F**, Hodgson TL, Mori D, et al. Ocular flutter associated with a localized lesion in the paramedian pontine reticular formation. *Ann Neurol* 2001;**50**:413–16.
- Bhidayasiri R**, Somers JT, Kim J-I, et al. Ocular oscillations induced by shifts of the direction and depth of fixation. *Ann Neurol* 2001;**49**:24–8.
- Bataller L**, Graus F, Saiz A, et al. Clinical outcome in adult onset idiopathic or paraneoplastic opsoclonus-myoclonus. *Brain* 2000;**124**:437–43.