

# Journal of Neurology Neurosurgery and Psychiatry

## Editor

Professor C Kennard

## Deputy Editor

Dr G D Perkin

## Associate Editors

Dr L Caplan  
Dr S Fleming  
Professor I R Whittle

## Web Editor

R Al-Shahi (UK)

## Editorial board

M P Barnes (UK)  
Y Ben-Shlomo (UK)  
S F Berkovic (Australia)  
I Bone (UK)  
M-G Bousser (France)  
T Brandt (Germany)  
D J Brooks (UK)  
M C Dalakas (USA)  
M Donaghy (UK)  
J S Duncan (UK)  
M Filippi (Italy)  
P J Goadsby (UK)  
M Husain (UK)  
P J Kirkpatrick (UK)  
S Love (UK)  
S Lovestone (UK)  
H Markus (UK)  
R Maurice-Williams (UK)  
T M McMillan (UK)  
K Mills (UK)  
I F Moseley (UK)  
AHV Schapira (UK)  
A Thompson (UK)  
E Tolosa (Spain)  
J Wardlaw (UK)  
J H J Wokke (The Netherlands)  
N W Wood (UK)  
Editor, *BMJ*

## Editorial assistants

A L Kirk  
E Ioannou

## Technical editor

M Dodd

## Instructions to authors

Full instructions are available online at [www.jnnp.com/misc/ifora.shtml](http://www.jnnp.com/misc/ifora.shtml)

If you do not have web access please contact the editorial office:

Journal of Neuroscience and Psychological Medicine  
Division of Neuroscience and Psychological Medicine  
Room 10E 15, Imperial College School of Medicine  
Charing Cross Hospital  
Fulham Palace Road  
London W6 8RF, UK  
Telephone +44 (0)20 8846 1213  
Fax +44 (0)20 8846 7730  
Email: [editor.jnnp@ic.ac.uk](mailto:editor.jnnp@ic.ac.uk)

## Subscription information

See page iv

## Copyright

© 2003 *BMJ Publishing Group*. All rights reserved; no part of this publication may be reproduced, stored in a retrieval system, or transmitted in any form or by any means, electronic, mechanical, photocopying, recording, or otherwise without the prior permission of the *BMJ Publishing Group*.

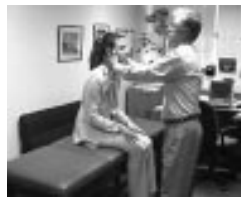
Authors are required to grant the *BMJ Publishing Group* an exclusive licence to publish; further details available online at [www.jnnp.com/misc/ifora.shtml](http://www.jnnp.com/misc/ifora.shtml)

• *Journal of Neurology Neurosurgery and Psychiatry* is published by *BMJ Publishing Group* and printed in UK on acid free paper by Thanet Press Limited, Margate, Kent

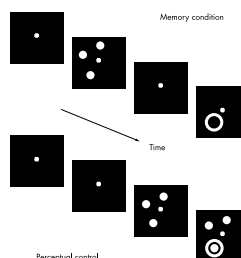
• Periodicals postage paid, Rahway, NJ. Postmaster: send address changes to: *Journal of Neurology Neurosurgery and Psychiatry*, c/o Mercury Airfreight International Ltd, 365 Blair Road, Avenel, NJ 07001, USA

## contents JNNP

Volume 74 Number 3 March 2003



See p 289



See p326



[www.publicationethics.org.uk](http://www.publicationethics.org.uk)

This journal is a member of and subscribes to the principles of the Committee on Publication Ethics

## Editorial

285 Letter from Cuba A J Wills, F R Miyares

## Editorial Commentaries

286 Vigabatrin, tiagabine, and visual fields  
MC Lawden

287 Objective measures for the progression of  
Parkinson's disease B Snow

288 Quality of life in motor neurone  
disease—towards a more practical assessment  
tool? J D Mitchell, M R O'Brien

## Review

289 Vestibular reflexes and positional manoeuvres  
A M Bronstein

## Papers

294 [<sup>123</sup>I] β-CIT SPECT is a useful method for  
monitoring dopaminergic degeneration in  
early stage Parkinson's disease  
A Winogrodzka, P Bergmans, J Booij,  
E A van Royen, J C Stoof, E C Walters

299 Discrete and dynamic scaling of the size of  
continuous graphic movements of  
parkinsonian patients and elderly controls  
M G Longstaff, P R Mahant, M A Stacy,  
A W A Van Gemmert, B C Leis, G E Stelmach

305 Neuropsychological and quality of life  
outcomes 12 months after unilateral thalamic  
stimulation for essential tremor J A Fields,  
A I Tröster, S P Woods, C I Higginson,  
S B Wilkinson, K E Lyons, W C Koller,  
R Pahwa

312 Raised plasma oxidised LDL in acute cerebral  
infarction M Uno, K T Kitazato, K Nishi,  
H Itabe, S Nagahiro

317 Incidence, risk, and case fatality of first ever  
stroke in the elderly population. The Rotterdam  
Study M Hollander, P J Koudstaal, M L Bots,  
D E Grobbee, A Hofman, M M B Breteler

322 S100B as a surrogate marker for successful  
clot lysis in hyperacute middle cerebral artery  
occlusion C Foerch, R du Mesnil de  
Rochemont, O Singer, T Neumann-Haefelin,  
M Buchkremer, F E Zanella, H Steinmetz,  
M Sitzer

326 A study of persistent post-concussion symptoms  
in mild head trauma using positron emission  
tomography S H A Chen, D A Kareken,  
P S Fastenau, L E Trexler, G D Hutchins

333 Second harmonic imaging: a new ultrasound  
technique to assess human brain tumour  
perfusion J U Harrer, L Mayfrank, M Mull,  
C Klötzsch

339 A controlled study comparing visual function in  
patients treated with vigabatrin and tiagabine  
G L Krauss, M A Johnson, S Sheth, N R Miller

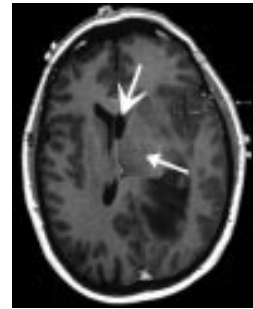
344 Hypothesis on the pathophysiology of  
syringomyelia based on simulation of  
cerebrospinal fluid dynamics H S Chang,  
H Nakagawa

- 348 Agreement among neurologists on the clinical diagnosis of dystonia at different body sites  
*G Logroscino, P Livrea, D Anaclerio, M S Aniello, G Benedetto, G Cazzato, L Giampietro, G Manobianca, M Marra, D Martino, P Pannarale, R Pulimeno, V Santamato, G Defazio*
- 351 Diagnostic criteria and the use of ICD-10 codes to define and classify minor head injury  
*J Bellner, S-M Jensen, J Lexell, B Romner*
- 353 Central pontine myelinolysis associated with hypokalaemia in anorexia nervosa  
*T Sugimoto, T Murata, M Omori, Y Wada*
- 356 Eyelid tremor in a patient with a unilateral paramedian thalamic lesion  
*G J Jungehülsing, C J Ploner*
- 359 Is neurocysticercosis a risk factor in coexistent intracranial disease? An MRI based study  
*R Azad, R K Gupta, S Kumar, C M Pandey, K N Prasad, N Husain, M Husain*
- 362 Saitohin gene is not associated with Alzheimer's disease  
*J R Streffer, A Papassotiropoulos, P Kurosinski, A Signorell, M A Wollmer, M Tsolaki, V Iakovidou, F Hörndli, J Bosset, J Götz, R M Nitsch, C Hock*
- 364 A case of gliosarcoma appearing as ischaemic stroke  
*S Züchner, W Kawohl, B Sellhaus, M Mull, L Mayfrank, C M Kosinski*
- 367 Seizures arising from the inferior parietal lobe can show ictal semiology of the second sensory seizure (SII seizure)  
*J Yamamoto, A Ikeda, M Matsushashi, T Satow, M Takayama, S Ohara, R Matsumoto, N Mikuni, J Takahashi, S Miyamoto, W Taki, N Hashimoto, H Shibasaki*
- 370 Endplate dysfunction causing respiratory failure in a patient with prior paralytic poliomyelitis  
*A Truffert, P H Lalive, J P Janssens, M Sinnreich, M R Magistris*
- 373 Improvement of central motor conduction after bone marrow transplantation in adrenoleukodystrophy  
*T Hitomi, T Mezaki, T Tsujii, M Kinoshita, H Tomimoto, A Ikeda, S Shimohama, T Okazaki, T Uchiyama, H Shibasaki*
- 376 Decision making in humans: the effect of manipulating the central noradrenergic system  
*R E O'Carroll, B P Papp*
- 379 Repetitive stimulation of the long thoracic nerve in myasthenia gravis: clinical and electrophysiological correlations  
*Y L Lo, T H Leoh, Y F Dan, Y E Tan, S Nurjannah, P Ratnagopal*
- 382 Diffusion weighted imaging in radiation necrosis  
*V Biousse, N J Newman, S B Hunter, P A Hudgins*

- 385 Neuroleptic malignant syndrome in Kufs' disease  
*A Reif, M F Schneider, A Hoyer, C Schneider-Gold, A J Fallgatter, W Roggendorf, B Pfuhlmann*

Letters

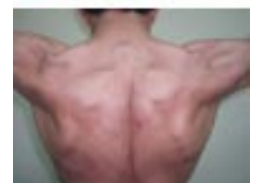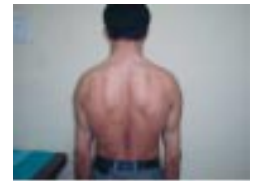- 388 Acute rotatory vertigo caused by a small haemorrhage of the vestibular cortex  
*J Boiten, J Wilmsink, H Kingma*
- 389 Coexistent Lewy body disease in a case of "visual variant of Alzheimer's disease"  
*D F Tang-Wai, K A Josephs, B F Boeve, R C Petersen, J E Parisi, D W Dickson*
- 389 Reversible callosal disconnection syndrome in internal hydrocephalus  
*T Nyffeler, R Bühler, P Höllinger, C W Hess*
- 391 Trigeminal autonomic cephalalgia-tic-like syndrome associated with a pontine tumour in a one year old girl  
*J A van Vliet, M D Ferrari, J Haan, L A E M Laan, JHC Voormolen*
- 392 Autoimmune myasthenia gravis after cardiac surgery  
*C Scoppetta, P Onorati, F Eusebi, C Scoppetta, P Onorati, F Eusebi, M Fini, A Evoli, A Vincent*
- 393 Chiari I malformation mimicking myasthenia gravis  
*C Rodolico, P Girlanda, C Nicolosi, G Vita, M Bonsignore, G Tortorella*
- 393 Expanding cerebral cysts (lacunae): a treatable cause of progressive midbrain syndrome  
*P L Longatti, A Fiorindi, A Carteri, F Caroli, A Martinuzzi*



See p333

Correspondence

- 395 Conflict and integration of spatial attention between disconnected hemispheres  
*I Derakhshan. Reply by S Ishiai, Y Koyama, T Furuya*



See p338

- 396 Book reviews

- 397 Proceedings

Neuroline

- 288 Harvard Whole Brain Atlas:  
[www.med.harvard.edu/AANLIB/home.html](http://www.med.harvard.edu/AANLIB/home.html)  
*D Summers*

Neurological picture

- 338 Muscle hypertrophy in myotonia congenita  
*B Varkey, L Varkey*

Neurological stamp

- 343 Allvar Gullstrand (1862–1930)  
*L F Haas*

Historical note

- 384 Neurofibromatosis  
*J M S Pearce*