

Journal of Neurology Neurosurgery and Psychiatry

Editor

Professor C Kennard

Deputy Editor

Dr G D Perkin

Associate Editors

Dr L Caplan
Dr S Fleming
Professor I R Whittle

Web Editor

R Al-Shahi (UK)

Editorial board

M P Barnes (UK)
Y Ben-Shlomo (UK)
S F Berkovic (Australia)
I Bone (UK)
M-G Bousser (France)
T Brandt (Germany)
D J Brooks (UK)
M C Dalakas (USA)
M Donaghy (UK)
J S Duncan (UK)
M Filippi (Italy)
P J Goadsby (UK)
M Husain (UK)
P J Kirkpatrick (UK)
S Love (UK)
S Lovestone (UK)
H Markus (UK)
R Maurice-Williams (UK)
T M McMillan (UK)
K Mills (UK)
I F Moseley (UK)
AHV Schapira (UK)
A Thompson (UK)
E Tolosa (Spain)
J Wardlaw (UK)
J H J Wokke (The Netherlands)
N W Wood (UK)
Editor, *BMJ*

Editorial assistants

A L Kirk
S Taylor

Technical editor

M Dodd

Instructions to authors

Full instructions are available online at www.jnnp.com/misc/ifora.shtml

If you do not have web access please contact the editorial office:
Journal of Neurology, Neurosurgery & Psychiatry
Division of Neuroscience and Psychological Medicine
Room 10E 15, Imperial College London
Charing Cross Hospital
Fulham Palace Road
London W6 8RF, UK
Telephone +44 (0)20 8846 1213
Fax +44 (0)20 8846 7730
Email: editor.jnnp@imperial.ac.uk

Subscription information

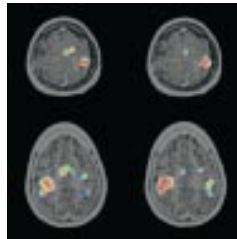

See page iv

Copyright

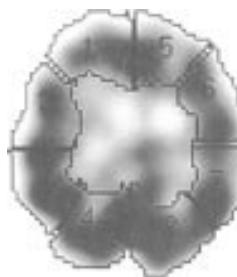© 2003 *BMJ Publishing Group*. All rights reserved; no part of this publication may be reproduced, stored in a retrieval system, or transmitted in any form or by any means, electronic, mechanical, photocopying, recording, or otherwise without the prior permission of the *BMJ Publishing Group*.

Authors are required to grant the *BMJ Publishing Group* an exclusive licence to publish; further details available online at www.jnnp.com/misc/ifora.shtml

- *Journal of Neurology Neurosurgery and Psychiatry* is published by *BMJ Publishing Group* and printed in UK on acid free paper by Thanet Press Limited, Margate, Kent
- Periodicals postage paid, Rahway, NJ. Postmaster: send address changes to: *Journal of Neurology Neurosurgery and Psychiatry*, c/o Mercury Airfreight International Ltd, 365 Blair Road, Avenel, NJ 07001, USA



See p471



See p479



www.publicationethics.org.uk

This journal is a member of and subscribes to the principles of the Committee on Publication Ethics

contents JNNP

Volume 74 Number 4 April 2003

Editorial

- 411 Stroke care: the way forward *T W J Watson, J E Simon, A M Buchan*

Editorial commentaries

- 413 Visible infarction on CT after stroke—what does it tell? *R Kay, A C F Hui*
413 Current research on diagnosing dementia *J Warner*

Review

- 415 False localising signs *A J Larner*

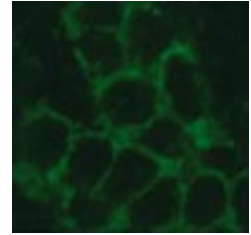
Papers

- 419 Occipital hypoperfusion in Parkinson's disease without dementia: correlation to impaired cortical visual processing *Y Abe, T Kachi, T Kato, Y Arahata, T Yamada, Y Washimi, K Iwai, K Ito, N Yanagisawa, G Sobue*
- 423 Onset age and severity of motor impairment are associated with reduction of myocardial ¹²³I-MIBG uptake in Parkinson's disease *K Hamada, M Hirayama, H Watanabe, R Kobayashi, H Ito, T Ieda, Y Koike, G Sobue*
- 427 Limb length and dementia in an older Korean population *J-M Kim, R Stewart, I-S Shin, J-S Yoon*
- 433 Neuropsychological prediction of conversion to dementia from questionable dementia: statistically significant but not yet clinically useful *J Tian, R S Bucks, J Haworth, G Wilcock*
- 439 One year changes in disability in multiple sclerosis: neurological examination compared with patient self report *E L J Hoogervorst, M J Eikelenboom, B M J Uitdehaag, C H Polman*
- 443 Cognitive impairment in probable multiple sclerosis *A Achiron, Y Barak*
- 447 Reliability of the variables in a new set of models that predict outcome after stroke *N U Weir, C E Counsell, M McDowall, A Gunkel, M S Dennis*
- 452 Visible infarction on computed tomography is an independent predictor of poor functional outcome after stroke, and not of haemorrhagic transformation *J M Wardlaw, T M West, P A G Sandercock, S C Lewis, O Mielke for The International Stroke Trials Collaborative Group*
- 459 Recanalisation of cerebral venous thrombosis *R W Baumgartner, A Studer, M Arnold, D Georgiadis*
- 462 Specific phobia is a frequent non-motor feature in stiff man syndrome *P Henningsen, H-M Meinck*
- 466 Clinical application of neuroimaging in epilepsy *U C Wiesmann*
- 471 Preoperative motor system brain mapping using positron emission tomography and statistical parametric mapping: hints on cortical reorganisation *P T Meyer, L Sturz, O Sabri, M Schreckenberger, U Spetzger, K S Setani, H-J Kaiser, U Buell*
- 479 Is a combination of Tc-SPECT or perfusion weighted magnetic resonance imaging with spinal tap test helpful in the diagnosis of normal pressure hydrocephalus? *F Hertel, C Walter, M Schmitt, M Mörsdorf, W Jammers, H P Busch, M Bettag*
- 485 Treatment of IgM antibody associated polyneuropathies using rituximab *A Pestronk, J Florence, T Miller, R Choksi, M T Al-Lozi, T D Levine*
- 490 Neuromuscular and sensory disturbances in patients with well treated coeliac disease *L Luostarinen, S-L Himanen, M Luostarinen, P Collin, T Pirttilä*

Short reports

- 495 β endorphin concentrations in PBMC of patients with different clinical phenotypes of multiple sclerosis *M Gironi, R Furlan, M Rovaris, G Comi, M Filippi, A E Panerai, P Sacerdote*
- 498 Motor evoked potentials from the pelvic floor in patients with multiple sclerosis *S Brostrom, J L Frederiksen, P Jennum, G Lose*
- 501 A diffusion tensor magnetic resonance imaging study of brain tissue from patients with migraine *M A Rocca, B Colombo, M Inglesse, M Codella, G Comi, M Filippi*
- 504 Thyrotoxic autoimmune encephalopathy: a repeat positron emission tomography study *S W Seo, B I Lee, J D Lee, S A Park, K S Kim, S H Kim, M J Yun*
- 507 Paraneoplastic ophthalmoplegia and subacute motor axonal neuropathy associated with anti-GQ1b antibodies in a patient with malignant melanoma *L Kloos, P Sillevs Smitt, C W Ang, W Kruit, G Stoter*
- 510 Middle cerebral artery territory infarction sparing the precentral gyrus: report of three cases *C Portera-Cailliau, C P Doherty, F S Buonanno, S K Feske*
- 513 Effects of decompressive craniectomy on brain tissue oxygen in patients with intracranial hypertension *M Jaeger, M Soehle, J Meixensberger*
- 516 American trypanosomiasis (Chagas' disease): an unrecognized cause of stroke *F J Carod-Artal, A P Vargas, M Melo, T A Horan*
- 519 Surgery for Parkinson's disease: lack of reliable clinical trial evidence *R L Stowe, K Wheatley, C E Clarke, N J Ives, R K Hills, A C Williams, J P Daniels, R Gray*
- 522 High concentrations of procollagen propeptides in chronic subdural haematoma and effusion *J Sajanti, K Majamaa*
- 525 Ictal magnetoencephalographic discharges from elementary visual hallucinations of status epilepticus *M Oishi, H Otsubo, S Kameyama, M Wachi, K Tanaka, H Masuda, R Tanaka*
- 528 Adult onset Niemann-Pick disease type C presenting with psychosis *K A Josephs, M W Van Gerpen, J A Van Gerpen*
- 530 Interlocking finger test: a bedside screen for parietal lobe dysfunction *L R Moo, S D Slotnick, M A Tesoro, D S Zee, J Hart*
- 533 Measurement of pulse pressure profiles in patients with trigeminal neuralgia *C L Turner, N Mendoza, R D Illingworth, P J Kirkpatrick*
- 536 Brain cysts associated with mutation in the Aristaless related homeobox gene, ARX *P Strømme, S J Bakke, A Dahl, J Géczy*

- 539 Sudden bilateral simultaneous deafness with vertigo as a sole manifestation of verteobasilar insufficiency *H Lee, H A Yi, R W Baloh*
- 542 The natural course of Sneddon syndrome: clinical and magnetic resonance imaging findings in a prospective six year observation study *S M Boesch, A L Plöner, A J Auer, W Poewe, F T Aichner, S R Felber, N T Sepp*



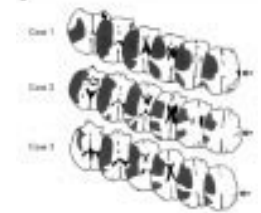
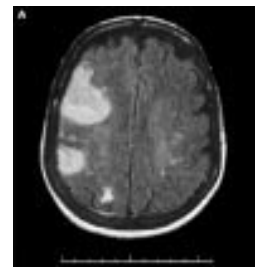
See p507

Letters

- 545 Effect of deprivation on time to hospital in acute stroke *M R Macleod, S C Lewis, M S Dennis*
- 546 Paraoxonase 1 promoter and coding region polymorphisms in Parkinson's disease *S N Kelada, P Costa-Mallen, H Checkoway, H A Viernes, F M Farin, T Smith-Weller, G M Franklin, L G Costa, H Checkoway, W T Longstreth Jr, C E Furlong, G P Jarvik, P D Swanson*
- 547 Multifocal myoclonus secondary to tranexamic acid *A C F Hui, T Y H Wong, K M Chow, C C Szeto*
- 547 Immunohistochemical study of caveolin-3 in idiopathic hyperCKaemia *M Capasso, S Lupo, A Di Muzio, A Uncini, S Servidei*

Correspondence

- 549 Benefit of folic acid supplementation in parkinsonian patients treated with levodopa *T Müller, D Woitalla, W Kuhn*
- 549 Dysphagia due to Chiari I malformation mimicking ALS *J Gamez, E Santamarina, A Codina. Reply: M Paulig*
- 550 High dose intravenous immune globulin in the treatment of hereditary recurrent brachial plexus neuropathy *G Ardolino, S Barbieri, A Priori. Reply: C J Klein, P J B Dyck, P J Dyck*



See p510

- 551 Book reviews

Neurological Picture

- 418 Intracranial hypertension secondary to giant arachnoid granulations *A Arjona, F Delgado, E Fernandez-Romero*

Historical note

- 432 A note on Hoover's sign *J M S Pearce*

Neuronline

- 484 Amoebaweb: www.vanguard.edu/faculty/ddegelman/amoebaweb Classics in the History of Psychology: <http://psychclassics.yorku.ca> *J Stone*

Neurological stamp

- 515 Fridtjof Nansen (1861–1930) *L F Haas*