

## SHORT REPORT

# Reversible acute axonal polyneuropathy associated with Wernicke-Korsakoff syndrome: impaired physiological nerve conduction due to thiamine deficiency?

S Ishibashi, T Yokota, T Shiojiri, T Matunaga, H Tanaka, K Nishina, H Hirota, A Inaba, M Yamada, T Kanda, H Mizusawa

*J Neurol Neurosurg Psychiatry* 2003;**74**:674–676

Acute axonal polyneuropathy and Wernicke-Korsakoff encephalopathy developed simultaneously in three patients. Nerve conduction studies (NCS) detected markedly decreased compound muscle action potentials (CMAPs) and sensory nerve action potentials (SNAPs) with minimal conduction slowing; sympathetic skin responses (SSRs) were also notably decreased. Sural nerve biopsies showed only mild axonal degeneration with scattered myelin ovoid formation. The symptoms of neuropathy lessened within two weeks after an intravenous thiamine infusion. CMAPs, SNAPs, and SSRs also increased considerably. We suggest that this is a new type of peripheral nerve impairment: physiological conduction failure with minimal conduction delay due to thiamine deficiency.

Phosphorylated thiamine, thiamine pyrophosphate (TPP), is an essential coenzyme in both the glycolytic and pentose phosphate pathways of glucose metabolism. Heavy alcohol consumption, extremely poor nutrition, hyperemesis gravidarum, post-gastrectomy, and total parenteral nutrition (TPN) are possible causes of thiamine deficiency which, in turn, gives rise to a wide variety of manifestations that include Wernicke-Korsakoff encephalopathy, peripheral neuropathy, heart failure, and lactic acidosis. A previous study described thiamine deficiency induced polyneuropathy as chronic axonal degeneration.<sup>1</sup> Cases of acute polyneuropathy associated with Wernicke-Korsakoff encephalopathy, however, have recently been reported.<sup>2,3</sup> We also treated three patients with acute axonal polyneuropathy and Wernicke-Korsakoff encephalopathy, whose neuropathic symptoms rapidly improved. We discuss the mechanism of this axonal dysfunction.

## CASE 1

A 41 year old man visited an outpatient psychiatry clinic because of depression. His diet had been unbalanced for a long time, and he had experienced nausea and vomiting due to acute gastritis. The next day he suffered muscle weakness and dysesthesia in his lower extremities. He rapidly developed double vision and could no longer stand because of severe muscle weakness in his lower extremities. Physical examination showed tachycardia and mild oedema in both lower extremities; neurological examination detected drowsiness, ophthalmoplegia, gaze evoked nystagmus, and distal predominant severe muscle weakness and sensory disturbances of the extremities with decreased deep tendon reflexes. Laboratory investigations found a decreased erythrocyte thiamine concentration of 6 µg/ml (normal 20–72 µg/ml) with lactic acidosis. Cerebrospinal fluid (CSF) was normal. Brain magnetic

resonance imaging (MRI) showed a marked signal intensity increase in the periaqueductal grey matter and mammillary bodies on the T2 weighted image. The initial nerve conduction study (NCS) showed markedly decreased amplitudes for compound muscle action potentials (CMAPs) and sensory nerve action potentials (SNAPs) in all four extremities (table 1). Motor and sensory nerve conduction velocities (NCVs) were normal. Sympathetic skin response (SSR) amplitudes were “no response”. The next day, CMAP and SNAP amplitudes showed further decreases. Several positive sharp waves (PSWs) were present on a needle electromyogram (EMG), but large, long duration motor unit potentials were rare. A sural nerve biopsy found evidence of only mild axonal degeneration with scattered myelin ovoids. Myelinated nerve fibre density was mildly decreased at 5982 fibres/mm<sup>2</sup> (normal 8270 ± 374<sup>4</sup>). Electron microscopy showed a normal density for unmyelinated axons. The clinical manifestations rapidly lessened in response to a daily intravenous infusion of 100 mg thiamine for one month, and his neurological disability score (NDS)<sup>5</sup> was also improved (table 1). The amplitudes of CMAP, SNAP, and SSR had almost returned to normal by hospital day 30 (fig 1).

## CASE 2

A 44 year old single man with a history of gastric ulcer had taken 100 ml of alcohol a day over 20 years. He stayed in bed because of common cold-like symptoms, and two days later was discovered unconscious. Neurological examination revealed drowsiness, gaze evoked nystagmus, and severe distal predominant muscle weakness in the extremities with decreased deep tendon reflexes. Laboratory investigations detected normocytic normochromic anaemia. Brain MRI showed a high signal intensity area on the T2 weighted image: around the cerebral aqueduct, around the third ventricle, and in the dorsomedial nucleus of the thalamus. NCS detected a marked decrease in the CMAP and SNAP amplitudes in all four extremities (table 1). SSR amplitudes were “no response”. On hospital day 14, numerous PSWs were present on a needle EMG, but large, long duration motor unit potentials were rare. A sural nerve biopsy showed moderate loss of myelinated fibres with scattered myelin ovoids. Myelinated fibre density was 3341 fibres/mm<sup>2</sup>. The clinical manifestations

**Abbreviations:** AMAN, acute motor axonal neuropathy; CMAP, compound muscle action potential; CSF, cerebrospinal fluid; EMG, electromyogram; GBS, Guillain-Barré syndrome; MRI, magnetic resonance imaging; NCS, nerve conduction study; NCV, nerve conduction velocity; NDS, neurological disability score; PDH, pyruvate dehydrogenase; PSW, positive sharp wave; SNAP, sensory nerve action potential; SSR, sympathetic skin response; TPN, total parenteral nutrition; TPP, thiamine pyrophosphate

**Table 1** Time course of nerve conduction and neurologic disability score

	Patient 1			Patient 2		Patient 3		Normal limit
	1*	2*	30*	1*	30*	1*	14*	
Median nerve CMAP								
DL (ms)	3.55	3.55	3.65	<b>3.95</b>	3.65	3.30	3.75	<3.8
NCV (m/s)	54.7	57.8	56.2	54.7	58.5	60.6	56.3	>54.3
Amp (mV)	6.0/5.7	<b>4.0/3.9</b>	10.6/10.4	<b>4.1/3.6</b>	10.4/9.8	13.5/12.1	27.0/25.9	>5.4
Tibialis nerve CMAP								
DL (ms)	3.75	3.75	3.85	4.60	4.60	4.00	4.50	<4.7
NCV (m/s)	51.9	48.9	48.8	41.5	43.5	51.0	50.7	>40.0
Amp (mV)	<b>5.4/5.0</b>	<b>2.6/2.1</b>	7.3/6.2	<b>2.7/2.4</b>	6.2/6.0	11.4/10.8	19.5/14.8	>5.8
Median nerve SNAP								
NCV (m/s)	55.8/60.3	57.9/57.2	60.3/60.1	43.4/42.5	46.4/47.4	55.6/63.3	55.6/59.6	>40.6
Amp ( $\mu$ V)	<b>14/13</b>	<b>8/6</b>	31/18	<b>6/5</b>	19/16	68/56	101/66	>16
Sural nerve SNAP								
NCV (m/s)	42.5	<b>NR</b>	45.5	<b>NR</b>	45.5	59.1	54.5	>40.6
Amp ( $\mu$ V)	<b>1.7</b>	<b>NR</b>	7.0	<b>NR</b>	6.4	11.3	29.2	>6.3
NDS	<b>60</b>	<b>64</b>	<b>8</b>	<b>72</b>	<b>10</b>	<b>24</b>	<b>2</b>	<2

Values in bold type are abnormal results. \*Hospital day.

NR, no response; CMAP, compound motor action potential; DL, distal latency; NCV, nerve conduction velocity; Amp, amplitude (peak-to-peak); SNAP, sensory nerve action potential; NDS, neurologic disability score.

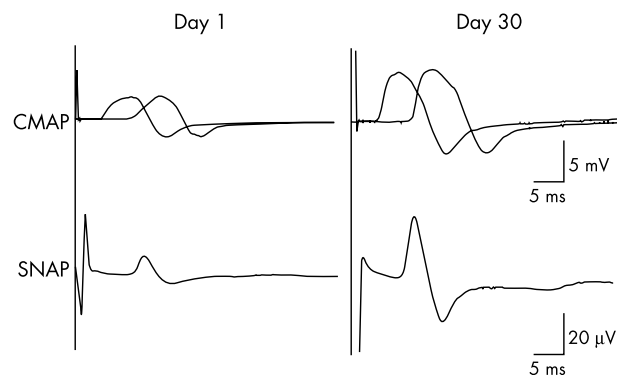
The skin temperature was kept above 32°C. Median nerve CMAPs and SNAPs were recorded with stimulus sites at the wrist and the elbow.

Tibialis nerve CMAPs were recorded at the ankle and the knee.

and NDS rapidly lessened in response to a daily intravenous infusion of 100 mg thiamine. Two months later the patient could walk with assistance due to improvement of distal predominant muscle weakness. By hospital day 30, the amplitudes on the CMAP, SNAP, and SSR were almost normal.

### CASE 3

A 58 year old single man with a history of subtotal gastrectomy for gastric cancer had experienced slight dysesthesia in both lower extremities. Three weeks later he vomited frequently and rapidly developed double vision and gait impairment. Neurological examination revealed ophthalmoplegia, gaze evoked nystagmus, mildly weak muscle strength in the lower extremities with decreased ankle tendon reflexes, and distal predominant sensory disturbances. Laboratory investigations found a decreased erythrocyte thiamine content of 8  $\mu$ g/ml. Brain MRI showed a high signal intensity area on the T2 weighted image around the periaqueduct. NCS was in the normal range, and a sural nerve biopsy was not evaluated. His NDS rapidly lessened in response to a daily intravenous infusion of 100 mg thiamine. Two weeks later the CMAP and SNAP amplitudes showed further increases (table 1).



**Figure 1** CMAPs and SNAPs of the median nerve before and after intravenous thiamine infusion (patient 1). Note rapid increase in CMAP and SNAP amplitudes.

### DISCUSSION

Such manifestations of chronic axonal polyneuropathy, as distal dominant sensory disturbances, decreased muscle strength, or decreased deep tendon reflexes in the extremities, complicate approximately 80% of the known cases of Wernicke-Korsakoff encephalopathy (psychosis polyneuritica). The central nervous system is considered more likely to be affected when the thiamine deficiency is severe and abrupt, whereas the peripheral nerves are usually disturbed by a long term thiamine deficiency,<sup>6</sup> but cases of Wernicke-Korsakoff encephalopathy and acute polyneuropathy due to thiamine deficiency after gastroplasty have been reported.<sup>2,3</sup> Since all the patients presented with vomiting after gastroplasty, it is suggested that a further thiamine deficiency caused by vomiting, in addition to chronic thiamine absorption disturbance, might trigger Wernicke-Korsakoff encephalopathy and/or acute polyneuropathy. Our patients may have developed acute axonal polyneuropathy and Wernicke-Korsakoff encephalopathy simultaneously due to a rapid thiamine deficiency caused by vomiting and fasting, as well as a state of chronic thiamine deficiency.

Ten cases of acute alcoholic axonal polyneuropathy, induced by the direct neurotoxic effect of ethanol or its metabolites, have been reported recently.<sup>7</sup> Metabolic polyneuropathy shows the pathology of acute axonopathy, which is important for differentiating from the axonal form of Guillain-Barré syndrome (GBS). Amelioration of clinical manifestations in the reported cases required a relatively long time, which reflects the pathologic nature of these cases, acute axonal degeneration. Although the brain stem lesion might have influenced their disability at onset, the neuropathic symptoms, glove-and-stockings type sensorimotor disturbances, in our patients improved rapidly in response to intravenous thiamine infusions. By hospital day 30 the CMAP and SNAP amplitudes had returned almost to normal, and the patients could walk. The period required for the improvement of our three patients was surprisingly short, if the pathologic process is simple "axonal degeneration".

There are three possible mechanisms of rapid recovery in NCS: distal conduction block due to demyelination; distal axonal regeneration; and physiological conduction failure on the axolemma. Distal conduction block due to demyelination is not likely in our patients because there were similar SSR

improvements that reflect unmyelinated nerve conduction. Rapid recovery of NCS due to the resolution of distal conduction has been reported,<sup>8</sup> usually accompanied by shortening of the distal latency. The second possibility was suggested by a report in which degeneration of the intramuscular axons was found in a motor point biopsy performed on a patient with acute motor axonal neuropathy (AMAN), who showed rapid recovery.<sup>9</sup> The authors proposed that axonal degeneration in AMAN may be restricted to the nerve terminals and that regeneration could therefore develop within a short period. Such a change might have occurred in the motor axons of our patients. The sensory nerves examined by SNAPs, which similarly showed good improvement in our patients, however, did not include the nerve terminals.

We think that decreased Na<sup>+</sup>-K<sup>+</sup>-ATPase activity due to thiamine deficiency physiologically contributes to the nerve conduction in our patients, although other metabolic changes, such as the lactic acidosis observed in case 1, might also influence these nerve conduction abnormalities. Several mechanisms physiologically influence nerve conduction.<sup>10</sup> Dysfunction of the sodium channels at the nodes of Ranvier has been suggested to cause physiological conduction block in GBS,<sup>11</sup> but experimentally induced conduction abnormalities by sodium channel blockade were always accompanied by marked conduction slowing.<sup>12</sup> We therefore speculate that another possible mechanism is responsible for the reversible physiological failure of nerve conduction in our patients. ATP decreases when there is thiamine deficiency because of a decrease in pyruvate dehydrogenase (PDH) activity which is said to be also associated with a decrease in Na<sup>+</sup>-K<sup>+</sup>-ATPase activity.<sup>13</sup> Na<sup>+</sup>-K<sup>+</sup>-ATPase activity is important for the maintenance of peripheral nerve depolarisation and axon excitability. In the diabetic neuropathy model rat, peripheral neuropathy caused by reversible axonal functional impairment as a result of decreased Na<sup>+</sup>-K<sup>+</sup>-ATPase activity coexists with irreversible peripheral neuropathy caused by ischaemia at the capillary level. This is thought to be the reason for the early improvement in response to treatment.<sup>14</sup> Fink and Cairns reported that compound nerve action potential amplitudes of both myelinated and unmyelinated axons are decreased as a result of Na<sup>+</sup>-K<sup>+</sup>-ATPase inhibition by ouabain, but that there was little apparent change in the conduction velocity.<sup>15</sup> Physiological nerve conduction failure with minimal conduction slowing and axonal degeneration may have been present in our patients. Lessening of axonal dysfunction, possibly caused by decreased Na<sup>+</sup>-K<sup>+</sup>-ATPase activity due to thiamine deficiency, should be responsible, if not exclusively, for rapid recovery from the neuropathic symptoms and NCS.

#### Authors' affiliations

S Ishibashi, T Yokota, H Tanaka, K Nishina, H Hirota, A Inaba, M Yamada, T Kanda, H Mizusawa, Department of Neurology and Neurological Sciences, Graduate School, Tokyo Medical and Dental University, 1-5-45, Yushima, Bunkyo-ku, Tokyo 113-8519, Japan  
T Shiojiri, T Matunaga, Department of Neurology, Asahi General Hospital, 1-1326, Asahi, Chiba 289-2511, Japan

Correspondence to: Dr T Yokota, Department of Neurology and Neurological Sciences, Graduate School, Tokyo Medical and Dental University, 1-5-45, Yushima, Bunkyo-ku, Tokyo 113-8519, Japan; tak-yokota.nuro@tmd.ac.jp

Received 10 September 2002

Accepted 11 January 2003

#### REFERENCES

- Ohnishi A, Tsuji S, Takamori M, et al. Beriberi neuropathy. Morphometric study of sural nerve. *J Neurol Sci* 1980;**45**:177-90.
- Cirignotta F, Manconi M, Ambrosetto P, et al. Wernicke-Korsakoff encephalopathy and polyneuropathy after gastroplasty for morbid obesity: report of a case. *Arch Neurol* 2000;**57**:1356-9.
- Koike H, Misu K, Soube G, et al. Postgastroectomy polyneuropathy with thiamine deficiency. *J Neurol Neurosurg Psychiatry* 2001;**71**:357-62.
- Kanda T, Oda M, Yonezawa M, et al. Peripheral neuropathy in xeroderma pigmentosum. *Brain* 1990;**113**:1025-44.
- Dyck PJ, Sherman WR, Swanson CJ, et al. Human diabetic endoneurial sorbitol, fructose, and myo-inositol related to sural nerve morphometry. *Ann Neurol* 1980;**8**:590-6.
- Denny-Brown D. The neurological aspects of thiamine deficiency. *Fed Proc* 1958;**17**:35-9.
- Wahrle JC, Spengos K, Hennerici M, et al. Alcohol-related acute axonal polyneuropathy: a differential diagnosis of Guillain-Barré syndrome. *Arch Neurol* 1998;**55**:1329-34.
- Kuwabara S, Yuki N, Noda M, et al. IgG anti-GM1 antibody is associated with reversible conduction failure and axonal degeneration in Guillain-Barré syndrome. *Ann Neurol* 1998;**44**:202-8.
- Ho TW, Hsieh ST, Griffin JW, et al. Motor nerve terminal degeneration provides a potential mechanism for rapid recovery in acute motor axonal neuropathy after *Campylobacter* infection. *Neurology* 1997;**48**:717-24.
- Waxman SG, Ritchie JM. Molecular dissection of the myelinated axon. *Ann Neurol* 1993;**33**:121-36.
- Waxman SG. Sodium channel blockade by antibodies: a new mechanism of neurological disease? *Ann Neurol* 1995;**37**:421-3.
- Yokota T, Saito Y, Miyatake T. Conduction slowing without conduction block of compound muscle and nerve action potentials due to sodium channel block. *J Neurol Sci* 1994;**124**:220-4.
- Matuda T, Cooper JR. Inhibition of neuronal sodium and potassium ion activated adenosinetriphosphatase by pyriethiamin. *Biochemistry* 1983;**22**:2209-13.
- Yorek MA, Wiese TJ, Conner CE, et al. Reduced Na<sup>+</sup>/K<sup>+</sup> adenosine triphosphatase activity and motor nerve conduction velocity in l-fucose-fed rats is reversible after dietary normalization. *Metabolism* 1996;**45**:229-34.
- Fink BR, Cairns AM. A new approach to differential peripheral nerve fiber block: Na<sup>+</sup>, K<sup>+</sup>-ATPase inhibition. *Anesthesiology* 1983;**59**:127-31.