

Journal of Neurology Neurosurgery and Psychiatry

Editor

Professor C Kennard

Deputy Editor

Dr G D Perkin

Associate Editors

Dr L Caplan
Dr S Fleminger
Professor I R Whittle

Web Editor

R Al-Shahi (UK)

Editorial board

M P Barnes (UK)
Y Ben-Shlomo (UK)
S F Berkovic (Australia)
I Bone (UK)
M-G Bousser (France)
T Brandt (Germany)
D J Brooks (UK)
M C Dalakas (USA)
M Donaghy (UK)
J S Duncan (UK)
M Filippi (Italy)
P J Goadsby (UK)
M Husain (UK)
P J Kirkpatrick (UK)
S Love (UK)
S Lovestone (UK)
H Markus (UK)
R Maurice-Williams (UK)
T M McMillan (UK)
K Mills (UK)
I F Moseley (UK)
AHV Schapira (UK)
A Thompson (UK)
E Tolosa (Spain)
J Wardlaw (UK)
J H J Wokke (The Netherlands)
N W Wood (UK)
Editor, *BMJ*

Editorial assistants

A L Kirk
S Taylor

Technical editor

M Dodd

Instructions to authors

Full instructions are available online at www.jnnp.com/misc/ifora.shtml
If you do not have web access please contact the editorial office:
Journal of Neurology, Neurosurgery & Psychiatry
Division of Neuroscience and Psychological Medicine
Room 10E 15, Imperial College London
Charing Cross Hospital
Fulham Palace Road
London W6 8RF, UK
Telephone +44 (0)20 8846 1213
Fax +44 (0)20 8846 7730
Email: editor.jnnp@imperial.ac.uk

Subscription information

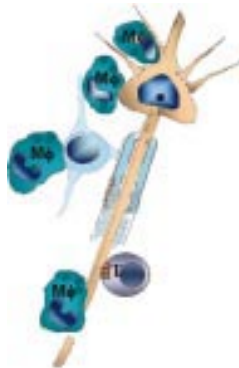
See page iv

Copyright

© 2003 *BMJ Publishing Group*. All rights reserved; no part of this publication may be reproduced, stored in a retrieval system, or transmitted in any form or by any means, electronic, mechanical, photocopying, recording, or otherwise without the prior permission of the *BMJ Publishing Group*.

Authors are required to grant the *BMJ Publishing Group* an exclusive licence to publish; further details available online at www.jnnp.com/misc/ifora.shtml

- *Journal of Neurology Neurosurgery and Psychiatry* is published by *BMJ Publishing Group* and printed in UK on acid free paper by Thanet Press Limited, Margate, Kent
- Periodicals postage paid, Rahway, NJ. Postmaster: send address changes to: *Journal of Neurology Neurosurgery and Psychiatry*, c/o Mercury Airfreight International Ltd, 365 Blair Road, Avenel, NJ 07001, USA



See p 695

**NEW
ONLINE
SUBMISSION**
**GO TO
WEBSITE**
**TO SUBMIT YOUR
MANUSCRIPT**



www.publicationethics.org.uk

This journal is a member of and subscribes to the principles of the Committee on Publication Ethics

contents JNNP

Volume 74 Number 6 June 2003

Editorial

- 695 Axonal injury in multiple sclerosis *H Lassmann*

Editorial commentary

- 697 How common is dementia with Lewy bodies?
R A Barker, T Foltynie

Review

- 699 Internet resources for neurologists *R Al-Shahi,
P A G Sandercock*

Papers

- 704 Event based and time based prospective memory in Parkinson's disease *S Katai, T Maruyama, T Hashimoto, S Ikeda*
- 710 Using the SF-36 measure to compare the health impact of multiple sclerosis and Parkinson's disease with normal population health profiles *A Riazi, J C Hobart, D L Lamping, R Fitzpatrick, J A Freeman, C Jenkinson, V Peto, A J Thompson*
- 715 Alzheimer's disease: differences in technetium-99m HMPAO SPECT scan findings between early onset and late onset dementia *P M Kemp, C Holmes, S M A Hoffmann, L Bolt, R Holmes, J Rowden, J S Fleming*
- 720 Dementia with Lewy bodies according to the consensus criteria in a general population aged 75 years or older *T Rahkonen, U Eloniemi-Sulkava, S Rissanen, A Vatanen, P Viramo, R Sulkava*
- 725 Neuroendocrine changes in patients with acute space occupying ischaemic stroke *S Schwarz, S Schwab, K Klinga, C Maser-Gluth, M Bettendorf*
- 728 Aetiological diagnosis of brain abscesses and spinal infections: application of broad range bacterial polymerase chain reaction analysis *L Kupila, K Rantakokko-Jalava, J Jalava, S Nikkari, R Peltonen, O Meurman, R J Marttila, E Kotilainen, P Kotilainen*
- 734 Abnormalities on diffusion weighted magnetic resonance imaging performed several weeks after a minor stroke or transient ischaemic attack *U G R Schulz, D Briley, T Meagher, A Molyneux, P M Rothwell*
- 739 Intra-arterial thrombolysis in 24 consecutive patients with internal carotid artery T occlusions *M Arnold, K Nedeltchev, H P Mattle, T J Loher, F Stepper, G Schroth, C Brekenfeld, M Sturzenegger, L Remonda*
- 743 Should asymptomatic patients with hereditary haemorrhagic telangiectasia (HHT) be screened for cerebral vascular malformations? Data from 22 061 years of HHT patient life *A J Easey, G M F Wallace, J M B Hughes, J E Jackson, W J Taylor, C L Shovlin*
- 749 Association of neprilysin polymorphism with cerebral amyloid angiopathy *M Yamada, N Sodeyama, Y Itoh, A Takahashi, E Otomo, M Matsushita, H Mizusawa*
- 752 Subdural haematoma: a potentially serious consequence of spontaneous intracranial hypotension *R J de Noronha, B Sharrack, M Hadjivassiliou, C A J Romanowski*

- 756 Failure to detect *Chlamydia pneumoniae* DNA in cerebral aneurysmal sac tissue with two different polymerase chain reaction methods *S Cagli, N Oktar, T Dalbasti, S Erensoy, N Özdamar, S Göksel, A Sayiner, A Bilgiç*
- 760 Brain tissue oxygen guided treatment supplementing ICP/ CPP therapy after traumatic brain injury *J Meixensberger, M Jaeger, A Vähä, J Dings, E Kunze, K Roosen*
- 765 Cerebrovascular pressure reactivity is related to global cerebral oxygen metabolism after head injury *L A Steiner, J P Coles, M Czosnyka, P S Minhas, T D Fryer, F I Aigbirhio, J C Clark, P Smielewski, D A Chatfield, T Donovan, J D Pickard, D K Menon*
- 771 Vestibular activation by bone conducted sound *M S Welgampola, S M Rosengren, G M Halmagyi, J G Colebatch*
- 779 p53, mdm2, EGFR, and msh2 expression in paired initial and recurrent glioblastoma multiforme *A M Stark, P Witzel, R J Strege, H-H Hugo, M Mehdorn*
- 784 Normal jugular bulb oxygen saturation *A Chierigato, F Calzolari, G Trasforini, L Targa, N Latronico*

Short reports

- 788 Systemic infection, interleukin 1 β , and cognitive decline in Alzheimer's disease *C Holmes, M El-OKl, A L Williams, C Cunningham, D Wilcockson, V H Perry*
- 790 Coexistence of CADASIL and Alzheimer's disease *V Thijs, W Robberecht, R De Vos, R Sciot*
- 793 Predictors of cognitive impairment in advanced Parkinson's disease *G Vingerhoets, S Verleden, P Santens, M Miatton, J De Reuck*
- 797 Hypertrophic olivary degeneration following pontine haemorrhage: hypertensive crisis or cavernous haemangioma bleeding? *T Krings, H Folyts, I G Meister, J Reul*
- 800 Hemispherectomy for large middle cerebral artery territory infarction: outcome in 19 patients *M B Pranesh, S Dinesh Nayak, V Mathew, B Prakash, M Natarajan, V Rajmohan, R Murali, A Pehlaj*
- 803 Mononeuritis multiplex in diabetes mellitus: evidence for underlying immune pathogenesis *P Kelkar, G J Parry*
- 807 The clinicopathological spectrum of Rosenthal fibre encephalopathy and Alexander's disease: a case report and review of the literature *J Jacob, N J Robertson, D A Hilton*
- 811 BOLD fMRI activation induced by vagus nerve stimulation in seizure patients *W-C Liu, K Mosier, A J Kalnin, D Marks*
- 814 Risk of recurrence of cerebral venous and sinus thrombosis during subsequent pregnancy and puerperium *S Mehraein, H Ortwein, M Busch, M Weih, K Einhäupl, F Masuhr*

- 817 Mental illness in new neurological patients *P Fink, M S Hansen, L Søndergaard, M Frydenberg*

Letters

- 820 Central pontine myelinolysis temporally related to hypophosphataemia *A W Michell, D J Burn, P J Reading*
- 820 Spastic movement disorder: what is the impact of research on clinical practice? *V Dietz*
- 821 Intracranial hypotension after chiropractic manipulation of the cervical spine *J Beck, A Raabe, V Seifert, E Dettmann*
- 822 Clinical and electrophysiological improvement of adrenomyeloneuropathy with steroid treatment *L X Zhang, R Bakshi, E Fine, H W Moser*
- 823 Acute anterior radiculitis associated with West Nile virus infection *M Park, J S Hui, R E Bartt*
- 825 A case of possible autoimmune bilateral vestibulopathy treated with steroids *O Schüler, M Strupp, V Arbusow, T Brandt*
- 825 An Italian family affected by Nasu-Hakola disease with a novel genetic mutation in the TREM2 gene *D Soragna, R Tupler, M T Ratti, L Montalbetti, L Papi, R Sestini*

Correspondence

- 827 Subthalamic deep brain stimulation for advanced Parkinson's disease: all that glitters is not gold *G Linazasoro*. Reply: *J L Houeto, V Mesnage, L Mallet, M L Welter, D Dormont, B Pidoux, P Cornu, Y Agid*
- 827 Head injury outcome prediction in the emergency department: a role for protein S-100B? *M T Wunderlich*. Reply: *W Townend, B Martin, D Yates, M Guy*
- 828 Screening for variant Creutzfeldt-Jakob disease *D A Hilton, J W Ironside*

Book reviews

Neurological stamp

- 698 Félix Guyon 1831–1920 *L F Haas*

Neuronline

- 703 Online Mendelian Inheritance in Man OMIM: www.ncbi.nlm.nih.gov/entrez *M J Parton*

Historical note

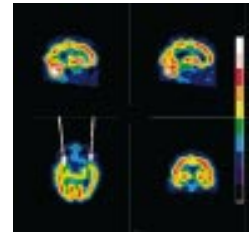
- 787 Sir David Ferrier MD, FRS *J M S Pearce*

Neurological picture

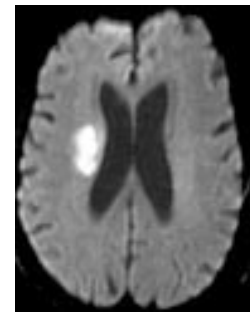
- 806 Coccidioidomycosis of the brain, mimicking en plaque meningioma *J R Komotar, R E Clatterbuck*

Proceedings

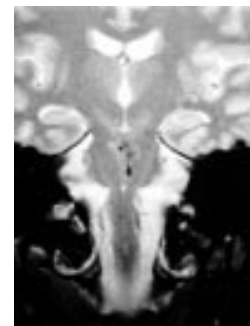
- 830 BNPA abstracts



See p 715



See p 734



See p 752