

Journal of Neurology Neurosurgery and Psychiatry

Editor

Professor M N Rossor

Deputy Editor

Dr M G Hanna

Associate Editors

Dr S Fleming, UK
Professor D Leys, France
Professor P Scheltens, The Netherlands
Professor I R Whittle, UK

Web Editor

R Al-Shahi (UK)

Editorial Board

M P Barnes (UK)
Y Ben-Shlomo (UK)
S F Berkovic (Australia)
I Bone (UK)
M-G Bousser (France)
T Brandt (Germany)
D J Brooks (UK)
M C Dalakas (USA)
M Donaghy (UK)
J S Duncan (UK)
M Filippi (Italy)
P J Goadsby (UK)
M Husain (UK)
P J Kirkpatrick (UK)
S Love (UK)
S Lovestone (UK)
H Markus (UK)
R Maurice-Williams (UK)
T M McMillan (UK)
K Mills (UK)
I F Moseley (UK)
AHV Schapira (UK)
A Thompson (UK)
E Tolosa (Spain)
J Wardlaw (UK)
J H J Wokke (The Netherlands)
N W Wood (UK)
Editor, *BMJ*

Editorial Assistant

A L Kirk

Technical Editor

N West

Instructions to authors

Full instructions are available online at www.jnnp.com/misc/ffora.shtml
If you do not have web access please contact the editorial office:
Journal of Neurology, Neurosurgery & Psychiatry
BMJ Journals, BMA House, Tavistock Square,
London WC1H 9JR, UK
Telephone +44 (0)20 7383 6890
Fax +44 (0)20 7383 6668
Email: jnnp@bmjgroup.com

Subscription information

See p iv

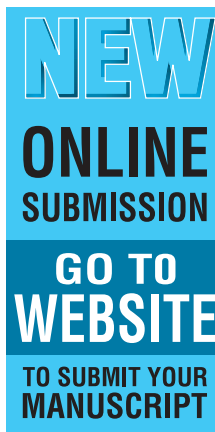
Copyright

© 2004 *BMJ Publishing Group*. All rights reserved; no part of this publication may be reproduced, stored in a retrieval system, or transmitted in any form or by any means, electronic, mechanical, photocopying, recording, or otherwise without the prior permission of the *BMJ Publishing Group*.

Authors are required to grant the *BMJ Publishing Group* an exclusive licence to publish; further details available online at www.jnnp.com/misc/ffora.shtml

• *Journal of Neurology Neurosurgery and Psychiatry* is published by *BMJ Publishing Group*, typeset by The Charlesworth Group, and printed in UK on acid-free paper by Thanet Press Limited, Margate, Kent

• Periodicals postage paid, Rahway, NJ. Postmaster: send address changes to: *Journal of Neurology Neurosurgery and Psychiatry*, c/o Mercury Airfreight International Ltd, 365 Blair Road, Avenel, NJ 07001, USA



www.publicationethics.org.uk

This journal is a member of and subscribes to the principles of the Committee on Publication Ethics

contents JNNP

Volume 75 Number 9 September 2004

Editorial

- 1229 Genes for stroke *H Markus*

Editorial commentaries

- 1232 Sexual wellbeing in Parkinson's disease
S F Farmer
- 1232 Primary progressive multiple sclerosis takes
centre stage *P M Matthews*
- 1234 Is it time to consider rationalising IFN- β
treatment in individuals with multiple sclerosis?
G Giovannoni

Neuroscience for neurologists

- 1235 A review of structural magnetic resonance
neuroimaging *M Symms, H R Jäger,
K Schmierer, T A Yousry*

Papers

- 1245 Postural abnormalities to multidirectional
stance perturbations in Parkinson's disease
*M G Carpenter, J H J Allum, F Honegger,
A L Adkin, B R Bloem*
- 1255 Subthalamic nucleus stimulation in advanced
Parkinson's disease: blinded assessments at
one year follow up *B Ford, L Winfield,
S L Pullman, S J Frucht, Y Du, P Greene,
J H Cheringal, Q Yu, L J Cote, S Fahn,
G M McKhann II, R R Goodman*
- 1260 Sexual well being in parkinsonian patients after
deep brain stimulation of the subthalamic
nucleus *L Castelli, P Perozzo, M L Genesis,
E Torre, M Pesare, A Cinquepalmi, M Lanotte,
B Bergamasco, L Lopiano*
- 1265 Hyperekplexia and stiff-man syndrome: abnormal
brainstem reflexes suggest a physiological
relationship *S Khasani, K Becker, H-M Meinck*
- 1270 Alzheimer's disease—one clinical syndrome,
two radiological expressions: a study on blood
pressure *F-E de Leeuw, F Barkhof, P Scheltens*
- 1275 Mild cognitive impairment: a cross-national
comparison *E Arnáiz, O Almkvist, R J Ivnik,
E G Tangalos, L O Wahlund, B Winblad,
R C Petersen*
- 1281 Mechanisms of normal appearing corpus
callosum injury related to pericallosal T1 lesions
in multiple sclerosis using directional diffusion
tensor and ^1H MRS imaging *J Oh, R G Henry,
C Genain, S J Nelson, D Pelletier*
- 1288 Abnormalities of cerebral perfusion in multiple
sclerosis *W Rashid, L M Parkes, G T Ingle,
D T Chard, A T Toosy, D R Altmann, M R Symms,
P S Tofts, A J Thompson, D H Miller*
- 1294 Biological activity of interferon betas in patients
with multiple sclerosis is affected by treatment
regimen and neutralising antibodies
*A Bertolotto, A Sala, S Malucchi, F Marnetto,
M Caldano, A Di Sapio, M Capobianco, F Gilli*
- 1300 Prognosis of asymptomatic stenosis of the
middle cerebral artery *C Kremer, T Schaettin,
D Georgiadis, R W Baumgartner*

- 1304 Neuroanatomical localisation and clinical correlates of white matter lesions in the elderly *S Artero, H Tiemeier, N D Prins, R Sabatier, M M B Breteler, K Ritchie*
- 1309 Magnetoencephalography (MEG) predicts focal epileptogenicity in cavernomas *H Stefan, G Scheler, C Hummel, J Walter, J Romstöck, M Buchfelder, I Lümkke*
- 1314 Gross morphology and morphometric sequelae in the hippocampus, fornix, and corpus callosum of patients with severe non-missile traumatic brain injury without macroscopically detectable lesions: a T1 weighted MRI study *F Tomaiuolo, G A Carlesimo, M Di Paola, M Petrides, F Fera, R Bonanni, R Formisano, P Pasqualetti, C Caltagirone*

Short reports

- 1323 Testosterone deficiency and apathy in Parkinson's disease: a pilot study *R E Ready, J Friedman, J Grace, H Fernandez*
- 1327 Apolipoprotein E e4 allele influences aggressive behaviour in Alzheimer's disease *D Craig, D J Hart, K McCool, S P McIlroy, A P Passmore*
- 1331 Mechanical ventilation and tracheostomy in multiple sclerosis *S J Pittock, B G Weinschenker, E F M Wijidicks*
- 1334 Smell testing: an additional tool for identification of adult Refsum's disease *F B Gibberd, M D Feher, M C Sidey, A S Wierzbicki*
- 1337 Autopsy proven sporadic frontotemporal dementia due to microvacuolar-type histology, with onset at 21 years of age *J S Snowden, D Neary, D M A Mann*
- 1340 Brain stem stroke associated with epidermoid tumours: report of two cases *S Yilmazlar, H Kocaeli, T Cordan*
- 1343 Optic chiasm enhancement associated with giant aneurysm and yttrium treated pituitary adenoma *C M Gabriel, J C Stevens, F Bremner, S Brew, G T Plant*
- 1346 Intraventricular cytarabine in a case of idiopathic hypertrophic pachymeningitis *I Kleiter, V H Hans, G Schuierer, J Marienhagen, P Hau, H Schütz, U Bogdahn, A Steinbrecher*
- 1349 Novel missense mutation in the caveolin-3 gene in a Belgian family with rippling muscle disease *P Y K Van den Bergh, J M Gérard, J A Elozegi, M U Manto, C Kubisch, B G H Schoser*
- 1352 Proton magnetic resonance neurospectroscopy and EEG cartography in corticobasal degeneration: correlations with neuropsychological signs

J Vion-Dury, N Rochefort, P Michotey, D Planche, M Ceccaldi

- 1356 Group study of an "undercover" test for visuospatial neglect: invisible cancellation can reveal more neglect than standard cancellation *E Wojciulik, C Rorden, K Clarke, M Husain, J Driver*
- 1359 Oculomotor abnormalities parallel cerebellar histopathology in autism *Y Takarae, N J Minshew, B Luna, J A Sweeney*

Letters

- 1362 Dystonia, tremor, and parkinsonism in a 54 year old man with 2-hydroxyglutaric aciduria *W E Owens, M S Okun*
- 1363 Transient myasthenia gravis in an elderly woman *W W Y Wong, R J M Lane*
- 1363 "Doctor, I can hear my eyes": report of two cases with different mechanisms *W Albuquerque, A M Bronstein*
- 1364 Transient compulsive hyperphagia in a patient with a thalamic infarct *P Cerrato, M Grasso, C Azzaro, C Baima, M Giraud, A Rizzuto, A Lentini, P Perozzo, B Bergamasco, G Sorrentino*
- 1365 Case study: cerebrovascular parkinsonism with levodopa addiction *O Lily, A Al-Din*

Correspondence

- 1367 Validity of language lateralisation by unilateral intracarotid Wada test *A Schulze-Bonhage, A Quiske. Reply: T Loddenkemper, D S Dinner, E Wyllie*
- 1368 Tangier disease *R S Kocen*
- 1368 Book reviews
- 1370 Correction

Neurological picture

- 1287 An unusual "empty delta sign" *L Deus-Silva, B Voetsch, A Nucci, J A Maciel, L R Caplan*

Historical notes

- 1299 Cotugno and cerebrospinal fluid *J M S Pearce*
- 1345 The Argyll Robertson pupil *J M S Pearce*

Miscellanea

- 1280 Echo: Sydenham's chorea may be relevant to common childhood idiopathic conditions