

VIRAL ENCEPHALITIS: CAUSES, DIFFERENTIAL DIAGNOSIS, AND MANAGEMENT

P G E Kennedy

i10

J Neurol Neurosurg Psychiatry 2004;**75**(Suppl II):i10–i15. doi: 10.1136/jnnp.2003.034280

Encephalitis refers to an acute, usually diffuse, inflammatory process affecting the brain. While meningitis is primarily an infection of the meninges, a combined meningoencephalitis may also occur. An infection by a virus is the most common and important cause of encephalitis, although other organisms may sometimes cause an encephalitis. An encephalitic illness caused by alteration of normal immune function in the context of a previous viral infection or following vaccination is also well recognised (acute disseminated encephalomyelitis, ADEM). An infectious encephalitis may also be difficult to distinguish from an encephalopathy that may be associated with numerous metabolic causes. Among the factors which have helped to focus attention on viral encephalitis over the last few years have been:

- ▶ the development of effective antiviral agents for this condition, most notably acyclovir for herpes simplex virus encephalitis (HSE) which is caused by herpes simplex virus (HSV)-1 or HSV-2
- ▶ the advent of human immunodeficiency virus (HIV) infection of the central nervous system (CNS) with its wide range of associated acute viral infections
- ▶ the recent recognition of emerging viral infections of the CNS such as West Nile encephalitis and Nipah virus encephalitis.

This article will address three broad areas of viral encephalitis—its causes, differential diagnosis, and management. While the approach will be a general one, I shall focus particularly on HSE which is the most frequent cause of sporadic fatal encephalitis in humans in the western world.

CAUSES OF VIRAL ENCEPHALITIS

The various causes of acute infectious viral encephalitis are shown in table 1. While precise figures for the incidence of encephalitis following these various viruses are not available, estimates have been given for some of them. For example, it has been estimated that HSE, the most important treatable viral encephalitis, has an incidence of about one case per million per year.¹ About 2000 cases occur annually in the USA.² About 90% of cases of HSE are caused by HSV-1, with 10% due to HSV-2, the latter usually being the cause of HSE in immunocompromised individuals and neonates in which it causes a disseminated infection. Molecular analyses of paired oral/labial and brain sites have indicated that HSE can be the result of a primary infection, a reactivation of latent HSV, or a re-infection by a second HSV.¹ These estimates of HSE may well be underestimates as judged by the experience of individual neurological centres and detailed studies using the polymerase chain reaction (PCR). Thus, a small PCR based study suggested that up to a fifth of patients with HSE may have mild or atypical disease caused by either HSV-1 or HSV-2, occurring especially in immunocompromised individuals such as those with HIV infection.³

A recent study in Finland also used PCR to detect various viruses in the CSF of over 3000 patients who had infections of the CNS including encephalitis, meningitis, and myelitis.⁴ It was found that, rather surprisingly, varicella zoster virus (VZV), the cause of chickenpox and herpes zoster, was the most frequently detected virus at 29%, with HSV and enteroviruses accounting for 11% of cases each, and influenza A virus found in 7% of cases. If one assumes a cause-and-effect relation between the detected virus and the CNS condition in a significant proportion of these cases, then it indicates that VZV has been generally underestimated, and HSV perhaps overestimated in frequency. Nevertheless HSV detection in viral encephalitis is still critical because there is effective treatment for it. Further prospective PCR based studies will be needed to answer these questions.

While HIV has not been listed as it usually causes a type of subacute encephalitis, it is important in so far as its associated immunosuppression predisposes the individual to viral encephalitis caused by, for example, HSV-1, HSV-2, VZV, and cytomegalovirus (CMV). The frequency and distribution of these viruses clearly varies according to the geographical region, with large differences seen between Europe, Asia, and the USA. Thus, St Louis virus encephalitis, which is caused by a mosquito borne arbovirus, occurs in the midwestern and eastern states of the

Correspondence to:
Professor P G E Kennedy,
Department of Neurology,
University of Glasgow, Institute
of Neurological Sciences,
Southern General Hospital,
Glasgow G51 4TF, UK;
p.g.kennedy@
clinmed.gla.ac.uk

USA, and not in the UK, while Japanese encephalitis is a major problem in Asia, and is the most important cause of epidemic encephalitis worldwide, causing up to 15000 deaths annually.⁵ Two “emerging” viral infections of the nervous system which have received much attention recently are West Nile virus encephalitis and Nipah virus encephalitis. The former is caused by the transport of neurovirulent strains of West Nile virus into the Western hemisphere, while the latter has resulted from the penetration of a newly recognised paramyxovirus across a species barrier from bat to pig,⁶ and represents the first large scale epizootic encephalitis involving direct animal to human transmission.

DIFFERENTIAL DIAGNOSIS OF VIRAL ENCEPHALITIS

The characteristic presentation of viral encephalitis usually consists of fever, headache, and clouding of consciousness together with seizures and focal neurology in some cases. However, the distinction between an infective viral encephalitis and a metabolic encephalopathy or ADEM may not always be straightforward. Once a diagnosis of infective viral encephalitis has been established it is then necessary to have a clear investigative plan to try to determine the likely cause. These three issues will now be considered in turn.

How can a viral encephalitis be distinguished from a non-infective encephalopathy?

There are numerous medical conditions which may produce an encephalopathic illness which may mimic viral encephalitis, and some of the most important of these are listed in table 2. Particularly prominent among these are systemic infections which can look very much like an encephalitis on presentation. In patients recently returning from abroad, particular vigilance must be paid to the possibility of such non-viral infections as cerebral malaria which may be rapidly fatal if not treated early. A number of metabolic conditions including liver and renal failure and diabetic complications may also cause confusion. The possible role of alcohol and drug ingestion must always be considered. Table 2 also indicates the need to sometimes consider some of the rarer causes of encephalopathy where appropriate pointers exist.

While the distinction may not always be straightforward, there are a number of clues which may indicate that the patient has an infective viral encephalitis rather than a non-viral encephalopathy. Table 3 summarises the most important of these and indicates the need for a careful examination and usually cranial imaging to exclude a structural lesion followed by CSF examination. These various clues should not be taken in isolation but considered as a whole to guide the

clinician, as not all of them are likely to be present in the same patient. Thus, the author has seen one patient with a proven metabolic encephalopathy who had a fluctuating mental status, but has found that the presence or absence of focal signs and seizures, the presence or absence of electroencephalographic (EEG) changes, normal or otherwise cranial imaging, and CSF profile have been particularly helpful in making the distinction between these two conditions.

How can an infective viral encephalitis be distinguished from ADEM?

ADEM, also known as postinfectious encephalomyelitis, usually follows either a vaccination within the preceding four weeks, or an infection which may be a childhood exanthema such as measles, rubella or chickenpox, or else a systemic infection characteristically affecting the respiratory or gastrointestinal systems.⁷ There is very good evidence from various sources to suggest an immune pathogenesis of this disorder, with an abnormal immune reaction directed against normal brain. Potential immune mechanisms include molecular mimicry between epitopes expressed by myelin antigens and viral or other pathogens, immune dysregulation, superantigen induction, and a direct result of the infection.⁸ It is important to distinguish ADEM from acute infectious encephalitis, acute non-infectious encephalitis, and an acute metabolic or toxic encephalopathy.⁸ While the diagnosis may not always be immediately obvious, there are a number of helpful clues in the history, examination, and investigative profile that may greatly assist in the distinction between ADEM and an infectious encephalitis. These differences have been very clearly identified by Davis⁷ and are summarised in table 4. The typical clinical picture is of a younger person with a history of vaccination or infection presenting abruptly, without fever at the onset of symptoms, and with multifocal neurological signs affecting both the CNS and possibly the peripheral nerve roots.⁹ It should also be appreciated that ADEM can also present with a very restricted neurological picture such as transverse myelitis, optic neuritis, and cerebellar ataxia, and differentiation from acute multiple sclerosis can sometimes be difficult. As is the case for table 3, these various diagnostic pointers should be taken together and not in isolation when trying to make the diagnosis of ADEM.

How can the likely cause of an acute infective encephalitis be determined?

The possible viral causes of acute infectious encephalitis have already been listed in table 1. There are also numerous non-viral causes of infectious encephalitis comprising various bacteria, rickettsia, fungi, and parasites; these are broadly, but not exhaustively, summarised in table 5. The general diagnostic approach to the differential diagnosis which I shall outline here is straightforward, and consists of the history, examination and then general and neurological investigations. However, it should be appreciated that in approximately half of cases the cause of viral encephalitis is not found.

Historical clues

A carefully taken history, usually obtained from the comatose patient's relatives, is of crucial importance in determining the likely cause of encephalitis. The presence of a prodromal illness, or a recent vaccination, may indicate ADEM, as would

Table 1 Causes of viral encephalitis

- ▶ Herpes simplex virus (HSV-1, HSV-2)
- ▶ Other herpes viruses: varicella zoster virus (VZV), cytomegalovirus (CMV), Epstein-Barr virus (EBV), human herpes virus 6 (HHV6)
- ▶ Adenoviruses
- ▶ Influenza A
- ▶ Enteroviruses, poliovirus
- ▶ Measles, mumps and rubella viruses
- ▶ Rabies
- ▶ Arboviruses—for example, Japanese B encephalitis, St Louis encephalitis virus, West Nile encephalitis virus, Eastern, Western, and Venezuelan equine encephalitis virus, tick borne encephalitis viruses
- ▶ Bunyaviruses—for example, La Crosse strain of California virus
- ▶ Reoviruses—for example, Colorado tick fever virus
- ▶ Arenaviruses—for example, lymphocytic choriomeningitis virus

Modified from Chaudhuri and Kennedy,⁹ with permission.

Table 2 Common causes of encephalopathy

- ▶ Anoxic/ischaemic
- ▶ Metabolic
- ▶ Nutritional deficiency
- ▶ Toxic
- ▶ Systemic infections
- ▶ Critical illness
- ▶ Malignant hypertension
- ▶ Mitochondrial cytopathy (Reye's and MELAS syndromes)
- ▶ Hashimoto's encephalopathy
- ▶ Paraneoplastic
- ▶ Neuroleptic malignant syndrome
- ▶ Traumatic brain injury
- ▶ Epileptic (non-convulsive status)

Reproduced from Chaudhuri and Kennedy,⁹ with permission.

a clinical development over a few days. A biphasic onset with a systemic illness followed by CNS disease is characteristic of enterovirus encephalitis.⁹ HSE usually has an abrupt onset with rapid progression over a few days, but there are no clearly distinguishing features that can be used to differentiate HSE from the other causes of viral encephalitis.⁷ A history of recent travel and the geographical context of the illness may also be important. For example, both cerebral malaria and human African trypanosomiasis should be considered in a patient who has recently travelled to Africa, Japanese encephalitis in the case of travel to Asia, and Lyme disease in the case of travel to high risk regions of Europe and the USA. A history of recent animal bites should raise suspicion of tick borne encephalitis or even rabies, and recent contact with infectious conditions such as a childhood exanthema or polio may also be relevant. The occupation of the patient may also be relevant—for example, a forest worker may be exposed to tick bites and medical personnel may have had recent exposure to individuals with infectious diseases. The season may also be relevant—for example, Japanese encephalitis is more common during the rainy season and arbovirus infections in the USA are more frequent during the summer and autumn months. Any predisposing factors should also be noted such as immunosuppression caused by disease and/or drug treatment. Individuals with organ transplants are particularly prone to opportunistic infections such as listeria, aspergillosis and cryptococcus, and HIV patients are also prone to a variety of CNS infections including HSV-2 encephalitis and CMV infection. A possible history of drug ingestion and/or abuse may also be highly relevant.

Examination clues

A thorough general examination may reveal systemic features indicating, for example, involvement of the respiratory or gastrointestinal systems. Skin rashes may indicate VZV or other viral infection such as measles, as well as non-viral causes such as rickettsial infection. Evidence of bites may point towards a possible diagnosis of Lyme disease or rabies. The incidence of "cold sores" in patients with HSE has not been shown to be different from that in the normal population and so they are not diagnostic.

Neurological examination may reveal focal features such as fronto-temporal signs, aphasia, personality change, and focal seizures which are characteristic of HSE, but such focality may be minimal during acute viral encephalitis and may not be diagnostic of a particular viral cause. It has recently been recognised that about 20% of HSE cases may be relatively mild and atypical without the typical focal features.³ Raised intracranial pressure may be evident but does not necessarily occur, certainly at the early stages. If the peripheral nervous system is involved then this raises the possibility of the encephalitis being ADEM or an infection with CMV, VZV or Epstein-Barr virus (EBV), which can all produce a combination of central and peripheral signs. The presence of myelitis or poliomyelitis points away from HSE and towards the possibility of polio, enterovirus, or arbovirus infection (especially West Nile virus and Japanese encephalitis).

Investigations

These are both general and specifically neurological.

General investigations include a routine full haematological and biochemical blood screen. A leucocytosis is common in ADEM and a relative lymphocytosis may occur in viral encephalitis. A leucopenia may occur in rickettsial infections, and a very raised erythrocyte sedimentation rate (ESR) might suggest tuberculosis or underlying malignancy. A thin and thick peripheral blood smear may be required in cases of suspected cerebral malaria. Biochemical screening is required in cases of suspected metabolic encephalopathy. A drug screen and urine analysis may also be relevant in some cases. A chest x ray should always be performed and if abnormal raises the possibilities of tuberculosis, mycoplasma, malignancy, and legionella. Serological investigations may be diagnostically useful but usually take over a week to perform which is of no utility in the acute situation. However, the presence of cold agglutinins can be quickly determined and, if positive, indicate a diagnosis of mycoplasma; an enzyme

Table 3 Frequent differences between encephalopathy and encephalitis

	Encephalopathy	Encephalitis
<i>Clinical features</i>		
Fever	Uncommon	Common
Headache	Uncommon	Common
Depressed mental status	Steady deterioration	May fluctuate
Focal neurologic signs	Uncommon	Common
Types of seizures	Generalised	Generalised or focal
<i>Laboratory findings</i>		
Blood	Leucocytosis uncommon	Leucocytosis common
CSF	Pleocytosis uncommon	Pleocytosis common
EEG	Diffuse slowing	Diffuse slowing and focal abnormalities
MRI	Often normal	Focal abnormalities

Reproduced from Davis,⁷ with permission.

These features are only guidelines for the clinician to help in the distinction between the two conditions. An individual patient is likely to show various combinations of these features.

CSF, cerebrospinal fluid; EEG, electroencephalogram; MRI, magnetic resonance imaging.

Table 4 Comparison of acute disseminated encephalomyelitis and infectious encephalitis

	Acute disseminated encephalomyelitis	Infectious encephalitis
<i>Clinical features</i>		
Most common age	Children	Any age
Recent vaccination	Common	Uncommon
Prodromal illness	Usually	Occasionally
Fever	May occur	Common
Visual loss (one or both eyes)	May occur	Uncommon
Spinal cord signs	May occur	Rare
<i>Laboratory findings</i>		
Blood	Leucocytosis occasionally occurs	Leucocytosis common
MRI (T2 weighted)	Multiple focal areas of hypersensitivity that are the same and may involve white matter of both hemispheres, basal ganglia, brainstem, cerebellum, and spinal cord	One or more diffuse areas of hypersensitivity involves the grey matter of both cerebral cortices and its underlying white matter and, to a lesser extent, basal ganglia, brainstem, and cerebellum
CSF	Lymphocytic pleocytosis, elevated protein, normal glucose, and negative cultures. Red blood cells seen in acute haemorrhagic leucoencephalitis.	Lymphocytic pleocytosis, elevated protein, normal glucose, and negative cultures. Red blood cells may be seen in herpes simplex encephalitis.

Reproduced, in part, from Davis,⁷ with permission.

linked immunosorbent assay (ELISA) can detect IgM antibodies to arboviruses as a rapid method of diagnosis. Viral culture from different sites may assist in eventual diagnosis, but in the author's opinion is seldom of use in the acute situation.

Neurological investigation usually starts with cranial imaging with a computed tomographic (CT) or magnetic resonance imaging (MRI) scan, primarily to exclude quickly an intracranial tumour or abscess, but also to yield specific diagnostic information. MRI is the imaging of choice in suspected cases of viral encephalitis, although CT scanning may be used where MRI facilities are not available. CT may be normal in HSE, especially early in the illness, but characteristically shows reduced attenuation in one or both temporal lobes or areas of hyperintensity.⁷ MRI is sensitive in the early stages of HSE although rarely it may be normal in this

condition. The typical MRI features in HSE are areas of focal oedema in the temporal lobes and orbital surface of the frontal lobes as well as the insular cortex and angular gyrus¹⁰ (fig 1); abnormal areas may show enhancement with gadolinium. Midline shift may be present in cases with significant cerebral oedema. Some other types of viral encephalitis such as Japanese encephalitis and eastern equine encephalitis are also associated with particular MRI abnormalities. Where available, functional imaging such as SPECT (single photon emission computed tomography) may yield additional useful information in cases of viral encephalitis—for example, temporal lobe hyperperfusion may be a marker of HSE. An EEG should also be performed in all cases of possible encephalitis, and is particularly useful in the distinction between encephalitis and metabolic encephalopathy. The EEG is invariably abnormal in HSE showing either early non-specific slowing or later "PLEDS" (periodic lateralising epileptiform discharges), although these are not themselves diagnostic of HSE.

Table 5 Non-viral causes of infectious encephalitis

Bacterial
<i>Mycobacterium tuberculosis</i>
<i>Mycoplasma pneumoniae</i>
<i>Listeria monocytogenes</i>
<i>Borrelia burgdorferi</i>
Leptospirosis
Brucellosis
Leptospirosis
Legionella
<i>Tropheryma whippelli</i> (Whipple's disease)
<i>Nocardia actinomyces</i>
<i>Treponema pallidum</i>
<i>Salmonella typhi</i>
All causes of pyogenic meningitis
Rickettsial
<i>Rickettsia rickettsia</i> (Rocky Mountain spotted fever)
<i>Rickettsia typhi</i> (endemic typhus)
<i>Rickettsia prowazekii</i> (epidemic typhus)
<i>Coxiella burnetii</i> (Q fever)
Ehrlichiosis (<i>Ehrlichia chaffeensis</i> —human monocytic ehrlichiosis)
Fungal
Cryptococcus
Aspergillosis
Candidiasis
Coccidiomycosis
Histoplasmosis
North American blastomycosis
Parasitic
Human African trypanosomiasis (sleeping sickness)
Cerebral malaria
<i>Toxoplasma gondii</i>
<i>Echinococcus granulosus</i>
Schistosomiasis

Modified from Chaudhuri and Kennedy,⁹ with permission.

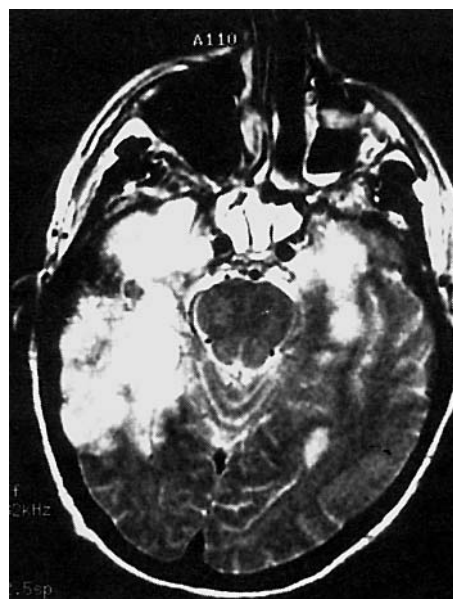


Figure 1 HSE. T2 weighted MRI showing extensive area of increased signal in right temporal lobe and lesser involvement of the left. Reproduced from Baringer¹⁰, with permission.

i14

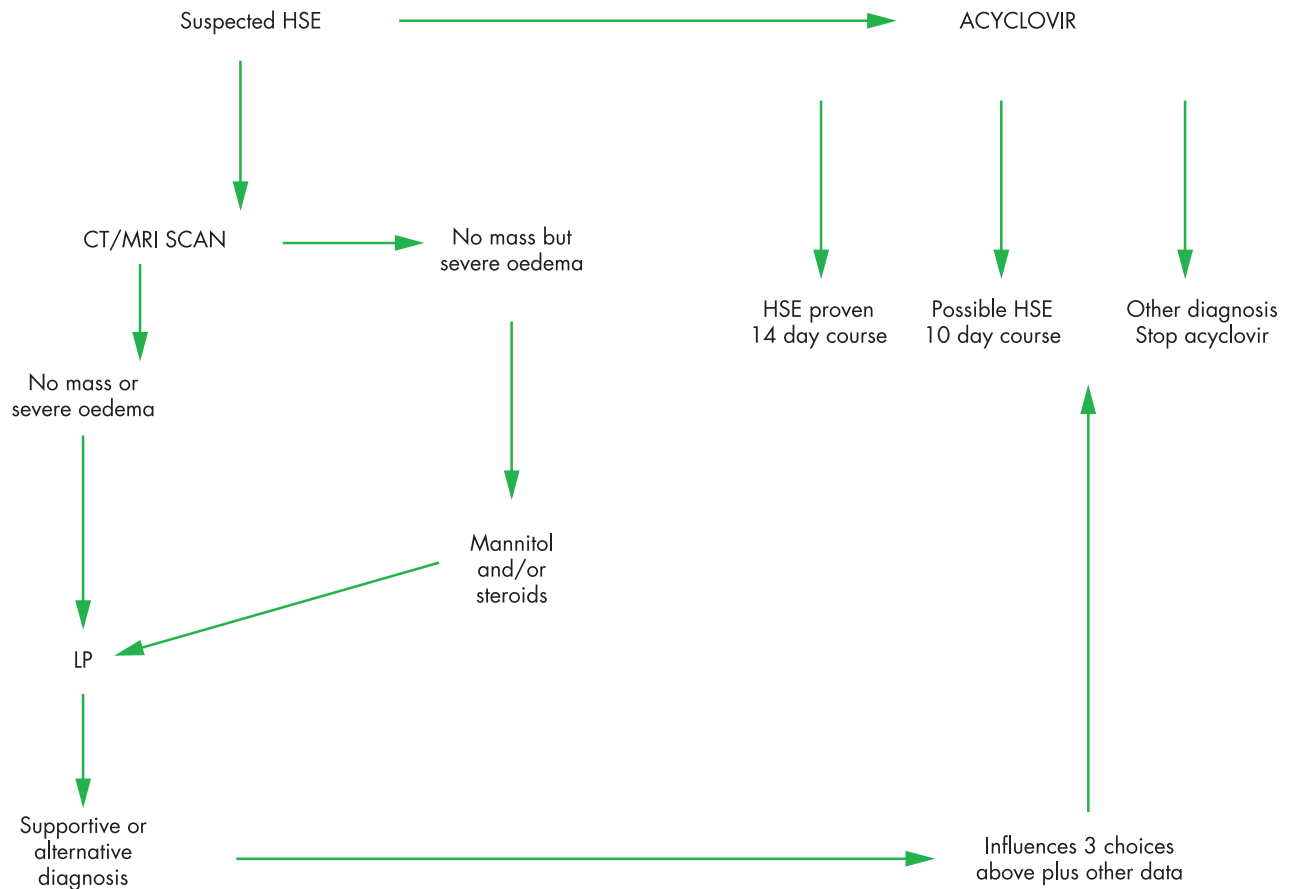


Figure 2 Suggested flow chart for basic management of suspected herpes simplex encephalitis (HSE).

Provided cranial imaging has excluded any contraindications such as a space occupying lesion or severe cerebral oedema and brain shift, a CSF analysis by lumbar puncture should be carried out in cases of suspected encephalitis. When significant cerebral oedema is present, I favour treatment with steroids and/or mannitol to reduce the intracranial pressure before lumbar puncture being reconsidered. Although about 5% of patients with HSE have a normal CSF profile, the typical features of HSE are a lymphocyte cell of 10–200/mm³ and an increased protein of 0.6–6 g/l.¹¹ A low CSF glucose is rare in viral encephalitis but when it occurs it raises the possibility that the encephalitis is actually caused by tuberculous meningoencephalitis. While xanthochromia may be present in HSE it is of no specific diagnostic value.¹⁰ The diagnosis of viral encephalitis has been greatly facilitated by CSF PCR. In an experienced diagnostic laboratory the CSF will should be positive for HSV DNA in about 95% of cases during the first week of the illness, with false negative results most likely occurring within the first 24–48 hours or after 10–14 days of the illness. The specificity of this test for HSE is over 95%. PCR can also be used to help diagnose viral encephalitis from other causes such as CMV, VZV, influenza, and enterovirus infection. While serum and CSF are frequently taken for estimation of viral antibody titres in the acute and convalescent phases, these are of little value in the acute management of the patient because of the delay in obtaining the results. Brain biopsy is now seldom performed largely because of the advent of acyclovir treatment (see below) and CSF PCR

diagnosis, but still may have to be considered where there is serious diagnostic doubt.

MANAGEMENT OF VIRAL ENCEPHALITIS

This can be considered from both the general and specific aspects.

The general management is essentially supportive and in severe cases is likely to be in a high dependency medical environment. Focal and generalised seizures need to be treated effectively with anticonvulsants, typically intravenous fosphenytoin in the first instance. While a degree of raised intracranial pressure, not requiring treatment, may well be present in viral encephalitis, it may become severe as evidenced by the development of papilloedema and rapid clinical deterioration, and severe sulcal effacement and midline shift on brain imaging. Such significantly raised intracranial pressure should be treated with intravenous mannitol and/or steroids. Despite the lack of an evidence base, the author does not usually withhold steroids in this situation, especially if the encephalitis is already being treated with antiviral agents. In the case of rapidly increasing intracranial pressure with clinical deterioration unresponsive to medical treatment, very serious consideration should be given to surgical decompression which can be lifesaving if carried out in time. In addition, other complications such as fluid and electrolyte imbalance, secondary bacterial infections, aspiration pneumonia, respiratory failure, and cardiac abnormalities should be detected early and treated appropriately. In the case of ADEM, steroids are frequently given

but in fact there have been no placebo controlled studies to prove their efficacy or otherwise in this condition.

If antiviral therapy is not given to patients with HSE the mortality is over 70%.¹² Specific antiviral therapy for HSE is intravenous acyclovir, a nucleoside analogue which acts specifically against virus infected cells which explains its remarkable safety and lack of toxicity. This drug has revolutionised the treatment and prognosis of HSE, although even with acyclovir therapy the morbidity and mortality is unacceptably high at 28% at 18 months after treatment.¹² If HSE is a definite possibility then acyclovir, 10 mg/kg three times daily, should be started as soon as possible. When the diagnosis is confirmed by CSF PCR, and/or where there are characteristic MRI changes, acyclovir should be continued for 14 days. During this period renal function should be closely monitored because of the rare development of renal impairment. Acyclovir should only be stopped where there is a definite alternative diagnosis made, otherwise a deterioration after cessation of therapy may be very difficult to interpret and manage.¹¹ The situation of still suspected HSE in the presence of a negative CSF PCR and MRI is less easy to manage. My own preference is to give acyclovir for 10 days in this scenario. This suggested scheme of management is summarised in fig 2. The prognosis of HSE is better in younger patients, and those having a disease duration of four days or less and a Glasgow coma score of 6 or less at the time of acyclovir initiation.¹² In some centres the CSF PCR is repeated at the end of acyclovir treatment and a further course of acyclovir recommended if it is positive to prevent a relapse.¹³ At present, the evidence base for this approach is awaited and in the author's centre this is not routine practice. However, the Collaborative Antiviral Study Group has just initiated a study in which this issue will be clarified and also the efficacy or otherwise of a 90 day course of oral valacyclovir after 14 days of acyclovir treatment will be

determined. Thus this practice could become standard in the future. For CMV encephalitis, particularly prominent in HIV infection, combination therapy with intravenous gancyclovir plus or minus foscarnet has been recommended,⁹ but there is not the evidence base in this condition that exists in the case of HSE therapy with acyclovir.

ACKNOWLEDGEMENTS

I wish to thank Professor Larry Davis for very helpful discussions and his critical review of the manuscript.

REFERENCES

- 1 Whitley R, Laeman AD, Nahmias A, *et al*. DNA restriction enzyme analysis of herpes simplex virus isolates obtained from patients with encephalitis. *N Engl J Med* 1982;**307**:1060–2.
- 2 Johnston RT. *Viral infections of the nervous system*, 2nd ed. Philadelphia: Lippincott-Raven, 1998.
- 3 Fodor PA, Levin MJ, Weinberg A, *et al*. Atypical herpes simplex virus encephalitis diagnosed by PCR amplification of viral DNA from CSF. *Neurology* 1998;**51**:554–9.
- 4 Koskiniemi M, Rantalaiho T, Piiparinen H, *et al*. Infections of the central nervous system of suspected viral origin: a collaborative study from Finland. *J Neuroviral* 2001;**7**:400–8.
- 5 Solomon T. Recent advances in Japanese encephalitis. *J Neuroviral* 2003;**9**:274–83.
- 6 Johnson RT. Emerging viral infections of the nervous system. *J Neuroviral* 2003;**9**:140–7.
- 7 Davis LE. Diagnosis and treatment of acute encephalitis. *The Neurologist* 2000;**6**:145–59.
- 8 Coyle PK. Postinfectious encephalomyelitis. In: Davis LE, Kennedy PGE, eds. *Infectious diseases of the nervous system*, 1st ed. Butterworth-Heinemann, 2000:83–108.
- 9 Chaudhuri A, Kennedy PGE. Diagnosis and treatment of viral encephalitis. *Postgrad Med J* 2002;**78**:575–83.
- 10 Baringer JR. Herpes simplex virus encephalitis. In: Davis LE, Kennedy PGE, eds. *Infectious diseases of the nervous system*, 1st ed. Butterworth-Heinemann, 2002:139–64.
- 11 Kennedy PGE, Chaudhuri A. Herpes simplex encephalitis. *J Neurol Neurosurg Psychiatry* 2002;**73**:237–8.
- 12 Whitley RJ, Gnann JW. Viral encephalitis: familiar infections and emerging pathogens. *Lancet* 2002;**359**:507–14.
- 13 Cinque P, Cleator GM, Weber T, *et al*. The role of laboratory investigation in the diagnosis and management of patients with suspected herpes simplex encephalitis: a consensus report. *J Neurol Neurosurg Psychiatry* 1996;**61**:339–45.