

# PostScript

## LETTERS

### "Who came with you?" A diagnostic observation in patients with memory problems?

The importance of obtaining collateral history when assessing patients attending the neurology clinic complaining of memory difficulties is well known.<sup>1,2</sup> Patients developing amnesia in the context of Alzheimer's disease may underplay their difficulties because of cognitive anosognosia, whereas those with purely subjective memory complaints (the "worried well") may overemphasise difficulties. Memory complaint, preferably corroborated by an informant, is one of the suggested diagnostic criteria of mild cognitive impairment (MCI).<sup>3</sup> Misdiagnosis of memory complaints may occur when no collateral history is available.<sup>4</sup>

For these reasons, all patients referred to my cognitive function clinic are sent, as part of their clinic appointment letter, a request asking them to bring a relative, friend, or carer from whom additional clinical information may be obtained; this is printed in bold type and in a separate paragraph. Despite this, some patients attend the clinic alone. A study was undertaken to measure the diagnostic value of this observation.

As part of an audit of referrals over a 2 year period (September 2002 to August 2004 inclusive), attendance or non-attendance of a relative or friend at each consultation was noted. Diagnosis of dementia was based on DSM-IV criteria, established by clinical interview, neuropsychological assessment and structural neuroimaging. Diagnosis of dementia subtype (Alzheimer's disease, vascular dementia, dementia with Lewy bodies, frontotemporal dementia) and of MCI followed widely accepted diagnostic criteria. All patients had minimum follow up of 6 months.

Of 183 new referrals seen, 150 (82%; 95% confidence interval (CI) 76 to 88%) followed the written instruction in the clinic appointment letter and attended with a relative, friend or carer; the remaining 33 (18%; 95% CI 4 to 31%) attended alone. In this cohort, 90 patients were diagnosed with dementia and 93 were not demented; three had MCI. Of the 150 patients accompanied to the clinic, 90 (60%; 95% CI 52 to 68%) had dementia; of the 60 not demented, one had MCI. None of the 33 patients attending alone had dementia, although two had MCI.

Hence, if attending the clinic with a relative, friend, or carer (that is, following the instructions given in the appointment letter) were considered a diagnostic test for dementia, it would have a sensitivity of 100% (95% CI 96 to 100%, Wilson method), specificity of 35% (95% CI 26 to 46%), and positive and negative predictive values of 60% (95% CI 52 to 67%) and 100% (95% CI 90 to 100%) respectively. Positive likelihood ratio was 1.55 (95% CI 1.33 to 1.80, log method), judged unimportant, but negative likelihood ratio (0) was large.

Although not absolute, as those unaccompanied patients with MCI might yet evolve to dementia, the period of follow up for some patients is brief, and clinically established diagnoses may require revision (for example, when neuropathological data become available), these findings nevertheless support the belief that attending the neurology clinic alone despite written instructions to the contrary is a robust sign of the absence of dementia.<sup>5</sup>

A J Larner

Cognitive Function Clinic, Walton Centre for Neurology and Neurosurgery, Liverpool, UK

Correspondence to: Dr A J Larner, Cognitive Function Clinic, Walton Centre for Neurology and Neurosurgery, Lower Lane, Fazakerley, Liverpool, L9 7LJ, UK; a.larner@thewaltoncentre.nhs.uk

doi: 10.1136/jnnp.2005.068023

Competing interests: none

### References

- 1 Tierney MC, Szalai JP, Snow WG, *et al*. The prediction of Alzheimer disease: the role of patient and informant perceptions of cognitive deficits. *Arch Neurol* 1996;**53**:423-7.
- 2 Carr DB, Gray S, Baty J, *et al*. The value of informant versus individual's complaints of memory impairment in early dementia. *Neurology* 2000;**55**:1724-6.
- 3 Petersen RC. Mild cognitive impairment as a diagnostic entity. *J Intern Med* 2004;**256**:183-94.
- 4 Larner AJ. Getting it wrong: the clinical misdiagnosis of Alzheimer's disease. *Int J Clin Pract* 2004;**58**:1092-4.
- 5 Matthews WB. *Practical neurology*, 3rd ed. Oxford: Blackwell Science, 1975:111.

### Laryngeal abductor paralysis can be a solitary manifestation of multiple system atrophy

Laryngeal abductor paralysis (LAP) and stridor are well known features that occur in over one third of patients with multiple system atrophy (MSA).<sup>1</sup> The pathogenesis of LAP is thought to be crico-arytenoid abductor muscle denervation,<sup>2</sup> although there is a lack of consistent evidence of motor cell loss in the nucleus ambiguus.<sup>3</sup> More recently, dystonia of the laryngeal adductor muscle has also been proposed.<sup>4</sup> LAP/stridor usually occurs in the advanced stages of the disease,<sup>5</sup> and is considered to be a poor prognostic feature.<sup>1,2</sup> In contrast, some MSA cases have shown LAP initially, with most of these reported by otolaryngology departments.<sup>3-7</sup> However, there are no systematic surveys as to the extent to which MSA patients initially present with LAP. We describe the result of a survey of 200 MSA inpatients conducted in a neurology department.

We reviewed the case records of 200 consecutive "probable" MSA patients who met the inclusion and exclusion criteria.<sup>8</sup> They were 119 men and 81 women, mean age 60 years; 29 had the Parkinsonian form (MSA-P) and 171 the cerebellar form

(MSA-C). Among these, eight patients (4%) (four MSA-P, four MSA-C) were shown to have stridor as the initial manifestation (table 1). Stridor was the solitary manifestation in six of the patients, though it was combined with minimal laryngeal signs in two of these six patients (inspiratory gasp in one; hoarseness in one) and REM (rapid eye movement)-sleep related behavioural disorder ("night terror") in one. In the remaining two patients stridor occurred together with bladder dysfunction or gait ataxia. In the former six patients, stridor was followed by bladder dysfunction in four, constipation in three, tremor/akinesia in one, ataxia in one, and postural hypotension in one. The average interval between the development of stridor and these later symptoms and signs was 3.3 years (range 1 to 6). The average interval between stridor and hospital admission was 5.4 years (1-10). In all eight patients, laryngoscopy confirmed that the stridor was caused by LAP. The grade of LAP at the first admission to our hospital (table 1), according to Isozaki's laryngoscopy classification,<sup>9</sup> was moderate (abductor paresis during waking; paradoxical adduction during sleep) in three and severe (complete paralysis) in five. Among those patients, continuous positive airway pressure was introduced in three, laser incision of the vocal fold was carried out in one, and subsequent tracheostomy was necessary in five.

In the cases presented, it proved true that LAP/stridor can be a solitary manifestation of MSA. The interval between LAP/stridor and hospital admission was rather long (on average 5.4 years), suggesting that the progression of LAP was not very rapid in those patients. Although the initial presentation of LAP/stridor was not common (it occurred in only 4% of all MSA patients), it is clinically relevant because patients with LAP/stridor but without obvious neurological symptoms may see general physicians or otolaryngologists first. Laryngeal stridor also occurs because of local inflammation or tumours, or from distant causes that affect the vagal nerves, such as upper thoracic or nasopharyngeal carcinoma. If such conditions have been excluded, central neurological causes should be considered. Co-morbid bladder dysfunction (particularly urinary incontinence and post-voiding residual volume of more than 100 ml), postural and postprandial syncope, parkinsonism, and ataxia are all red flags suggestive of MSA.<sup>10</sup> In our eight patients, bladder dysfunction was an early sign and was chronologically correlated with LAP/stridor; this finding is in line with a previous report.<sup>9</sup> These atypical features for a local laryngeal pathology suggest that further studies of the brain are necessary to confirm the diagnosis of MSA.

A Uzawa, R Sakakibara, N Tamura, M Asahina, Y Yamanaka, T Uchiyama, T Ito, T Yamamoto, Z Liu, T Hattori  
Department of Neurology, Chiba University, 1-8-1 Inohana Chuo-ku, Chiba 260-8670, Japan

Correspondence to: Dr Ryuji Sakakibara; sakakibara@faculty.chiba-u.jp

**Table 1** Patients with multiple system atrophy who initially presented with laryngeal abductor paralysis/stridor

Patient*	Years from the onset of illness										Laryngoscopy findings†					
	0	1	2	3	4	5	6	7	8	9		10	11	12	13	
1. 62/M MSA-P	Laryngeal stridor						BD	Decreased sweating	Akinesia, cerebellar ataxia, PH		<b>Admission:</b> tracheotomy				++	
2. 74/F MSA-P	Laryngeal stridor					Constipation, BD, PH, akinesia		<b>Admission:</b> inspiratory gasp, hoarseness								+++
3. 83/F MSA-C	Laryngeal stridor, inspiratory gasp				Ataxic gait, BD, constipation				PH	<b>Admission:</b> tracheotomy						+++
4. 59/F MSA-C	Laryngeal stridor, RBD	Ataxic gait						<b>Admission:</b> CPAP > tracheotomy								++
5. 62/M MSA-C	Laryngeal stridor	Constipation, BD				<b>Admission:</b> ataxic gait, akinesia, inspiratory gasp; CPAP										+++
6. 57/F MSA-P	Laryngeal stridor, hoarseness	Hand tremor	Dysphasia			<b>Admission:</b> akinesia, ataxic gait, BD										+++
7. 53/M MSA-P	Laryngeal stridor, hoarseness, BD, erectile dysfunction, constipation	PH, decreased sweating, ataxic gait				<b>Admission:</b> laser incision > tracheotomy										++
8. 63/F MSA-C	Laryngeal stridor, ataxic gait	Admission														+++

\*Age, sex, diagnosis.

†Laryngeal abductor paralysis: +(mild), ++(moderate), +++(severe), Isozaki's classification.

AH], pnoea hypoxaemia index; BD, bladder dysfunction; CPAP, continuous positive airway pressure; F, female; HUT, head up tilt (60° for 10 min); M, male; MSA-C, cerebellar form of multiple system atrophy; MSA-P, parkinsonian form of multiple system atrophy; ODJ, oxygen desaturation index (dips per hour); PH, postural hypotension; RBD, REM sleep behavioural disorder; SAS, sleep apnoea syndrome.

doi: 10.1136/jnnp.2005.069344

Published Online First 9 June 2005

Competing interests: none declared

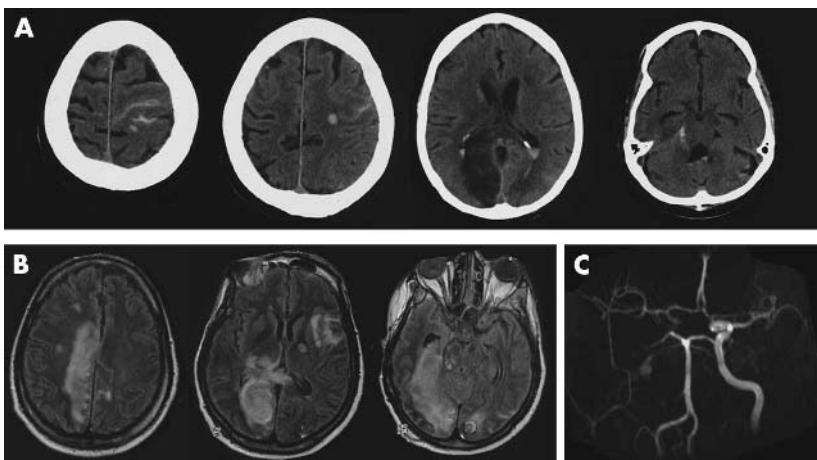
## References

- 1 **Wenning GK**, Tison F, Ben Shlomo Y, *et al*. Quinn NP. Multiple system atrophy: a review of 203 pathologically proven cases. *Mov Disord* 1997;12:133–47.
- 2 **Bannister R**, Gibson W, Michaels L, *et al*. Laryngeal abductor paralysis in multiple system atrophy. A report on three necropsied cases, with observations on the laryngeal muscles and the nuclei ambigu. *Brain* 1981;104:351–68.
- 3 **Isozaki E**, Matsubara S, Hayashida T, *et al*. Morphometric study of nucleus ambiguus in multiple system atrophy presenting with vocal cord abductor paralysis. *Clin Neuropathol* 2000;19:213–20.
- 4 **Isono S**, Shiba K, Yamaguchi M, *et al*. Pathogenesis of laryngeal narrowing in patients with multiple system atrophy. *J Physiol (Lond)* 2001;536:237–49.
- 5 **Martynovits G**, Leventon G, Goldhammer Y, *et al*. Vocal cord paralysis as a presenting sign in the Shy-Drager syndrome. *J Laryngol Otol* 1988;102:280–1.
- 6 **Kew J**, Gross M, Chapman P. Shy-Drager syndrome presenting as isolated paralysis of vocal cord abductors. *BMJ* 1990;300:1441.
- 7 **Hughes RG**, Gibbin KP, Lowe J. Vocal fold abductor paralysis as a solitary and fatal manifestation of multiple system atrophy. *J Laryngol Otol* 1998;112:177–8.
- 8 **Gilman S**, Low PA, Quinn N, *et al*. Consensus statement on the diagnosis of multiple system atrophy. *J Auton Nerv Syst* 1998;74:189–92.
- 9 **Isozaki E**, Miyamoto K, Osanai R, *et al*. Clinical studies of 23 patients with multiple system atrophy presenting with vocal cord paralysis. *Rinsho Shinkeigaku (Clinical Neurology)*. 1991;31: 249–54, (in Japanese with English abstract).
- 10 **Kirby R**, Fowler C, Gosling J, *et al*. Urethrovaginal dysfunction in progressive autonomic failure with multiple system atrophy. *J Neurol Neurosurg Psychiatry* 1986;49:554–62.

### Disseminated *Pseudallescheria boydii* infection successfully treated with voriconazole

A 56 year old, right handed African-American man with past history of left knee osteoarthritis, remote intravenous drug use, remote alcoholism, and seropositivity for hepatitis C was admitted to a local hospital for fatigue, chest pain, 13.6 kg weight loss, night sweats, and vision loss. On examination, a loud systolic murmur was present. An electrocardiogram (ECG) displayed T wave alternans and a transoesophageal echocardiogram revealed severe mitral regurgitation with mitral valve vegetations, ruptured chordae tendineae, and left ventricular ejection fraction of 75%. He was diagnosed as having endocarditis and cytomegalovirus endophthalmitis, and was treated with ceftriaxone, vancomycin, ganciclovir, foscarnet, aspirin, metoprolol, lisinopril, nifedipine, and intravenous esmolol. He developed fever (39.3°C) and his mental status declined. A head computed tomography (CT) scan showed left occipital haemorrhage. His left leg became cold and pale with an ankle:brachial index of 0.4. Blood cultures grew yeast. Amphotericin B was started and he was transferred to our hospital for further care.

Upon arrival his temperature was 36.4°C, pulse was 80 beats per minute and regular, respiratory rate was 25 per minute, and blood pressure was 106/76 mm Hg on the right and 160/83 mm Hg on the left. On auscultation a



**Figure 1** (A) Head computed tomography scan showing left parietal intraparenchymal, subarachnoid, and intraventricular haemorrhages, right middle cerebral and anterior cerebral arteries, bilateral posterior cerebral arteries and left insular artery ischaemic infarcts. (B) In addition, a brain magnetic resonance imaging (MRI) scan shows right thalamic and left internal capsule lacunes, and the initial left occipital ischaemic infarct with haemorrhage. (C) A magnetic resonance angiogram showing no flow in the right internal carotid artery.

II/VI holosystolic murmur over the apex and bibasilar rales were heard. His left leg was cold with pulses detectable only by Doppler. He was alert and oriented to person and place only, and recalled 1/3 items after short delay. His speech was fluent and well articulated. He had light perception on the right and was only able to count fingers centrally on the left. He displayed mild left leg weakness, normal reflexes and flexor plantar responses, mild right pronator drift, and diminished left sided proprioception. Ophthalmological examination disclosed dense bilateral vitreous infiltrates, retinal lesions, segmental retinal detachments, and scattered choroidal inflammation worse on the right. Flucytosine was added.

An ECG revealed a prolonged QT interval, Q waves in II, III, and AVF leads, and signs of left ventricular hypertrophy. The laboratory studies revealed a white blood cell count of 25 600/ $\mu$ l with 69% neutrophils, 23% lymphocytes, 6% monocytes, 1% eosinophils, and 1% bands; haematocrit, 30%; platelets, 207 000/ $\mu$ l; troponin T, negative; aspartate aminotransferase (AST) and alanine aminotransferase (ALT), mildly elevated at 79 U/l and 99 U/l, respectively (a finding attributed to active hepatitis C); alkaline phosphatase 96 U/l; and the erythrocyte sedimentation rate (ESR) 26 mm/hr. Serological examination for human immunodeficiency virus (HIV) was negative.

A thoracoabdominal CT scan disclosed a 2×2 cm mass in the right subclavian and common carotid arteries and a right renal infarct. The left iliac artery was occluded. Intravenous heparin, in attempt to salvage the left leg, resulted in left parietal subarachnoid, intraparenchymal, and intraventricular haemorrhages. The causative organism was identified as *Pseudallescheria boydii* resistant to amphotericin, flucytosine, and fluconazole. On day 13 voriconazole was begun. He underwent urgent mitral valve replacement and left superior and profunda femoral, and iliac embolectomy. Heparin was discontinued, and he remained in prolonged coma. A head CT scan displayed new right frontoparietal, right anterior cerebral artery (ACA), right posterior cerebral artery (PCA) and

bilateral small cerebellar infarcts (fig 1A). A follow up brain magnetic resonance imaging (MRI) scan revealed several new small left frontal and parietal haemorrhages and ischaemic infarcts of the right thalamus, ACA, and PCA along with the left insula, basal ganglia, and parietal lobe (fig 1B). The right internal carotid artery was occluded (fig 1C). The findings were attributed to infectious emboli and haemorrhaging from mycotic aneurysms.

On day 38 of hospitalisation the patient's coma resolved. He was eventually able to follow simple commands, and sit and stand, although expressive aphasia and left hemiparesis remained. His vision improved to 20/800 on the left. He was subsequently discharged to a long term care facility.

### Discussion

*Pseudallescheria boydii* (anamorph or asexual phase: *Scedosporium apiospermum*) is a ubiquitous saprophytic fungus commonly found in soil, manure, decaying vegetation, and polluted water. Its commonest clinical presentation in the USA is as mycetoma, a chronic limited subcutaneous infection in immunocompetent individuals engendered by minor trauma, and is characterised by grain formation and local tissue destruction.<sup>1</sup> However, *P. boydii* has recently emerged as an agent of invasive fungal disease as well, a phenomenon linked to the increasing prevalence of immunosuppression in the community.<sup>1–3</sup> Although endocarditis and endophthalmitis have been described,<sup>1</sup> lung, bone, joint, or central nervous system (CNS) involvement is more typical of this organism.<sup>4</sup> Infections are classically acquired through penetrating trauma<sup>1</sup> or massive inoculation through inhalation, such as may occur in near drowning in stagnant or polluted water.<sup>3</sup> Disease subsequently results from contiguous extension and haematogenous dissemination. It is likely that our patient acquired his infection through prior intravenous drug use, resulting in endocarditis with secondary dissemination to eye, kidney, extremities, and brain.

Among the various types of invasive fungal disease attributable to *P. boydii*, survival rates

appear to be particularly poor with central nervous system and/or valvular involvement. A relatively recent literature review revealed that of 39 patients with documented CNS disease, only nine were known to have survived<sup>3</sup>; no prior reports exist of survivors of endocarditis.<sup>1</sup> Intrinsic resistance to amphotericin B, a mainstay in the treatment of most invasive fungal diseases including aspergillosis and mucormycosis, has been reported repeatedly, a trait undoubtedly associated with poor survival in patients in whom the diagnosis is delayed.<sup>1-3</sup> We describe the first immunocompetent survivor from *P. boydii* native valve endocarditis complicated by multiple ischaemic and haemorrhagic strokes and peripheral embolisation.

Successful treatment of invasive disease due to *P. boydii* hinges upon surgical resection with institution of appropriate antifungal therapy. Miconazole, an imidazole derivative used topically for many dermatophyte infections, was previously the treatment of choice in the light of this organism's resistance to many commonly used systemic antifungals, including amphotericin B and fluconazole. However, its poor CNS penetration,<sup>3</sup> toxicity profile, and unavailability in the USA as an intravenous formulation<sup>1-3</sup> render it less than desirable. Of the azole antifungals, voriconazole, a newly licensed triazole derivative, appears to be the most viable due to its spectrum of activity and excellent CNS penetration. It is steadily becoming the treatment of choice.<sup>3</sup> Although both itraconazole and ketoconazole have been used successfully in treatment of pulmonary pseudallescheriasis,<sup>3</sup> their poor CNS penetration significantly impairs their therapeutic utility in the treatment of brain abscess.

#### L G Apostolova

Department of Neurology, University of California, Los Angeles, CA, USA

#### E K Johnson

Saint Luke's Hospital, Chesterfield, MO, USA

#### H P Adams Jr

Department of Neurology, University of Iowa, Iowa City, IA, USA

Correspondence to: Dr L G Apostolova, Tichi Wilkerson-Kassel Dementia Fellow, Department of Neurology, University of California at Los Angeles, Reed Neurological Research Center 2-238, 710 Westwood Plaza, Los Angeles, CA 90095, USA; lapostolova@mednet.ucla.edu

The patient described in this letter consented to his details being published

doi: 10.1136/jnnp.2005.067322

Competing interests: none declared

#### References

- O'Bryan TA, Browne FA, Schonder JF. *Scedosporium apiospermum* (*Pseudallescheria boydii*) endocarditis. *J Infect* 2002;**44**:189-92.
- Munoz P, Marin M, Tornero P, et al. Successful outcome of *Scedosporium apiospermum* disseminated infection treated with voriconazole in a patient receiving corticosteroid therapy. *Clin Infect Dis* 2000;**31**:1499-501.
- Nesky MA, McDougal EC, Peacock JE Jr. *Pseudallescheria boydii* brain abscess successfully treated with voriconazole and surgical drainage: case report and literature review of central nervous system pseudallescheriasis. *Clin Infect Dis* 2000;**31**:673-7.
- Travis LB, Roberts GD, Wilson WR. Clinical significance of *Pseudallescheria boydii*: review of

10 years' experience. *Mayo Clin Proc* 1985;**60**:531-7.

- Dworzack DL, Clark RB, Borkowski WJ Jr, et al. *Pseudallescheria boydii* brain abscess: association with near-drowning and efficacy of high-dose, prolonged miconazole therapy in patients with multiple abscesses. *Med (Baltimore)* 1989;**68**:218-24.

### Ocular tilt reaction and anterior inferior cerebellar artery syndrome

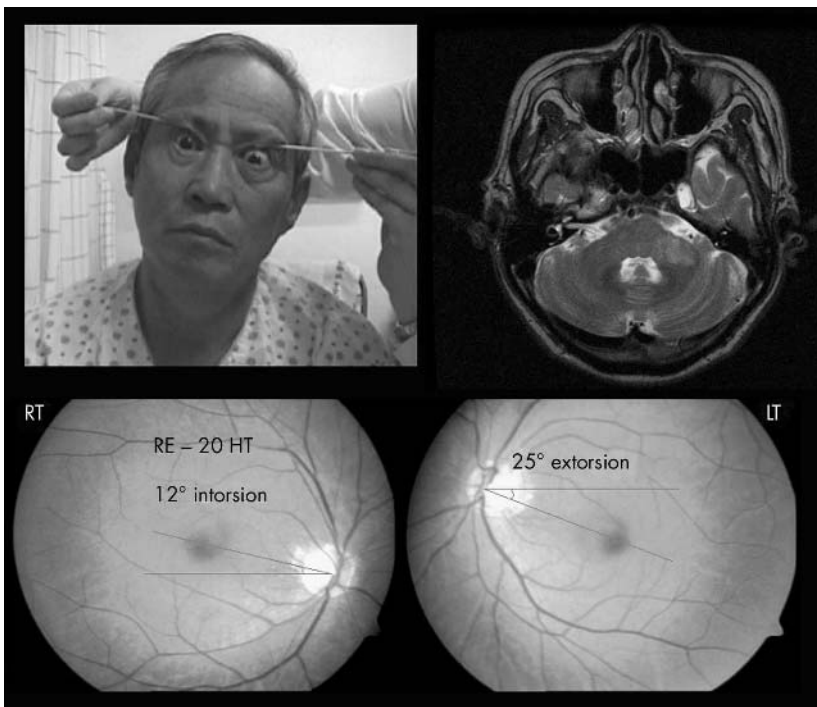
The ocular tilt reaction (OTR) is an eye-head postural reaction consisting of ipsilateral head and neck tilt, skew deviation, and ocular torsion. OTR indicates either a unilateral peripheral vestibular deficit (inner ear or vestibular nerve) or a unilateral lesion of brain stem pathways from the vestibular nuclei to the interstitial nucleus of Cajal in the rostral midbrain.

The anterior inferior cerebellar artery (AICA) supplies the lateral inferior pontine tegmentum and middle cerebellar peduncle, vestibulocochlear nerve including the root entry zone, inner ear, and anterior inferior cerebellum.<sup>1</sup> Although there has been one report of skew deviation owing to an AICA infarction,<sup>1</sup> the cardinal features of the OTR have not previously been documented. We describe two patients with AICA infarction, each of whom had ipsiversive OTR—one with complete OTR, the other with skew deviation and tonic ipsiversive ocular torsion.

The first was a 58 year old man with long standing hypertension who presented with sudden vertigo and imbalance. On neurological examination, he had bilateral gaze evoked horizontal nystagmus, left peripheral facial weakness and numbness, dysmetria of

the left limbs, and gait ataxia. There was no caloric response on the left side. Pure tone audiometry showed 65 dB sensorineural hearing loss on the left side. The subjective visual vertical with binocular viewing was tilted 17 degrees to the left (that is, counterclockwise from the patient's point of view). Fundus photography showed 25° extorsion of the left eye and 12° intorsion of the right eye. He had a skew deviation with a right hypertropia of 20 prism diopters in primary gaze (fig 1). Magnetic resonance imaging (MRI) including diffusion images showed acute infarcts in the left middle cerebellar peduncle and the left lateral inferior pontine tegmentum (fig 1).

The second patient was a 58 year old woman with type 2 diabetes mellitus and hypertension who developed severe vertigo, hearing loss, tinnitus on the left side, dysarthria, and imbalance. She had bilateral gaze evoked nystagmus with a horizontal-rotatory component. There was left peripheral facial weakness and numbness, dysmetria of the left limbs, and gait ataxia. Pure tone audiometry showed a 65 dB sensorineural hearing loss on the left side. Fundus photography showed 14° extorsion of the left eye and 3° extorsion of the right eye. Prism testing showed a skew deviation with a right hypertropia of 6 diopters in the primary position. Subjective visual vertical with binocular viewing was tilted 13° to the left (that is, counterclockwise from the patient's point of view). Caloric response was absent on the left side. MRI showed new infarcts in the left middle cerebellar peduncle, left lateral inferior pontine tegmentum, and anterior inferior cerebellum, possibly including the flocculus. Two months later the subjective visual vertical was normal. Fundus photography



**Figure 1** Tonic ocular tilt reaction in patient 1. Note sustained head tilt and concurrent vertical divergence of the eyes (skew deviation). T2 weighted axial magnetic resonance imaging of the brain showed acute infarcts in middle cerebellar peduncle and lateral inferior pontine tegmentum. There is conjugate leftward torsion of the eyes (that is, counterclockwise from the patient's point of view): a 25° extorsion of the left eye and a 12° intorsion of the right eye. HT, hypertropia; LT, left; RE, right eye; RT, right. Patient consent was obtained for publication of this figure.

now showed 1° of extorsion of the left eye, indicating that the left eye had been extorted by 13° at the first examination (that is, by 14° minus 1°) and 9° of extorsion of the right eye, indicating that at the first examination the right eye had in fact been intorted by 6° (that is, by 3° minus 9°).

**Comment**

Most earlier reports of AICA infarction have focused on the brain stem or cerebellar findings. Recently, there have been several reports describing the clinical importance of inner ear symptoms, vertigo and/or sudden deafness.<sup>2-3</sup> However, a detailed description of OTR as a sign of AICA infarction has not been reported previously.

OTR, a sign of vestibular dysfunction in the roll plane, is characterised by a triad of conjugate ocular torsion, skew deviation, and head tilt. It results from destructive or irritative lesions of central or peripheral graviceptive vestibular pathways. Although head tilt is a common component of OTR, skew deviation with conjugate ocular torsion often occurs without head tilt as in our patient. Thus the pathophysiology of a partial OTR (that is, skew deviation and conjugate ocular torsion without head tilt) is the same as that of a complete OTR, and skew deviation with conjugate ocular torsion is sufficient for the diagnosis of OTR.

In addition to lesions of the central and peripheral vestibular pathways conveying graviceptive signals, lesions of the cerebellum may also result in OTR. Skew deviation is commonly seen with cerebellar infarction. Mossman and Halmagyi described two patients with cerebellar stroke, presumably in the territory of the posterior inferior cerebellar artery, who had tonic conjugate ocular torsion without associated head tilt.<sup>4</sup> These investigators speculated that interruption of nodular inhibitory projections to graviceptive neurones in the ipsilesional vestibular nuclei may have accounted for the contraversive conjugate ocular torsion.<sup>4</sup>

Sensorineural hearing loss and canal paresis to caloric stimulation on the left side clearly indicated involvement of the peripheral audio-vestibular system. Ipsiversive OTR with acute peripheral vestibular lesions was described in a previous report.<sup>3</sup> Considering the direction of OTR and known vascular anatomy of the AICA, damage to the inner ear or the root entry zone of the eighth nerve probably accounts for the ipsilesional OTR with AICA infarction.

In conclusion, this is the first report of well documented OTR with AICA infarction. The ipsiversive OTR in these patients probably resulted from infarction of the inner ear or the root entry zone of the eighth nerve.

**Acknowledgements**

This study was supported by grants of the Oriental Medicine R&D Project (03-PJ9-PG6-S002-0001), Ministry of Health and Welfare, Republic of Korea.

**H Lee**  
Department of Neurology, Keimyung University School of Medicine, 194 Dongsan dong, Daegu, 700-712, South Korea

**S-Y Lee**  
Department of Ophthalmology, Keimyung University School of Medicine

**H Lee, S-R Lee**  
Brain Research Institute, Keimyung University School of Medicine

**B-R Park**  
Department of Physiology, Medicine and Hanbang Brain Disease Research Centre, Wonkwang University School of Medicine, Iksan, South Korea

**R W Baloh**  
Department of Neurology, UCLA School of Medicine, Los Angeles, California, USA

Correspondence to: Dr Hyung Lee; hlee@dsmc.or.kr

doi: 10.1136/jnnp.2005.069104

Competing interests: none declared

Patient consent was obtained for publication of figure 1

**References**

- 1 **Oas JG, Baloh RW.** Vertigo and the anterior inferior cerebellar artery syndrome. *Neurology* 1992;**42**:2274-9.
- 2 **Lee H, Whitman GT, Lim JG, et al.** Bilateral sudden deafness as a prodrome of anterior inferior cerebellar artery infarction. *Arch Neurol* 2001;**58**:1287-9.
- 3 **Lee H, Sohn II, Jung DK, et al.** Sudden deafness and anterior inferior cerebellar artery infarction. *Stroke* 2002;**33**:2807-12.
- 4 **Mossman S, Halmagyi M.** Partial ocular tilt reaction due to unilateral cerebellar lesion. *Neurology* 1997;**49**:491.
- 5 **Safran AB, Viber D, Issoua D, et al.** Skew deviation following vestibular neuritis. *Am J Ophthalmol* 1994;**118**:238-45.

**Video assessment of rTMS for Tourette syndrome**

In a recent study, subthreshold 1 Hz repetitive transcranial magnetic stimulation (rTMS) over left motor or premotor cortex failed to improve tics in patients with Gilles de la Tourette syndrome (GTS) as determined by self assessment scores.<sup>1</sup> However, video ratings of this study had not been analysed. Here, we present the results of blinded analysis of the video of GTS patients who participated in the previous study. We show that rTMS has a placebo effect and confirm that low intensity motor or premotor rTMS does not have a specific effect on tics in GTS.

In a placebo controlled cross-over study of 16 patients with GTS, subthreshold 1 Hz rTMS (2400 stimuli delivered on 2 consecutive days) were applied under three conditions in random order: left motor, left premotor, and left motor sham stimulation. Videotapes were recorded before and after each rTMS intervention in eight patients. One of the authors (AHS) who did not know the patients and was blinded to the treatment conditions, rated the video recordings. Data were analysed using two different rating scales, the Modified Rush Video Scale

(MRVS)<sup>2</sup> and an ‘‘Adapted Yale’’ Video Scale (AYVS) which was developed for this study. With the MRVS, the following five tic domains are rated from 0 to 4 according to severity: number of body areas involved with tics, motor tic severity, phonic tic severity, frequency of motor tics, and frequency of phonic tics. The sum of the five domain scores provides a total tic impairment score (0-20). As the MRVS does not consistently score the complexity, intensity, and interference of tics, we devised an additional scale using the categories of the Yale Global Tic Severity Scale (YGTSS).<sup>3</sup> This new scale, the AYVS, rated the following five domains from 0 to 5 according to severity: number of different tics, frequency of tics, intensity of tics, complexity of tics, and interference of tics. Each domain was rated separately for motor and vocal tics. The sum of the five domains gave a total motor tic score and a total vocal tic score; these scores combined yielded the total tic impairment score (0-50).

Tics were partially, albeit non-significantly, suppressed following each of the three interventions (table 1 and fig 1, two factorial repeated measures ANOVA with the factors time and rTMS). However, the effect of active rTMS did not exceed the effect observed following sham stimulation. rTMS effects in this study were variable and tic scores showed a regression towards the mean, that is patients with high scores at baseline tended to have lower scores after the rTMS intervention, and vice versa (univariate ANOVA with the difference in video score before and after rTMS as dependent factor and baseline scores as covariant). In other words, the changes of tic severity that we observed most likely reflect the waxing and waning course of tics rather than an intrinsic rTMS effect.

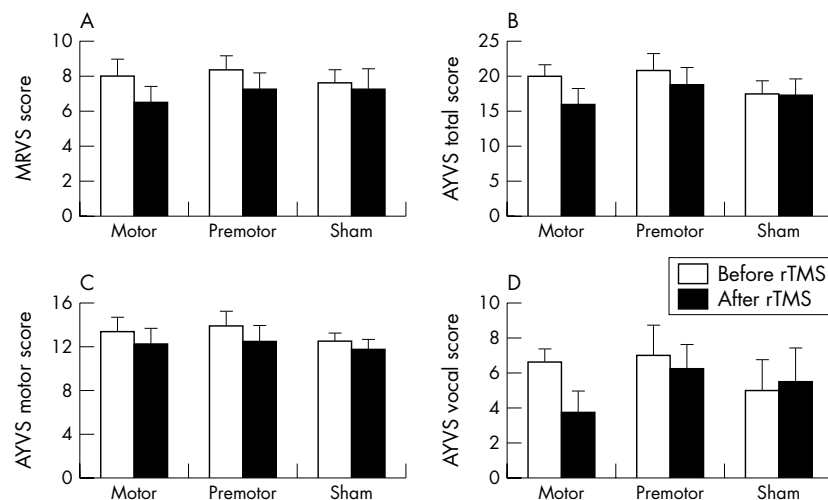
The results of this video assessment are in keeping with patients’ self assessment based on the Motor tic, Obsessions and compulsions, Vocal tic Evaluation Survey (MOVES),<sup>4</sup> a self rating scale that patients completed before and after rTMS.<sup>1</sup> Neither motor and vocal tic subscales nor obsession and compulsion subscales were changed by rTMS, which indicates that rTMS as used in the present study is not an effective treatment for tics or obsessions/compulsions in GTS patients. However, because ADHD symptoms were not assessed, we cannot exclude the fact that rTMS as used in the present study might have an effect on ADHD.

There was good correlation between the MRVS and the AYVS ( $\rho=0.69$ ;  $p<0.01$ , Spearman’s correlation). The AYVS thus

**Table 1** Mean differences (before and after rTMS) and confidence intervals of clinical scores

Score	Motor rTMS	Premotor rTMS	Sham rTMS
MRVS total score			
Mean difference	1.5	1.1	0.4
95% CI	-0.8 to 3.8	-0.5 to 2.8	-1.2 to 2.0
AYVS total score			
Mean difference	4	2.1	0.3
95% CI	-0.3 to 8.3	0.2 to 4.0	-2.6 to 3.1
AYVS motor score			
Mean difference	1.1	1.4	0.8
95% CI	-1.3 to 3.5	0.5 to 0.9	-0.9 to 2.4
AYVS vocal score			
Mean difference	2.9	0.8	-0.5
95% CI	0.4 to 5.3	-1.1 to 2.6	-2.4 to 1.4

AYVS, Adapted Yale Video Scale; CI, confidence interval; MRVS, Modified Rush Video Scale.



**Figure 1** Video scores before and after each intervention (means and standard error of the mean). (A) Modified Rush Video Scale (MRVS) total score; (B) Adapted Yale Video Scale (AYVS) total score; (C) AYVS motor score; (D) AYVS vocal score.

appears to be a valid and comprehensive tool to assess tic severity in GTS patients, but it needs to be evaluated further.

We conclude that left motor or premotor low intensity 1 Hz rTMS does not improve tics in GTS patient as assessed by blinded video scoring. Further studies, perhaps using higher intensity rTMS, longer rTMS trains, or bilateral stimulation, are needed to delineate the usefulness of rTMS in GTS patients. In these studies, blinded and independent video rating should be used.

### Acknowledgements

The authors thank all patients who participated in this study.

#### A H Snijders

Sobell Department of Neurophysiology, Institute of Neurology, Queen Square, London, UK

#### B R Bloem

Department of Neurology, University Medical Centre St Radboud, Nijmegen, The Netherlands

#### M Orth, J C Rothwell

Sobell Department of Neurophysiology, Institute of Neurology, Queen Square, London, UK

#### M R Trimble, M M Robertson

Department of Neuropsychiatry, The National Hospital for Neurology and Neurosurgery, London, UK

#### A Münchau

Sobell Department of Neurophysiology, Institute of Neurology, Queen Square, London, UK

Correspondence to: Dr Alexander Münchau, Department of Neurology, University Medical Centre Hamburg-Eppendorf, Martinistrasse 52, 20246 Hamburg, Germany; muenchau@uke.uni-hamburg.de

doi: 10.1136/jnnp.2004.058321

A Münchau and M Orth were supported by the Tourette Syndrome Association (USA) and the Raymond Way Unit, Institute of Neurology, Queen Square, London, UK. AH Snijders was supported by the Hersensichting Nederland

Competing interests: none declared

### References

- 1 Münchau A, Bloem BR, Thilo KV, *et al*. Repetitive transcranial magnetic stimulation for Tourette syndrome. *Neurology* 2002;59:1789–91.
- 2 Goetz CG, Pappert EJ, Louis ED, *et al*. Advantages of a modified scoring method for the Rush Video-Based Tic Rating Scale. *Mov Disord* 1999;14:502–6.
- 3 Leckman JF, Riddle MA, Hardin MT, *et al*. The Yale Global Tic Severity Scale: initial testing of a clinician-rated scale of tic severity. *J Am Acad Child Adolesc Psychiatry* 1989;28:566–73.
- 4 Gaffney GR, Sieg KG, Hellings JC. The MOVES: a self-rating scale for Tourette's syndrome. *J Child Adolesc Psychopharmacol* 1994;4:269–80.

### A case of superior cerebellar artery syndrome with contralateral hearing loss at onset

Deafness is rare in ischaemic stroke but sometimes occurs as a result of lower pons infarction. The main cause of such deafness is occlusion of the anterior inferior cerebellar artery (AICA); occlusion of the superior cerebellar artery (SCA), which perfuses the higher pons, causes SCA syndrome and also results in deafness but is extremely rare.<sup>1</sup> In the present report, we describe a patient with SCA syndrome, whose initial complaint was contralateral hearing loss.

### Case report

A 64 year old male with untreated hyperglycaemia and hypertension was admitted 4 h after the sudden onset of deafness in his right ear. Hearing loss was the only complaint and other neurological signs were absent. Right sensorineural hearing loss was revealed by a hearing test (fig 1A). After several examinations including stapedial reflexes and speech discrimination, an initial diagnosis of sudden deafness was made. However, 8 h later the patient complained of diplopia, vertigo, and nausea. Impaired abducens function in the right eye and bilateral lateral gaze nystagmus were observed. Finger-nose and heel-knee tests suggested left cerebellar ataxia. Hence, a diagnosis of SCA syndrome was made, and argatroban, an anti-coagulant, was adminis-

tered. Diffusion weighted magnetic resonance imaging (MRI) 12 h after onset showed infarctions in the left cerebellum (fig 1B) and lateral superior pons (fig 1C). Magnetic resonance angiography showed loss of blood flow in the lower basilar artery (fig 1D). Respiratory failure developed 4 h later, and the next day the patient also showed right hemiparesis and Horner's syndrome. Bilateral cortical blindness was also present. A diagnosis of SCA syndrome with hemiparesis and cortical blindness was made. A fluid attenuated inversion recovery (FLAIR) image 2 weeks later showed an enlarged infarction in the left cerebellum, and a new infarction in the right cerebellum, dorsal pons, and bilateral occipital lobes (fig 1E). The patient's symptoms remained unchanged 3 months later.

### Discussion

SCA syndrome shows ipsilateral cerebellar ataxia and Horner's syndrome, contralateral superficial sensory disturbance and hearing loss, as well as nystagmus toward the impaired side, vertigo, and nausea.<sup>2</sup> Fibres from the contralateral auditory nucleus join the lateral lemniscus, pass into the brain, and terminate in the hearing centre. Therefore, impairment of the lateral lemniscus on one side causes hearing loss on the other. In SCA infarction, the ischaemic lesion occurs in the area where fibres from the nucleus have already crossed, and therefore sensory hearing loss is observed in the contralateral side.

We describe a rare case of SCA syndrome which began with deafness in one ear. Although deafness sometimes occurs as a result of brainstem infarction, most cases of ipsilateral hearing loss are due to AICA infarction.<sup>3</sup> To our knowledge, the study by Doyle *et al* is the only previous report of hearing loss due to contralateral SCA infarction.<sup>1</sup> Amarenco *et al* described a large series of SCA syndrome cases, where no patient showed contralateral deafness.<sup>4</sup> The present report presents an important finding regarding symptoms of ischaemic stroke, and suggests that hearing loss, although rare, can be the first symptom. It is necessary to carefully observe patients with sudden deafness.

#### T Murakami, Y Ono, N Akagi, E Oshima, Y Hamakawa, N Omori

Department of Neurology, National Hospital Organization Okayama Medical Center, Okayama, Japan

#### M Shoji

Department of Neurology, Okayama University Graduate School of Medicine and Dentistry, Okayama, Japan

#### Y Hayashi

Department of Neurology, National Hospital Organization Okayama Medical Center, Okayama, Japan

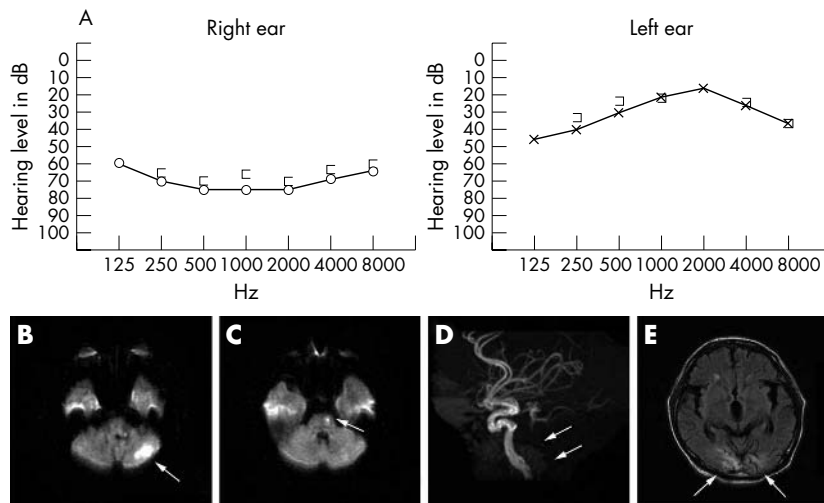
#### K Abe

Department of Neurology, Okayama University Graduate School of Medicine and Dentistry, Okayama, Japan

#### Y Manabe

Department of Neurology, National Hospital Organization Okayama Medical Center, Okayama, Japan

Correspondence to: Dr Tetsuro Murakami, Department of Neurology, Okayama University Graduate School of Medicine and Dentistry, 2-5-1 Shikata-cho, Okayama 700-8558, Japan; neuron@cc.okayama-u.ac.jp



**Figure 1** (A) Right sensorineural hearing loss. “o” and “x” indicate air conduction without masking in the right and left ears, respectively. “|” and “|” indicate bone conduction with masking in the right and left ears, respectively. (B, C) Axial diffusion weighted MRI images (B, C) 12 h after the onset of deafness. Note high signal intensity at the left cerebellum (B, arrow) and left lateral superior pons (C, arrow). (D) Magnetic resonance angiography showing occlusion of the lower basilar artery (arrows). (E) Axial FLAIR showing high intensity areas at both occipital lobes (arrows).

The patient described in this letter consented to his details being published

doi: 10.1136/jnnp.2004.058735

Competing interests: none declared

**References**

- Doyle KJ, Fowler C, Starr A. Audiologic findings in unilateral deafness resulting from contralateral pontine infarct. *Otolaryngol Head Neck Surg* 1996;114:482-6.
- Mills CK. Hemianesthesia to pain and temperature and loss of emotional expression on the right side, with ataxia of the upper limbs on the left. The symptoms probably due to a lesion of the thalamus or superior peduncles. *J Nerv Ment Dis* 1908;35:331-2.
- Lee H, Sohn SI, Jung DK, et al. Sudden deafness and anterior inferior cerebellar artery infarction. *Stroke* 2002;33:2807-12.
- Amarenco P, Hauw JJ. Cerebellar infarction in the territory of the superior cerebellar artery: a clinicopathologic study of 33 cases. *Neurology* 1990;40:1383-90.

**BOOK REVIEWS**

**Myology, third edition**

Edited by Andrew G Engel, Clara Franzini-Armstrong. New York: Published by McGraw-Hill, 2004, \$395.00 (hardback), pp 1960. ISBN 0-07-137180X.

This is the third edition of an established two volume text covering all aspects of human muscle disease. Since the second edition in 1994 rapid advances in the molecular genetic understanding of a range of muscle diseases have occurred. Indeed some diseases, such as muscle channelopathies, have only been fully recognised as distinct entities during this period. These huge advances are reflected in a complete and up-to-date revision. Myology

contains 70 chapters divided into three parts: Part 1, Scientific basis of muscle disease; Part 2, General approaches to neuromuscular disease; and Part 3, Diseases of muscle. All chapters are well constructed and written by authorities in each field. It is likely to be parts 2 and 3 that are of most interest to the readers of the *JNNP*. Part 2 is full of practical information. In particular the chapters on clinical examination and electrodiagnosis will be of interest to clinicians frequently encountering patients with neuromuscular symptoms and will also be valuable for trainees. Also in part 2 is an informative chapter on the evolving clinical uses of imaging in the investigation of muscle disease. It seems clear that MRI is going to play an increasing role in the evaluation of muscle diseases in the future. Part 3 contains comprehensive chapters on all of the known human muscle diseases. More genes have been discovered in the area of muscle disease than in virtually any other area within neurology in the past few years. This is reflected in the fact that 21 of the 30 chapters describing individual muscle diseases are given over to genetic disorders, including the muscular dystrophies, congenital myopathies, muscle channelopathies, genetic inclusion body myopathies, and the metabolic myopathies. I found it difficult to fault any of these chapters. The continuing challenges involved in understanding the molecular pathogenesis of and in treating the inflammatory myopathies are well covered. The final seven chapters of part 3 cover disorders of neuromuscular transmission, neuropathies, and neuronopathies. Myology the third edition must have been a mammoth task to produce and the editors are to be congratulated. I think there is plenty of accessible information, of practical use for clinicians and trainees dealing with muscle disease. I can thoroughly recommend this text.

M G Hanna

**Essential Neurology, 4th edition**

Edited by Iain Wilkinson and Graham Lennox. Oxford: Oxford University Press, 2005, pp 268, £22.95 (softcover). ISBN 1405118679

**Lecture Notes: Neurology, 8th edition**

Edited by Lionel Ginsberg. Oxford: Oxford University Press, 2005, pp 184, £17.95 (softcover). ISBN 1405114371

What constitutes the “core knowledge” of neurology that all medical students should reasonably be expected to learn? This is a question that *Lecture Notes: Neurology* (LNN) and *Essential Neurology* (EN)—two stalwarts of the medical student library—continue to grapple with in their latest editions.

EN, longer but with fewer chapters than LNN, tackles subjects in greater depth (and hence claims to be a review text for MRCP), whilst LNN has greater breadth, with suggestions for extra reading and key points summarising each chapter. Both texts incorporate case histories, somewhat more successfully in EN if only because the answers are physically separate, encouraging readers to pause and think about each presentation. Illustrations seem more integral to the text in EN, but this volume does have some surprising typographical gaffes—for example, Brown-Séqard, L’Hermitte; Argyll Robertson with a hyphen. I enjoyed reading about “messy breakfast syndrome” and “Kellogg’s epilepsy” which, like “flying saucer syndrome”, are variant names for juvenile myoclonic epilepsy. Considering my experience of general neurological clinics, I would have valued more discussion in EN on “neurologically unexplained symptoms”, which seem so frequent, and a specific section on neurofibromatosis, the commonest monogenic disorder that I see, albeit rarely.

How should the undergraduate neurology text develop, assuming that it is not wholly superseded by internet browsing? Should there be more emphasis on expert consensus diagnostic criteria and management guidelines, rather than succinct qualitative descriptions of neurological conditions, facilitating pattern recognition, and their treatment? Should there be greater reference to the evidence base (and its inadequacies)—for example, citing of systematic reviews? These are issues to be addressed by the authors in future editions, but for now one has no hesitation in recommending either of these volumes to medical students, or both, since it would be invidious to choose one as “better”.

A J Larner

**A historical dictionary of psychiatry**

Edited by Edward Shorter. Oxford: Published by Oxford University Press, 2005, £30.50 (hardcover), pp 338. ISBN 0-19-517668-5

Edward Shorter is Professor of History of Medicine at the University of Toronto and this 338 page volume is claimed to be the first “Historical Dictionary of Psychiatry”. As always in alphabetical order, discovery of individual entries is easy and an index takes us to words embedded in the text, more in encyclopaedia fashion.

Neurology without physical signs? The neurologist may still feel this is adequate definition of psychiatry, particularly nowadays with so many publications that bring together works in

the fields of neurology, psychology, and psychiatry (take, for example, Adam Zeman's *Consciousness, a User's Guide*). Thus *Gestalt* merits its long entry and the wholeness of this book is enhanced by a guide to pronunciation of difficult names that is embedded in the text and thus for example, helpfully, we are given *HO-ka* for Alfred Erich *Hoche*. This is a sort of bibliographic essay that guides the writer and is a standard work the writer should have at his side. Several individuals in the Menninger family are grouped together and give us insight into the medical achievements of father and sons. Neurologists will not be surprised to find Jung and Kraepelin, and happily also stumble upon James Parkinson, Charcot, and Wernicke, each wearing his psychiatry hat. The electrical circuitry that binds our specialties includes an entry on Hitzig. Lest all this history become too much, the entries on anxiety and phobias cover a substantial seven pages. This volume will assist neurologists, psychologists, and psychiatrists in their quest for learning; medical authors should find it very handy indeed.

C Gardner-Thorpe

### The Auditory Cortex, A Synthesis of Human and Animal Research

Edited by Reinhard Konig, Peter Heil, Eike Budinger, Henning Scheich. Published by Lawrence Erlbaum Associates, New Jersey, 2005, £62.95 (hardcover), pp 493. ISBN 0-8058-4938-6

A spirit who hears me tapping/The five-sensed cane of mind

Amid such unguessed glories/That I am worse than blind.

H Kemp, *Blind*, 1919

Most clinical neurologists scarcely spare a thought for the auditory brain: it is what takes over where the VIII<sup>th</sup> nerve ends, and if they think of it at all, it is probably in connection with such exotic maladies as cortical deafness or curios like musical hallucinations. But by any criterion this is an interesting place – from pitch-difference limens it is but a few synapses to Mozart and Shakespeare.

I attended the scientific meeting that spawned this book, and so I had the odd experience while reading it of hearing in my mind's ear the cut and thrust of platform discussion petrified to the more sober exchanges of scientific prose. For the auditory neuroscientist, the book provides a state of the art overview of the field, refreshingly catholic in its scope. There are idiosyncrasies, but they are the quirks of luminaries, and all the more valuable for that. No question, then, that the book will please the crowd for whom it was intended. But is there anything for the neurologist?

Things start reassuringly enough in Part I ("Auditory cortical fields and their functions") with auditory cortex anatomy. This is truly a closed book for most clinicians, both figuratively and, because the cortex lies deep within the recesses of the Sylvian fissure, quite literally. A chapter on the neuro-behavioural study of auditory cortex reminds us that Ferrier, no less, used it to make fundamental claims about the organisation of the brain. We move on to voices, and speech: so far, so good. Part II ("Coding of sounds"),

with its heavy-duty electrophysiology, is more of a challenge; and yet the coding of sounds is a problem of the most fundamental scientific and philosophical interest. How on earth is it possible to reconstruct the world we hear from the one-dimensional flutter of two membranes? Part III ("Plasticity, learning and cognition") addresses the interface between the auditory cortex and experience. Confronted with a chapter about ferrets, perhaps the clinician will master an initial rising sense of alarm by recalling that this is the science that made possible the cochlear implant and may yet explain how cocktail parties work (or fail).

If neurologists should learn something here about bats, barn owls, or ferrets, it can't hurt. This book is a bracing corrective to the error, too often implicit in clinical practice as in daily life, that the eyes (human eyes, at that) are the sole windows of the brain. To paraphrase that poem of Kemp's, the unguessed glories of the auditory cortex remind us that the five-sensed cane of mind is, after all, five-sensed.

J Warren

### Mechanism and management of headache, seventh edition

Edited by James W Kance, Peter J Goadsby. Published by Elsevier, Philadelphia, 2005, £34.99 (hardback), pp 392. ISBN 0-7506-7530-6

As a general rule, it is safe to assume that any textbook entering a seventh edition does so on its merits and must be worth reading. The latest edition of the classic *Mechanism and Management of Headache* by Lance and Goadsby does not disappoint. It is occasioned not just by the passage of time but also by advances in the field of headache that make a new edition necessary. Among these, the long-awaited revision of the International Classification of Headache Disorders is the most important, as it has created some entirely new headache entities and significantly altered criteria for others.<sup>1</sup> New information about the structural consequences of seemingly benign headache disorders – iron deposition in the brainstem, an increased prevalence of clinically silent ischaemic brain lesions in migraineurs, for example – and impressive gains in understanding of the basic pathophysiology of headache also demand explication for practising physicians. So too do new "hot topics" such as the possible connection between patent foramen ovale and aura, or the use of nerve stimulators to treat various forms of headache. And finally, the treatment landscape for many headache disorders, notably migraine, has changed considerably since publication of the sixth edition: new triptans, the advent of topiramate for prophylaxis, the increasing popularity of preemptive treatments for menstrual migraine, to name just a few.

Readers who turn to this book for up to the minute information about the pathophysiology of headache, research advances, and the latest treatment recommendations will find it all here, as the book has been thoroughly and thoughtfully updated. That this has been done without sacrificing the time-tested features of the previous editions is a credit to the authors and editors. In particular, the delightful, personable voice of Dr Lance remains recognisable in many of the

chapters, especially those dealing with the general approach to the patient, while Dr Goadsby's scientific authority shows plainly in chapters dealing with pathophysiology. Dr Lance's preface to the first edition has been retained, and is a delight to read: the good natured, sensible, still-relevant advice of a master clinician. Readers should take note of the impressive, ever-expanding list of scientific collaborators and scholarly heirs to the incredibly productive Lance-Goadsby headache dynasty. With the publication of this edition, the list has expanded from 35 to 53, and contains the names of many of headache's best and brightest. There is no better testament to the enduring legacy and influence of both authors.

The new edition is slightly smaller than the previous one, and the cover design has been updated. Those are cosmetic changes only, but appreciated nonetheless. Chapter titles and order have not been changed, save for the welcome insertion of a new chapter on chronic daily headache. The book begins with an historical overview of headache that serves as a useful reminder of just how far we have come from the days when holes were drilled in the skull to relieve headache. Throughout the book, photographs have been updated or replaced, and in general are clearer than those in previous editions. Horner's syndrome, third nerve palsy, and other physical findings are nicely and usefully illustrated, and are a true asset to the chapter on examination.

Not unexpectedly, the chapters dealing with headache classification and pathophysiology have undergone the most extensive revision. Updated, timely information about natural treatments has also been added, reflecting the reality of patient interest and enthusiasm for such things. A new table on clinical stratification of acute, specific migraine therapies has been added to the treatment chapter, and other tables in this chapter are more carefully organised, larger, and more readable than those in previous editions. A small oversight is the retention of the older term "tension headache" in many places – perhaps done to save space, but if so at the expense of the subtle but important implications conveyed by the longer term "tension-type."

E Loder

### Reference

- 1 The International Classification of Headache Disorders, 2<sup>nd</sup> Edition. *Cephalalgia* 2004;24(Suppl 1):1-160.

### Oxford handbook of psychiatry

Edited by David Semple, Roger Smyth, Jonathan Burns, Rajan Darjee, Andrew McIntosh. Published by Oxford University Press, Oxford, 2005, £24.95, pp 953. ISBN 0-19-852783-7

### Psychiatry, third edition, Oxford core texts

Edited by Michael Gelder, Richard Mayou, John Geddes. Oxford University Press, Oxford, 2005, £24.95 (softcover), pp 333. ISBN 0-19-852863-9

The *Oxford Handbook of Psychiatry* is a wonderful little book. The "little" applies to its size



and not its stature, as it is actually over 900 pages long and packed with a wealth of useful and interesting information. There has clearly been a tremendous amount of effort put into its production including the piloting of various versions with local SHOs. Although it is aimed primarily at the SHO, it would be a useful book for psychiatrists of all levels because it is so comprehensive. It provides discrete chapters for each type of psychiatric disorder, which contain key facts about the illness with a focus on management, both immediate and long term. These are preceded by several chapters on assessment and followed by a number of chapters devoted to specific considerations such as ethics and the law, how to deal with unusual situations, and therapeutics in specific circumstances such as pregnancy and co-morbid medical conditions. If that is not all, there are chapters devoted to the various types of psychotherapy and evidence-based psychiatry

and there are lists of useful contact addresses and websites, ICD10/DSMIV diagnostic codes, mental health act section codes, reference ranges for common blood and urine tests, and readily accessible instructions for rapid tranquillisation. Interspersed within this information are a number of "extras" in pink shaded boxes that add richness to the text and provide very enjoyable reading. Examples include a Shakespeare sonnet on death, a list of past and present famous people with an affective disorder, quotes from Kraepelin, and the story of Oedipus.

Another recent psychiatry publication from Oxford Press is the third edition of *Psychiatry*. This is an update of the well regarded text for medical undergraduates, GPs, and those requiring a general knowledge of psychiatry. The information is very well laid out in easily digestible sections. There are also more highlighted lists and tables than previous editions that serve to emphasise important

information or provide ready reference to aspects of assessment and management. This improved version is highly recommended to the non-specialist.

E Joyce

## CORRECTION

doi: 10.1136/jnnp.2004.059824corr1

D J Mahad, A Hellden, J Jarvis, *et al.* Aciclovir induced posterior leucoencephalopathy (*J Neurol Neurosurg Psychiatry* 2005;**76**:1308–9). The authors of this letter were mistakenly grouped according to their affiliations. The correct ordering of the authors is: D J Mahad, A Hellden, J Jarvis, D Mitra, A Gholkar, P F Chinnery.

# Volume 76 Assessors

The Editor is grateful to the following, who have assisted in the assessment of papers during the past year.

D Aarsland  
G Abbruzzese  
K Abe  
J Acheson  
L Ada  
M Adamaszek  
C Adler  
S Agapejev  
Y Agid  
N Agrawal  
J Y Ahn  
T Ala  
S Alamowitch  
A Albanese  
A Alberti  
M Alberts  
A Al-Chalabi  
M P Alexander  
J Alisky  
R Allan  
S Allder  
S Allen  
R Al-Shahi  
M Altieri  
J C Alvarez Uzabeaga  
T Alves  
A Amato  
M Aminoff  
P Anand  
F Andermann  
N Anderson  
S Anderson  
V Anderson  
N Andrews  
J Andrich  
C Angelini

J C Antoine  
A Antonini  
M D A S Antonio  
P Appellos  
D Araujo  
F Arbabi  
M Arena  
A Argyriou  
K Arimura  
C Armon  
E Arnaiz  
S Arnardottir  
P Arnett  
E Arnold  
M Arnold  
I Arnulf  
S Artero  
A Aruin  
A Arzimanoglou  
S Asano  
R Asherson  
K Ashkan  
A Atkinson  
C Avezaat  
T Aziz  
P Azouvi  
H S Bachelard  
J Baehring  
H Baezner  
I Baguley  
A Bahra  
P Bain  
S Bakchine  
G Baker  
R Bakshi  
K Bala

R Balaji  
L Balcer  
R Baldwin  
R W Baloh  
O Bandmann  
R Barclay-Goddard  
F Barinagarrementeria  
F Barkhof  
L Barnes  
M Barnes  
T Barnes  
G Barnett  
R J Barohn  
J-C Baron  
P Barone  
W Barr  
C Bass  
A Bastian  
M Bastin  
A Bateman  
D Bates  
R Baumgarner  
S Baxendale  
G Beaumont  
J G Becher  
E Beghi  
L Beglinger  
L Belayev  
B Bell  
E Bellissant  
E Bellone  
H Benamer  
O Benavente  
M Bendszus  
M Benedict  
T Bengner

T Benke  
E Ben-Menachen  
C Bennett  
Y Ben-Shlomo  
J Berciano  
H Berendse  
D Berg  
S Berilgen  
S Berkovic  
G Berlot  
G E Berrios  
F Besag  
G Besson  
F Bethoux  
S Betmouni  
J Bevilacqua  
B B Bhakta  
K Bhatia  
F Biagi  
G Jan Biessels  
E Bigler  
K Bihari  
P Bill  
M Billiard  
G Binetti  
A Biondi  
A Bizzi  
F Blaes  
J Bland  
R Blankenstein  
A Bleasel  
S Blecic  
K Blennow  
O Blin  
B Bloem  
C Boake

H Boer  
 B F Boeve  
 M D Boggild  
 J Bogousslavsky  
 A Bokde  
 F Boller  
 S Bombois  
 S Bombois  
 I Bone  
 R Bonelli  
 D Bonifati  
 P Boon  
 R Bordet  
 N Bornstein  
 H Bostock  
 A Bowen  
 J Bowler  
 A Bowling  
 G Boysen  
 M Bozzali  
 L Bracco  
 R Bracewell  
 K Bradley  
 M Brainin  
 S Brandner  
 J Brandt  
 T Brandt  
 L Brass  
 S Bressman  
 B Brew  
 A Brice  
 A Briddon  
 F Briganti  
 T Britton  
 J Broad  
 B Brochet  
 S Brocke  
 M Brodie  
 A M Bronstein  
 D Brooks  
 N Brooks  
 B Brophy  
 M M Brown  
 P Brown  
 R G Brown  
 R Brown  
 R Bruyn  
 C Buckley  
 J Buckley  
 H Budka  
 R Bullock  
 M Bunnage  
 N Burgess  
 D Burke  
 D Burn  
 J Burne  
 A Burns  
 K Bushara  
 K Bushby  
 N Busis  
 M Buttman  
 N Buxton  
 J V Byrne  
 H Caci  
 L Caeiro  
 P Calabrese  
 R Camicioli  
 J Campistol-Plana  
 N Canas  
 L Candelise  
 P Canhao  
 L Caplan  
 A Capurso  
 F Cardoso  
 D Carey  
 C Carlotti  
 R Carne  
 A Carolei  
 L Carr  
 A Carson  
 K Carter  
 R Caselli  
 A Casey  
 V Caso  
 M Catani  
 G Cavallo  
 M Celani  
 F Cendes  
 R Ceravolo  
 J-H Cha  
 D Chadwick  
 I R Chambers  
 A Chamorro  
 C Chan  
 D Chan  
 J H Chang  
 M C Chartier-Harlin  
 J Chataway  
 K Chaudhuri  
 V Chaudhury  
 L Cheng-Hsien  
 W Cheshire  
 B Cheung  
 K Chiappa  
 P F Chinnery  
 J Choi  
 M Choksey  
 I H Choo  
 K Chou  
 K M Chow  
 D Clark  
 C Clarke  
 J Classen  
 T Clausen  
 R Clifford-Jones  
 A Clifton  
 C Clough  
 H Clusmann  
 H Cock  
 H Cohen  
 A Colchester  
 J Cole  
 A J Coles  
 D Collier  
 M Collins  
 S Collins  
 C Colosimo  
 C Comella  
 C Confavreux  
 M Connor  
 C Constantinescu  
 R Cooke  
 M Cookson  
 P Corcia  
 C Cordonnier  
 F Coreia  
 D Cornblath  
 M Cosentino  
 C Counsell  
 P Couratier  
 A Covanis  
 P Coyle  
 S Craft  
 S Cramer  
 P Cras  
 I Crassard  
 D Craufurd  
 T J Crawford  
 L Crevits  
 J Crinion  
 E Croes  
 A Croquelois  
 A Crosby  
 S Crutch  
 L Csiba  
 M Czosnyka  
 A Da Costa  
 M Daffershofer  
 J Dalmau  
 J Dalrymple-Alford  
 M Damian  
 P Damier  
 T Daniel  
 J-F Dartigues  
 Y Dauvilliers  
 C Davie  
 B Davies  
 R Davies  
 M Davis  
 H Dawes  
 J Day  
 P Dazzan  
 D D'Cruz  
 C De Carli  
 J de Jonghe  
 M de Koning-Tijssen  
 F-E de Leeuw  
 D De Ridder  
 E De Schryver  
 J de Seze  
 V de Simone  
 N De Stefano  
 B de Swart  
 B de Toffol  
 R Deane  
 L M DeAngelis  
 S Deb  
 M Debette  
 S Debette  
 L Defebvre  
 G Defer  
 K Deguchi  
 I Dehaene  
 F Deisenhammer  
 A Demchuk  
 A Demetriades  
 T den Heijer  
 M Dennis  
 D Deplanque  
 P Derambure  
 B Desvergne  
 D Devos  
 R Dewey  
 C Di Bonaventura  
 V Di Piero  
 R Diaz-Arrastia  
 J P R Dick  
 R Dickstein  
 J Diehl  
 H C Diener  
 M Dieterich  
 V Dietz  
 D Dippel  
 D W Dodick  
 M Donaghy  
 G Donnan  
 A Dressel  
 B Dubois  
 X Ducrocq  
 M Duddy  
 C Dufouil  
 M Dumas  
 R Duncan  
 S Duncan  
 L Dunn  
 F Durif  
 J Du-Shin  
 C Duyckaerts  
 P Dyck  
 R Dykes  
 T Dziedzic  
 G Ebers  
 S Ebihara  
 K Ebmeier  
 G Edan  
 M Edwards  
 D Eidelberg  
 M Elam  
 R J Elble  
 P Eldridge  
 C J K Ellis  
 G Elrington  
 J S Elston  
 J Engel  
 S Engelborghs  
 S Engelter  
 E Englund  
 G Essick  
 S Estus  
 A Evans  
 J Evans  
 I Everall  
 V G Evidente  
 B Eymard  
 F Fabbro  
 C Faber  
 R Fahlbusch  
 S Farmer  
 J Farrar  
 A Fasano  
 A Fawcett  
 F Fazekas  
 F Fazio  
 V Feigin  
 A Feinstein  
 H Feldman  
 R E Ferner  
 R Ferri  
 L Feuillet  
 D H F Fytche  
 D Fialho  
 M Filippi  
 L J Findley  
 M Fiorelli  
 C Fischer  
 R Fisher

S Fitzek  
 P Flachenecker  
 S Fleminger  
 J Flint  
 B Fontaine  
 P Fontoura  
 G A Ford  
 A Forsberg  
 L Forsgren  
 M Forsting  
 C Fowler  
 N Fox  
 Y Fragoso  
 G Francis  
 P Francis  
 A Frank  
 B Frankel  
 P Franks  
 L Fratiglioni  
 J Fridriksson  
 J Friedman  
 J H Friedman  
 A-M Frischauf  
 G Frisoni  
 E Frohman  
 S Frucht  
 J-P Fryns  
 P Fuhr  
 T Fujioka  
 H Fukuyama  
 G Fuller  
 A Furby  
 A Furlan  
 M Gaab  
 C Gabriel  
 D Gadian  
 D Galasko  
 A Gale  
 C Gandolfo  
 P Garcia de Frutos  
 E Garde  
 C Gardner-Thorpe  
 R Garg  
 S E Gariballa  
 R Garikapati  
 P Garrard  
 M P J Garssen  
 G Gascon  
 T Gasser  
 J-Y Gauvrit  
 H-J Gdynia  
 W Gedroyc  
 M S George  
 D Georgiadis  
 M Geschwind  
 A Geurts  
 G Ghacibeh  
 J Ghika  
 I Ghorayeb  
 G Giaccone  
 J Gibson  
 J Gillard  
 J Gilsbach  
 R Ginestal  
 G Giovannoni  
 M Giroit  
 M Giroud  
 P Giunti  
 P Goadsby  
 O Godefroy  
 E Goebell  
 C Goetz  
 R Gold  
 G Goldenberg  
 L Goldstein  
 P Golumbek  
 R E Gonsette  
 M L Gorno-Tempini  
 K Gorson  
 S Graham  
 R Grant  
 W Grant  
 F Graus  
 T Graves  
 A J E Green  
 B Greenberg  
 J Greene  
 J Greenhalgh  
 J Greenspan  
 R Greenwood  
 R Gregory  
 M Gresty  
 J Grieve  
 G Grond Ginsbach  
 M Grossman  
 R Grunewald  
 C Guilleminault  
 R Gupta  
 C Guttmann  
 M Guye  
 G-J Haan  
 J Haan  
 L Haas  
 M Hackett  
 R Hadden  
 P Hagell  
 M Haglund  
 J Hallak  
 P Halligan  
 G M Halmagyi  
 J Halperin  
 S Hammans  
 H Hampel  
 R Hanajima  
 C Hanemann  
 D Hannequin  
 A Hansen  
 S Happe  
 Y Harati  
 O Hardiman  
 J Hardy  
 M I Hariz  
 I Hart  
 R Hart  
 Y Hart  
 H-P Hartung  
 M Harzheim  
 A Hassan  
 J Hata  
 T Hatano  
 S Haulon  
 W Hauser  
 P Hautecoeur  
 C Hawkes  
 S A Hawkins  
 C Hawley  
 H Hayakawa  
 R Hayward  
 D Healy  
 M Hecht  
 C Heesen  
 K M Heilman  
 C Hemmings  
 M Henderson  
 G Hengstman  
 H Henon  
 M Henze  
 U Herrlinger  
 M Herrmann  
 J N Higgins  
 H Hildebrandt  
 M Hill  
 J Hillert  
 D Hilton-Jones  
 R Q Hintzen  
 M Hirayama  
 Y Hirayasu  
 G Hirose  
 M Hirsch  
 K Hisanaga  
 S L Ho  
 K Hoang-Xuan  
 J Hobart  
 P Hobson  
 S Hodgson  
 P Hoekstra  
 R Hohlfield  
 C Holmes  
 J Holton  
 M Hommel  
 D Hommer  
 O R Hommes  
 J Hoozemans  
 D Hornung  
 M Horsfield  
 H Hosseini  
 J Houeto  
 H Houlden  
 A House  
 R Howard  
 S-W Hsu  
 A Hufnagel  
 R Hughes  
 T Hughes  
 P Humphrey  
 M Husain  
 M Hutchinson  
 P Hutchinson  
 W Hutchison  
 J Iddon  
 M Ihara  
 M Inglese  
 R Inzelberg  
 D Inzitari  
 S Ishiai  
 S Iwase  
 G Izquierdo  
 M Jackson  
 B Jacobs  
 G Jade  
 A Jaillard  
 P Jallon  
 W Janig  
 S Jankelowitz  
 J Jankovic  
 E Janssens  
 P Jarman  
 A Jefferson  
 B Jennett  
 R Jensen  
 H Johansenberg  
 T John  
 K Johnson  
 M Johnson  
 S Jones  
 C Jonker  
 D Joshi  
 E Josien  
 W Jost  
 S Joubert  
 E Joyce  
 B Jude  
 F Juengling  
 E Juettler  
 H Jung  
 A-E Kaasik  
 G Kafatos  
 R Kalaria  
 M Kamaki  
 S S Kamin  
 T Kanda  
 T Kansu  
 P Kapeller  
 S Kapil  
 L Kappelle  
 L Kappos  
 N Kapur  
 G Karas  
 N Kassell  
 M Kasten  
 S Katai  
 D Katz  
 J Katz  
 R Katzenschlager  
 H Kaube  
 D Kaufer  
 P Kehoe  
 C Kellinghaus  
 A Kemeny  
 O Kempfski  
 P G E Kennedy  
 A G Kermode  
 R Kerwin  
 K Khalatbari  
 I Khan  
 E Khedr  
 D Khurana  
 D Kidd  
 M Kiefer  
 M Kiernan  
 J Killestein  
 J Kim  
 Y-H Kim  
 J King, Jr.  
 H Kingma  
 R Kirby  
 P Kirkpatrick  
 M Kivipelto  
 C J M Klijn  
 A Klimkowicz  
 L B Kline  
 T Klockgether  
 U Klose  
 P Knapp  
 I Kneebone  
 N Koch-Henriksen

H-C Koennecke  
 M Koepp  
 M Koga  
 M Koltzenburg  
 D Kondziella  
 M Kopelman  
 A D Korczyn  
 R Korinthenberg  
 C Kosinski  
 P Koudstaal  
 N Kovacs  
 P Krack  
 J Kramer  
 C Krarup  
 A Kreisler  
 I Kreitschmann-Andermahr  
 H Kremer  
 J Kreuzer  
 E Krishnamoorthy  
 P Krystkowiak  
 J Kulisevsky  
 D Kullmann  
 S Kumar  
 V Kumari  
 A Kurz  
 S Kuwabara  
 M Ladouceur  
 P Laloux  
 M Lambert  
 A Lammertsma  
 P Lamont  
 C Lampl  
 C Lamy  
 J Lance  
 R Lane  
 D Langdon  
 G Lange  
 R Lanius  
 M Lanteri-Minet  
 A Larner  
 V Larrue  
 E Lartigau  
 P Lasjaunias  
 H Lassmann  
 L Latini Corazzini  
 S Laureys  
 M Lavoie  
 M C Lawden  
 S M Lawrie  
 F Lazaro Perlado  
 T Le Tourneau  
 J P Leach  
 B R F Lecky  
 X Leclerc  
 T Ledin  
 H Lee  
 K L Leenders  
 A Leentjens  
 A Lees  
 J-P Lefaucheur  
 C Lefebvre  
 A Leff  
 J-M Leger  
 B Legros  
 D J Lehmann  
 J Leigh  
 P Leigh  
 J-P Lejeune  
 T Lempert  
 G Lennox  
 F Lenz  
 G L Lenzi  
 J Leonard  
 R Lesser  
 S Lewis  
 K-K Liao  
 C Lichy  
 D Liebeskind  
 E T Lim  
 M Lima  
 P Limousin  
 K W Lindsay  
 H Lipton  
 G Livingston  
 T Loddenkemper  
 J Lodder  
 E Loder  
 G Logroscino  
 A Lombes  
 C Loo  
 O Lopez  
 N Losseff  
 S Love  
 S Lovestone  
 P Low  
 C Lubetzki  
 B Lubicz  
 C Lucas  
 J Luchsinger  
 H Luders  
 G Lundborg  
 M Lunn  
 L M Luxon  
 T Lynch  
 R Macdonald  
 C Machado  
 M Mackowiak-Cordoliani  
 P Maddison  
 A Maertens de Noordhout  
 O Malik  
 R A Malik  
 L Mallet  
 C L Mallucci  
 G Mallucci  
 F Manes  
 P Manganotti  
 H Manji  
 D M A Mann  
 R Manni  
 J Mant  
 P Maquet  
 H J Markowitsch  
 H Markus  
 L Marsh  
 F MARTIN  
 R Martin  
 P Martinez-Martin  
 A Martins da Silva  
 C Martyn  
 J-L Mas  
 J Masdeu  
 S Massengo  
 C Masson  
 F Mastaglia  
 C Masters  
 D Mataix-Cols  
 M Mataro  
 C J Mathias  
 T Mathiesen  
 P S Mathuranath  
 R Matsumoto  
 A Matsumura  
 H Matsunaga  
 P Matthews  
 H P Mattle  
 A Mauskop  
 A Mayes  
 T McAllister  
 A McCaddon  
 D McFarland  
 N McGregor  
 C McGuigan  
 P McGuire  
 I McKeith  
 P J McKenna  
 J G McLeod  
 T McMillan  
 E Medeiros de Bustos  
 N Medford  
 M M Mehndiratta  
 J Mellers  
 A Mendelow  
 M F Mendez  
 M Menken  
 G Meola  
 R Metz  
 C Meyer  
 M Meyer  
 P Michel  
 R Mielke  
 E Mignot  
 J Mink  
 P Misra  
 A Mitchell  
 J D Mitchell  
 P Mitchell  
 M Mizuguchi  
 H Mizusawa  
 G Modi  
 C Monaca  
 L Montalbetti  
 J J Mooij  
 M Moonis  
 D Moore  
 A Moosa  
 T Moreau  
 R Morecraft  
 J Morgan  
 C Morganti-Kossmann  
 K Morgen  
 J Moriarty  
 A Morini  
 C Morris  
 J Morrow  
 F Mottaghy  
 T Moulin  
 M Mouradian  
 K Muir  
 P Muir  
 C Mulder  
 M Mumenthaler  
 C Mummery  
 N Munro  
 M Muqit  
 Y Muragaki  
 R Muri  
 D Murphy  
 N Murray  
 D Na  
 Y Nagahama  
 H Nagayama  
 G Nagels  
 Z Nagy  
 D Neary  
 P Nestor  
 T Neumann-Haefelin  
 P Newman  
 S P Newman  
 E T C Ngan  
 A Nicolson  
 N Nighoghossian  
 C Nimsky  
 M Nishimura  
 K Nobuhara  
 A Nordberg  
 J Noseworthy  
 J Noth  
 H Nukada  
 T Nurmikko  
 G Nys  
 M Oertel  
 E O'Hearn  
 M Okun  
 M Olde Rikkert  
 A Oliviero  
 T Olsen  
 D O'Neill  
 S O'Neill  
 H Openshaw  
 J Opitz  
 C Oppenheim  
 J-M Orgogozo  
 R W Orrell  
 M Orth  
 K Ostergaard  
 C Ostertag  
 P O'Suilleabhain  
 J-C Ouallet  
 O Outteryck  
 F Ovsiew  
 A M Owen  
 L Ozelius  
 M Paciaroni  
 C Padovan  
 L Padua  
 M-C Pai  
 J Palace  
 C Panayiotopoulos  
 L Pantoni  
 F Panza  
 S Pappata  
 L Parnetti  
 J Parvizi  
 A Pascual-Leone  
 F Pasquier  
 G Pasquier  
 M Pasquini  
 P Patrick  
 P Pattoneri  
 J M S Pearce  
 R Peatfield  
 P Pedersen  
 E Peitersen  
 S Peker  
 J Peltola  
 D Perani

D Perennou	G Rinkel	G Schott	A J Steck
D Perkin	J Rio	J M Schott	H Stefan
M-P Perriol	N Rizzuto	J Schramm	T Steiner
J Perumpillichira	W Robberecht	J B Schulz	D Stephens
M A Petersen	P Robert	S Schwid	D L Stevens
R Petersen	F Roberti	G Scivoletto	J Stevens
A Petzold	R Roberts	M Seeck	R Stewart
A Pezzini	T Roberts	G Seidel	W Stewart
J D Pickard	D Robertson	R J Seitz	P Stieg
C Pierrot-Deseilligny	G Robinson	J Serra-Mestres	N Stocchetti
M Piggott	K Rockwood	F Servadei	T Stojkovic
Y Pijnenburg	G Rodesch	S Sevim	E Stolz
T Pinho e Melo	H Rodgers	C Sewry	J Stone
E Pischik	V Rohde	S Sgouros	E Storey
G T Plant	G Roks	K Shahlaie	L-J Stovner
S Podnar	S Rolstad	N Sharafadin Zadeh	A Straube
W Poewe	G C Roman	M Sharpe	M Subramaniam
D Pohl	S Rombouts	B Sharrack	L Sudarsky
A Pollock	B Romner	P Shaw	C Sudlow
M Pollock	M A Ron	G Sheean	Y Sun
C Polman	Y Roos	J Shenker	S Sunaert
J Ponsford	M Rose	D Sherman	R Surtees
N Pongvarin	B Rosen	H Shill	T Swan
M Powell	M Rosenfeld	T Shimohata	M Swash
P Praamstra	K Rosenkranz	L Shin	N R Swerdlow
L Prashanth	R Rosenwasser	R Shin	R J Swingler
P Preux	F Roser	J Shneerson	O Sydow
M Prevett	E D Ross	H Shoji	M Tabert
J Punt	S Rossi	S Shorvon	S Tabrizi
A Quattrone	P Rossini	A Shuaib	Y Takarae
N Quinn	J Rother	M Shumacher	C Talbot
A Qureshi	M Rousseaux	D Sichinava	K Talbot
A Raabe	J Rowe	Z Siddiqi	E-K Tan
A Rabinstein	L Rowland	K Siddiqui	C Taschner
T Rahkonen	E Roze	E Sidransky	M Tatagiba
R Rajarethinam	S Ruchnicki	R Siegert	R Tate
V Rajshekhar	R Ruff	M Sierra	B Taylor
H Rambold	J Rutka	V Silani	G P Taylor
V G Ramesh	A Ryan	E Silber	E Teke
R Rampling	P Ryvlin	S Silberstein	C Teunissen
S Rana	U Sabatini	P Sillevs Smitt	E Thiery
J Randolph	A Sadun	M Silva	V Thijjs
W Rashid	S Saiki	J Silver	A J Thomas
G Ravaglia	A Salazar	C Simonin	A Thomas
G Raymond	S Salloway	B Simpson	A Thompson
G W Rebeck	F Salvi	G Simpson	E J Thompson
G Rees	M Samuel	C Sindic	P Thompson
J H Rees	J Sander	S Singh	P Tofts
J Reijneveld	M Saporta	C-A Sirbu	E Tolosa
M Reilly	G Saposnik	A G Smith	R Tomer
R Reilmann	J Savitz	M Smith	T Tomson
M Reinges	E Scarpini	S Smith	D Toni
I Reinvang	W Schady	J S Snowden	J C Tonn
T Revesz	B Schaller	G Sobue	B Toone
N Reyns	A Schapira	M Sokal	A Toosy
S Ricci	R Scheid	P Soliveri	C Toth
F Richard	G Scheler	E Somerville	E Tournier-Lasserre
I Richard	P Schellinger	A Sorensen	E Touze
P Richards	E Scherder	H Soreq	A Traboulsee
M Richardson	R Schiffmann	K Sotaniemi	B Traynor
H Rickards	B Schmand	J D Speelman	H Tremlett
B Ridha	H Schmidt	P S Spencer	M R Trimble
P Rieckmann	R Schmidt	S S Spencer	B Tripathi
E Righetti	K Schmierer	C Sprung	P Trouillas
H Ring	B Schmitz	M Stacy	A Truini
E B Ringelstein	E Schmutzhard	C Stam	M Trummer
P Ringleb	A Schnider	J Stam	L-K Tsai
D Ringuenet	J Schoenen	C Stapf	D Turnbull
G Rinkel	R Schondorf	S Starkstein	L Turner-Stokes

H Tyne  
 E Uhl  
 B Uitdehaag  
 F Unverzagt  
 C Urch  
 D Vaillancourt  
 P Vajkoczy  
 G Vallar  
 J-M Vallat  
 C Van Broeckhoven  
 L H van den Berg  
 W van der Flier  
 M van der Knaap  
 J van der Naalt  
 P A van Doorn  
 B van Engelen  
 J van Hilten  
 T van Laar  
 B van Oosten  
 W J van Rooij  
 J Van Swieten  
 L van Zyl  
 R Vanderploeg  
 W Vandertop  
 C Vaney  
 J A L Vanneste  
 T R Varma  
 K Vass  
 R Veerhuis  
 K Vemmos  
 M Verbeek

A Verdelho  
 J Verghese  
 F Verhey  
 N Verlander  
 P Vermersch  
 M Vermeulen  
 R Vermeulen  
 C Verny  
 J Vesper  
 E Veznedaroglu  
 M Vidailhet  
 L Vignatelli  
 A Vincent  
 M Visser  
 P J Visser  
 D Vodusek  
 J Voges  
 G Volans  
 J Volkmann  
 M von Brevern  
 R von Kummer  
 S Vucic  
 S Vukusic  
 D Wade  
 D Waitzman  
 G Waldemar  
 M Walker  
 R Walker  
 Z Walker  
 T Walls  
 L Walter

K Ward  
 N Ward  
 J Wardlaw  
 T Warner  
 T Warr  
 J Warren  
 H Watanabe  
 J Weber  
 D Weintraub  
 W-U Weitbrecht  
 K Welch  
 M Weller  
 R O Weller  
 G Wenk  
 K Werhahn  
 D Werring  
 K Wester  
 M Westphal  
 C Wheeler-Kingshott  
 I Whittle  
 E F M Wijdicks  
 E Wilder-Smith  
 R Will  
 B Willer  
 D Williams  
 H Williams  
 J Williams  
 H Willison  
 E Willoughby  
 A Wills  
 J Winer

H Winn  
 R Wityk  
 F Woermann  
 J Wokke  
 H Wolf  
 C D A Wolfe  
 G Wolfe  
 N Wood  
 R Wood  
 P Worth  
 D Wright  
 A Wu  
 S Yamada  
 Z Yetkin  
 T Yoshida  
 C Young  
 T Yousry  
 W Yu  
 K Zackowski  
 J Zajicek  
 W Zbigniew  
 D S Zee  
 A Zeman  
 J Zentner  
 H Zephir  
 J Zijlmans  
 R Zivadinov  
 M Zuber

# Volume 76 Reviewers

The Editor is grateful to the following for reviewing books during the past year.

A Bahra  
 J Ball  
 P Boon  
 R Botell  
 S Crutch

K Fotopoulou  
 C Gardner-Thorpe  
 M G Hanna  
 E Joyce  
 A Larner

E W Loder  
 J C Moeler  
 W H Oerte  
 R W Orrell  
 P Richards

A Schrag  
 S Tabrizi  
 J Warren  
 T A Yousry