

# PostScript

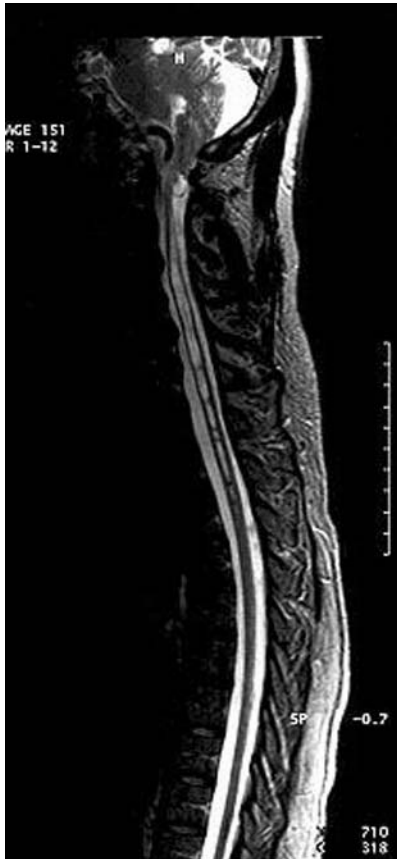## LETTERS

### "Dropped head syndrome" in syringomyelia: report of two cases

"Dropped head syndrome" is characterised by weakness of the extensor muscles of the neck, with or without involvement of the neck flexors, and is commonly caused by a variety of neuromuscular disorders, including myasthenia gravis, polymyositis, amyotrophic lateral sclerosis, facio-scapulo-humeral dystrophy, nemaline myopathy, carnitine deficiency, spinal muscular atrophy, and isolated neck extensor myopathy.<sup>1,2</sup> There are isolated reports of dropped head syndrome occurring in cervical spondylitis and ankylosing spondylitis.<sup>3</sup> In this report, we describe the clinical and imaging findings of two patients who had dropped head syndrome as a rare neurological sign secondary to syringomyelia.

#### Case report 1

A 46 year old right handed man presented during May 2002 with insidious onset, gradually progressive weakness and wasting



**Figure 1** Sagittal T2 weighted image showing the hyperintense lesion in the cervicodorsal cord with multiple haustriations and associated tonsillar herniation.

of the small muscles of the left hand since August 1998. This deficit stabilised after a period of one year. At the onset of illness, he had also developed mild difficulty in using his right hand for performing fine work but this symptom remained stable. He noticed occasional fasciculations over the arms for one year. After two years and nine months he developed rapidly progressive head drop and required assistance of the hand to maintain the head in an erect posture, and he also had mild difficulty in lifting his head off the bed while rising from the supine position. There was no history of impaired sensation to touch, pain, or temperature, or inadvertent burns over the hands or shoulders. There were no features to suggest Horner's syndrome or symptoms referring to the cranial nerves, lower limbs, cerebellar system, or sphincters. There was no nuchal pain, restricted neck movements, or symptoms of raised intracranial pressure.

Examination revealed mild cerebellar dysarthria and fasciculations over the tongue. There were no features of Horner's syndrome and the eye movements, facial sensations, palatal reflexes, and pharyngeal reflexes were normal. Occasional fasciculations were present over the arms. There was Medical Research Council grade 2 weakness of the neck extensor muscles with head drop and grade 4 weakness of the neck flexors. There was mild wasting of the erector spinae muscles in the neck and asymmetric wasting of the small muscles of the hand, including the thenar, hypothenar, and interossei muscles bilaterally, with the left side being affected more severely. Power in the lower limbs was normal. Deep tendon reflexes were sluggish in the upper limbs and exaggerated in the lower limbs, with a bilateral flexor plantar response. The sensory system revealed bilateral C2 hypoesthesia, with



**Figure 2** Clinical feature of dropped head with severe wasting and weakness of neck extensor muscles. This photograph is reproduced with the full consent of the patient.

impaired pain and temperature sensations in both upper limbs and in the shoulder girdle region. Magnetic resonance imaging of the spine and brain revealed a septate intrinsic cord hypointensity in T1 weighted images, becoming hyperintense in T2 weighted images extending from the C2 to C7 (fig 1) levels, associated with low lying cerebellar tonsils and brainstem reaching the lower border of C1. Brain images revealed evidence of hydrocephalus. There was no evidence of myelomeningocele. Electromyography of the distal muscles in the upper limbs showed fibrillation and fasciculation potentials. Motor and sensory conduction studies were normal. Investigations including serum chemistry and haemogram were normal.

#### Case report 2

A 30 year old man presented in December 2003 with progressive weakness and atrophy of the right shoulder girdle muscles with a duration of one year, followed by similar symptoms on the left side for 10 months; at presentation he was unable to raise his arms. In the last six months he had developed head drop, with difficulty in maintaining the head in the erect posture, and since this time he had noticed weakness and atrophy of the hand muscles. There were no symptoms of pain or restricted neck movements, and there was no sensory impairment, sphincter disturbance, or cerebellar ataxia. Neurological deficits were present in the form of thoracic kyphoscoliosis and wasting of the extensor muscles of the neck, resulting in severe weakness and dropped head (fig 2). Power in the neck flexors was grade 4. Severe asymmetric wasting of the shoulder girdle muscles, in addition to moderate wasting of the arm, forearm, and hand muscles was noted, with bilateral clawing. There was grade 2 power in the proximal muscles, including the arm, and grade 3 in the small muscles. Deep tendon reflexes were absent in the upper limbs and exaggerated in the lower limbs, with a bilateral extensor plantar response. Temperature sensation was impaired in the entire body except for the face. Posterior column and spinothalamic sensations were normal. Contrast magnetic resonance imaging of the spine, including T1 weighted and T2 weighted images, revealed a cerebrospinal fluid signal intensity lesion involving the entire cord, with expansion of the cord, and no evidence of abnormal contrast enhancement, suggestive of holocord syringomyelia.

#### Discussion

Dropped head syndrome is a well known feature in a variety of neuromuscular disorders, and is also described in diseases of the bone and joints, such as ankylosing spondylitis and cervical spondylitis.<sup>3</sup> Neck flexion weakness is typical in most conditions, but prominent neck extensor weakness has been described in several reports. In the recent review article on dropped head syndrome in amyotrophic lateral sclerosis, 19 different conditions are listed as causes for dropped head syndrome, but syringomyelia is not mentioned as a cause.<sup>4</sup> Our patients presented with classic features of cervical intrinsic cord lesion suggestive of

syringomyelia and had the typical features of dropped head syndrome.

**A Nalini, S Ravishankar**

National Institute of Mental Health and Neurosciences,  
Bangalore, India

Correspondence to: Dr A Nalini, National Institute of Mental Health and Neurosciences (NIMHANS), Hosur Road, Bangalore 560 029, India; nalini@nimhans.kar.nic.in; atchayaramnalini@yahoo.co.in

doi: 10.1136/jnnp.2004.040428

Received 4 March 2004

Revised form received 2 June 2004

Accepted 8 June 2004

Competing interests: none declared

The patient gave consent for reproduction of the photograph.

## References

- 1 **Suarez GA**, Kelly JJ. The dropped head syndrome. *Neurology* 1992;**42**:1625-7.
- 2 **Lomen-Hoerth C**, Simmons ML, DeArmond SJ, et al. Adult-onset nemaline myopathy: another cause of dropped head. *Muscle Nerve* 1999;**22**:1146-9.
- 3 **Swash M**. Dropped-head and bent-spine syndromes; axial myopathies? *Lancet* 1998;**352**:758.
- 4 **Gourie-Devi M**, Nalini A, Sandhya S. Early or late appearance of "dropped head syndrome" in amyotrophic lateral sclerosis. *J Neurol Neurosurg Psychiatry* 2003;**74**:683-6.

## Vitamin B-12, serum folate, and cognitive change between 11 and 79 years

A recent Cochrane review reported that although vitamin B-12 deficiency is known to be associated with cognitive impairment in old age, benefits of supplementation on mental ability are unclear.<sup>1</sup> The situation is similar to that for blood pressure, in which hypertension is associated with neuropsychological deficits in adulthood but cognitive outcomes of lowering blood pressure in randomised controlled trials are equivocal. We found that for blood pressure, the limited effect of intervention is partly explained by the relation between childhood IQ and adult blood pressure—children with higher IQs had lower mid-life blood pressures.<sup>2</sup> As approximately 50% of the variance in adult IQ is explained by childhood IQ, studies failing to account for "pre-morbid" mental ability are likely to overestimate the association between adult IQ and blood pressure. Previously we reported significant relations between various tests of mental ability in old age and vitamin B-12 and folic acid concentrations in the blood.<sup>3</sup> We now describe the association between vitamin B-12 and serum folate and lifetime change in mental ability using the same cognitive test at age 11 and age 79.

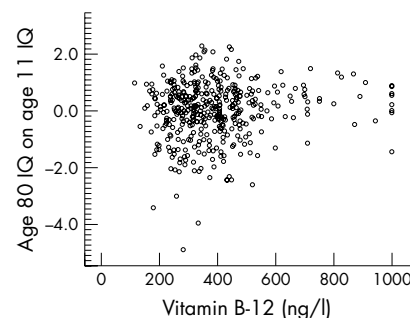
As reported more fully elsewhere,<sup>4</sup> the 1932 Scottish Mental Survey (SMS1932) measured the mental ability of almost all (n = 87 498) children born in 1921 and attending Scottish schools on 1 June 1932 with a validated test of IQ, the Moray House test (MHT). With local ethics approval, 550 survivors of the SMS1932 were recruited in Lothian, Scotland by a variety of means. They underwent a health assessment, including blood sampling for vitamin B-12 and folate, and the MHT was re-administered.<sup>4</sup> In all, 483 participants were matched to age 11 MHT scores from the SMS1932, and an age-in-days-adjusted IQ

score was calculated. As previously, we included only participants with mini-mental state examination scores greater than 23 and no history of dementia, to exclude pathological cognitive decline as far as possible.<sup>4</sup> None of the participants had a history of head trauma or ongoing CNS affecting disease. The resultant sample comprised 470 participants (194 men, 276 women).

Mean (SD) serum vitamin B-12 was 390 (161) ng/l (n = 422) and mean serum folate was 337 (155) µg/l (n = 391). Pearson correlation coefficients with age 11 IQ were:  $r = 0.04$  ( $p = 0.42$ ) for B-12 and  $r = 0.13$  ( $p = 0.010$ ) for folate; and with age 79 IQ,  $r = 0.12$  ( $p = 0.018$ ) for B-12 and  $r = 0.12$  ( $p = 0.016$ ) for folate. Linear regression of age 79 IQ controlling for age 11 IQ confirmed a significant effect on age 79 IQ for B-12 ( $\beta = 0.092$ ,  $p = 0.016$ ,  $R^2$  improvement = 0.008) but not for folate ( $\beta = 0.038$ ,  $p = 0.33$ ). Only two participants had folate levels below the normal range (<5 µg/l) and omitting these did not affect correlation coefficients with age 11 and age 79 IQ scores. Twenty five participants had vitamin B-12 levels below the normal range (<200 ng/l) and there was a stronger correlation with age 79 IQ in this group ( $r = 0.57$ ,  $p < 0.001$ ) than in those well within the normal range  $\geq 250$  ng/l ( $r = 0.10$ ,  $p = 0.031$ ). The difference between these two correlation coefficients was significant ( $p = 0.016$ ). After adjusting for all variables known to be associated with lifetime change in IQ (sex, *APOE*  $\epsilon 4$  status, cigarette smoking, statin use, and number of drugs prescribed),<sup>4</sup> vitamin B-12 remained a significant contributor ( $\beta = 0.095$ ,  $p = 0.011$ ). Together, these variables explained 4.5% of total variance in age 79 IQ scores after adjusting for IQ at age 11. The number of units of alcohol consumed per week was also positively correlated with age 79 IQ score (Spearman  $\rho = 0.10$ ,  $p = 0.026$ ), but was no longer significantly associated ( $\beta = -0.01$ ,  $p = 0.73$ ) once age 11 IQ and vitamin B-12 were adjusted for.

## COMMENT

Both vitamin B-12 and folate correlate with IQ in old age in a non-demented population. Lower serum B-12 at age 79 is associated with cognitive decline between age 11 and age 79. By contrast, serum folate at age 79 correlates with age 11 IQ, and controlling for this reduces the correlation with IQ in old age to almost zero. Hence, in this sample the relation between serum folate and old age mental ability can be fully explained by its



**Figure 1** Vitamin B-12 levels and standardised residuals of age 79 IQ regressed on age 11 IQ in a surviving cohort of the Scottish Mental Survey 1932 (n = 422).

correlation with IQ scores on the same test given 68 years previously. This is a similar situation to that with blood pressure.<sup>2</sup> This further emphasises the importance of interpreting associations between cognition and other variables in older people in the context of "pre-morbid" mental ability. The effect size of vitamin B-12 is smaller than those found with more domain specific cognitive tests,<sup>3</sup> contributing less than 1% of total variance in age 79 IQ. It is unlikely to be clinically apparent. However, the effect was more significant in the small subsample with laboratory defined deficiency.

Inspection of the relation between vitamin B-12 and the standardised residual score of age 79 IQ regressed on age 11 IQ (fig 1) suggests that the overall correlation is accounted for by a subgroup that is cognitively vulnerable to vitamin B-12 deficiency. Moreover, this vulnerability occurs at levels within the normal laboratory range. An IQ decline of >1 SD occurred in seven of 18 participants (39%) with a serum vitamin B-12 of <200 ng/l, 19 of 84 (23%) with levels of 200–299 ng/l, 21 of 103 (20%) with levels of 300–399 ng/l, and 21 of 149 (14%) with levels of >399 ng/l. Further work is required to confirm this and ascertain what makes these individuals vulnerable. One explanation is that this is a group having "metabolically significant" vitamin B-12 deficiency within the normal range with raised homocysteine or methylmalonic acid levels.<sup>5</sup> This may help target B-12 therapy, but at present identifying this group remains challenging. Our data suggest that in a non-demented, relatively healthy population, serum folate concentrations were not related to IQ in old age after controlling for childhood mental ability. However, only two participants in our sample had folate values below the normal range, so other studies are needed to assess the cognitive effects of folate deficiency and treatment with folic acid.

## ACKNOWLEDGEMENTS

The research was supported by the UK Biotechnology and Biological Sciences Research Council. JMS is the recipient of a "Leading Practice Through Research" award from the Health Foundation. IJD is the recipient of a Royal Society-Wolfson Research Merit Award. LJW holds a Wellcome Trust Career Development Award.

**J M Starr**

Geriatric Medicine unit, Royal Victoria Hospital, Craigleith Road, Edinburgh, EH4 2DN, UK

**A Pattie, M C Whiteman, I J Deary**

Psychology, School of Philosophy, Psychology and Language Sciences, University of Edinburgh

**L J Whalley**

Department of Mental Health, University of Aberdeen, Clinical Research Centre, Cornhill Royal Hospital, Aberdeen, UK

Dr John M Starr; john.starr@ed.ac.uk

doi: 10.1136/jnnp.2004.046219

Competing interests: none declared

## REFERENCES

- 1 **Malouf R**, Areosa Sastre A. Vitamin B12 for cognition. *Cochrane Database of Systematic Reviews*. CD004326, 2003.
- 2 **Starr JM**, Taylor MD, Hart CL, et al. Childhood mental ability and blood pressure at midlife: linking the Scottish Mental Survey 1932 and the Midspan studies. *J Hypertens* 2004;**22**:893-8.

- 3 Duthie SJ, Whalley LJ, Collins AR, *et al.* Homocysteine, B vitamin status and cognitive function in older adults. *Am J Clin Nutr* 2002;**75**:908–13.
- 4 Deary IJ, Whiteman MC, Starr JM, *et al.* The impact of childhood intelligence in later life: following up the Scottish Mental Surveys of 1932 and 1947. *J Pers Soc Psychol* 2004;**86**:130–47.
- 5 Clarke R, Grimley Evans J, Schneede J, *et al.* Vitamin B12 and folate deficiency in later life. *Age Ageing* 2004;**33**:34–41.

## Stent assisted endovascular thrombolysis of internal carotid artery dissection

Spontaneous dissection of the extracranial internal carotid artery (ICA) is a major cause of stroke with severe residual handicap in young adults.<sup>1</sup> Recently, stent supported angioplasty has been used to treat intimal dissection in case of neurological symptoms while on anticoagulation or as an alternative to the traditionally accepted use of anticoagulation.<sup>2,3</sup> We report a case of internal carotid artery dissection causing hemiplegia successfully treated with emergent endovascular stenting followed by intra-arterial thrombolysis.

### Case report

A 44 year old right handed man was admitted to the emergency room after an acute episode of left side weakness, which resolved within three hours. The patient had been well until the onset of symptoms. There was no history of trauma, strenuous exercise, hypertension, or other medical problems. In the week prior to admission, he reported intermittent headaches and right sided neck pain after four days of diving. A cranial computed tomography (CT) scan was normal. Diffusion weighted imaging (DWI) of the brain performed six hours after the onset of symptoms while the patient was asymptomatic showed no evidence of infarction. T2-weighted magnetic resonance images and fat suppressed images showed a semilunar hypersignal of a mural haematoma in the infrapetrous segment of the right ICA suggestive of a dissection. Low molecular weight heparin treatment (enoxaparin sodium 1 mg/kg subcutaneously every 12 hours) was started to obtain true anticoagulation.

Three hours later, the patient had sudden left sided hemiplegia, hypaesthesia, hemianopia, and hemineglect. The National Institutes of Health Stroke Scale (NIHSS) score was 12. Transcranial Doppler ultrasound did not show any flow signal from the middle cerebral artery (MCA) pointing to an acute occlusion. Because of the likely poor

chance of revascularisation with intravenous thrombolytic therapy, emergent endovascular revascularisation followed by intra-arterial thrombolysis was planned. Angiography (fig 1A) performed within three hours and 30 minutes of onset of the new symptoms showed the typical narrowed aspect of the ICA with no opacification of the intracranial arteries. Right hemispheric circulation was analysed on the left carotid angiogram: the right anterior cerebral artery (ACA) filled via anterior communicating artery, and the distal branches of the right MCA were completely occluded. Proximal ICA recanalisation was achieved by implantation of two tandem self-expandable stents (Carotid Wall stent, Boston Scientific Inc, Natick, MA), covering the suprabulbar cervical portion of the ICA (fig 1B). Subsequent intracranial angiography showed a fresh thrombus in the right carotid siphon and confirmed the occlusion of the MCA. Intra-arterial tissue plasminogen activator (tPA) was infused directly into the thrombus four hours after the onset of the new symptoms (40 mg total). There was good proximal recanalisation with residual filling defects in some branches of the MCA (fig 1C) and immediate clinical improvement. The patient received a 5000 U heparin bolus during the procedure and then continuous 500 U/h infusion for 24 hours. Heparin therapy was then replaced by clopidogrel and aspirin, both 75 mg daily. On day 2, MRI showed brain infarct in the deep MCA territories with asymptomatic haemorrhagic transformation. The carotid artery and the MCA were fully patent at ultrasound examination with no evidence of restenosis. There were no periprocedural complications and the patient's symptoms improved gradually after the procedure. On day 7, he was discharged on aspirin and clopidogrel with no residual symptoms.

### Discussion

Ischaemic stroke in patients with ICA dissection mainly results from thromboembolic, or, less frequently, haemodynamic mechanisms.<sup>4</sup> Formation of a false channel in the vessel wall or endothelial damage may favour formation of a local thrombus, which becomes less adherent and prone to embolise distally.<sup>1</sup> Although no general agreement exists on the best management of extracranial carotid artery dissection, and because of the threat of an embolic complication, anticoagulation with heparin followed by oral warfarin is used in most institutions.<sup>5</sup> In case of an embolic complication in a patient with

known carotid artery dissection revealed by local signs or a transient ischaemic attack, as in our patient, no recommendation exists about emergent therapy. Some reports suggest that intravenous thrombolysis might be safe and effective when given within three hours of onset of stroke without worsening the arterial wall tearing.<sup>6</sup> However, in case of severe stenosis, near occlusion, or even occlusion of the ICA, regardless of the cause, intravenous or intra-arterial thrombolysis has had a poor recanalisation rate, less than 15%.<sup>7</sup>

Endovascular stenting in patients with carotid artery dissection has been successfully used in either selected cases with haemodynamically significant stenosis or when anticoagulation failed to prevent embolic stroke.<sup>2,3</sup> It permitted resolution of the stenosis with immediate recanalisation of the artery. After the procedure, there was no need for anticoagulation and the patient was treated with antiplatelet agents. Our patient had acute hemiplegia with MCA occlusion despite adequate medical therapy. Intravenous thrombolysis given within three hours of onset of symptoms might be an alternative treatment,<sup>8</sup> but it would have likely not been effective since ICA near occlusion would have been left in place; systemic thrombolysis was contraindicated because of the anticoagulation therapy.

We chose a new approach combining endovascular stenting and intra-arterial thrombolysis. Mechanical reopening of occluded large vessels is currently being explored only in carefully selected cases of acute stroke management to minimise the risk of haemorrhagic complications. By taking advantage of the immediate recanalisation of completely occluded vessels it permits delivery of thrombolytic agents directly in the clot, maximising the chance of total distal recanalisation.

Although so far no clinical trial has documented the efficacy of emergent revascularisation in the setting of acute stroke, accumulated anecdotal data show that endovascular mechanical revascularisation is likely to become an important alternative therapeutic approach in properly selected stroke patients. A potential disadvantage of mechanical reopening is the production of embolic debris.<sup>9</sup> With stent deploying in dissected carotid artery, there is a theoretical risk of the intramural clot contained within the dissected segment breaking into the cerebral circulation leading to embolisation distally. In our case, the MCA emboli were demonstrated prior to stenting using transcranial Doppler ultrasound. Another alternative to intra-arterial thrombolysis could be the use of mechanical thrombectomy devices to remove the clot from the carotid siphon and MCA.

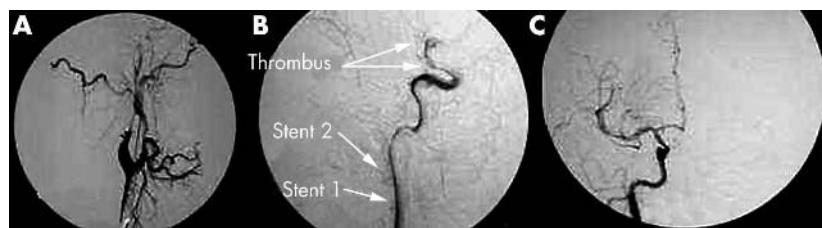
This case report is to our knowledge the first example of the potential use of stenting followed by intra-arterial thrombolysis to treat and cure symptomatic carotid artery dissection. However, no conclusions can be drawn about the safety of endovascular approach in this clinical setting. Further evaluation is needed to address its risk–benefit ratio.

**H Abboud**

Department of Neurology and Stroke Center, Bichat University Hospital and Medical School, Denis Diderot University-Paris VII, France

**E Houdart**

The Department of Interventional Neuroradiology, Lariboisiere Hospital, Denis Diderot University-Paris VII, France



**Figure 1** (A) Baseline right common carotid artery (CCA) angiogram shows near occlusion distal to the origin of the infrapetrous segment of the right internal carotid artery (ICA). (B) Post stenting right ICA angiogram demonstrates complete resolution of the ICA occlusion and shows the thrombus in the carotid siphon and in the MCA. (C) Right ICA angiogram after 40 mg of intra-arterial tissue plasminogen activator, recanalisation of the carotid siphon and of the M1 and M2 segment of the MCA and partial recanalisation of some branches of the MCA.

**E Meseguer, P Amarenco**

Department of Neurology and Stroke Center, Bichat University Hospital and Medical School, Denis Diderot University-Paris VII, France

Correspondence to: Halim Abboud, Department of Neurology and Stroke Center, Bichat Hospital, 46 rue Henri Huchard, F-75018 Paris, France; halim.abboud@bch.ap-hop-paris.fr

doi: 10.1136/jnnp.2004.041863

Competing interests: none declared

**References**

- 1 Schievink WI. Spontaneous dissection of the carotid and vertebral arteries. *N Engl J Med* 2001;**344**:898-906.
- 2 Malek AM, Higashida RT, Phatouros CC, et al. Endovascular management of extracranial carotid artery dissection achieved using stent angioplasty. *AJNR Am J Neuroradiol* 2000;**21**:1280-92.
- 3 Cohen JE, Leker RR, Gotkine M, et al. Emergent stenting to treat patients with carotid artery dissection: clinically and radiologically directed therapeutic decision making. *Stroke* 2003;**34**:e254-7.
- 4 Lucas C, Moulin T, Deplanque D, et al. Stroke patterns of internal carotid artery dissection in 40 patients. *Stroke* 1998;**29**:2646-8.
- 5 Lyrer P, Engelter S. Antithrombotic drugs for carotid artery dissection. *Stroke* 2004;**35**:613-14.
- 6 Derex L, Nighoghossian N, Turjman F, et al. Intravenous tPA in acute ischemic stroke related to internal carotid artery dissection. *Neurology* 2000;**54**:2159-61.
- 7 Arnold M, Schroth G, Nedeltchev K, et al. Intra-arterial thrombolysis in 100 patients with acute stroke due to middle cerebral artery occlusion. *Stroke* 2002;**33**:1828-33.
- 8 Tissue plasminogen activator for acute ischemic stroke. The National Institute of Neurological

Disorders and Stroke rt-PA Stroke Study Group. *N Engl J Med* 1995;**333**:1581-7.

- 9 Qureshi AI. Endovascular treatment of cerebrovascular diseases and intracranial neoplasms. *Lancet* 2004;**363**:804-13.

**Bell's palsy: a study of the treatment advice given by Neurologists**

Bell's palsy is defined as an isolated unilateral lower motor neurone facial weakness of no obvious cause. The incidence has been estimated at around 23 to 25 cases per 100 000 population annually.<sup>1</sup> Although the prognosis is generally good, around 16% are left with varying degrees of permanent disability.<sup>2</sup>

The use of steroids and acyclovir in the treatment of Bell's palsy has been addressed in two recent Cochrane reviews.<sup>3 4</sup> These found no benefit from either but concluded that available studies were insufficiently powered to detect a treatment effect.

Neurologists are often asked by primary care physicians for treatment advice and in view of this uncertainty we were interested in studying the recommendations given. A questionnaire (appendix) was emailed to all consultant neurologists (n = 35) and specialist registrars (n = 21) in Scotland. Responses were collated at six weeks following an interim reminder. Fisher's exact test was used to compare groups; odds ratios with 95% confidence intervals and significance were calculated (table 1).

Replies were received from 27 consultants and 17 registrars, response rates of 77% and

81%, respectively. In all, there had been 69 requests received for treatment advice in the preceding three months. Referral for guidance from neurologists amounted to 26% of the total number of cases predicted by incidence studies.<sup>1</sup>

Only 5% of neurologists said they would always see the patient, with further 29% if atypical features were present. The use of steroids depended strongly on the stage of presentation, 76% giving steroids within 24 hours of onset, 62% within three days, and only 28% up to seven days. Fewer gave steroids in certain subcategories (12% in pregnancy, 19% in Ramsay Hunt syndrome, 62% in a complete syndrome, and 45% in a partial syndrome).

The steroid regimen advised was variable, with most advocating 40 to 60 mg of prednisolone, with or without a tapering dose. Only 20% of neurologists gave acyclovir in every instance; a further 20% gave it if there was evidence of Ramsay Hunt syndrome.

On the whole the responses from consultants and registrars were similar. However, while both advised steroids early on, consultants still recommended steroids up to seven days (42%) compared with only 6% of specialist registrars (p = 0.009). Geographical variability was evident; Glasgow neurologists advised steroids more readily, with 95%, 74%, and 21% giving them at 24 hours, three days, and seven days, respectively. This compared with 42% (p = 0.002), 42% (p = 0.065), and 17% (p = 0.34) at Edinburgh. There was also a trend for Glasgow physicians to prescribe more acyclovir (21% v 11% (p = 0.37)).

**Table 1** Treatment of Bell's palsy by subcategory

	"Yes" responses by consultants	"Yes" responses by registrars	"No" responses by consultants	"No" responses by registrars	OR (95% CI)	p Value
Do you see the patient?	1	1	14	9	0.642 (0.355 to 11.63)	0.5
Steroids within 24 h?	20	12	6	5	1.389 (0.347 to 5.55)	0.25
Steroids within 3 d?	17	9	9	8	1.68 (0.482 to 5.85)	0.18
Steroids within 7 d?	11	1	15	16	11.7 (1.35 to 102)	0.009
Steroids in pregnancy?	2	3	19	13	0.456 (0.067 to 3.12)	0.27
Steroids in Ramsay Hunt?	5	5	20	11	0.55 (0.13 to 2.32)	0.21
Steroids in complete syndrome?	18	10	8	7	1.58 (0.44 to 5.64)	0.20
Steroids in partial syndrome?	11	7	14	8	0.9 (0.25 to 3.25)	0.25
Do you give acyclovir?	6	3	14	9	1.29 (0.255 to 6.49)	0.30

	"Yes" responses by Edinburgh neurologists	"Yes" responses by Glasgow neurologists	"No" responses by Edinburgh neurologists	"No" responses by Glasgow neurologists	OR (95%CI)	p Value
Do you see the patient?	2	0	5	14	NA	
Steroids within 24 h?	5	18	7	1	0.4 (0.004 to 0.403)	0.002
Steroids within 3 d?	5	14	7	5	0.255 (0.05 to 1.19)	0.07
Steroids within 7 d?	2	4	10	15	0.75 (0.11 to 4.9)	0.35
Steroids in pregnancy?	1	3	9	14	0.52 (0.05 to 5.8)	0.39
Steroids in Ramsay Hunt?	2	5	10	12	0.48 (0.08 to 3.03)	0.26
Steroids in complete syndrome?	3	14	9	5	0.12 (0.02 to 0.63)	0.01
Steroids in partial syndrome?	3	9	8	9	0.38 (0.08 to 1.89)	0.15
Do you give acyclovir?	1	3	8	11	0.46 (0.04 to 5.3)	0.37

CI, confidence interval; OR, odds ratio.

## COMMENT

Although many neurologists advise steroids and some would recommend acyclovir, the uncertainty regarding the treatment of Bell's palsy is reflected in our questionnaire responses.

The majority of responders indicated that their advice was not based on local guidelines and many commented on the lack of evidence. Some felt it was imperative to discuss the uncertainty with the patient; others that better randomised controlled trials are needed.

A new Scotland based randomised controlled trial will start later this year (Morrison J, personal communication). This study, coordinated by primary care physicians and ear, nose and throat surgeons, will compare four treatment arms (comprising steroids, acyclovir, placebo) within 48 to 72 hours of onset. Assessment of treatment effect will include photographs and questionnaires about objective and subjective outcomes. The aim is to recruit up to 720 patients, of whom 480 will have begun treatment within 48 hours of onset. Given the annual incidence of Bell's palsy in Scotland, the researchers estimate that this will take up to 18 months. Uncertainty in managing this condition can only be resolved by well conducted randomised controlled trials.

**M Shaw**

Glasgow Royal Infirmary, 10 Alexandra Parade,  
Glasgow G31 2ER, UK

**F Nazir, I Bone**

Southern General Hospital, Govan Road, Glasgow

Correspondence to: Dr Monica Shaw;  
drmonicashaw@hotmail.com

doi: 10.1136/jnnp.2004.048439

Competing interests: none declared.

## APPENDIX

### Bell's palsy questionnaire

1. How frequently in the last 3 months have you received a query from a GP about treatment of a Bell's palsy? \_\_\_\_\_
2. Do you arrange to see the patient before giving advice? Yes/No \_\_\_\_\_
- If you are satisfied with the clinical diagnosis: 3. Would you advise steroids

- within 24 hours? Yes/No
  - within 3 days? Yes/No
  - within 7 days? Yes/No
  - in pregnancy? Yes/No
  - with Ramsay Hunt syndrome? Yes/No
  - with complete facial palsy (loss of taste/hyperacusis)? Yes/No
  - with partial facial palsy? Yes/No
4. If steroids are advised, what regime would you suggest? \_\_\_\_\_
  5. Is the advice you give on steroids based on local guidelines? Yes/No
  6. Would you advise acyclovir? Yes/No
  - If yes:
    7. Is the advice you give on acyclovir based on local guidelines? Yes/No
    8. Any additional comments:

## References

- 1 **Martyn CN**, Hughes RAC. Epidemiology of peripheral neuropathy. *J Neurol Neurosurg Psychiatry* 1997;**62**:310-18.

- 2 **Peitersen E**. The natural history of Bell's palsy. *Am J Otol* 1982;**4**:107-11.
- 3 **Cochrane review**. Acyclovir for Bell's palsy (idiopathic facial paralysis). 2003;**3**.
- 4 **Cochrane review**. Corticosteroids for Bell's palsy (idiopathic facial paralysis). 2003;**3**.

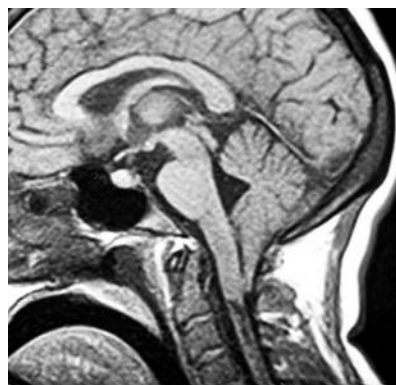## Ondine's curse during pregnancy

We report a case of a 34 year old right handed woman seen at 29 weeks' gestation who suffered from apnoea of unknown aetiology. This pregnancy, as well as her first gestation, was complicated by generalised oedema and high blood pressure. Starting at week 25, her husband noticed she had developed intermittent brief periods of apnoea only while sleeping, which lasted as long as one minute but of variable duration. Her husband awakened her each time she had a protracted episode of apnoea. She was asymptomatic while awake. In the 29th week she suffered a more severe apnoea. She was intubated in the field and taken to the hospital for an emergency caesarean section. There was no spontaneous labour. Inability to breathe spontaneously persisted for two weeks post-partum and a neurological consultation was requested.

On initial evaluation blood pressure was 140/90 and the heart rate was 90 beats/min. The neurological examination revealed upbeat nystagmus of small amplitude in the primary position which did not change with upward or downward gaze. She had lack of spontaneous breathing. She was fully awake and cooperative, sitting up in bed with no assistance. While intubated she had an obvious cough reflex but the gag reflex was not formally tested. Tongue examination showed normal movement and power with no evidence of atrophy or fasciculation. Otherwise, cranial nerve and sensorimotor examinations were entirely normal. There was normal tone, with downgoing plantar reflexes and no evidence of other pyramidal findings. There was no record of arrhythmia. No yawning, vomiting, or hiccups were present during the examination and they were not seen by nursing staff.

It was of interest that this patient had suffered from apnoea presenting immediately after her first vaginal delivery two years previously. This was treated with intubation and resolved spontaneously with successful extubation approximately four hours later.

Magnetic resonance imaging of the brain, brain stem, and cervical spinal cord was



**Figure 1** Magnetic resonance imaging of the brain (sagittal section) showing a Chiari malformation with tonsillar herniation at C2 level and a cervical syrinx.

carried out, and showed a Chiari malformation with tonsillar herniation at C2 level and a cervical syrinx.

After posterior cranial fossa decompression the patient recovered spontaneous breathing and was off any ventilatory support within six hours. She and her child have been followed for two years following this event. She remains in good health with normal polysomnographic testing.

## COMMENT

Ondine's curse is a rare form of central respiratory failure which includes severe sleep apnoea.<sup>1</sup> We describe the case of recurrent sleep apnoea associated with pregnancy and delivery and related to a Chiari malformation that became symptomatic only during pregnancy. We hypothesise that the generalised oedema that occurred during pregnancy, with a potentially mild increase in intracranial pressure, produced dysfunction of central chemoreceptors or the respiratory integrative system of the brain stem. Additionally there may have been compression of the lower cranial nerves, impairing input from peripheral chemoreceptors.<sup>2</sup> Related to this, our patient suffered severe sequelae from a central malformation that was previously clinically inapparent. Although Ondine's curse has rarely occasionally described in patients with Chiari malformation,<sup>3</sup> the expression of secondary sleep apnoea uniquely during pregnancy has not been reported before. Finally we wish to highlight the complete recovery of this patient after posterior fossa decompression, as we found in another published case.<sup>4</sup>

**J J Ochoa-Sepulveda, J J Ochoa-Amor**

Neurology Department, "Hospital Universitario Reina Sofia", 14012 Cordoba, Spain

Correspondence to: Dr Juan Ochoa-Sepulveda;  
jjos@telefonica.net

doi: 10.1136/jnnp.2004.048025

Competing interests: none declared

## REFERENCES

- 1 **Severinghaus JW**, Mitchell RA. Ondine's curse: failure of respiratory center automaticity while awake. *Clin Res* 1962;**10**:122.
- 2 **Botelho RV**, Bittencourt LR, Rotta JM, et al. Polysomnographic respiratory findings in patients with Arnold-Chiari type I malformation and basilar invagination with or without syringomyelia: preliminary report of a series of cases. *Neurosurg Rev* 2000;**23**:151-5.
- 3 **Levitt P**, Cohn MA. Sleep apnea and the Chiari I malformation: case report. *Neurosurgery* 1988;**23**:508.
- 4 **Gupta R**, Oh U, Spessot A, et al. Resolution of Ondine's curse after suboccipital decompression in a 72-year-old woman. *Neurology* 2003;**61**:275-6.

## Gender influence on the progression of HTLV-I associated myelopathy/tropical spastic paraparesis

HTLV-I associated myelopathy/tropical spastic paraparesis (HAM/TSP) is a chronic and disabling disease caused by the human T-lymphotropic virus type I. Onset of the disease is insidious and the disease usually progresses slowly over years.<sup>1</sup> However, there have been reports of the rapid evolution of HAM/TSP over months or even weeks. The

basis for these different progression patterns is poorly understood and only a few studies have dealt with this matter.<sup>2</sup> The present study aimed at evaluating a Brazilian HAM/TSP population for possible factors implicated in the progression of the disease.

## Methods

We reviewed the files of 338 HTLV-I infected patients evaluated at the outpatient clinic of the Reference Centers for Neurological Infections and HTLV-I, Evandro Chagas Clinical Research Institute (IPEC), FIOCRUZ, Rio de Janeiro, Brazil. Patients were included in the study if they fulfilled the World Health Organization criteria for HAM/TSP,<sup>1</sup> but were excluded if they had concurrent infections or other disabling diseases that could interfere with clinical progression. The eligible patients were submitted to a clinical questionnaire and physical examination between June 2002 and February 2003. Clinical severity was evaluated using the IPEC disability scale (table 1), which was

developed exclusively for the prospective assessment of HAM/TSP.<sup>3</sup> We evaluated clinical progression using a disease progression index (DPI) defined as the IPEC disability final score divided by the duration of the disease, from onset of symptoms, in years. We used this value to divide our sample into quartiles. Patients whose values were under the 25th percentile were called slow progressors and patients whose values were above the 75th percentile were called fast progressors. Both groups were compared for their demographic and clinical characteristics using Fisher's test. DPI values were compared using the Mann-Whitney U test. All p values were two sided and an  $\alpha = 0.05$  was employed.

## Results

A total of 250 individuals were excluded due to lack of neurological disease or the presence of concurrent infections. The mean age of the remaining 88 individuals was 53.1 years, and there were more women (68.2%) than men.

The mean age at onset was 40.7 years and the mean duration of disease was 12.5 years.

Comparison between the fast ( $n = 22$ ) and the slow ( $n = 22$ ) progression groups showed a significantly higher prevalence of women in the former group ( $p = 0.02$ ). Statistical analysis of other variables failed to show significant differences.

To evaluate the possible role of sex hormones in this difference, because the mean age of menopause is around 50 years,<sup>4</sup> we compared men and women according to age at onset of the disease (early onset:  $<50$  years; late onset:  $\geq 50$  years). The mean DPI of women and men were, respectively, 1.79 and 1.17 ( $p = 0.009$ ) in the early onset group ( $n = 66$ ; 66% women) and 2.59 and 1.78 ( $p = 0.731$ ) in the late onset group ( $n = 22$ ; 68% women), suggesting that women have a faster progression than men if the disease starts before the menopause.

## Discussion

This is the first study to suggest that HAM/TSP progresses faster in women than in men. This difference seems to be particularly important in women whose disease started before the menopause. Although gender differences regarding the clinical evolution of HAM/TSP have not been reported before, there has been evidence of a disproportional number of women with this disease. Firstly, there is a worldwide female to male preponderance of HAM/TSP patients ranging from 1.5:1 to 3.5:1.<sup>5</sup> Secondly, Nagai *et al* analysed the proviral load of 202 HAM/TSP patients and 243 asymptomatic HTLV-I carriers and found a significantly higher proviral load in female patients when compared to males.<sup>6</sup> It is well known that a higher proviral load is associated with the development of clinical disease.

The reason for the gender difference in our study is unknown, but it is possible that sex hormones play a role in the evolution of the disease. To test this hypothesis, we compared the DPI of patients whose disease had started before and after the age of 50, the mean age of the menopause. The finding of a significantly worse evolution in the female group with early onset of disease, coupled with no significant gender difference being observed in the late onset group, suggests that female hormones may be implicated in HAM/TSP pathogenesis and that their presence at higher levels may be associated with a faster clinical progression. Further support for this idea is provided by the beneficial effects of danazol, an androgenic drug, in the treatment of some HAM/TSP cases.<sup>7</sup>

In summary, we found evidence of worse clinical progression in women with HAM/TSP compared to men. We hypothesise that sex hormones may account for this difference. If confirmed by further studies, this information may lead to a better understanding of the mechanisms involved in HAM/TSP pathogenesis and suggest different treatment options.

**M A S D Lima, R B S Bica**

Federal University of Rio de Janeiro (UFRJ),  
Clementino Fraga Filho University Hospital (HUCFF),  
Rio de Janeiro, Brazil

**A Q C Araújo**

Reference Centers on Neuroinfections and HTLV,  
Evandro Chagas Institute of Clinical Research (IPEC),  
FIOCRUZ, Rio de Janeiro, Brazil

**Table 1** The IPEC disability scale

Motor score: Gait
0. Normal
1. Abnormal but can walk independently
2. Abnormal and dependent on eventual unilateral support
3. Abnormal and dependent on permanent unilateral support
4. Abnormal and dependent on eventual bilateral support
5. Abnormal and dependent on permanent bilateral support
6. Abnormal, dependent on permanent bilateral support, and occasional use of a wheelchair (WC)
7. Permanent use of a WC, stands up, and remains upright without support
8. Permanent use of a WC, uses arms to stand up, and remains upright without support
9. Permanent use of a WC, needs assistance from others to stand up and remain upright with support
10. Permanent use of a WC, unable to stand up, exhibits voluntary movements of the lower limbs when seated
11. Permanent use of WC, unable to stand up, and does not have any voluntary movements of the lower limbs
Motor score: Running
0. Runs
1. Unable to run
Motor score: Climbing stairs
0. Climbs
1. Climbs only when holding the handrail
2. Unable to climb
Motor score: Jumping
0. Jumps on one or two feet
1. Jumps on two feet, but not with only one
2. Jumps on two feet only with hand support
3. Unable to jump
Spasticity score: Clonus
0. Absent
1. Only induced by the examiner
2. Spontaneous
Spasticity score: Flexor/extensor spasms
0. Absent
1. Present
Sensory score: Paresthesias
0. Absent
1. Present, eventually
2. Present, permanently
Sensory score: Lumbar and/or lower limb pain
0. Absent
1. Present, eventually
2. Present during most of the day
Sphincter score: Bladder control
0. Total
1. Urgency
2. Eventual incontinence or retention
3. Use of permanent catheter or regular use of relieve catheter
Sphincter score: Bowel continence
0. Normal
1. Constipation
2. Incontinence or total retention, needs manual extraction or enemas
Total: 0-29

Correspondence to: Marco Antonio S D Lima, 109  
Queensberry Street #12, Boston, MA 02215, USA;  
mdelima@bidmc.harvard.edu

doi: 10.1136/jnnp.2004.035709

Competing interests: none declared

## References

- 1 **Osame M.** *Review of WHO Kagoshima meeting and diagnostic guidelines for HAM/TSP*, 1st ed. New York: Raven Press, 1990.
- 2 **Kuroda Y, Fujiyama F, Nagumo F.** Analysis of factors of relevance to rapid clinical progression in HTLV-I-associated myelopathy. *J Neurol Sci* 1991;**105**(1):61–6.
- 3 **Oliveira AL, Bastos FI, Afonso CR.** Measurement of neurologic disability in HTLV-I associated myelopathy: validation of a new clinical scale. *AIDS Res Hum Retroviruses* 1992;**17**(suppl):S65.
- 4 **Greenblatt RB.** Fertility in the middle-aged woman. *IPPF Med Bull* 1980;**14**(4):2–4.
- 5 **Gessain A, Gout O.** Chronic myelopathy associated with human T-lymphotropic virus type I (HTLV-I). *Ann Intern Med* 1992;**117**(11):933–46.
- 6 **Nagai M, Usuku K, Matsumoto W, et al.** Analysis of HTLV-I proviral load in 202 HAM/TSP patients and 243 asymptomatic HTLV-I carriers: high proviral load strongly predisposes to HAM/TSP. *J Neuroviral* 1998;**4**(6):586–93.
- 7 **Harrington WJ Jr, Sheremata WA, Snodgrass SR, et al.** Tropical spastic paraparesis/HTLV-1-associated myelopathy (TSP/HAM): treatment with an anabolic steroid danazol. *AIDS Res Hum Retroviruses* 1991;**7**(12):1031–4.

## Plasma VEGF as a marker for the diagnosis and treatment of vasculitic neuropathy

Vasculitic neuropathy is treatable with immunotherapy. However, histological evidence of vasculitis is not always obtained from nerve and muscle biopsies.<sup>1</sup> In particular, in cases of non-systemic vasculitic neuropathy showing no or minimum abnormal findings in serological tests, negative biopsy results cause considerable difficulty in the diagnosis.<sup>1</sup>

Vascular endothelial growth factor (VEGF) is a potent, multifactorial cytokine.<sup>2</sup> VEGF is derived from endothelial cells and pericytes in response to hypoxia, and induces angiogenesis and microvascular hyperpermeability through its binding to VEGF receptors.<sup>2</sup> Vascular involvement by vasculitic neuropathy results in hypoxia. It was reported that VEGF was overexpressed in vasculitic lesions in biopsied sural nerves, and that plasma VEGF levels were found to be raised in dermatomyositis with peripheral neuropathy.<sup>3</sup> These findings suggest that VEGF levels may be increased in patients with vasculitic neuropathy. Although an increase in plasma or serum VEGF concentrations has been reported in some patients with systemic vasculitis,<sup>3</sup> there have been no studies to evaluate plasma VEGF in a series of patients with vasculitic neuropathy. With respect to VEGF levels in neuropathies, a marked increase in serum levels was reported in the Crow-Fukase (POEMS) syndrome.<sup>4</sup> In addition, alterations in VEGF are associated with cancer and diabetes mellitus, and VEGF is involved in the angiogenesis of these diseases.

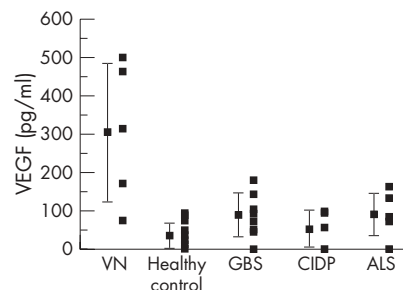
In this study, we investigated the plasma VEGF concentrations in patients with vasculitic neuropathy in comparison with other neuropathies. After obtaining informed consent, samples were obtained from five patients with vasculitic neuropathy confirmed by muscle or sural nerve biopsies. They all presented with neuropathy as a

cardinal manifestation, and included three patients with polyarteritis nodosa, one with vasculitic neuropathy associated with Sjögren syndrome, and one with non-systemic vasculitic neuropathy. None of the patients were on drug treatment at the time of sampling. After disease remission was achieved by treatment with corticosteroids or other immunosuppressants, we analysed plasma VEGF again in three of the patients, including two with polyarteritis nodosa and one with Sjögren syndrome. As a control group, we used plasma from 18 age matched healthy volunteers, eight patients with Guillain-Barré syndrome, five with chronic inflammatory demyelinating polyradiculoneuropathy (CIDP), and seven with amyotrophic lateral sclerosis, after obtaining informed consent. Patients with diabetes mellitus or cancer were not included in the study.

Venous blood was sampled into an EDTA tube with minimal stasis. The sample was centrifuged and the plasma VEGF concentration was determined by a quantitative sandwich-enzyme immunoassay technique using a Quantikine kit (R&D Systems, Minneapolis, Minnesota, USA). As VEGF is secreted by platelets in the clotting process,<sup>5</sup> we measured plasma samples, not sera, to evaluate the circulating VEGF level precisely.

Differences between the groups were tested by the Kruskal-Wallis test and the Mann-Whitney U test. Differences were considered significant when the probability (p) value was <0.05. Significance tests for group differences were computed with StatView v5.0 (SAS Institute, Cary, North Carolina, USA).

The mean (SD) plasma VEGF concentrations in patients with vasculitic neuropathy (303 (182) pg/ml) were significantly higher than in the healthy controls (30.9 (31.7) pg/ml) (p<0.01) as well as in patients with Guillain-Barré syndrome (85.7 (57.3) pg/ml) (p<0.05), CIDP (49.9 (48.3) pg/ml) (p<0.05), and amyotrophic lateral sclerosis (88.1 (55.7) pg/ml) (p<0.05) (fig 1). There was no statistical difference in plasma VEGF concentrations between healthy controls and patients with CIDP, Guillain-Barré syndrome, or amyotrophic lateral sclerosis. The plasma VEGF concentrations in patients with vasculitic neuropathy before treatment (423 (97.1) pg/ml) decreased significantly after successful treatment with corticosteroids or other immunosuppressants, to 150 (114) pg/ml (p<0.05). One case with polyarteritis nodosa and the patients with vasculitic neuropathy associated with Sjögren syndrome had a



**Figure 1** Plasma levels of vascular endothelial growth factor (VEGF) in patients with vasculitic neuropathy (VN), healthy controls, Guillain-Barré syndrome (GBS), chronic inflammatory demyelinating polyradiculoneuropathy (CIDP), and amyotrophic lateral sclerosis (ALS).

marked decrease in plasma VEGF after treatment (from 461 to 91.3 pg/ml and from 496 to 77.8 pg/ml, respectively). In the other patient with polyarteritis nodosa, the plasma VEGF levels decreased mildly, from 313 to 281 pg/ml.

## COMMENT

Our results indicated that increased plasma VEGF could be a useful marker for the diagnosis of vasculitic neuropathy and for monitoring a therapeutic effect.

This is the first report to show a significant increase in plasma VEGF levels in patients with vasculitic neuropathy compared with other neuropathies. As our patients with vasculitic neuropathy did not have cancer or diabetes mellitus, and as the plasma VEGF concentrations were significantly decreased after treatment, we consider that VEGF would be secreted into blood by the vasculitic lesions in this conditions. We could find no significant increase in plasma VEGF levels in CIDP, Guillain-Barré syndrome, or amyotrophic lateral sclerosis. Vasculitic neuropathy may present with clinical manifestations similar to CIDP or other peripheral neuropathies.<sup>1</sup> The increase in plasma VEGF could be a helpful marker to distinguish vasculitic neuropathy from CIDP and other peripheral neuropathies in such patients.

Although our results indicate the potential value of plasma VEGF as a marker in the diagnosis and treatment of vasculitic neuropathy, the significance of the results is limited by the relatively small number of patients. Further studies with a larger study population are necessary to confirm our results.

**K Sakai, K Komai, D Yanase, M Yamada**  
Department of Neurology and Neurobiology of  
Aging, Kanazawa University Graduate School of  
Medical Science, Kanazawa 920-8640, Japan

Correspondence to: Dr K Sakai; ksakai@med.  
kanazawa-u.ac.jp

doi: 10.1136/jnnp.2004.047571

Competing interests: none declared

## References

- 1 **Collins MP, Periaquet MI, Mendell JR, et al.** Nonsystemic vasculitic neuropathy insights from a clinical cohort. *Neurology* 2003;**61**:623–30.
- 2 **Nomura M, Yamaguchi S, Harada S, et al.** Possible participation of autocrine and paracrine vascular endothelial growth factors in hypoxia-induced proliferation of endothelial cells and pericytes. *J Biol Chem* 1995;**270**:28316–24.
- 3 **Matsui N, Mitsui T, Endo I, et al.** Dermatomyositis with peripheral nervous system involvement: activation of vascular endothelial growth factor (VEGF) and VEGF receptor (VEGFR) in vasculitic lesions. *Intern Med* 2003;**42**:1233–9.
- 4 **Watanabe O, Arimura K, Kitajima I, et al.** Greatly raised vascular endothelial growth factor in POEMS syndrome. *Lancet* 1996;**347**:702.
- 5 **Maloney JP, Silliman CC, Ambruso DR, et al.** In vitro release of vascular endothelial growth factor during platelet aggregation. *Am J Physiol* 1998;**275**:1054–61.

## Acute aspiration pneumonia due to bulbar palsy: an initial manifestation of posterior fossa convexity meningioma

False localising signs of intracranial lesions are defined as signs not generally associated with disturbances of function at the site of

the lesion.<sup>1,2</sup> An intracranial tumour which has not metastasised may give rise to focal signs of disordered nervous function at a distance from itself in a number of ways. Even though these neurological signs are labelled as false localising signs, it is important to be aware that such signs are in no way "false".<sup>3</sup> Various cranial nerve palsies have been reported as false localising signs, with the sixth cranial nerve being the most common.<sup>1</sup> According to Gassel, ninth to 12th cranial nerve palsies never provide false localisation.<sup>1</sup> Since Dodge reported the first case of false localising sign involving the lower cranial nerve, only two cases have been reported in the literature.<sup>4</sup> We report a third case of false localising sign involving the left ninth and 10th cranial nerves.

A 29 year old man presented to the medical department of our hospital with history of hoarseness of voice of 15 days duration, dysphagia of 1 week duration, and cough with expectoration and respiratory distress of 2 days duration together with history of fever. On examination, he was febrile, with a pulse of 100 bpm and blood pressure of 120/80 mm Hg. Respiratory examination revealed bilateral coarse crepitations. Neurological examination revealed absent gag reflex on the left side with deviation of the palate to the right side without any other neurological deficit. Indirect laryngoscopic examination revealed paralysis of left vocal cord.

Haematological examination revealed haemoglobin (Hb) 13.6%, a WBC count of 16 800/mm, and an erythrocyte sedimentation rate (ESR) of 120 mm/h. Chest x ray of the patient revealed bilateral pneumonitis. He was treated with antibiotics according to culture sensitivity. He progressively improved and was discharged. At discharge, he had persistent hoarseness of voice and vocal cord palsy on the left side. About 4 weeks later he presented with a history of bifrontal headache and was referred to our department. Neurological examination revealed bilateral papilledema and left palatal palsy with absent gag reflex. Other cranial nerves were normal. Motor and sensory system examination was normal. Occasional swaying to the

left side on tandem walking suggested involvement of the cerebellar system. In view of these findings, a left posterior fossa mass lesion involving the lower cranial nerves such as a schwannoma was suspected. However, magnetic resonance imaging (MRI) of the brain revealed a large isointense homogeneously enhancing mass lesion attached to the convexity dura (fig 1). It also revealed evidence of herniation of the cerebellar tonsils below the margin of the foramen of magnum and anterior displacement of the cerebellum causing stretching of the lower cranial nerves on the left side. The patient underwent midline suboccipital craniotomy and total excision of the lesion. The cerebellum was found compressed and deeply indented by the tumour. Postoperatively he improved neurologically. His gag reflex and palatal movements progressively improved and he was asymptomatic at 2 month follow up.

False localising signs are unexpected neurological deficits and reflect pathology distant from the expected anatomical locus. Prominent false localising signs are less common today, as diagnosis is usually made at an early stage.<sup>4</sup> Cranial nerve involvement as a false localising sign is found in 12.5% of cerebral tumours.<sup>2</sup> According to Gassel, false localising signs are more common in patients with signs of raised intracranial pressure. Due to the long intracranial course, sixth cranial nerve palsy is commonly associated with supratentorial mass lesions as a false localising sign.<sup>1</sup> Most reports described single cranial nerve disturbance as a false localising sign. Rarely have multiple cranial nerve palsies been reported as false localising signs.<sup>4,5</sup>

Ehni proposed various mechanisms responsible for false localising signs. These include: (i) general compression of a nerve having a long course; (ii) meningitis; (iii) oedema and gliosis; (iv) metastatic deposits; (v) infarctions at a distance from the primary lesion due to occlusion of a vessel by a neoplasm or by cerebral herniation through a dural aperture; (vi) gross brain displacement involving the brainstem and causing traction of cranial nerves and kinking of cranial nerves over vessels; and (vii) brain stem

shifting to the opposite side causing tentorial notching, pressure at the rim of the foramen magnum, pressure at points of emergence of cranial nerves, and involvement of the corticospinal tract.<sup>6</sup> Gassel pointed out that false localising signs are commonly associated with intracranial meningiomas as they are discrete tumours that tend to compress and displace the brain rather than infiltrate cerebral tissues.<sup>1</sup> He also commented upon the rigidity of the bony skull and its dural compartments, as well as the outcome of pressure within the skull causing movement of parts of the brain towards the tentorial opening and foramen magnum resulting in herniation pressure on various blood vessels.<sup>1</sup> O'Connell suggested that displacement of the brainstem by the tumour results in slackening of the horizontally directed nerves such the seventh to 11th cranial nerves and stretching of the anteriorly directed nerves such as the fifth and sixth around the lateral margin of the dural foramen.<sup>7</sup> Matsuura and Kondo proposed that displacement rather than rotation of the brainstem, causing compression and/or angulation of the affected nerve rather than stretching or traction, is the most significant factor for inducing contralateral trigeminal neuralgia and hemifacial spasm.<sup>5</sup> However, according to Haddad and Taha, rotation of the brainstem shifts the basilar artery or loop of its branches close to the trigeminal nerve at its root entry zone and causes trigeminal neuralgia.<sup>8</sup>

Most cranial nerve dysfunctions presenting as false localising signs appear as hypoactive dysfunctions.<sup>1,6</sup> Rarely has hyperactive dysfunction syndrome involving the cranial nerve, such as trigeminal neuralgia or hemifacial spasm, been reported in the literature.<sup>5,8</sup> False localising sign involving lower cranial nerves is extremely rare with just two cases reported in the literature.<sup>4</sup> Maurice-Williams proposed two mechanisms causing lower cranial nerve palsy: firstly, cerebellar hemisphere impacting the foramen magnum, causing reaction and oedema and thereby compression of the lower cranial nerve and secondly, displacement of the cerebellum to the contralateral side, forcing the brainstem to the ipsilateral side and thus exerting traction on the contralateral lower cranial nerve.<sup>4</sup> The case reported here involved a large cerebellar convexity meningioma causing cerebellar herniation downwards into the foramen magnum and anteriorly into the lateral cerebello-medullary cistern which resulted in stretching of the lower cranial nerves. The cranial nerve function improved following excision of the tumour. Awareness of the possibility of false localising signs and the conditions in which they are most likely to occur is very important as they may be indicative of serious life threatening pathology within the neural pathway.<sup>3</sup>

S N Shenoy, A Raja

Department of Neurosurgery, Kasturba Medical College and Hospital, Manipal, India

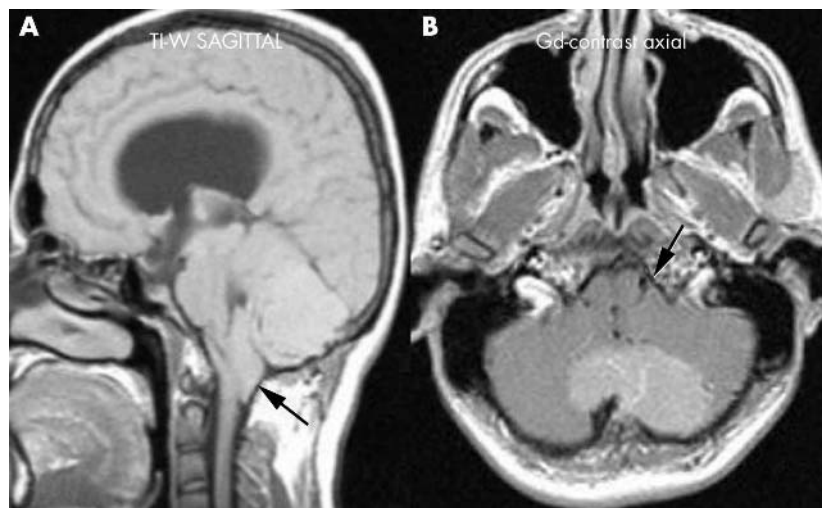
Correspondence to: Satyanarayana N Shenoy, Department of Neurosurgery, Kasturba Medical College and Hospital, MANIPAL-576 119, UDUPI, Karnataka, India; shenoysn@yahoo.com

doi: 10.1136/jnnp.2004.040444

Competing interests: none declared

## References

- 1 Gassel MM. False localizing signs. A review of the concept and analysis of the occurrence in 250



**Figure 1** MRI of the brain. (A) Sagittal section shows herniation of the tonsils below the foramen magnum due to an isointense mass lesion (arrow). (B) Axial T1 weighted image showing isointense mass lesion, enhanced homogeneously with gadolinium, causing compression of the cerebellum and anterior displacement of the cerebellum into the lateral cerebello-medullary cistern resulting in stretching of the lower cranial nerves (arrow).



- cases in intracranial meningioma. *Arch Neurol* 1961;**4**:526–54.
- 2 Collier J. The false localizing signs of intracranial tumours. *Brain* 1904;**27**:490–505.
  - 3 Larner AJ. False localising signs. *J Neurol Neurosurg Psychiatry* 2003;**74**(4):415–8.
  - 4 Maurice-Williams RS. Multiple crossed false localizing signs in a posterior fossa tumour. *J Neurol Neurosurg Psychiatry* 1975;**38**:1232–4.
  - 5 Matsuura N, Kondo A. Trigeminal neuralgia and hemifacial spasm as false localizing signs in patients with a contralateral mass of the posterior cranial fossa. Report of three cases. *J Neurosurg* 1996;**84**:1067–71.
  - 6 Ehni G. False localizing signs in intracranial tumour. Report of a patient with left trigeminal palsy due to right temporal meningioma. *Arch Neurol Psychiatry* 1950;**64**:692–8.
  - 7 O'Connell JEA. Trigeminal false localizing signs and their causation. *Brain* 1978;**101**:119–42.
  - 8 Haddad FS, Taha JM. An unusual case of trigeminal neuralgia: contralateral meningioma of the posterior fossa. *Neurosurgery* 1990;**26**:1033–8.

## Acquired Chiari 1 malformation and syringomyelia following lumboperitoneal shunting for pseudotumour cerebri

An important but not widely recognised complication of lumboperitoneal shunting is the development of a Chiari 1 deformity and syringomyelia. We present a case of a patient who developed symptomatic cerebellar tonsillar descent and syrinx formation following treatment of pseudotumour cerebri with lumboperitoneal shunting.

### Case report

A 31 year old woman was diagnosed with pseudotumour cerebri following development of headaches, loss of vision, and papilloedema, in association with a cerebrospinal fluid (CSF) opening pressure of 36 cm H<sub>2</sub>O. Cranial imaging showed an attenuated ventricular system and no other abnormality. In particular, the posterior fossa was satisfactory in appearance. She was treated with lumboperitoneal shunt insertion, with resolution of her symptoms.

Twelve months later, the patient reported a 6 month history of left hemisensory loss, left arm weakness, and unsteadiness. Neurological examination revealed wasting and reduced power of the intrinsic muscles of the left hand, and left-sided hyperaesthesia to pin-prick. Magnetic resonance (MR) imaging showed the development of cerebellar tonsillar descent and syringomyelia throughout the cervico-thoracic spinal cord. The patient underwent insertion of a low pressure ventriculoperitoneal shunt and removal of the lumboperitoneal shunt, with subsequent symptomatic improvement. There was, however, no resolution of the syrinx on follow up MR imaging.

### Discussion

The development of cerebellar tonsillar descent is a recognised but rarely reported complication following lumboperitoneal shunting,<sup>1–5</sup> usually in the treatment of communicating hydrocephalus.<sup>1,3,5</sup> It has been reported to occur in a large proportion of paediatric patients undergoing this procedure, with Chumas *et al* reporting a 70% incidence in this age group,<sup>1</sup> but its incidence in the adult population is undefined. The development of secondary syringomyelia appears to be much less common, with the

above paediatric patients reporting an incidence of syrinx formation of 4%. The development of Chiari 1 and syringomyelia formation following lumboureteral shunting for the treatment of pseudotumour cerebri is recognised but has been less commonly reported.<sup>2,4,5</sup>

There is a small number of papers reporting chiari development following lumbar shunting for communicating hydrocephalus in children, but only two case reports of syringomyelia formation.

The association of syrinx formation and cerebellar tonsillar descent through the foramen magnum is well described,<sup>6</sup> and is postulated to occur as a consequence of a cranial-spinal CSF pressure gradient and diversion of CSF down the central canal of the spinal cord rather than over the cerebral convexities.<sup>3,4,6</sup> It would seem remarkable that this complication is not seen more commonly in the treatment of pseudotumour cerebri.

The non-resolution of the syrinx, in our case following lumboperitoneal shunt removal, is consistent with other workers' experiences, although resolution has been reported in one instance.<sup>7</sup>

In conclusion, we describe the development of Chiari 1 deformity and syrinx formation as an important but otherwise poorly recognised complication of lumboperitoneal shunting in patients with pseudotumour cerebri.

R Padmanabhan, D Crompton, D Burn, D Birchall

Regional Neurosciences Centre, Newcastle upon Tyne, UK

Correspondence to: Daniel Birchall, Neuroradiology, Newcastle General Hospital, Newcastle upon Tyne NE4 6BE, UK; daniel.birchall@nuth.nhs.uk

doi: 10.1136/jnnp.2004.051276

Competing interests: none declared

### References

- 1 Chumas PD, Armstrong DC, Drake JM, *et al*. Tonsillar herniation: the rule rather than the exception after lumboperitoneal shunting in the pediatric population. *J Neurosurg* 1993;**78**:568–73.
- 2 Sullivan LP, Stears JC, Ringel SP. Resolution of syringomyelia and Chiari 1 malformation by ventriculoatrial shunting in a patient with pseudotumour cerebri and a lumboperitoneal shunt. *Neurosurgery* 1988;**22**:744–7.
- 3 Fischer EG, Welch K, Shillito J. Syringomyelia following lumboureteral shunting for communicating hydrocephalus. *J Neurosurg* 1977;**47**:96–100.
- 4 Hart A, David K, Powell M. The treatment of 'acquired tonsillar herniation' in pseudotumour cerebri. *Br J Neurosurg* 2000;**14**:563–5.
- 5 Johnston I, Jacobson E, Besser M. The acquired Chiari malformation and syringomyelia following spinal CSF drainage. *Acta Neurochir* 1998;**140**:417–28.
- 6 Williams B. The distending force in the production of 'communicating syringomyelia'. *Lancet* 1969;**4**:189–93.
- 7 Peerless SG. Commentary. *Neurosurgery* 1988;**22**:747.

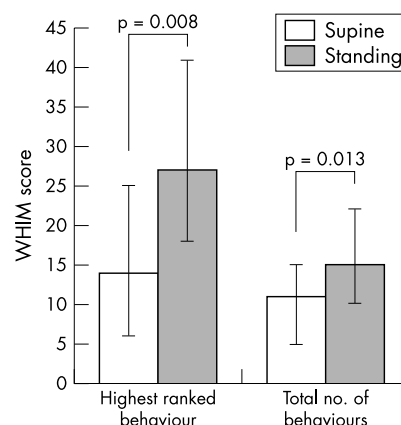
## Effect of posture on levels of arousal and awareness in vegetative and minimally conscious state patients: a preliminary investigation

Moderate to severe brain injury is estimated to occur in 25 individuals per 100 000 population every year. Of these, 10–20%

never fully regain consciousness but remain in a vegetative or minimally conscious state.<sup>1</sup> Patients in the vegetative state may appear at times to be wakeful, with cycles of eye closure and eye opening resembling those of sleep and waking, but show no sign of awareness or of a functioning mind.<sup>2</sup> In contrast, patients considered to be in a minimally conscious state are said to show inconsistent but definite evidence of awareness despite profound cognitive impairment.<sup>3</sup>

At present, the pathophysiology underlying the vegetative and minimally conscious states is unclear, a standard treatment approach is lacking, and very little has been discovered to advance rehabilitation techniques. It is widely acknowledged that active rehabilitation should begin early in the intensive care setting, and should be applied to all patients (including those who remain mechanically ventilated). However, this is not yet routine practice. Several reports have highlighted the generic benefits of early rehabilitation,<sup>4</sup> however, the benefits of specific interventions remain to be demonstrated. Over the last year, our group has investigated the effects of postural change on levels of arousal and awareness.

A total of 12 patients (eight men, four women; mean age 49 years, range 19–71) classified as either vegetative (n = 5) or minimally conscious (n = 7) according to international guidelines<sup>2,3</sup> were assessed using the Wessex Head Injury Matrix (WHIM), a 62 point score, which records the recovery of behaviours in brain injured patients.<sup>5</sup> Patients were assessed lying in bed, during a 20 minute period of standing using a tilt table at 85°, and again while lying in bed. During the observations blood pressure was measured using an oscillometric cuff. The observations were repeated over a one week period, and the median highest ranked behaviour and median total number of behaviours observed were recorded. The local research ethics committee approved all investigations. Informed assent was obtained from the next of kin.



**Figure 1** The median highest ranked behaviour and total number of behaviours observed in the lying and standing positions for both vegetative and minimally conscious patients. The highest rank ( $p=0.008$ ) and total number of behaviours ( $p=0.0013$ ) observed increased significantly in the standing position. Error bars indicate the interquartile range. WHIM, Wessex Head Injury Matrix.

**Table 1** Highest ranked behaviours recorded in the supine and standing positions for each patient

Patient	VS/MCS*	Supine score	Behaviour observed	Standing score	Behaviour observed
1	VS	43	Smiled	43	Smiled spontaneously
2	VS	4	Eyes held by painful stimulus <2 s	4	Eyes held by painful stimulus <2 s
3	VS	5	Looked at person briefly	26	Frowned/grimaced during physio
4	VS	1	Eyes opened briefly	49	Vocalised in response to pain
5	VS	14	Yawned, sighed	26	Frowned/grimaced during physio
6	MCS	13	Looked at person moving limbs <3 s	16	Turned eyes to look at person talking
7	MCS	20	Vocalised during physio	36	Switched gaze from one person to another
8	MCS	26	Frowned/grimaced in response to pain	34	Monosyllabic response to questions
9	MCS	14	Yawned, sighed	14	Yawned, sighed
10	MCS	18	Tracked for 3–5 seconds	28	Looked at object when requested
11	MCS	8	Made eye contact	23	Showed selective response to preferred people
12	MCS	42	Could find a card from four	43	Smiled spontaneously

\*Patient classification at the time of recruitment is denoted VS (vegetative state) or MCS (minimally conscious state).

We found that eight patients (three vegetative and five minimally conscious) showed consistent improvements in the highest ranked behaviours (table 1;  $p = 0.008$ ) and total number of behaviours ( $p = 0.013$ ) observed in the standing position (fig 1). Three patients (two vegetative and one minimally conscious) showed no change and one minimally conscious patient showed only an increase in the highest ranked behaviour observed. Although WHIM scores in three vegetative patients increased during standing, the behaviours observed did not reach a level suggesting awareness of self and/or environment. After standing the WHIM scores in the supine position were equal to or below those acquired before standing. No change in blood pressure was observed ( $p = 0.3$ ).

Our preliminary results suggest that positional changes may have a significant impact on behaviours in vegetative and minimally conscious patients. Although the benefit of this phenomenon in rehabilitation remains unproved, these findings have clear implications for the assessment and categorisation of patients. Neurological assessments used to classify patients according to international guidelines relating to the vegetative and minimally conscious states typically take place with the patient lying in bed. Where physical constraints permit, it may be important to also observe patients in the standing position.

## Acknowledgement

The authors are grateful to Dr R Barker for the neurological assessment.

### L Elliott

Department of Physiotherapy, Addenbrooke's NHS Trust, Cambridge, UK

### M Coleman

Wolfson Brain Imaging Centre, University of Cambridge, Cambridge, UK

### A Shiel

Faculty of Medicine, National University of Ireland, Galway, Ireland

### B A Wilson

MRC Cognition and Brain Sciences Unit, Cambridge, UK

### D Badwan

Royal Leamington Spa Rehabilitation Hospital, Warwick, UK

### D Menon

Wolfson Brain Imaging Centre, University of Cambridge, Cambridge, UK

### J Pickard

Wolfson Brain Imaging Centre, Cambridge, UK

Correspondence to: L Elliott, Senior Physiotherapist, Physiotherapy Department, Box 185, Addenbrooke's Hospital, Cambridge, CB2 2QQ, UK; louise.elliott@addenbrookes.nhs.uk

All authors are members of the Cambridge Coma Study Group

### Authors' contributions:

L Elliott—Principal investigator (data acquisition and patient recruitment).

A Shiel—Data acquisition and patient recruitment.

M Coleman—Data analysis and manuscript preparation

B Wilson—Project supervision.

D Badwan—Patient recruitment and data analysis.

D Menon—Project supervision.

J Pickard—Project supervision.

doi: 10.1136/jnnp.2004.047357

This work was funded by the Smiths Charity, the fund for Addenbrooke's and an MRC programme grant (number G9439390 ID 56833).

Competing interests: none declared

## References

- 1 Royal College of Physicians (UK). *Rehabilitation following acquired brain injury—National Clinical Guidelines*. London: Lavenham Press, 2003:8.
- 2 Royal College of Physicians (UK). The vegetative state: guidance on diagnosis and management. A report of a working party of the Royal College of Physicians. *Clin Med* 2003;2:249–54.
- 3 Giacino JT, Ashwal S, Childs N, et al. The minimally conscious state: definition and diagnostic criteria. *Neurology* 2002;58:349–53.
- 4 Talbot LR, Whitaker HA. Brain-injured persons in an altered state of consciousness: measures and intervention strategies. *Brain Injury* 1994;8(Pt 8):689–99.
- 5 Shiel A, Horn SA, Wilson BA, et al. The Wessex Head Injury Matrix (WHIM) main scale: a preliminary report on a scale to assess and monitor patient recovery after severe head injury. *Clin Rehabil* 2000;14:408–16.

## BOOK REVIEWS

### Neurological disorders in pregnancy

Edited by Jacqueline M Washington. Published by the Parthenon Publishing Group, 2004, £87.00 (hardcover), pp 150. ISBN 1-84214-189-9

Many neurological disorders occur in women of childbearing age. This small book is designed to bridge the wide gap existing between the disciplines of neurology and obstetrics. It provides a concise overview of the most common neurological disorders that may be seen during pregnancy. Three categories of problems are encountered by obstetricians and neurologists: management of neurological pre-existing disorders during pregnancy, neurological disorders directly due to pregnancy, and neurological affections that require special treatment considerations during pregnancy. The book covers these three categories with eight chapters devoted to migraine, cerebrovascular disease, epilepsy, back pain, multiple sclerosis, peripheral nerve disorders, myasthenia gravis, and central nervous infections. Each chapter includes consideration of the influence of pregnancy on the disorder, the effect of the disorder on pregnancy, and potential effects of proposed therapies on the developing foetus—all concerns shared by every clinician who care for pregnant women. The different chapters provide a useful resource with lists of dosages, contraindications, monitoring guidelines, and side effects of drugs in pregnancy.

Two other chapters, covering muscle diseases (in particular myotonic dystrophy) and brain tumours, could have been useful. One also could regret the nearly complete absence of figures or diagrams for a book intended not only for neurologists but also for obstetricians. In contrast, most chapters contain many useful tables.

A few remarks are also worth mentioning. For example, the section covering the course of migraine during and after pregnancy is sometimes redundant and could have been summarised. Post partum angiopathy should also be added to the aetiologies of postpartum headaches. In the chapter on cerebrovascular disease, eclampsia and hemorrhage sections could have been better detailed.

On the whole, this book represents a useful concise text (more than in-depth literature summary or detailed analysis of complex issues) written in a balanced, practical, and informative way. It can be used by a wide audience and will facilitate understanding and treatment of neurologic problems in pregnant women.

C Lamy

### The neuropathology of dementia, 2nd edition

Edited by M Esiri, M-Y Lee, J Q Trojanowski. Published by Cambridge University Press, Cambridge, 2004, £195.00, pp 563. ISBN 0-5218-1915-6

Inspecting the hardcover graphics of this new edition your reviewer was startled to find blazoned his comments on the previous, and first, edition to encourage your purchase. It is therefore clear that I am a supporter of this enterprise in principle – though modesty will prevail and I will not flaunt my prescience in

remarking on the desirability of this latest, and any subsequent, redrafting.

I regret that this review will not take the form of a direct comparison between the present and previous editions since my recollection of the former is based on a fading and rose-tinted affection, rather than direct consultation with the source material. Obsessionality is a professional hazard in neuropathology—either acquired or innate—but in my case it does not extend to detailed record keeping of book loans. I hope the trainee who chose to keep the book has had much joy of it. No doubt his extended loan reflects the esteem he/she felt for the educational value of the first edition.

There is no doubt that the present book is considerably larger, reflecting significant increased content. However there is no flab, and the overall size and scope are, respectively, manageable and focussed. The book has acquired distinguished American co-editors in place of Dr James Morris (whose career trajectory has taken him deep into health service management) but much of James's contribution remains, suitably updated, as a core of practical advice related to the diagnostic process in dementia neuropathology, and the particular pathologies associated with Alzheimer's disease and Vascular dementia. The latter section particularly reflects his welcome and homespun wisdom in an area fraught with unresolved problems of clinicopathological correlation. I am glad they have retained it. Similarly the contribution to the text by Professor Esiri shares this feeling of direct personal tutoring from an approachable expert. The editors have also retained the previous structure, roughly summarisable as: what dementia is, where in the brain might be affected, how to go about a pathological survey of a dementia brain, and, finally, what you might find related to specific diagnostic categories. This comprehensive approach is now fleshed out by the introduction of more authors to bring expertise related to individuals' conditions, additional "introductory" material about the clinical genetics of dementia (styled "molecular diagnosis" for some reason) and neuroimaging in dementia, and increased content reflecting on pathogenesis and research into relevant disease models. The book is now an edited multi-author compilation rather than a more personal distillation from a small group. Looking at the arithmetic there are 27 USA authors, 14 UK, and four others from Australia and Scandinavia—the latter empowered only to pronounce on alcohol and dementia and CADASIL. Bar this small non-cross Atlantic contingent the chapters work out at 11 USA and 10 UK, with two mixed, illustrating a previously unrecognised American propensity for job sharing.

The content is uniformly well presented and informative. Referencing largely peters out in 2002 indicating the long lead time for this type of book but this is not a bad thing. The modern tendency to rush into print with one's latest minor observation on, for example, yet another apoptotic or oxidation marker contributes little to the overall progress of neuropathological research in neurodegeneration. The purpose of a book like this is to record those aspects of the understanding of dementia disorders that withstand time and become part of the accepted wisdom rather than twitching with every modish straw in the wind.

The imaging chapter is an especially fine thing with dazzling illustration and some

alarming jargon. Continuum-mechanical warping using calculations based on Cauchy-Navier equations with variable Lamé elasticity coefficients, and purple brains, add a new and distracting element to a neuropathology book. However the integration of neuropathology and neuroimaging data is a highly desirable goal in clinical neuroscience and it would be ludicrous to reject it here. This content illustrates just how widely a "neuropathology" text needs to cast its net to retain its value in such an interdisciplinary world as neurodegeneration research and the clinical neuroscience of dementia.

In summary, another triumph and an indispensable addition to this field. If I had any hope of getting the book back I would automatically loan it to any new neuropathology trainee, but its appeal is far broader and it should be studied by anyone entering dementia research from a tissue-based angle. For a quotable plug to blurb over the sleeve of the third edition I offer the publisher: "buy one, get one free".

L F Haas

### Catastrophic neurological disorders in the emergency department

Edited by E F M Wijdicks. 2004: Published by Oxford University Press, Oxford £70.00 (hardback), pp 306. ISBN 0-19-516880-1

Neurological conditions in the emergency department have to be quickly identified because more and more therapeutic options are available. Most of the academic approaches focus on diseases. Wijdicks offers an interesting and very practical insight of neurology in the emergency room. This is the second edition of catastrophic neurological disorders in the emergency department, third book of a trilogy dedicated to critical care neurology. Eight new chapters were added, seven of which appear in an entirely new first section on the evaluation of presenting symptoms indicating urgency. There is a final new chapter on forensic neurology.

The first part is original and very practical: from the initial symptoms in the emergency room such as "confused and febrile", the evaluation of the patient, diagnosis orientation, algorithms for the choice of paraclinical tools, and therapeutic issues are discussed. One of the chapters I really found original is the one entitled "Shortness of breath". This question is not often taken into account in teaching regarding neurological disorders. If you look for more precise data, you will find "little boxes" that point out to more precise issues such as the role of the ascending reticular activating system.

The second part is about how to evaluate conditions that can deteriorate (coma, acute obstructive hydrocephalus, brain oedema). The chapter on coma is exhaustive, with illustrations and figures commenting on different mechanisms. Toxicology is also very present in this book.

The last part is more conventional and deals with most of the urgent neurological conditions such as ischaemic stroke, haemorrhagic stroke, and spinal cord injury. Unfortunately, the author did not integrate a chapter on myasthenia or Guillain-Barré syndrome, which are often under-recognised in the emergency department.

There are different levels of reading whether one searches for general data on a disease, differential diagnoses, or more precise elements such as a reference or pathophysiological explanations. Illustrations are very helpful; in particular, the ones on oculomotor disturbances and neuroradiological resources are well chosen. This book can also be an excellent source of inspiration for teaching.

All the doctors (from students to consultants) who have to walk through an emergency department should have this book on their bookshelves. A pocket edition of such an educational book would be useful!

C Cordonnier

### Cerebrovascular disease, cognitive impairment, and dementia

Edited by J O'Brien, D Ames, L Gustafson, M F Folstein, E Chui. Published by Martin Dunitz, London pp406.

The proportion of patients who will be victim of stroke or dementia is terrifying: after the age of 80 years, 1 in 5 people is affected by dementia, and 1 in 10 have had a stroke or transient ischaemic attacks. The burden of stroke and dementia will continue to increase during the next 20 years in western countries, owing to increasing life expectancy. Therefore, the economic burden of both disorders will also become a major public health issue. Stroke is an important cause of cognitive impairment and dementia. Stroke prevention, the only way to prevent vascular dementia, may also be an effective way to "prevent" Alzheimer's disease—or at least to prevent the anticipation of its clinical onset, possibly due to the summation of vascular and Alzheimer lesions. Although the term "vascular dementia" appears in several chapters, the editors discuss two other important concepts. The first is the wide notion of "vascular cognitive impairment", which includes a large range of severity of cognitive impairments associated with vascular lesions; behind this term is the hope of an effective prevention. The second is the interaction between Alzheimer lesions and stroke, explaining that many patients already have some degree of cognitive impairment before stroke, which may be degenerative in origin in many cases.

The book is divided into 26 chapters, including classification and diagnosis, epidemiology and risk factors, pathophysiology, clinical features, assessment, and management. The organization of the book proceeds logically. All chapters end with the most important references. The information is made clear and is accurate. The target audience consists of all care providers who treat patients with dementia or cerebrovascular disorders. Its length and its level of details make it appropriate for residents looking for a practical knowledge, and also for trained specialists. This book will be of major interest for all those who treat patients with cognitive decline or patients at risk.

D Leys

D Leys has been paid or received funds for research during the last 5 years by Sanofi-Synthelabo, AstraZeneca, Takeda, Lilly, and Servier for educational programmes, speaking, and consulting.