

# PostScript

## LETTERS

### Possible transcallosal seizure induction by paired pulse transcranial magnetic stimulation in a patient with frontal lobe epilepsy

Seizure induction by high frequency transcranial magnetic stimulation (TMS) has been reported in normal subjects and by single pulse TMS close to the epileptic focus in patients with epilepsy.<sup>1</sup>

#### Case report

We report an 18 year old patient with right frontal lobe epilepsy due to paramedian focal cortical dysplasia (FCD). The patient's usual seizure semiology consisted of a somatosensory aura of the left hand followed by a tonic seizure of the left arm which evolved to a bilateral asymmetrical tonic seizure without loss of consciousness. In the two years preceding the study (see below) he had rare night-time seizures only. His anti-epileptic medication consisted of levetiracetam 500 mg, phenobarbital 25 mg, and carbamazepine 1600 mg daily.

During presurgical videoelectroencephalogram (video-EEG) monitoring, interictal EEG showed right frontotemporal spikes. Ictal EEG revealed seizure patterns with a right frontal onset. Magnetic resonance imaging (MRI) showed FCD in the right superior frontal gyrus extending into the right precentral gyrus (fig 1A). Neurological examination was normal.

#### Transcranial magnetic stimulation

The patient participated in a TMS study using a protocol described previously<sup>2</sup> to evaluate

intracortical excitability of both motor cortices (M1). The study was approved by the local ethics committee, and the patient gave written informed consent.

We used a focal 70 mm figure of eight coil connected to two magnetic stimulators via a BiStim module (Magstim Company, Dyfed, UK). Surface electromyography (EMG) was recorded from the contralateral abductor digiti minimi muscle (ADM) of the hand.

TMS commenced over the left M1 contralateral to the epileptic focus with the coil placed over the M1 hand area. First, motor thresholds (RMT, AMT) and cortical induced silent period at an intensity of 110% RMT were evaluated. Next, paired pulse TMS (conditioning stimulus set at 38% of maximum stimulator output, second stimulus 60% of stimulator output) was started on the left M1 with a train of paired pulses with ISI 2, 3, 10, and 15 ms in a random order.

After 65 stimuli, the patient noticed that his habitual somatosensory aura of the left hand followed by myoclonic jerks of the left forearm (mainly biceps brachii muscle and forearm flexor muscles) was triggered by each stimulus, contralateral to the epileptogenic zone but ipsilateral to the cortical stimulation. The jerks were triggered by both single and paired stimuli at all ISI and rapidly involved both arms. These motor phenomena were different from the typical seizure semiology. EMG recordings of the ADM showed movement artefacts 63–75 ms after the MEP (fig 1B). The TMS was immediately interrupted, which aborted the myoclonus at once.

The TMS data of the left hemisphere showed increased motor thresholds, prolonged cortical induced silent period, markedly decreased intracortical inhibition, and increased facilitation compared with 20 controls<sup>2</sup> (percentiles of the patient's measures within the control group: >99% for ISI 2 and

CSP, >95% for motor thresholds and ISI 15, >90% for ISI 10, and >85% for ISI 3).

After the TMS experiment, the patient was again free of daytime seizures until the last follow up visit six months later.

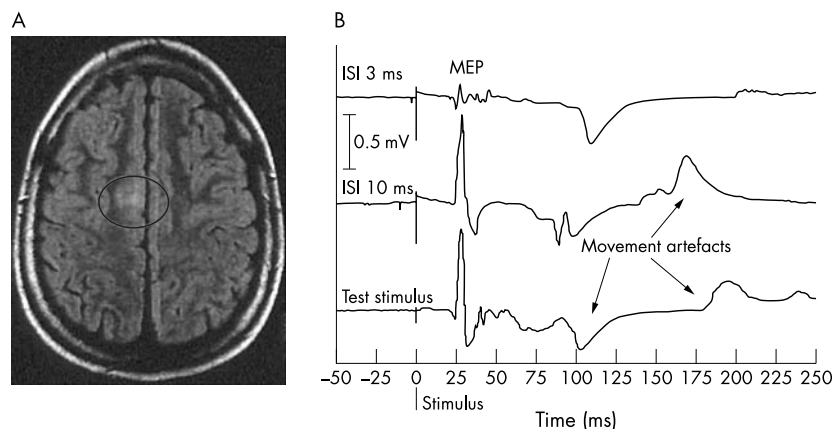
### Transcallosal seizure induction by paired pulse TMS

In patients with epilepsy, all reported cases of seizure induction by TMS have occurred during ipsilateral stimulation and near to the epileptic focus. Therefore, it has been assumed that direct stimulation of the epileptogenic tissue was required to trigger a seizure.<sup>1</sup> We used a focal coil placed over the left M1 hand area more than 5 cm away from the midline. Thus, it is unlikely that the right epileptogenic zone or mesial frontal cortex of the present patient was stimulated directly, and we assume that an indirect transcallosal activation of the epileptogenic zone provoked the aura. The latency of 65–75 ms of the myoclonic jerks after the MEP may reflect polysynaptic pathways in addition to a direct transcallosal connection of both M1. It is still not clear whether involvement of additional cortical areas such as the ipsilesional and contralesional sensory cortices or basal ganglia contributed to the seizure provocation. Despite the patient's statement that the jerks were not volitional, this cannot be completely ruled out. The preceding somatosensory aura, however, represented his typical seizure semiology. We hypothesise that transcallosal activation of the epileptic focus was promoted by the increased excitability of M1, which was due to the underlying FCD. This, in turn, led to the aura and peri-ictal changes in M1 excitability facilitating TMS driven myoclonic jerking. It has been previously reported that FCD is intrinsically epileptogenic and promotes reflex seizures.<sup>3</sup>

There is a possibility that ipsilateral pathways of movement activation could underlie our observations. In a child with extensive cortical dysplasia, TMS of the unaffected hemisphere evoked MEPs in both ADM muscles implying bilateral corticospinal connections from one cortex.<sup>4</sup> Histological studies on severe brain damage in early development have revealed collateral sprouting into denervated areas of cortex or spinal cord.<sup>5</sup> Ipsilateral activation under maximum muscle contraction has been observed in healthy volunteers and in patients with acute stroke.<sup>5</sup> Our patient, however, presumably had congenital but circumscribed FCD, no motor deficits, and was investigated at rest. This and the fact that his habitual somatosensory aura occurred before the myoclonic jerks strongly argue against the activation of ipsilateral corticospinal tracts. Activation of a silent mirror focus in the left hemisphere with subsequent spread to the right is also unlikely because exclusively right sided ictal and interictal epileptiform discharges were recorded during the video-EEG monitoring.

### Changes in motor cortex excitability

Our patient's higher motor thresholds compared with controls are very likely due to his ion channel blocking anticonvulsant medication.<sup>6</sup>



**Figure 1** (A) Axial T2-weighted magnetic resonance imaging (MRI) scan (fluid attenuated inversion recovery (FLAIR)) of the patient's brain. T2 prolongation and blurring of grey-white junction represents focal cortical dysplasia of 1 × 1 cm (see circle) located in the right superior frontal sulcus (extending to the right motor cortex, seen in further MRI slices). (B) Examples of motor evoked potentials (MEPs) from the right abductor digiti minimi muscle (ADM) during transcranial magnetic stimulation of the left hemisphere at different interstimulus intervals (ISI) and after unconditioned test stimulus. The patient showed stimulus triggered myoclonic jerks of both hands and forearms leading to movement artefacts in the ADM recordings.

The loss of intracortical inhibition and increased intracortical facilitation in the left hemisphere contralateral to the epileptogenic zone may reflect synaptic reorganisation of the ipsilesional and contralateral motor cortices. These distant functional cortical changes associated with malformations of cortical development have also been described previously.<sup>7</sup> The prolongation of the cortical induced silent period seen in the present patient may be independent of the phenobarbital intake<sup>6</sup> and confirms similar findings from previous studies as a remote effect of FCD on the motor cortex in untreated patients with cortical dysgenesis.<sup>7</sup>

## Conclusion

Unilateral epileptogenic FCD involving M1 can induce complex bilateral alteration of motor cortex excitability resulting in a net increase of excitability. In such cases, transcallosal seizure induction appears to be possible with paired pulse TMS using a focal coil away from the epileptic focus.

J Reis, F Rosenow, B Fritsch, S Knake,  
W H Oertel, H M Hamer

Interdisciplinary Epilepsy-Center, Department of  
Neurology, Philipps-University Marburg, Germany

Correspondence to: J Reis, Interdisciplinary Epilepsy-Center, Department of Neurology, Philipps-University Marburg, Rudolf-Bullmann-Str. 8, 35033 Marburg, Germany; reis@staff.uni-marburg.de

doi: 10.1136/jnnp.2004.042127

Competing interests: none declared

## Reference

- 1 Classen J, Witte OW, Schlaug G, et al. Epileptic seizures triggered directly by focal transcranial magnetic stimulation. *Electroencephalogr Clin Neurophysiol* 1995;**94**:19–25.
- 2 Reis J, Tergau F, Hamer HM, et al. Topiramate selectively increases motor cortex excitability in human motor cortex. *Epilepsia* 2002;**43**:1149–56.
- 3 Palmieri A, Gambardella A, Andermann F, et al. Intrinsic epileptogenicity of human dysplastic cortex as suggested by corticography and surgical results. *Ann Neurol* 1995;**37**:476–87.
- 4 Maegaki Y, Yamamoto T, Takeshita K. Plasticity of central motor and sensory pathways in a case of unilateral extensive cortical dysplasia: investigation of magnetic resonance imaging, transcranial magnetic stimulation, and short-latency somatosensory evoked potentials. *Neurology* 1995;**45**:2255–61.
- 5 Caramia MD, Palmieri MG, Giacomini P, et al. Ipsilateral activation of the unaffected motor cortex in patients with hemiparetic stroke. *Clin Neurophysiol* 2000;**111**:1990–6.
- 6 Ziemann U, Lonnecker S, Steinhoff BJ, et al. Effects of antiepileptic drugs on motor cortex excitability in humans: a transcranial magnetic stimulation study. *Ann Neurol* 1996;**40**:367–78.
- 7 Cincotta M, Borgheresi A, Guidi L, et al. Remote effects of cortical dysgenesis on the primary motor cortex: evidence from the silent period following transcranial magnetic stimulation. *Clin Neurophysiol* 2000;**111**:1340–5.

## Hashimoto's encephalopathy: steroid resistance and response to intravenous immunoglobulins

Hashimoto's encephalopathy is a steroid responsive disorder characterised by high titres of anti-thyroid antibodies and manifesting as sub-acute onset of confusion, episodes of myoclonus, seizures, and stroke-like episodes. Although excellent response to steroids is characteristic, other treatments

such as plasmapheresis or administration of azathioprine or cyclophosphamide have been occasionally tried. We report a case of initially steroid responsive Hashimoto's encephalopathy which became steroid resistant and then responded well to intravenous immunoglobulins.

## Case report

A 29 year old woman was admitted in 1987 with an episode of headache, confusion, agitation, and hallucination. She had a mild fever and was thought to have neck stiffness. A CT scan was normal as were the inflammatory markers. CSF examination showed 9240 red cells and 33 white cells (45% polymorphs and 55% lymphocytes). CSF protein, glucose, and microbiology were normal. A presumed diagnosis of meningo-encephalitis was made and the patient was treated with acyclovir and antibiotics. The patient made a good recovery but was re-admitted a week later with agitation and confusion with pain and weakness down the left side. No focal neurology was found on examination and the patient was thought to be suffering from an anxiety state.

During the next 14 years, the patient was admitted on several occasions with episodes of confusion and agitation: investigations including lumbar puncture, CT scans, EEG, thyroid function, porphyria screens, autoantibody screens (including antinuclear antibodies, ANCA, and those against extractable nuclear antigens), and metabolic and septic screens were found to be normal. She had been admitted to the psychiatry unit and was thought to be suffering from acute mania or a dissociative state, precipitated by stress and sleep deprivation. In 2001, she was referred to the neurology clinic for similar episodes, which were increasing in frequency.

On first review in the neurology clinic, clinical examination was unremarkable except for bilaterally symmetrical and brisk reflexes. MRI scan of the brain and EEG were repeated and found to be normal. Thyroid peroxidase antibody was raised at 250 IU/ml (normal range 0–60). Thyroid function tests were normal.

She remained well until April 2003 when a further episode of drowsiness and confusion occurred (thyroid peroxidase antibody 266 IU/ml). This responded remarkably and within 24 h to a course of dexamethasone given intravenously at a dose of 16 mg daily for 5 days. An EEG repeated during the episode showed diffuse slowing but no epileptiform abnormalities.

The patient was re-admitted in May 2004 with another episode of confusion and agitation. Interestingly, this episode occurred after a 5 day course of oral prednisolone 60 mg/day for a chest infection. Apart from the acute confusional state there was no focal neurology. Repeat CT scan and CSF examination including oligoclonal bands were within normal limits. Repeat thyroid peroxidase antibody was elevated at 272 IU/ml (normal range 0–60). Voltage gated potassium channel antibodies were negative. Other investigations including thyroid function remained normal. EEG showed diffuse bilateral slow wave activity. A 7 day course of intravenous dexamethasone 16 mg/day was initiated. The confusion and agitation worsened and later she became very drowsy. Intravenous immunoglobulin (400 mg/kg daily) was given causing a dramatic improvement within 12 h. Unfortunately, on the same day, the patient

developed an increase in alanine transaminase and C-reactive protein levels. A possible reaction to intravenous immunoglobulin was considered and the infusion was discontinued. Later, the increased levels were confirmed to be secondary to septicaemia from a *Staphylococcus aureus* infected cannula site. The inflammatory markers normalised after a course of antibiotics. During this time the patient remained drowsy, confused, and occasionally agitated. A 5 day course of intravenous immunoglobulin was reinstated. Again, there was a dramatic improvement within 24 h and she was discharged home at the end of the course having completely recovered.

## Discussion

Hashimoto's encephalopathy (HE) is a steroid responsive disorder characterised by high titres of anti-thyroid antibodies. The original description of this condition was in an established case of Hashimoto's thyroiditis where the patient developed focal neurological deficits and coma.<sup>1</sup> Clinical presentation includes episodic confusion, myoclonus, seizures, and stroke-like episodes.<sup>2</sup> Females are more affected than males (3.6:1), with a mean age of onset of 41 years. The hallmark of HE is its response to steroids, most cases improving within a few hours to days.<sup>3</sup> The titres of anti-thyroid antibodies maybe independent of the severity of the clinical presentation.<sup>4</sup> Fewer than 100 cases of HE have been reported in the literature. Goitre and hypothyroidism can be associated with the disorder, but the majority of patients are euthyroid. Although steroid responsiveness is the rule, additional immunosuppressive therapy in the form of azathioprine and cyclophosphamide has been tried in a minority of patients.<sup>2,3</sup> One case report of HE responding to plasmapheresis is documented.<sup>5</sup> There was no benefit in the two documented cases where intravenous immunoglobulin was administered.<sup>5,6</sup>

Several pathophysiological hypotheses have been suggested for HE. The initial report of HE suggested a vascular aetiology followed by localised cerebral oedema as a possible mechanism.<sup>1</sup> Some authors suggest that the CSF thyroid autoantibodies may react with a putative CNS antigen and form immune complexes.<sup>2,4</sup> The immunopathological basis of this syndrome has been compared to a relapsing form of acute disseminated encephalomyelitis.<sup>7</sup> Although reversible MRI findings have been described in HE,<sup>8</sup> neuroimaging (except for isolated patchy uptake by isotope scans) is usually normal in most cases.<sup>3</sup> Cerebral angiography has been found to be normal in several cases of HE, unlike in many other cerebral vasculitides.<sup>1,3,5</sup>

Thyroid autoantibodies can co-exist with several other forms of autoimmune encephalomyelitis, but the normal MRI scan, the initial dramatic response to steroids, and negative autoantibodies for most other common vasculitides, tends to favour the diagnosis of HE in our case. Steroid responsive encephalopathy associated with Hashimoto's thyroiditis is an alternately proposed name for this condition,<sup>9</sup> but the vast majority of cases have normal thyroid function, leaving 'Hashimoto's encephalopathy' a universally accepted term. A recent literature review of 85 patients with encephalopathy and anti-thyroid antibodies suggests that the combination of encephalopathy, high serum anti-thyroid antibody concentrations, and



responsiveness to glucocorticoid therapy seems unlikely to be due to chance.<sup>10</sup>

The initial meningo-encephalitic type presentation of our patient in 1987 was probably the first manifestation of HE in view of clinical findings and laboratory data (Mild CSF pleocytosis is not unusual in HE.<sup>3</sup>) There was a delay of 14 years before the diagnosis was first established, in spite of several hospital admissions. The initial relapses after diagnosis responded well to steroids, confirming the diagnosis of HE. Whether the current episode was precipitated by the sudden withdrawal of oral steroids or the chest infection itself, for which they were prescribed, is unclear.

Our patient illustrates the possibility of steroid resistance in an established case of HE and the need to consider further immunomodulatory therapy. Intravenous immunoglobulins are a safe, convenient, and effective treatment in such circumstances.

S Jacob, Y A Rajabally

Department of Neurology, Leicester Royal Infirmary, University Hospitals of Leicester, Leicester LE1 5WW, UK

Correspondence to: Dr Y A Rajabally, Department of Neurology, University Hospitals of Leicester, Royal Infirmary, Leicester LE1 5WW, UK; yusuf.rajabally@uhl-tr.nhs.uk

doi: 10.1136/jnnp.2004.049395

Competing interests: none declared

## References

- 1 Lord Brain, Jellinek EH, Ball K. Hashimoto's disease and encephalopathy. *Lancet* 1966;**2**:512-4.
- 2 Shaw PJ, Walls TJ, Newman PK, et al. Hashimoto's encephalopathy: a steroid-responsive disorder associated with high anti-thyroid antibody titre – report of 5 cases. *Neurology* 1991;**41**:228-33.
- 3 Peschen-Rosin R, Schabet M, Dichgans J. Manifestation of Hashimoto's encephalopathy years before onset of thyroid disease. *Eur Neurol* 1999;**41**:79-84.
- 4 Ferraci F, Moretto G, Candeago RM, et al. Antithyroid antibodies in the CSF. Their role in the pathogenesis of Hashimoto's encephalopathy. *Neurology* 2003;**60**:712-4.
- 5 Boers PM, Colebatch JG. Hashimoto's encephalopathy responding to plasmapheresis. *J Neurol Neurosurg Psychiatry* 2002;**73**:601.
- 6 Henchey R, Cibula J, Helveston W, et al. Electroencephalographic findings in Hashimoto's encephalopathy. *Neurology* 1995;**45**:977-81.
- 7 Chaudhuri A, Behan PO. The clinical spectrum, diagnosis, pathogenesis and treatment of Hashimoto's encephalopathy (recurrent acute disseminated encephalomyelitis). *Curr Med Chem* 2003;**10**(19):1945-53.
- 8 Bohnen NI, Parnell KJ, Harper CM. Reversible MRI findings in a patient with Hashimoto's encephalopathy. *Neurology* 1997;**49**:246-7.
- 9 Mahmud FH, Renaud DL, Reed AM, et al. Steroid-resistant encephalopathy associated with Hashimoto's thyroiditis in an adolescent with chronic hallucinations and depression: case report and review. *Pediatrics* 2003;**112**(3 Pt 1):686-90.
- 10 Chong JY, Rowland LP, Utiger RD. Hashimoto's encephalopathy. Syndrome or myth? *Arch Neurol* 2003;**60**:164-71.

## Spontaneous lobar haemorrhage in CADASIL

CADASIL is an autosomal dominant form of arteriopathy, primarily affecting cerebral vessels, and predominantly caused by point mutations in the *Notch3* gene on the short

arm of chromosome 19.<sup>1</sup> Affected individuals develop subcortical strokes and cognitive deficits in their 50s and 60s.<sup>2</sup> Brain magnetic resonance imaging (MRI) shows large areas of leukoencephalopathy and multiple subcortical lacunar infarcts. Small arteries and capillaries are characterised histologically by a non-atherosclerotic, non-amyloid angiopathy with accumulation of granular osmiophilic material (GOM) within the smooth muscle cell basement membranes and extracellular matrix.<sup>3</sup> While CADASIL is considered a primarily ischaemic form of vascular dementia, microhaemorrhages have recently been reported in 31% of symptomatic *Notch3* mutation carriers, suggesting that structural fragility of the arterial walls may lead to leaking of haem products.<sup>4</sup> Lobar haemorrhage in the absence of other risk factors for haemorrhage has previously been reported in one patient with CADASIL.<sup>5</sup> Here we report a second case.

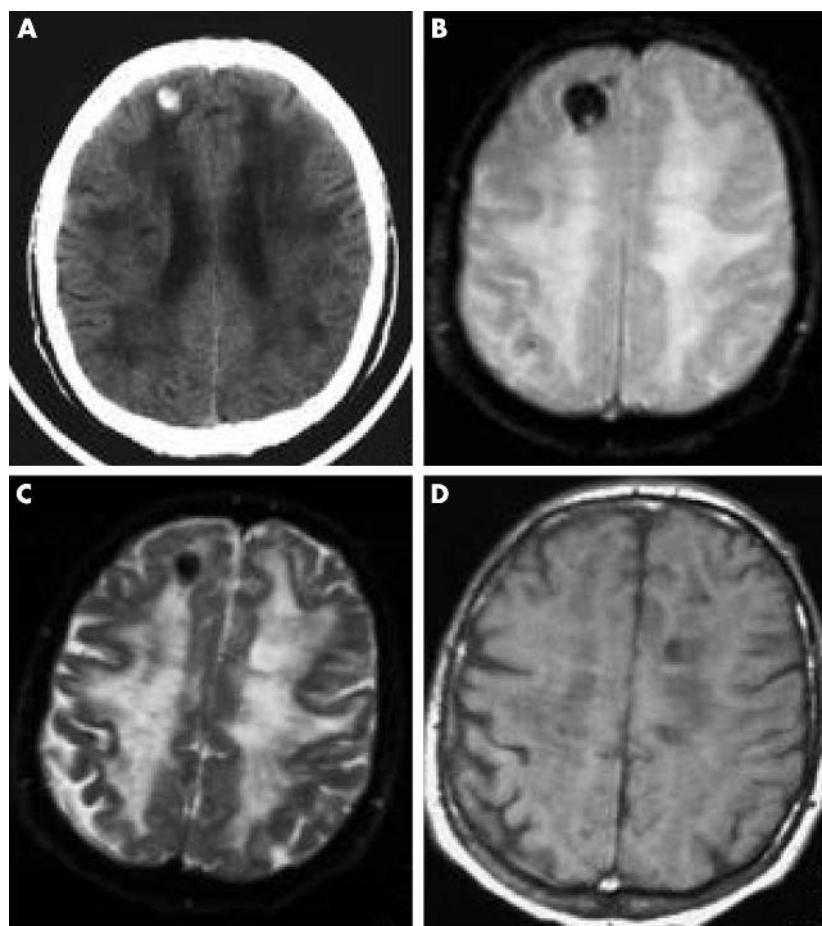
## Case report

A 56 year old man who had been diagnosed with multiple sclerosis six years earlier was admitted to the hospital with an acute change in mental state. He had collapsed at

home and was unresponsive when rescue arrived. In the emergency room he had a depressed level of consciousness and difficulty following commands, with paucity of speech, dysarthria, and hypophonia. There was no evidence of head trauma. His blood pressure was 100/63 mm Hg and his temperature was 36.1°C.

Past medical history included chronic obstructive pulmonary disease, prostate resection for prostate cancer, and a history of nicotine and alcohol dependence. He had no history of hypertension, diabetes mellitus, or coagulopathy. His drug treatment included ipratropium, ranitidine, methylprednisolone, and albuterol. His mother, now deceased, had been diagnosed as having multiple sclerosis and had migraines with auras, stroke-like symptoms, and dementia. He had eight siblings, three with headaches and one with recent transient ischaemic events.

Computed tomography (CT) of the head in the emergency department showed an area of high attenuation in the right frontal lobe consistent with an acute intraparenchymal haemorrhage (fig 1A). There was no evidence of trauma on head CT. Gradient echo MRI sequences of the brain done on hospital day 2 showed a 2×2.5 cm area of haemorrhage in



**Figure 1** (A) Non-contrast computed tomography of the head done in the emergency room showing an area of high attenuation in the right frontal lobe consistent with acute haemorrhage. The other panels show non-contrast magnetic resonance imaging done on hospital day 2: (B) Gradient echo sequence demonstrating a 2×2.5 cm area of haemorrhage in right frontal lobe, a microhaemorrhage in the right parietal region, and extensive white matter disease. (C, D) The area of haemorrhage is hypointense on T2 and isointense on T1 weighted imaging, consistent with an acute haemorrhage.

the superior-anterior aspect of the right frontal lobe white matter as well as a microhaemorrhage in the right parietal region (fig 1B). The area of haemorrhage was hypointense on T2 (fig 1C) and iso-intense on T1 weighted sequences (fig 1D), consistent with acute haemorrhage. There was no MRI evidence of a cavernous haemangioma, arteriovenous malformation, or tumour. Magnetic resonance angiography was not done.

A brain biopsy of the right frontal lobe done on the seventh hospital day showed degeneration of small and medium sized arteries. Vessel walls were thick and hyalinised in the grey matter, white matter, and meninges. PAS staining was positive and the muscular coat of the large vessels revealed degenerative changes. Electron microscopy showed the granular osmiophilic material characteristic of CADASIL. *Notch3* gene testing revealed a R133C mutation in exon 4, consistent with the diagnosis of CADASIL. The patient remained normotensive throughout his hospital stay. On the fifth hospital day he developed aspiration pneumonia requiring mechanical ventilation. He died eight days later as a result of this pneumonia.

### Comment

This is the second report of spontaneous cerebral haemorrhage in a patient with CADASIL. In 1977, Sourander and Walinder reported a 29 year old man with hereditary multi-infarct dementia on anticoagulants, with a large haemorrhage in the right hemisphere.<sup>5</sup> This family was thought to be one of the first with CADASIL; however, recent testing for *Notch3* mutations in the family has not confirmed that diagnosis.<sup>6</sup> In 1992, Baudrimont *et al* reported a case of massive left cerebral haematoma involving the caudate nucleus, internal capsule, and thalamus in a 40 year old normotensive woman who was a member of a large CADASIL family. She had no known history of other risk factors for haemorrhage.<sup>7</sup>

The index patient in this report had no evidence of coagulopathy and no history of previous hypertension, cerebral haemorrhage, or anticoagulant therapy. The patient could have experienced a haemorrhagic contusion related to a closed head injury during his unwitnessed fall before admission, but there was no evidence of trauma on physical examination or on head CT. On MRI there was no evidence of a cavernous haemangioma, arteriovenous malformation, or neoplasm. Necropsy was not carried out.

Ultrastructural analysis of small arteries in human postmortem brain and skin in patients with CADASIL shows breakdown of the arterial wall cytoarchitecture, which may help explain the propensity for microhaemorrhages.<sup>8</sup> The first *notch3* transgenic mouse shows early widening of the subendothelial and intra-smooth-muscle spaces in the vascular smooth muscle cells, denoting weakening of the arterial wall and increasing susceptibility to micro- and macrohaemorrhages.<sup>9</sup>

This case report supports the growing evidence for both ischaemia and haemorrhage in a variety of small artery diseases including amyloid angiopathy and CADASIL.<sup>10 11</sup> Clinicians may need to consider the possibility of haemorrhage when evaluating new events and deciding on treatment for stroke prevention in patients with CADASIL.

### Acknowledgements

Supported by grants P20 RR015578 and K08MH001487.

#### A V MacLean

Brown Medical School, Providence, Rhode Island, USA

#### R Woods, L M Alderson, S P Salloway

Department of Clinical Neurosciences, Brown Medical School

#### S Correia

Department of Psychiatry and Human Behavior, Brown Medical School

#### S Cortez, E G Stopa

Department of Pathology (Neuropathology Division), Brown Medical School

Correspondence to: Professor Stephen Salloway, Department of Neurology, Butler Hospital, 345 Blackstone Blvd, Providence, RI 02906, USA; Stephen\_Salloway@brown.edu

doi: 10.1136/jnnp.2004.042564

Competing interests: none declared

### References

- Joutel A, Corpechot C, Ducros A, *et al*. *Notch3* mutations in CADASIL, a hereditary adult-onset condition causing stroke and dementia. *Nature* 1996;**383**:707–10.
- Dichgans M, Mayer M, Utner I, *et al*. The phenotypic spectrum of CADASIL: clinical findings in 102 cases. *Annals of Neurology* 1998;**44**:731–9.
- Ruchoux MM, Maurage CA. CADASIL: cerebral autosomal dominant arteriopathy with subcortical infarcts and leukoencephalopathy. *J Neuropathol Exp Neurol*, 1997;**56**:947–64.
- Lesnik Oberstein SA, van den Boom R, van Buchem MA, *et al*. Cerebral microbleeds in CADASIL. *Neurology* 2001;**57**:1066–70.
- Sourander P, Walinder J. Hereditary multi-infarct dementia: morphological and clinical studies of a new disease. *Acta Neuropathol (Berlin)* 1977;**39**:247–54.
- Kalimo H, Ruchoux MM, Viitanen M, *et al*. CADASIL: a common form of hereditary arteriopathy causing brain infarcts and dementia. *Brain Pathol* 2002;**12**:371–84.
- Baudrimont M, Dubas F, Joutel A, *et al*. Autosomal dominant leukoencephalopathy and subcortical ischemic stroke: a clinicopathological study. *Stroke* 1993;**24**:122–5.
- Rouchoux MM, Maurage CA. Endothelial changes in muscle and skin biopsies in patients with CADASIL. *Neuropathol Appl Neurobiol* 1998;**24**:60–5.
- Ruchoux MM, Domenga V, Brulin P, *et al*. Transgenic mice expressing mutant *notch3* develop vascular alterations characteristic of cerebral autosomal dominant arteriopathy with subcortical infarcts and leukoencephalopathy. *Am J Pathol* 2003;**162**:329–42.
- Greenberg SM. Cerebral amyloid angiopathy and vessel dysfunction. *Cerebrovasc Dis* 2002;**13**(suppl 2):42–7.
- Dichgans M, Hollmannspotter M, Herzog J, *et al*. Cerebral microbleeds in CADASIL: a gradient-echo magnetic resonance imaging and autopsy study. *Stroke* 2003;**34**:376–7.

### Urinary retention caused by a small cortical infarction

The cortical representation of micturition is speculated to reside in the medial frontal lobes.<sup>1 2</sup> Lesion pathology, however, varies from acute stroke to a neoplasm, and there is not necessarily a small, distinct lesion.<sup>2</sup> We report a case of urinary retention in which the main presenting symptom is thought to have been caused by a small cortical infarction.

### Case report

One morning, a 66 year old, right handed man had difficulty urinating. He had no history of voiding difficulty, diabetes mellitus, injury to the lower urinary tract, or neurological disease. Digital rectal examination and ultrasonography of the prostate detected no enlargement. Urinalysis showed no haematuria or pyuria. He was not taking any medications that cause voiding dysfunction. There was no urinary incontinence, but he had difficulty in voiding even though he felt the bladder was full. At that time, he also had difficulty in lifting his left arm and leg and so was brought to our hospital. Neurological examination in the emergency room found no weakness, and he was sent home. Later, he experienced urinary retention and visited the emergency room again. His post void residual urine volume was 350 ml, and an urinary catheter was inserted. At that time the patient was alert, and his cranial nerves were intact. Limb muscle strength was normal. Sensory examination was unremarkable. Tendon reflexes were normal in all four limbs. Tandem gait and standing on one foot were difficult. He had normal bladder sensation but difficulty in urinating. Drip infusion pyelography revealed no abnormality in the upper urinary tract or the form of the bladder. Filling cystometry showed stable detrusor with normal bladder sensation, whereas acontractile detrusor was noted in the voiding phase. He could void only with strain, having a peak flow rate of 5.0 ml/s and a voided volume of 135 ml. Diffusion weighted MRI, performed on the day of onset, showed a small, distinct, high intensity signal, and T1 weighted imaging showed a low signal in the right caudal part of the anterior cingulate gyrus, indicative of an infarct in the acute stage (fig 1A and C). No definitive infarct was observed elsewhere. MR angiography showed no occlusion or stenosis of the intracranial vessels. An electrocardiogram was normal. Transthoracic echocardiograms showed no abnormal findings. The urinary catheter was withdrawn 3 days after admission, and he had no subsequent difficulty with urination. His gait returned to normal about the same time.

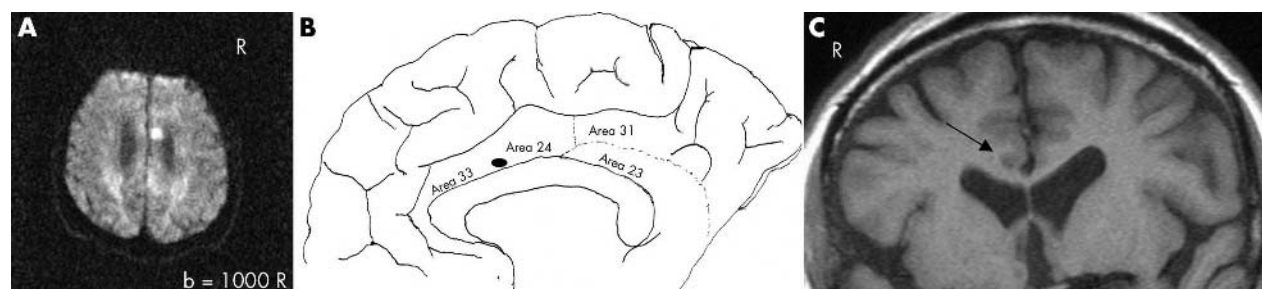
### Discussion

In the acute stage of a cerebral vascular accident, the presenting symptom often is urinary retention due to detrusor areflexia,<sup>3</sup> but patients who have this problem usually have a major stroke with severe neurological deficits.

To the best of our knowledge, this is the first report in the English literature of urinary retention, although temporary, caused by a small cortical infarct as shown by diffusion weighted MRI.

Various cortical areas are activated during voiding because a network of brain regions is necessary for voiding modulation.<sup>4</sup> The locations of the primary cerebrum cortical areas for voiding and storage are speculated to be separate, the former being at the para-central lobule.<sup>2</sup> A PET study found normal micturition to be associated with activation of the middle frontal gyrus, superior frontal gyrus, superior precentral gyrus, thalamus, and the caudal part of the anterior cingulate gyrus in the left hemisphere.<sup>5</sup> Another recent PET study showed that increased brain activity related to increasing bladder volume was located in the bilaterally mid-cingulate cortex, while that related to decreased urge to





**Figure 1** Diffusion weighted MRI. (A) The axial section shows a small high signal in the right caudal part of the anterior cingulate gyrus. (B) The closed ellipse denotes the lesion in the cortical map (map modified from Brodmann, 1909). (C) In the T1 weighted MRI procedure, the coronal section shows a low intensity signal in the right caudal part of anterior cingulate gyrus (arrow). (Imaging condition: a negative tilt of  $-20^\circ$  to the orbitomeatal line.)

void was bilaterally in a different portion of the mid-cingulate gyrus.<sup>4</sup>

Although the infarct in our patient was located in the caudal part of the anterior cingulate gyrus, it was on the right side, nearby the region activated in the PET study.<sup>4</sup> SPECT showed increased blood flow in the right medial frontal area, indicative that urinary retention was due to “decreased urge to void”, and decreased flow in the right medial parietal lobe, which might explain the gait disturbance, in light of the essentially normal sensory examination. Unfortunately, a PET scan was not available in our hospital (Kameda Medical Center). Because there has been no report of an isolated lesion of the cingulate gyrus causing hemiparesis, these brain imaging studies indicate that the left hemiparesis, which disappeared within a half day of onset, could have been due to a transient ischaemic attack.

Urinary symptoms disappeared 3 days after admission, probably because the cortical neuron network compensated by providing a functional alternative to the lesion damaged by the infarct. This is similar to the condition of urinary incontinence after cerebral infarction, as is well documented. The laterality of the lesion in this patient differs from that in a previous PET study<sup>4</sup> which showed bilateral activation in the cingulate gyrus. Because this report cites only a single case, its applicability is limited. Additional lesion studies of patients with micturition disturbance due to small cortical infarcts should help to identify the anatomical cerebral structures involved in voiding.

**K Funakoshi, T Fukutake, H Nishino, S Sato**  
Department of Neurology, Kameda Medical Center,  
Chiba, Japan

**T Yamanishi**  
Department of Urology, Dokkyo University School of  
Medicine, Tochigi, Japan

Correspondence to: Dr Funakoshi, Department of  
Neurology, Dokkyo University School of Medicine,  
Kitakobayashi 880, Mibu, Shimotsuga, Tochigi 321-  
0293, Japan; kei-f@dokkyomed.ac.jp

doi: 10.1136/jnnp.2004.050542

Competing interests: none declared

## References

- 1 **Sakakibara R**, Hattori T, Yasuda K, *et al*. Micturitional disturbance after acute stroke: analysis of the lesion site by CT and MRI. *J Neurol Sci* 1996;**137**:47–56.
- 2 **Kuroiwa Y**. Neurological bladder dysfunction due to frontal lobe lesions. *Neurol Med (Tokyo)* 1992;**36**:561–7.

3 **Bradley WE**. Cystometry and sphincter electromyography. *Mayo Clin Proc* 1976;**51**:329–35.

4 **Athwal BS**, Berkley KJ, Hussain I, *et al*. Brain responses to changes in bladder volume and urge to void in healthy men. *Brain* 2001;**124**:369–77.

5 **Sam N**, Claus S, Jorgen KI, *et al*. Cerebral activation during micturition in normal men. *Brain* 2000;**123**:781–9.

## BOOK REVIEW

### Neuropsychiatry and behavioural neurology explained

Edited by A J Mitchell. Published by Saunders, London, 2004, £69.00 (hardback), pp 500. ISBN 0-7020-2688-3

This is an ambitious project for a single author; the whole of neuropsychiatry explained using an up to date, evidence based review of the literature, and in a format that is designed to be attractive to read. There are numerous figures, boxes, lists with bullet points, and “clinical pointers” to break up the text.

Although aimed particularly at liaison and old age psychiatrists, this book will have wide appeal and be of interest to neurologists. They will be able to quickly access clinically relevant discussion of the neuropsychiatric sequelae of common neurological disorders. The core sections of the book, on dementia and delirium, neuropsychiatric treatments, and the psychiatric complications of neurological diseases, are excellent. The discussion is practical and to the point. The reader is not stifled with references strewn in the text. They must therefore have confidence in the assertions of the author; I am confident that we are being offered accurate information. But at times the style feels a little pedantic; for example, those of us who dared to believe that alcohol might cause depression are put firmly in our place. Another quibble I have is the value of some of the lists/classifications which were of uncertain provenance. We are, for example, given lists suggesting difference aetiologies for chorea versus athetosis, but some would be sceptical of the value in splitting choreoathetosis. Many classifications are based on neuroanatomical models of neuropsychiatry that need to be treated with caution.

The book strays into biological psychiatry, and a later section is devoted to understanding how neurological disorders result in neuropsychiatric symptoms, but this does cause a problem because some of the discussion of the neuropsychiatric sequelae of a

particular disorder may not be found in the index chapter on that disorder, but in this later section. For example, the only discussion of suicide following head injury in the chapter on head injury is a single misleading sentence indicating that suicide accounts for 10% of head injury deaths. Yet, easily missed, 300 pages later, in the chapter on the neurological origins of suicide, is a more complete account of the relationship.

Overall, however, this book is a significant achievement. A large amount of material has been made readily accessible. There are no lacunae and the length of discussion of each disorder is proportionate to its importance. The book is to be trusted and recommended. One interesting innovation is a list of support groups and useful websites in the appendix. Neurologists and psychiatrists and their trainees have good reason to buy this book.

**S Fleming**

## CORRECTIONS

doi: 10.1136/jnnp.2004.047118corr1

Wood J M, Worringham C, Kerr G, *et al*. Quantitative assessment of driving performance in Parkinson's disease (*J Neurol Neurosurg Psychiatry* 2005;**76**:176–80). SD instead of SE was inadvertently inserted during the publication process in tables 2, 3, and 4. The p values are unaffected.

doi: 10.1136/jnnp.2003.029389corr1

Barber PA, Demchuk AM, Hill MD, *et al*. The Probability of middle cerebral artery MRA flow signal abnormality with quantified CT ischaemic change: targets for future therapeutic studies (*J Neurol Neurosurg Psychiatry* 2004;**75**:1426–30). The following errors appeared in this article:

- (1) The median CT ASPECTS and DWI ASPECTS quoted in the article were both 8. These are incorrect and should be CT ASPECTS 9 and DWI ASPECTS 8;
- (2) Sixty-six per cent (95% CI 0.56–0.75) of the patients had CT ischaemic change, while 81% (95% CI 0.72–0.88) of the DWI scans identified areas of hyperintense signal (not 67% and 79% quoted in the article);
- (3) In figure 2 the numbers in parentheses on the x axis were incorrect. The correct numbers for each ASPECTS value are 10 (34), 9 (21), 8(12), 7 (11), 6 (12), and 5 (10).