

PostScript

LETTERS

Long term results of unilateral posteroventral pallidotomy for antipsychotic drug induced tardive dyskinesia

Tardive dyskinesia (TD) is a well known side effect of neuroleptic drug treatment, and may coexist with tardive dystonia.¹ It can be treated with several drugs, although they rarely lead to a complete removal of symptoms. The main treatment of TD consists of gradual neuroleptic drug dose reduction and where possible complete withdrawal.² Nevertheless, in 40% of TD cases, symptoms do not disappear within 5 years of drug withdrawal. Wang *et al* first described a pallidotomy as a treatment modality for TD.³ In severe cases of TD and dystonia, this can lead to significant amelioration of abnormal movements and pronounced improvement in function and quality of life.⁴

PATIENT AND METHODS

We report a 51 year old, chronically hospitalised man with a 29 year history of schizophrenia. During this period, he was treated successfully for his psychotic symptoms with depot haloperidol and cisordinol. In 1993, he developed TD. Initially it consisted of an involuntary tic (myoclonus-like movements of the orofacial muscles), referred to in the literature as tardive tic.⁵ Both hands showed dyskinetic and myoclonic movements, the left hand less pronounced than the right, and there was severe acathisia. Haloperidol treatment was discontinued and symptoms of psychosis relapsed. Other medications tried included biperiden (6 mg/day), sulpiride (400 mg/day), amantadine (200 mg/day), dextimide (1.5 mg/day), oxazepam (50 mg/day), and clonazepam (1.5 mg/day). Treatment with clozapine (up to 600 mg/day) and valproate (600 mg/day) improved the psychosis and the TD temporarily, but symptoms returned and became severely devastating and invalidating, because TD progressed to involve choreo-athetotic movements, most pronounced on the right side of the body and the midline. The patient also developed choreo-athetotic movements of the jaws, tongue, lips, neck, and upper chest muscles, leading to improper and irregular breathing, involuntary grumbling, production of uncontrollable noises, and frequent periods of pain in the chest. There was dysarthria, but no abnormal swallowing. He could walk, but only in a very dyskinetic manner. Socially he was totally isolated.

Huntington's disease and Wilson's disease were excluded. The pre-operative Unified Dystonia Rating Scale (UDRS) Revised score was 24. Dyskinesia and dystonia, as scored by the Unified Parkinsons Disease Rating Scale (UPDRS) were rated as 4 for both.

Owing to the unsuccessful medical treatment, and onset of a rapid deterioration in dyskinetic symptoms in the right side of the body, we decided on left sided posteroventral pallidotomy. In July 1999, the

patient underwent surgery. Because of thoracic kyphosis, he could not be placed in a head coil or neck quad. We therefore obtained a pre-operative CT scan for "individual targeting". The coordinates of a target in the posteroventral globus pallidus (GP) were established (2 mm in front of the mid anterior-posterior commissure (AC-PC), 5 mm below the AC-PC and 21 mm lateral of the AC-PC (head width 16 cm, third ventricle width 6 mm, AC-PC 25 mm long)). Five lesions were made at 8, 6, 4, and 2 mm, and on target at 82° for 60 s. As this did not result in a satisfying improvement of dyskinesia, a 2.0 mm diameter unipolar radio-frequency electrode (Fisher TCU 003) was inserted 2 mm lateral to the first target point. A second series of lesions was performed as above, which resulted in a complete disappearance of abnormal movements.

Post-operatively, no complications were observed. Involuntary grumbling was reduced by 95%. The patient was discharged from hospital 7 days after the operation, after withdrawal of phenytoin, dexamethasone, and ciprofloxacin. The post operative UDRS score was 2, and dyskinesia measured with the UPDRS was 0.

A post-operative CT scan of the brain showed a lesion centred 23 mm lateral of the midline in the calculated target point in the left GPI. One year after this pallidotomy, the patient was functioning very well. He was very content with the nearly complete abolition of TD, which allowed him again to paint, travel, and visit his family. Now, 5 years after the operation, he is still functioning very well, with no signs of recurrence of dyskinesia and dystonia. His UDRS and UPDRS scores remain at 2 and 0 respectively.

DISCUSSION

In this case report, we describe the outcome of posteroventral pallidotomy in a patient with drug induced TD. As more experience is gained,^{3,4} posteroventral pallidotomy, a procedure with documented effects on parkinsonian dyskinesias and dystonia, seems to be an effective treatment to improve or abolish symptoms of this movement disorder. The effect is not only apparent immediately and during the first months after pallidotomy, but as is shown in this patient can be maintained for long period of time.

Gpi target localisation was based on CT as an MRI was anatomically not possible. This would have been a good case for microelectrode recording, which at the time was not available at our hospital. Instead, we overlaid two CT images, taken parallel to the AC-PC line to enhance contrast, and compared them with the concurrent Schaltenbrand atlas page. This indicated that in the second, effective, series of lesions we targeted the Gpi close to the border of the Gpe. In Parkinson's disease, very often a very small lesion in the Gpi can immediately be very successful; however in this our patient such a "parkinson Gpi lesion" had no immediate visible effect. This does not exclude the possibility that over a longer period of time positive postoperative results could have evolved, as is often observed in patients with

dystonia after pallidal stimulation or pallidotomy.

In our opinion, compared with pallidotomies in Parkinson's disease, the target for TD and dystonia could be anatomically slightly different—that is, more lateral in the posteroventral GP perhaps because of different activity of the GpE. More study into this pathology is needed.

M W P M Lenders, H P J Buschman

Department of Neurosurgery, Medical Spectrum Twente, Enschede, The Netherlands

M D I Vergouwen

Department of Neurology, Academic Medical Center, Amsterdam, the Netherlands

E N H J Steur

Department of Neurology and Movement Disorder Unit, Medical Spectrum Twente, Enschede, The Netherlands

P Kölling

Department of Psychiatry, Medical Spectrum Twente, Enschede, The Netherlands

M Hariz

Unit of Functional Neurosurgery, Institute of Neurology, Queens Square, London, UK

Correspondence to: Dr H P J Buschman, Department of Neurosurgery, Medisch Spectrum Twente, PO Box 50 000, 7500 KA Enschede, The Netherlands; rbuschman@neuromodulation.nl

doi: 10.1136/jnnp.2004.044438

Competing interests: none declared

REFERENCES

- Burke RE, Fahn S, Jankovic J, *et al*. Tardive dystonia: late-onset and persistent dystonia caused by antipsychotic drugs. *Neurology* 1982;32:1335–46.
- Gerlach J, Casey DE. Tardive dyskinesia. *Acta Psychiatr Scand* 1988;369–78.
- Wang Y, Turnbull I, Calne S, *et al*. Pallidotomy for tardive dyskinesia. *Lancet* 1997;349:777–8.
- Weetman J, Anderson IM. Bilateral posteroventral pallidotomy for severe antipsychotic induced tardive dyskinesia and dystonia. *J Neurol Neurosurg Psychiatry* 1997;63:554–6.
- Kurlan R, Kersun J, Behr J, *et al*. Carbamazepine induced tics. *Clin Neuropharmacol* 1989;12:298–302.

An Iranian family with congenital myasthenic syndrome caused by a novel acetylcholine receptor mutation (CHRN K171X)

Acetylcholine receptor (AChR) deficiency is the most common form of congenital myasthenic syndrome (CMS). Most AChR deficiencies are caused by mutations in the coding region of the AChR epsilon subunit.¹ We report an Iranian Muslim family from the province of Eastern Azerbaijan (Maragheh) in which three of five offspring of consanguineous parents had early onset CMS arising from a newly described mutation in the epsilon subunit of the AChR; this mutation

has been identified homozygously in all the three sibs. This is the first report of an AChR epsilon subunit mutation in Iran.

Case presentation

The affected brother (case 1) was 23 years old and the affected sisters were 19 (case 2) and 16 (case 3) years old. The unaffected brother was 21 and the healthy sister was 13 years old. There was no history of miscarriage or infant mortality in the family, although, according to verbal accounts from the mother, fetal movements were decreased in all the affected sibs and case 1 had a difficult labour. The clinical diagnosis of CMS in this family had been made first in 1996. All cases presented with neonatal hypotonia, regurgitation, ptosis (case 1 developed ptosis at the age of 6 months), and delayed motor milestones. The course of the disease had been slowly progressive, transiently exacerbated by stress. Generalised weakness was more severe in the afternoons. Treatment with prednisone for 1 year yielded no improvement. There was positive response to pyridostigmine bromide (Mestinon) and the required doses had gradually been increased. There were no other affected relatives in the family.

On clinical examination, all patients were ambulant, although with limited walking distance. There was bilateral ptosis and limited eye movements. The bulbar muscles were also involved, manifesting as nasal speech (more severe in case 1), chewing problems (in cases 1 and 3), swallowing difficulties, and bilateral facial weakness. Pupillary response to light was normal. Muscle involvement was predominantly proximal. Cases 1 and 3 had a waddling gait, especially in the afternoons. Deep tendon reflexes were normal. There was no muscle wasting, scapulae alatae, scoliosis, or respiratory distress. No hospitalisations for respiratory problems were reported. Case 1 had left elbow hyperlaxity and case 3 also revealed severe bilateral elbow hyperlaxity (more severe on the left side). Case 3 had mild flexion contracture of her left knee.

Muscle enzymes were normal. Electromyography of nasalis muscles showed decrements (60%, 53%, and 35% in cases 1, 2, and 3, respectively) in response to low

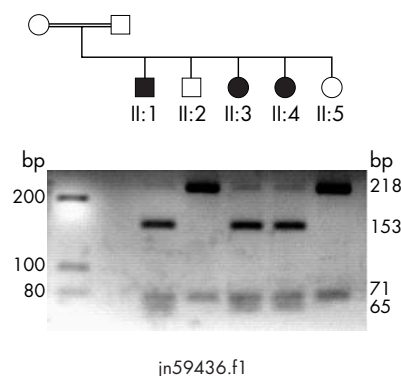


Figure 1 Pedigree and restriction enzyme analysis of the Iranian CMS family. The affected siblings (II:1, II:3, and II:4) are homozygous for the mutation *CHRNE* K171X (511A→T); the unaffected siblings (II:2 and II:5) do not carry the mutation. The mutation *CHRNE* K171X creates a new *Bfa*I site. DNA of the parents was not available for genetic studies.

frequency repetitive nerve stimulation. Anti-AChR antibodies were negative in all affected sibs.

Genetic analysis

All 12 exons, adjacent intronic regions, and the promoter region of the AChR epsilon subunit gene (*CHRNE*, GenBank accession number AF105999/gi4580858) were amplified by PCR. PCR amplified fragments were purified with the NucleoSpin Extract kit (Macherey-Nagel, Düren, Germany) and sequenced with an Applied Biosystems model 3100 Avant DNA sequencer and fluorescence labelled dideoxy terminators (Perkin-Elmer, Foster City, CA, USA).

Screening for mutation K171X of the *CHRNE* gene was performed by restriction digest of PCR products in the patients and the healthy siblings. A 304 bp fragment containing exon 6 was amplified by PCR from genomic DNA using primers 5'-AGGTACAGATGGGAACAGAG-3' and 5'-TCTGGACCCGCTAGAAGCG-3'. A *Bfa*I digest yields 218, 71, and 15 bp fragments for the wild type allele. The mutation K171X introduces a new *Bfa*I restriction site, therefore resulting in fragments of 153, 71, 65, and 15 bp in length (fig 1).

Analysis of the *CHRNE* gene revealed a homozygous nonsense mutation K171X (511A→T) in all three affected siblings. The two healthy siblings did not carry this mutation. DNA of the parents was not available for genetic analysis. The mutation causes a premature translation stop in exon 6 of the epsilon subunit of the AChR. Position 171 is located in the N-terminal extracellular domain of the epsilon subunit protein. The mutation has not been previously described in the literature.

Discussion

Severe endplate AChR deficiency can result from different types of recessive mutations in the AChR subunit genes. As the mutation identified in this family lies in the N-terminal region of the epsilon subunit, a putative translation product would not be inserted into the membrane and expressed at the cell surface. Another possibility is the degradation of the mutated epsilon subunit mRNA containing a premature stop codon in exon 6 by nonsense mediated decay. Therefore, we hypothesise that the K171X mutation leads to a deficiency of AChR at the endplate.

Mutations in the coding region of the AChR epsilon subunit are said to be a common cause of CMS in eastern Mediterranean countries.² Most of the *CHRNE* mutations reported so far are null mutations leading to receptor deficiency at the endplate. However, cases of homozygous nonsense mutations, as reported in our case, are rather rare compared to the number of frameshift and missense mutations. AChR epsilon subunit mutations have not yet been reported from Iran, despite the high rate of consanguineous marriages in the country. CMS associated with facial malformations has been reported in Iranian and Iraqi Jews,³ who were subsequently found to have a homozygous mutation (-38A→G) in an E-box element within the promoter region of the *RAPSN* gene.⁴ Another similar patient of Iranian Jewish origin has been reported with the same founder mutation in a series of early onset CMS cases.¹

The clinical features of our cases with *CHRNE* K171X mutation are similar to those

of other patients, including Europeans, with AChR epsilon mutations.¹ Although congenital joint contractures have not been previously reported in CMS patients with AChR epsilon mutations, one of our cases (case 3) had mild flexion contracture of her left knee, although, in contrast to patients with *RAPSN* mutations, none of our cases had arthrogryposis multiplex congenita.¹⁻⁵ A distinguishing feature in cases 1 and 3 was the presence of asymmetric elbow hyperlaxity. Joint laxity has not been previously reported in any type of CMS; however, it can be seen in some congenital myopathies. We postulate that fetal hypotonia in the presence of intrauterine biomechanical forces might have influenced the normal modelling of the elbow joint.

It seems that the incidence of CMS in Iran is similar to that in other countries. Recognition of differing features of CMS could help establish a definite genetic diagnosis and help implement appropriate measures.

Acknowledgements

We thank the patients and their family for their kind participation in this study.

P Soltanzadeh

Department of Neurology, Tehran University of Medical Sciences, Tehran, Iran

J S Müller

Molecular Myology Laboratory, Friedrich-Baur-Institute, Department of Neurology, Ludwig-Maximilians-University, Munich, Germany

A Ghorbani

Department of Neurology, Tehran University of Medical Sciences, Tehran, Iran

A Abicht, H Lochmüller

Molecular Myology Laboratory, Friedrich-Baur-Institute, Department of Neurology, Ludwig-Maximilians-University, Munich, Germany

A Soltanzadeh

Department of Neurology, Tehran University of Medical Sciences, Tehran, Iran

Correspondence to: Dr Payam Soltanzadeh, Department of Neurology, Shariati University Hospital, Kargar-Shomali Avenue, Tehran 14114, Iran; p_soltanzadeh@yahoo.com

doi: 10.1136/jnnp.2004.059436

This work was supported by grants from the Deutsche Forschungsgemeinschaft (DFG) to HL and AA. JSM receives a scholarship from the Boehringer Ingelheim Fonds.

Competing interests: none declared

References

- Burke G, Cossins J, Maxwell S, et al. Distinct phenotypes of congenital acetylcholine receptor deficiency. *Neuromuscul Disord* 2004;14:356-64.
- Middleton L, Ohno K, Christodoulou K, et al. Chromosome 17p-linked myasthenias stem from defects in the acetylcholine receptor epsilon-subunit gene. *Neurology* 1999;53:1076-82.
- Goldhammer Y, Blatt I, Sadeh M, et al. Congenital myasthenia associated with facial malformations in Iraqi and Iranian Jews: a new genetic syndrome. *Brain* 1990;113:1291-306.
- Ohno K, Sadeh M, Blatt I, et al. E-box mutations in the *RAPSN* promoter region in eight cases with congenital myasthenic syndrome. *Hum Mol Genet* 2003;12:739-48.
- Müller JS, Abicht A, Christen HJ, et al. A newly identified chromosomal microdeletion of the rapsyn gene causes a congenital myasthenic syndrome. *Neuromuscul Disord* 2004;14:744-9.

Transient ischaemic attack with trigeminal autonomic symptoms

Trigeminal autonomic cephalalgias present with excruciating headaches and accompanying autonomic features such as ipsilateral lachrymation, rhinorrhoea, and eyelid ptosis. For clinical purposes, these headaches are subclassified into cluster headaches, paroxysmal hemicranias, and the SUNCT syndrome (sudden unilateral neuralgiform headache with conjunctival injection and tearing),¹ of which the paroxysmal hemicrania subtypes such as the acute and chronic hemicranias are indomethacin responsive. Neuroimaging is often normal in trigeminal autonomic cephalalgias; nevertheless MRI should be considered, as there are associations between trigeminal autonomic cephalalgia and multiple sclerosis,² lateral medullary infarction,³ pontine tumours,⁴ basilar aneurysms,³ and other posterior fossa lesions. We present an unusual case of recurrent transient ischaemic attacks (TIA) with symptoms reminiscent of a trigeminal autonomic cephalalgia which ceased after a ponto-mesencephalic infarct.

Case report

A 65 year old woman was admitted with a three day history of stereotyped neurological episodes. These were characterised by a burning sensation in the left side of face, congestion of the left eye, lachrymation from the left eye, watery discharge from the left nostril, slurring of speech, and difficulty in walking. These episodes were not accompanied by headache. Each episode lasted for around 30 minutes and occurred three or four times a day. On examination, there were no focal neurological deficits. In hospital, she had four more episodes. As she had a left mature cataract (fig 1), the possibility of glaucoma induced by lens rupture was considered and ruled out. Computed tomography of the brain was unremarkable. The possibilities considered were a vertebro-basilar TIA and a trigeminal autonomic cephalalgia. As she had additional neurological symptoms, a TIA was considered more likely than trigeminal autonomic cephalalgia, and she was started on aspirin and intravenous heparin. Indomethacin was begun at 75 mg/day but had to be discontinued after a single dose because of gastric distress. Two days later, her episodic symptoms disappeared; however, she now complained of persistent right sided weakness and difficulty in walking. On examination, she had a new left sided Horner's syndrome, right upper motor neurone facial palsy, and right upper limb weakness. Deep tendon reflexes were brisker on the right than on the left. Magnetic resonance imaging of the brain at this time

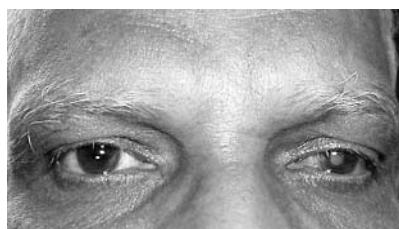

Figure 1 Congestion of the left eye during an acute attack. The patient gave written consent for this photograph to be reproduced.

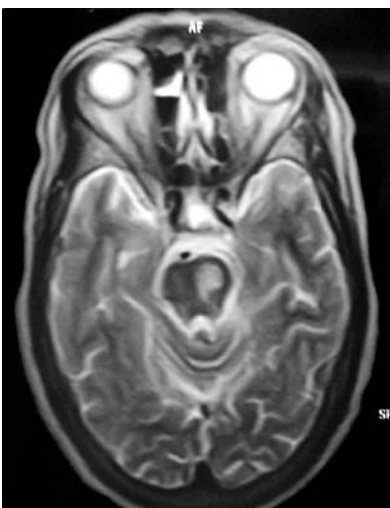

Figure 2 T2 Weighted magnetic resonance image showing an acute left ponto-mesencephalic infarct.

(one week after the onset of symptoms) showed an acute infarct at the left ponto-mesencephalic junction (fig 2). At follow up 10 days later, her gait had improved. Her episodic symptoms had disappeared.

Comment

Cranio-facial autonomic symptoms such as ipsilateral lachrymation, rhinorrhoea, conjunctival congestion, ptosis, or eyelid oedema are the sine qua non of trigeminal autonomic cephalalgia. It is thought that activation of the trigeminal afferent system generates pain, and co-activation of the VIIth nerve efferent parasympathetic pathway produces the autonomic manifestations such as ipsilateral lachrymation and rhinorrhoea. A mechanism analogous to this can be evoked to explain our patient's symptoms. She had an ischaemic stroke in the ponto-mesencephalic junction. Ischaemia in this region could involve the trigeminal main sensory and mesencephalic nuclei, resulting in facial dysaesthesia comparable to ischaemic nerve pain. In contrast to the "boring" intense pain often encountered with trigeminal autonomic cephalalgias, the burning dysaesthasias are more consistent with ischaemia. Ischaemia could also trigger trigemino-facial synapses in the superior salivatory nucleus and switch on the facial efferent parasympathetic pathway, resulting in ipsilateral lachrymation and rhinorrhoea.

To the best of our knowledge, this is the first report of a TIA presenting with trigeminal sensory-autonomic symptoms. This report highlights the expanding spectrum of trigeminal autonomic cephalalgias and emphasises the need to rule out a vertebro-basilar TIA in elderly patients with a new onset of trigeminal autonomic cephalalgia, especially if additional neurological symptoms are present.

B V Maramattom

Department of Neurology, Lourdes Hospital, Kochi, South India; bobvarkeys@yahoo.com

doi: 10.1136/jnnp.2004.061366

Competing interests: none declared

References

- 1 Goadsby PJ, Lipton RB. A review of paroxysmal hemicranias, SUNCT syndrome and other short-lasting headaches with autonomic feature, including new cases. *Brain* 1997;120:193–209.
- 2 Davey R, Al-Din A. Secondary trigeminal autonomic cephalalgia associated with multiple sclerosis. *Cephalalgia* 2004;24:605–7.
- 3 Galende AV, Camacho A, Gomez-Escalonilla C, et al. Lateral medullary infarction secondary to vertebral artery dissection presenting as a trigeminal autonomic cephalalgia. *Headache* 2004;44:70–4.
- 4 van Vliet JA, Ferrari MD, Haan J, et al. Trigeminal autonomic cephalalgia-tic-like syndrome associated with a pontine tumour in a one-year-old girl. *J Neurol Neurosurg Psychiatry* 2003;74:391–2.
- 5 Giffin NJ, Goadsby PJ. Basilar artery aneurysm with autonomic features: an interesting pathophysiological problem. *J Neurol Neurosurg Psychiatry* 2001;71:805–8.

Tympanic measurement of body temperature in stroke patients "turned on its ear"

Body temperature is an important prognostic factor in acute stroke, and it is a marker of life threatening infections such as pneumonia.¹ In clinical practice rectal temperature is regarded as a valid and reliable indicator of body temperature, but in the past 15 years tympanic infrared thermometers have been introduced into widespread clinical use. Tympanic temperature measurement is easier, faster, and less invasive than rectal measurement. However, concerns remain about the reliability and validity of this method.²

The product manual of the tympanic thermometer warns against overestimation of body temperature when the patient has been lying on one ear. Many stroke patients are hemiparalytic or hemiparetic and therefore may lie on one ear. The aim of our study was to investigate the error in tympanic temperature measurements in patients who have had a stroke and have been lying on one ear in this way.

For this observational study we included patients who had had an ischaemic or haemorrhagic stroke and were admitted to the stroke unit of a university medical centre or to the stroke rehabilitation unit of an affiliated nursing home, both in an urban area. Exclusion criteria were inability to lie on one ear and absence of a rectal cavity. We used the NIH stroke scale (NIHSS) to assess stroke severity.³ No follow up was conducted.

Tympanic temperature was measured in both ears after the patient had been lying on one ear of choice for at least 15 minutes (first measurement). The measurements were carried out in patients on waking in the morning or after an afternoon nap. The ear the patient had been lying on and the other ear will be further referred to as the lower ear and the upper ear, respectively. The second measurement was conducted by a different investigator—who was not aware of the results of the first measurement—approximately 10 minutes after the patient had no longer been lying on one ear, and consisted of tympanic and rectal temperature measurements.

To assess reliability we computed the difference between lower and upper ear temperature in consecutive tympanic measurements and analysed this difference graphically, as described by Bland and Altman.⁴ Validity was assessed by comparing the mean

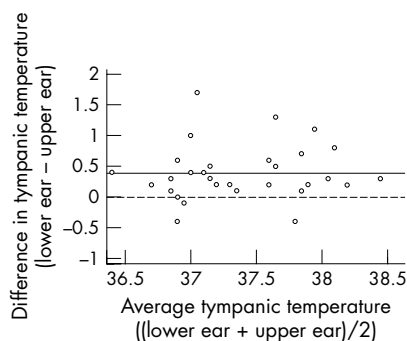


Figure 1 Difference in tympanic temperature taken from the upper and lower ear, plotted against the average tympanic temperature taken from both ears (Bland-Altman plot). The solid horizontal line in the centre indicates the mean difference between the tympanic temperatures (0.39°C), while the dashed horizontal line indicates no difference (the null hypothesis).

tympanic temperatures with mean rectal temperature.

We studied 30 patients (nine male, 21 female). Their mean age was 69.5 years, and their median NIHSS score was 11, ranging from 0 to 38. The mean of the first tympanic temperature taken from the lower ear was 37.6°C. The mean tympanic temperatures taken from the upper ear were both 37.2°C and the second measurement from the lower ear had a mean of 37.3°C. Mean rectal temperature was also 37.3°C. The mean difference between the two ears was 0.39°C (95% confidence interval, 0.22 to 0.56). This difference ranged from -0.4°C to 1.7°C (fig 1). The mean difference between the first measurement taken from the lower ear and the rectal temperature was 0.29°C (0.13 to 0.45).

Comment

Our study showed a clinically significant difference between tympanic temperature measurements in the two ears after a stroke patient had been lying on one ear. This difference disappeared after a while when the patient was no longer lying on one ear. There was no relation between actual body temperature and the size of the measurement error. Although the manufacturer of the tympanic thermometer cautions against heating of the auditory canal when the patient has been lying on one ear, especially in children, neither this effect nor its magnitude is well known.

In our opinion, a systematic error of 0.4°C on average is not acceptable from a clinical point of view. It may lead to unnecessary

investigations and treatment with antibiotics in a considerable number of patients; moreover, an error of this size could have decreased the statistical power of clinical trials of temperature lowering treatment in acute stroke patients, if tympanic temperature was used without attention being paid to the side the patient was lying on.⁵

Acknowledgements

The support of the nursing staff of the stroke units of the Erasmus Medical Centre (René Rook) and nursing home Antonius Binnenweg (Hannie van Gijzen) is gratefully acknowledged.

A J J Rampen, E J van Breda, D W J Dippel

Department of Neurology, Erasmus Medical Centre, Rotterdam, Netherlands

Correspondence to: Dr Eric J van Breda, Department of Neurology, Erasmus Medical Centre, PO box 1738, 3000 DR Rotterdam, Netherlands; <http://www.pais-study.org/>

doi: 10.1136/jnnp.2004.058149

Competing interests: none declared

References

- 1 Reith J, Jorgensen HS, Pedersen PM, *et al*. Body temperature in acute stroke: relation to stroke severity, infarct size, mortality, and outcome. *Lancet* 1996;**347**:422–5.
- 2 Varney SM, Manthey DE, Culpepper VE, *et al*. A comparison of oral, tympanic, and rectal temperature measurement in the elderly. *J Emerg Med* 2002;**22**:153–7.
- 3 Brott T, Adams HP, Olinger CP, *et al*. Measurements of acute cerebral infarction: a clinical examination scale. *Stroke* 1989;**20**:864–70.
- 4 Bland JM, Altman DG. Statistical methods for assessing agreement between two methods of clinical measurement. *Lancet*, 1986;*i*, 307–10.
- 5 van Breda EJ, van der Worp HB, van Gemert HM, *et al*. Behandeling van een beroerte door verlag van lichaamstemperatuur; "Paracetamol (acetaminophen) in stroke" (PAIS): start van een klinische trial. *Ned Tijdschr Geneesk* 2003;**147**:1976–8.

BOOK REVIEW

Brain fiction, self-deception and the riddle of confabulation

Edited by William Hirstein. Published by Wiley, 2004, £22.95 (hardcover), pp 288. ISBN 0262083388.

The striking neuropsychological symptom of confabulation represents a prototypical form of false remembering and as such has stimulated great interest among neurologists,

psychiatrists, and neuropsychologists. *Brain Fiction* by William Hirstein is the first book to place confabulation at the centre of its attention. By doing so, Hirstein is faced with the challenge of presenting and examining the various discussions surrounding the definition, the subtypes, the neural, and cognitive basis of confabulation and crucially the relation between its various forms and manifestations. *Brain Fiction*, however, has taken up further challenges. By borrowing and integrating data and notions from both neuroscience and epistemology, Hirstein puts forward an original definition and model of confabulation, as a dynamic interplay of creative and "checking" mental processes. More generally, Hirstein chooses confabulation as a promising template for the formulation of an interdisciplinary dialogue and interchange of ideas between neuroscience, psychology, and philosophy. In addition, the book proposes to hold a place for confabulation in a continuum of behaviours, ranging from "normal" other, and self-deception attempts in everyday life to deficits of theory of mind, awareness, and symptoms of sociopathy.

It should be evident from the above, that *Brain Fiction* is addressed to professionals of diverse fields and Hirstein has tried to accommodate the potential clefts in acquaintance with expert knowledge and technical terms. However, the specialised reader should keep in mind that the book does not offer an examination exhaustive in content or encyclopaedic in format. The book is of limited interest to clinicians. It mainly aims at disentangling confabulation from the strict boundaries of its hitherto neuroscientific examination and exposing it to direct philosophical enquiry. This is an endeavour that promises mutual interdisciplinary benefits. Yet the author, perhaps motivated by the existing lack of theoretical and descriptive consensus on the subject, also chooses to propose a new aetiological account of the phenomenon in neuroscientific terms. Inevitably, this analysis often entails smoothing of the hard edges of some conflicting neuroscientific findings, and partial coverage of some complex issues raised by confabulation, such as its implications for theories of consciousness, self-formation, and motivation. Such selectivity though has noteworthy benefits. The book introduces an unprecedented emphasis in the study of confabulation by placing the definition, taxonomy, and implications of the phenomenon into epistemological perspective. Thus, it sets the ground for fruitful neuro-philosophical discussions and it refreshes the way neurologists, psychiatrists, and psychologists view this and other related symptoms.

A Fotopoulou