LETTERS

Relapse of neuromyelitis optica associated with oral progestin

INTRODUCTION

Neuromyelitis optica (NMO) is an autoimmune disease of the central nervous system (CNS) characterised by optic neuritis (ON) and severe myelitis. NMO is a sexually dimorphic disease, predominantly affecting women and is active throughout most of their childbearing years. Pregnancy and delivery might adversely affect the course of NMO[1–3]; in turn, NMO could affect the outcome of pregnancy.[4] Further, immunological changes derived from high levels of oestrogen and progesterone during pregnancy might influence the outcomes of NMO. However, the effect of exogenous progesterone on NMO has not been reported. Here, we describe a female patient with NMO that relapsed after oral ingestion of progestin prescribed for her dysfunctional uterine bleeding.

CASE REPORT

A 41-year-old Chinese woman with a 14-year history of NMO (figure 1A, B) was admitted to the hospital on her fourth day of decreased visual acuity in the left eye in October 2016. Fourteen days before the present attack, she was treated with oral norethindrone for 9 days (10 mg/day for the first 3 days, 7.5 mg/day for the subsequent 3 days and 6.25 mg/day for the final 3 days) due to dysfunctional uterine bleeding. One day after withdrawal of norethindrone, vision deteriorated in her left eye. She had been taking azathioprine, 2 mg/kg/day, since the previous relapse in 2015. Neurological examination revealed poor binocular vision (uncorrected visual acuity of the left eye <20/400, but the right eye with hand movement acuity since the disease onset); other neurological abnormalities were unremarkable. A cell-based assay for serum aquaporin 4 (AQP4) antibody[5] was positive. Serum rheumatoid factor and antinuclear antibody spectrum tests were all negative. In addition, routine blood examination suggested mild anaemia, with decreased blood cell count (3.48×10^{12}/L) and haemoglobin level (96 g/dL). MRI showed enlargement of the left optic nerve and hyperintensity in fat-saturated T2-weighted sequences without gadolinium enhancement (figure 1C). Intravenous high-dose methylprednisolone (HDMP) was administered. Her uncorrected visual acuity of the left eye was 20/40 before subsequent discharge.

Since this was not her first attack related to progestin, the potential risk of a relapse of NMO after progestin exposure was a concern. A previous attack of NMO dating back to February 2015 may also have been related to progestin administration as shown in figure 1. While continuing oral low-dose prednisone (10 mg/day) to prevent relapse of NMO, she received a 9-day course of norethindrone prescribed by the gynaecologist for her dysfunctional uterine bleeding. One day after discontinuation of norethindrone, decreased visual acuity in the left eye suddenly occurred but improvement followed after HDMP therapy. Oral glucocorticoids and then azathioprine were used to prevent the recurrence of these symptoms, and azathioprine, 2 mg/kg/day, was maintained until the present relapse, which occurred after the administration of progestin.

In review of this patient's 14-year history of NMO, the initial onset occurred during her first month postpartum in November 2002. Subsequently, she suffered four relapses (figure 1A). The recent third and fourth relapses followed treatment with oral progestin and despite concurrent treatment with immunosuppressive agents (oral low-dose prednisone or azathioprine). Before the two progestin-related relapses, two additional relapses occurred, presumably due to her voluntary cessation of low-dose prednisone treatment (10 mg/day) (figure 1A). All four episodes of NMO began 4–5 days before menstruation.

DISCUSSION

In the present case study, we describe a female patient with NMO whose recent two attacks appeared to be associated with oral progestin treatment for a gynaecological disease. This case report underscores the need for considering the effects of exogenous progestin on the disease course of NMO.

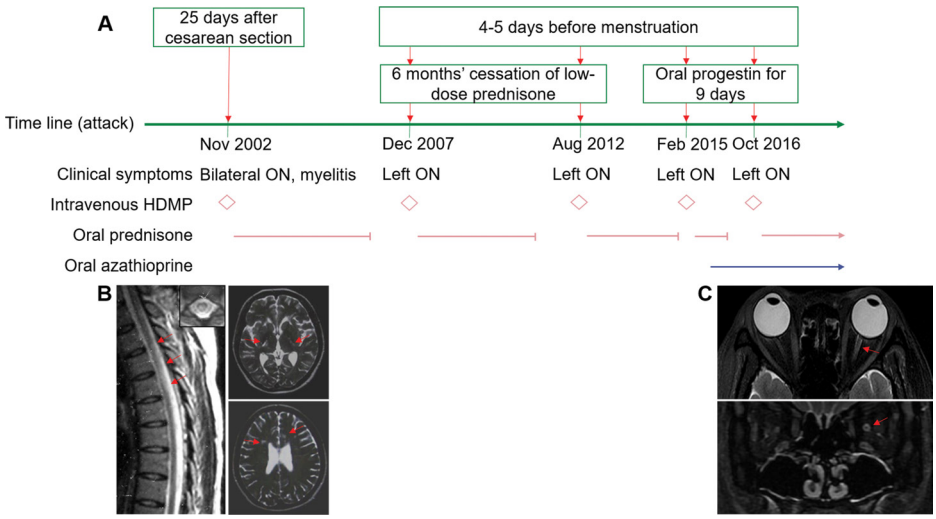

Figure 1 The clinical, paraclinical course and therapeutic regimens of a female patient with NMO. (A) Timeline of NMO and therapeutic regimens. (B) November 2002: sagittal T2-weighted image of spinal cord exhibits hyperintense lesions in the thoracic spinal cord from the T2 to T4 levels. Axial brain MRI scan shows corticospinal tract lesions involving the posterior limb of the internal capsule and periventricular area on T2-weighted sequence. (C) October 2016: fat-saturated T2-weighted axial (above) and coronal (below) images show left optic nerve enlargement with hyperintensity. NMO, neuromyelitis optica; ON, optic neuritis; HDMP, high-dose methylprednisolone; red ◊ symbols, period of high-dose methylprednisolone use; red horizontal lines, period of oral prednisone treatment; blue horizontal lines, period of oral azathioprine treatment.

J Neurol Neurosurg Psychiatry: first published as 10.1136/jnnp-2017-316356 on 9 October 2017. Downloaded from http://jnnp.bmj.com/ on April 23, 2024 by guest. Protected by copyright.

NMO is an autoimmune disease of the CNS mediated by anti-AQP4 antibodies, and the production of autoantibody is T helper (Th)-cell dependent. Recent research suggests that the high levels of progesterone and oestrogen during pregnancy induce marked changes in the immunological milieu of NMO.[6] Elevated levels of endogenous progesterone and oestrogen can boost the production of interleukin-6 and B-cell activating factor, which may facilitate the survival and activity of self-reactive peripheral B cells and production of anti-AQP4 antibody.[6] Additionally, high levels of sex hormones might increase antibody glycosylation and activation-induced cytidine deaminase expression, which is responsible for immunoglobulin mutation and class switching.[6] High levels of progesterone and oestrogen might decrease interferon-γ generation, which is postulated to enhance Th2-mediated immunity.[6] The change in helper T cell subset, AQP4 antibody classes, subclasses and glycosylation pattern under the influence of sex hormones during and after pregnancy may also lead to disease progression. For the current patient, her four relapses coincided with the fourth or fifth day before menstruation. This sequence appears consistent with the potential relationship between the hormonal changes and activity of NMO. Significantly, the most recent (third and fourth) relapses followed administration of the exogenous supplemental progestin, suggesting that oral progestin might increase the risk of relapse in NMO.

A survey of published literature regarding female hormonal impact on the course of NMO reported that the annual relapse rate (ARR) increased in the first 3 months postpartum.[1–3] Additionally, ARR was not significantly reduced[2 3] during the third trimester of the pregnancy. No explanations for these reports are currently available. Furthermore, whether oral progestin therapy produces a similar effect to that of endogenous progesterone in vivo[6] is unclear as are its governing mechanisms. The potential complex interplay between female hormones and the immune system, and their impact on the clinical manifestations of NMO, warrant further study to understand the pathogenesis of NMO and its management in female patients.

Li-Min Li,[1] Chao Zhang,[1] Lin-Jie Zhang,[1] Hui-Yue Guo,[1] Chun-Sheng Yang,[1] Rui Zhang,[1] Yu-Jing Li,[1] Fu-Dong Shi,[1,2] Li Yang[1]

[1]Department of Neurology, Tianjin Neurological Institute, Tianjin Medical University General Hospital, Tianjin, China

[2]Department of Neurology, Barrow Neurological Institute, St. Joseph's Hospital and Medical Center, Phoenix, Arizona, USA

Correspondence to Dr Li Yang, Department of Neurology, Tianjin Neurological Institute, Tianjin Medical University General Hospital, Tianjin 300052, China; yangli2001@tmu.edu.cn

Contributors L-ML, CZ, L-JZ, H-YG, C-SY, RZ and LY managed the patient; Y-JL performed AQP4 antibody detection; L-ML drafted the manuscript; LY and F-DS edited and revised the manuscript.

Funding This work was supported by National Natural Science Foundation of China (grant number: 81471221)

Competing interests None declared.

Patient consent Obtained.

Ethics approval The present study was approved by the Ethics Committee of Tianjin Medical University General Hospital.

Provenance and peer review Not commissioned; externally peer reviewed.

OPEN ACCESS

Open Access This is an Open Access article distributed in accordance with the Creative Commons Attribution Non Commercial (CC BY-NC 4.0) license, which permits others to distribute, remix, adapt, build upon this work non-commercially, and license their derivative works on different terms, provided the original work is properly cited and the use is non-commercial. See: http://creativecommons.org/licenses/by-nc/4.0/

© Article author(s) (or their employer(s) unless otherwise stated in the text of the article) 2018. All rights reserved. No commercial use is permitted unless otherwise expressly granted.

Check for updates

To cite Li L-M, Zhang C, Zhang L-J, *et al*. *J Neurol Neurosurg Psychiatry* 2018;**89**:788–789.

Received 2 May 2017
Revised 18 September 2017
Accepted 22 September 2017
Published Online First 9 October 2017

J Neurol Neurosurg Psychiatry 2018;**89**:788–789.
doi:10.1136/jnnp-2017-316356

REFERENCES

1 Bourre B, Marignier R, Zéphir H, *et al*. Neuromyelitis optica and pregnancy. *Neurology* 2012;78:875–9.
2 Kim W, Kim SH, Nakashima I, *et al*. Influence of pregnancy on neuromyelitis optica spectrum disorder. *Neurology* 2012;78:1264–7.
3 Shimizu Y, Fujihara K, Ohashi T, *et al*. Pregnancy-related relapse risk factors in women with anti-AQP4 antibody positivity and neuromyelitis optica spectrum disorder. *Mult Scler* 2016;22:1413–20.
4 Nour MM, Nakashima I, Coutinho E, *et al*. Pregnancy outcomes in aquaporin-4-positive neuromyelitis optica spectrum disorder. *Neurology* 2016;86:79–87.
5 Yang CS, Zhang DQ, Wang JH, *et al*. Clinical features and sera anti-aquaporin 4 antibody positivity in patients with demyelinating disorders of the central nervous system from Tianjin, China. *CNS Neurosci Ther* 2014;20:32–9.
6 Davoudi V, Keyhanian K, Bove RM, *et al*. Immunology of neuromyelitis optica during pregnancy. *Neurol Neuroimmunol Neuroinflamm* 2016;3:e288.

J Neurol Neurosurg Psychiatry: first published as 10.1136/jnnp-2017-316356 on 9 October 2017. Downloaded from http://jnnp.bmj.com/ on April 23, 2024 by guest. Protected by copyright.