

## Letters

## Clinical and biological features of cerebral venous sinus thrombosis following ChAdOx1 nCoV-19 vaccination

Vaccines for COVID-19 were developed with unprecedented speed and since January 2021, the AstraZeneca/Oxford University ChAdOx1 nCoV-19 vaccine has been administered to over 400 million people globally.<sup>1</sup> In April 2021, the Medicines and Healthcare products Regulatory

Agency (MHRA) and the European Medicines Agency reported a possible association between ChAdOx1 nCoV-19 and a rare syndrome of unusual site thrombosis combined with thrombocytopenia, termed vaccine-induced immune thrombotic thrombocytopenia (VITT). Frequency of VITT varies across age groups. Overall, 411 cases of VITT have been reported to the MHRA by 21 July 2021 with fatality rate of 17.76% (73/411).<sup>2</sup>

We report our experience of four VITT cases from a single tertiary referral centre in London, UK, who suffered cerebral venous sinus thrombosis (CVST) with or without thrombosis elsewhere. Baseline

clinical and laboratory features are shown in [table 1](#). Informed written consent was obtained from all patients before publication. All patients fulfilled the proposed diagnostic criteria for VITT<sup>3,4</sup>. Each case was reported via the MHRA Yellow card scheme and other national VITT–CVST surveillance projects.

All four patients were women aged 41–46 years and diagnosed with VITT 7–28 days post ChAdOx1 nCoV-19 vaccination. Each presented with headache and varying degrees of neurological deficit. Detailed case histories are provided in the online supplemental material. Neuroimaging for patient 1 demonstrated

**Table 1** Baseline characteristics and laboratory markers of four patients presenting with cerebral venous sinus thrombosis following AstraZeneca/Oxford University ChAdOx1 nCoV-19 vaccine

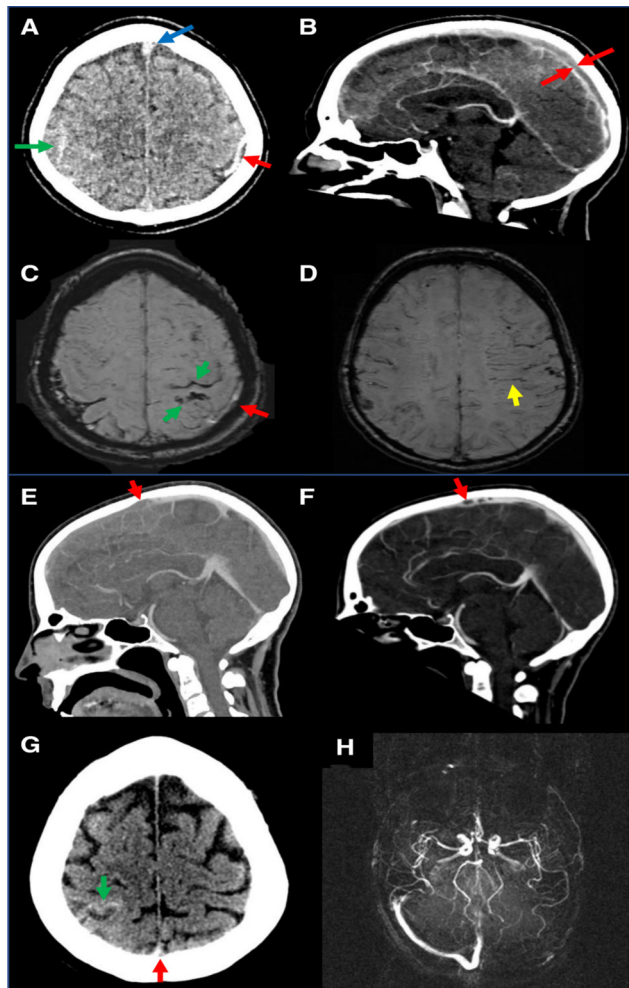
	Patient 1	Patient 2	Patient 3	Patient 4
Sex	Female	Female	Female	Female
Age (years)	46	41	43	46
Medical history	Migraine	Migraine	Hypertension Deep Vein Thrombosis	Migraine
Clinical presentation	Headache, collapse, hemiparesis	Headaches, vomiting, abdominal pain	Shortness of breath, collapse headache, paraesthesia	Headache
No. of days post vaccine	14	9	28	9
Thrombosis	CVST	CVST Branch portal vein thrombus PE	CVST Pulmonary saddle embolus	CVST Hepatic vein thrombus Portal vein thrombus
Bleeding	Subarachnoid haemorrhage	None	Subarachnoid haemorrhage	None
Admission bloods				
HemosIL AcuStar HIT-IgG* (<1 U/mL)	0.05 (neg)	0.03 (neg)	0.04 (neg)	0.02 (neg)
Immucor ELISA PF4 HIT-IgG (<0.4 Optical Density (OD))	<b>2.48</b>	<b>2.19</b>	<b>2.35</b>	<b>2.18</b>
HYPHEN BioMed ELISA PF4 HIT-IgG (<0.4 OD)	<b>1.67</b>	<b>1.89</b>	<b>1.92</b>	<b>1.78</b>
Platelets (150–400×10 <sup>9</sup> )	<b>39</b>	<b>125</b>	<b>161</b>	<b>57</b>
D-dimer (<500 ng/mL), FEU	>20 000	>20 000	>20 000	>20 000
Fibrinogen (1.9–4.3 g/L)	<b>0.7</b>	4.26	2.75	<b>1.4</b>
Troponin (ng/L) (<19.8)	4.3	<b>54.8</b>	4.6	1.6
PT (12.8–17.4 s)	14.7	13.5	14.8	12.0
APTT (25.0–35.0 s)	<b>43.2</b>	28.5	26.2	39.0
DRVVT ratio	Negative	Negative	Negative	Negative
Antithrombin (70–130 IU/dL)	107	110	123	114
Protein C activity (70–130 IU/dL)	72	155	65	144
Free protein S antigen (70–130 IU/dL)	68.8	119.0	102.8	92.7
Factor VIII (50–150 IU/dL)	64.3	172.7	59.2	193
VWF:Ag (50–150 IU/dL)	220	202.8	226.3	220.1
VWF:Rco (50–150 IU/dL)	235	192.2	236.1	178.1
Plasminogen activity (70–130 IU/dL)	72	101	84	94
PAI-1 (ng/mL)*†	<b>10.1</b>	<b>12.9</b>	<b>38.3</b>	<b>25.8</b>
E-selectin*†	6.9	<b>14.0</b>	9.9	7.2
ICAM-1*†	78.8	138.6	129.7	130.1
VCAM-1*†	<b>1192.8</b>	760.3	<b>1605.8</b>	<b>1276.5</b>
Thrombomodulin*†	4.9	3.9	<b>6.0</b>	5.9
P-selectin*†	33.1	<b>37.3</b>	<b>82.4</b>	<b>59.7</b>
C3 (0.79–1.52 mg/dL)	1.25	<b>0.23</b>	0.79	1.06
C4 (0.16–0.38 mg/dL)	<b>0.10</b>	0.35	<b>0.12</b>	<b>0.25</b>
C3a (ng/mL)††	<b>289.4</b>	151.8	<b>570.2</b>	80.4
C5b-9 (ng/mL)††	184.8	194.9	<b>468.9</b>	<b>254.2</b>

\*Mean (range) levels in eight control plasma samples tested in parallel: PAI-1: 4.1 (2.9–6.7); E-selectin: 7.5 (2.8–13.5); ICAM-1: 98.8 (77.0–148.0); VCAM-1: 671.9 (190.7–1076); thrombomodulin: 5.1 (4.8–5.8) and P-selectin: 26.5 (0–34.7) ng/mL.

†Performed in postadmission bloods.

‡Mean (range) in control plasma as defined by manufacturer: C3a: 129.6 (33.8–268.1) and C5b-9: 147 (75–219) ng/mL. Values in bold are abnormal.

APTT, activated partial thromboplastin time; CVST, cerebral venous sinus thrombosis; DRVVT, dilute Russell's viper venom time; ICAM-1, intercellular adhesion molecule-1; PAI-1, plasminogen activator inhibitor-1; PE, pulmonary embolus; PF4, platelet factor 4; PT, prothrombin time; VCAM-1, vascular cell adhesion molecule-1; VWF:Ag, Von Willebrand antigen; VWF:Rco, Von Willebrand factor ristocetin factor.



**Figure 1** Cranial images from four patients with cerebral venous sinus thrombosis vaccine-induced immune thrombotic thrombocytopenia. (A) Initial non-contrast CT scan of the head performed on admission of patient 1. A left parietal cortical vein (red arrow) is hyperdense and expanded, as is the anterior aspect of the superior sagittal sinus (blue arrow). Diffuse high attenuation is seen within the sulcal spaces of the right parietal lobe in keeping with subarachnoid haemorrhage (green arrow). (B) Midline sagittal slice from CT venogram (CTV) performed at admission of patient 1. There is an extensive filling defect throughout the entirety of the imaged superior sagittal sinus (red arrows). Contrast can be seen anterior to the thrombus. (C,D): MR susceptibility-weighted imaging sequence performed 2 weeks following admission of patient 1. (C) A filling defect is still present within the left cortical parietal vein (red arrow). Foci of susceptibility are present within the sulcal and cortical superior parietal lobule in keeping with subarachnoid haemorrhage with haemosiderin staining (green arrows). (D) Multiple dilated deep medullary veins (yellow arrow) within the left cerebral hemisphere which have developed as a result of the venous obstruction. (E) Initial CTV head performed on admission for patient 2. A large thrombus is seen within the mid-superior sagittal sinus where it is expanded (red arrow). It extends anteriorly with no contrast opacification anteriorly. (F) CTV performed at 2 weeks for patient 2 shows interval improvement with a reduction in size of the thrombus (red arrow) at the mid-superior sagittal sinus and contrast visible anteriorly. (G) Patient 3 initial unenhanced CT scan performed at the time of admission. There is subarachnoid haemorrhage (green arrow) within right post-central sulcus with cortical oedema posteriorly. Hyperdensity within the posterior superior sagittal sinus in keeping with acute sinus venous thrombosis (red arrow). (H) Reconstructed 3D Maximum Intensity Projection (MIP) projection from a contrast-enhanced MR venogram for patient 4 performed on day 3 of admission. Complete lack of contrast opacification within the left transverse or sigmoid sinus due to extensive venous thrombosis is seen.

extensive thrombosis involving both the dural venous sinuses and superficial cortical veins as well as associated subarachnoid haemorrhage in the parietal sulci bilaterally (figure 1A–D) but

no thrombosis detected in imaging of the abdomen. Patient 2 initially presented with superior sagittal sinus thrombosis associated with right-sided neurological deficit (figure 1E), branch intrahepatic

portal venous thrombus and non-occlusive segmental pulmonary arteries filling defects consistent with pulmonary emboli (CT pulmonary angiogram (CTPA)). CT venogram (CTV) performed 2 weeks later showed improvement with a reduction in thrombus size (figure 1F). In patient 3, CTV demonstrated extensive dural venous sinus thrombosis affecting the superior sagittal, left transverse and sigmoid sinuses (online supplemental figure S1) and CTPA revealed a large saddle embolus with extensive thrombus extending into all lobar branches bilaterally with features of right heart strain (online supplemental figure S2). MRI further delineated multiple sites of thrombosed cortical veins and subarachnoid haemorrhage (figure 1G). For patient 4, CTV demonstrated extensive CVST with secondary area of infarct/oedema in the left posterior temporal lobe (figure 1H). CT scan of the abdomen demonstrated portal (online supplemental figure S3A) and hepatic vein thrombus (online supplemental figure S3B).

Of the typical abnormal blood parameters reported in the literature for VITT, thrombocytopenia and hypofibrinogenemia were evident in three out of four and two out of four patients, respectively, and all four exhibited grossly raised D-dimer. We confirm the importance of selecting appropriate anti-platelet factor 4 (PF4) antibody tests<sup>5</sup> as all patients tested negative in the AcuStar HIT-IgG (PF4-H) chemiluminescent assay but strongly positive in two anti-PF4 ELISAs (ImmuCor, Hyphen BioMed) (table 1). Additional autoantibody tests revealed low levels of antinuclear antibodies in patients 2 and 4 (23–30 units at 1:40 serum dilution, assay cut-off=20 units), while antiphospholipid (aPL) antibodies were undetectable in nine different aPL assays employed (IgG, IgM, IgA anticardiolipin and anti- $\beta$ 2GPI; IgG anti-domain I of  $\beta$ 2GPI; IgG, IgM anti-phosphatidylserine/prothrombin). Thus, our results reinforce the conclusion that anti-PF4 is the key pathogenic antibody in VITT.

A uniform management approach was taken with urgent plasma exchange (PLEX) initiated in combination with Intravenous Immunoglobulin (IVIg) (1 g/kg in two divided doses over 2 days timed appropriately around PLEX to minimise loss of IVIg), high-dose steroids (1 g intravenous methylprednisolone followed by 20 mg dexamethasone intravenous or oral for 4 days with tapering dose over the next few days) and non-heparin-based anticoagulants (initially argatroban) with rituximab (375 mg/m<sup>2</sup>) in two patients. All four

patients survived with complete resolution of symptoms and laboratory markers supporting this therapeutic approach in a syndrome currently estimated as having a 70% mortality rate especially in those presenting with evidence of bleeding.<sup>3 6</sup> Transformation of cerebral infarction to haemorrhage is a well-recognised complication of CVST and may have been exacerbated by severe thrombocytopenia and hypofibrinogenemia (both of which were apparent in our first case) as well as the need for anticoagulation.

Overall management of the four cases presented here represents an aggressive approach to VITT and we believe this played a central role in the favourable outcome of our patients. Patient 1 had a dramatic presentation and was critically unwell with a Glasgow Coma Score of 10 on arrival. Her laboratory markers also reflected severe disease. Given the high mortality rates in such a presentation, a decision was made to start PLEX early and resulted in a rapid improvement in clinical status. While IVIg and PLEX address preformed VITT antibodies, the short course of high-dose steroids was given to reduce further antibody formation and reduce the cerebral oedema associated with the extensive CVST and cerebral haemorrhage. We adopted the same strategy for the subsequent three patients although their presentations were less severe. With respect to anticoagulation, argatroban was chosen as its short half-life of 45 min permits monitoring and rapid adjustment. Once clinically stabilised and platelet recovery was observed, anticoagulation was switched to once daily fondaparinux and then to the oral anticoagulant apixaban on discharge. Online supplemental table S1 (patient 1) and online supplemental figure S5 summarise changes in laboratory markers in response to treatment.

Intriguingly, all four patients had notably raised levels of von Willebrand factor antigen and activity, as well as plasminogen activator inhibitor-1 compared with control plasma tested in parallel. Circulating factor VIII, thrombomodulin, E-selectin, intercellular adhesion molecule-1, vascular cell adhesion molecule-1 and P-selectin were also elevated to variable degrees (table 1; methods summarised in online supplemental material page 4). Taken together, these findings suggest ongoing fibrinolysis and are indicative of an inflammatory platelet and endothelial response. In contrast, prothrombin time, activated partial thromboplastin time, antithrombin, protein S and protein C measurements were unremarkable suggesting that patients are not developing

disseminated intravascular coagulation. This is slightly surprising given the very high D-dimer and reduced fibrinogen, which must therefore reflect localised fibrin formation and breakdown.

Further serological analysis (table 1) in our four patients may point towards additional approaches for VITT management. Results from our functional platelet aggregation assay suggest that although it is generally recommended to avoid heparin anticoagulant in VITT, it may not aggravate progressive thrombosis (online supplemental figure S4). Platelet aggregation induced by serum from three patients in the absence of heparin was reduced with both low-dose and high-dose Unfractionated Heparin compared with control serum (in contrast to classical HIT serum). Serum from patient 3 who was not thrombocytopenic at any time had no effect on donor platelet aggregation (online supplemental figure S4).

Complement inhibition with eculizumab was also shown to benefit VITT<sup>7</sup> and indeed complement activation was evident in our patients as demonstrated by low levels of C3 (patient 2) and C4 (patients 1, 3 and 4) coupled with raised C3a (patients 1 and 3) and C5b-9 (patients 3 and 4) (table 1). It is worth noting that thrombin, FXa and plasmin generated during the fibrinolytic process are all capable of inducing complement activation and C5b-9 terminal complex assembly. We propose measurement of both total complement levels and activation products may support stratified patient management with anticomplement biologics.

To our knowledge, this is the first study to interrogate immune, coagulant/haemostatic, platelet and endothelial disturbances combined with imaging in VITT. Our clinical and laboratory findings are remarkably uniform, consistent with a genuine syndrome<sup>3 4</sup> and the good outcomes reported here suggest that rapid aggressive therapy directed at pathogenesis could be beneficial. As the number of VITT cases rises globally, it is of utmost importance to understand the biological mechanisms that drive or further complicate VITT.

Christina Crossette-Thambiah,<sup>1,2</sup>  
Charis Pericleous,<sup>3</sup> Namir Asmar,<sup>4</sup>  
Joshua Bomsztyk,<sup>2</sup> Amita Ranger,<sup>2</sup>  
Abdul Shlebak,<sup>2</sup> Saipriya Ramji,<sup>5</sup>  
Soma Banerjee,<sup>6</sup> Mike Laffan,<sup>1,2</sup>  
Deepa J Arachchillage <sup>1,2</sup>

<sup>1</sup>Centre for Haematology, Department of Immunology and Inflammation, Imperial College London, London, UK

<sup>2</sup>Department of Haematology, Imperial College Healthcare NHS Trust, London, UK

<sup>3</sup>National Heart and Lung Institute, Imperial College London, London, UK

<sup>4</sup>Department of Neuroradiology, Imperial College Healthcare NHS Trust, London, UK

<sup>5</sup>Neuroradiology, Imperial College Healthcare NHS Trust, London, UK

<sup>6</sup>Department of Stroke & Neurosciences, Imperial College Healthcare NHS Trust, London, UK

**Correspondence to** Dr Deepa J Arachchillage, Centre for Haematology, Department of Immunology and Inflammation, Imperial College London, London, UK; d.arachchillage@imperial.ac.uk

**Twitter** Deepa J Arachchillage @DeepaArachchil1

**Acknowledgements** The authors would like to thank Dr Nina Salooja, Dr Fateha Chowdhury, Dr Kamala Gurung and Dr Isaac Obisanya, all clinical teams at intensive care and hyperacute stroke unit, nursing staff of the Apheresis Team and laboratory staff involved in care of the patients at Imperial College Healthcare NHS Trust. The authors would like to specially thank the haematology and biochemistry laboratory staff (Steve Fox, Francine Leutche-Djoudie, Harsha Hirani and Nelesh Morjari) at Royal Brompton Hospital for performing most of the additional laboratory assays and Dr Marta Peverelli at National Heart and Lung Institute, Imperial College London.

**Contributors** DJA conceived the study, involved in data collection, data verification, data analysis, figures and data interpretation, wrote the original draft and reviewed and edited the manuscript. CC-T contributed to data collection, data verification, data analysis, figures and writing and editing the original manuscript. CP performed some of the laboratory assays and involved in data analysis, data interpretation and writing and editing of the manuscript. ML interpreted the data and wrote and revised the manuscript. JB and AR contributed to data collection. NA and SR provided radiology images and edited the manuscript. AS and SB contributed to writing the manuscript. All authors reviewed and approved the final version of the manuscript.

**Funding** This study was partly funded by Imperial College COVID19 Research Fund (P88531 received by DJA and G26266 received by CP and DJA). CP was funded by Versus Arthritis (21223).

**Competing interests** DJA received research funding from Bayer PLC and Leo Pharma outside of this research project. ML received consultation and speaker fees from AstraZeneca, Sobi, Leo Pharma, Takeda and Pfizer but it was not related to this research project. Others have no conflict of interests to declare.

**Patient consent for publication** Obtained.

**Ethics approval** This study was approved by research ethics committee approval (17/WA/0161).

**Provenance and peer review** Not commissioned; externally peer reviewed.

**Data availability statement** Raw data can be made available via direct contact with DJA (d.arachchillage@imperial.ac.uk).

**Supplemental material** This content has been supplied by the author(s). It has not been vetted by BMJ Publishing Group Limited (BMJ) and may not have been peer-reviewed. Any opinions or recommendations discussed are solely those of the author(s) and are not endorsed by BMJ. BMJ disclaims all liability and responsibility arising from any reliance placed on the content. Where the content includes any translated material, BMJ does not warrant the accuracy and reliability of the translations (including but not limited to local regulations, clinical guidelines, terminology, drug names and drug dosages), and is not responsible

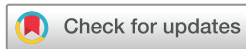for any error and/or omissions arising from translation and adaptation or otherwise.

This article is made freely available for personal use in accordance with BMJ's website terms and conditions for the duration of the covid-19 pandemic or until otherwise determined by BMJ. You may download and print the article for any lawful, non-commercial purpose (including text and data mining) provided that all copyright notices and trade marks are retained.

© Author(s) (or their employer(s)) 2022. No commercial re-use. See rights and permissions. Published by BMJ.

► Additional supplemental material is published online only. To view, please visit the journal online (<http://dx.doi.org/10.1136/jnnp-2021-327340>).

CC-T and CP contributed equally.



**To cite** Crossette-Thambiah C, Pericleous C, Asmar N, *et al.* *J Neurol Neurosurg Psychiatry* 2022;**93**:445–448.

Received 11 June 2021

Accepted 26 August 2021

Published Online First 29 September 2021

*J Neurol Neurosurg Psychiatry* 2022;**93**:445–448.

doi:10.1136/jnnp-2021-327340

**ORCID iD**

Deepa J Arachchillage <http://orcid.org/0000-0001-5993-4850>

**REFERENCES**

- 1 WCC-DGWHO. Available: <https://covid19.who.int/>
- 2 . Available: [https://assets.publishing.service.gov.uk/government/uploads/system/uploads/attachment\\_data/file/1005194/Coronavirus\\_vaccine\\_-\\_summary\\_of\\_Yellow\\_Card\\_reporting\\_14.07.21\\_clean.pdf](https://assets.publishing.service.gov.uk/government/uploads/system/uploads/attachment_data/file/1005194/Coronavirus_vaccine_-_summary_of_Yellow_Card_reporting_14.07.21_clean.pdf)
- 3 Scully M, Singh D, Lown R, *et al.* Pathologic antibodies to platelet factor 4 after ChAdOx1 nCoV-19 vaccination. *N Engl J Med* 2021;384:2202–11.
- 4 Guidance produced by the expert haematology panel (Ehp) focussed on vaccine induced thrombosis and thrombocytopenia (VITT). Available: <https://b-s-h.org.uk/about-us/news/guidance-produced-by-the-expert-haematology-panel-ehp-focussed-on-vaccine-induced-thrombosis-and-thrombocytopenia-vitt/>
- 5 Platton S, Bartlett A, MacCallum P, *et al.* Evaluation of laboratory assays for anti-platelet factor 4 antibodies after ChAdOx1 nCoV-19 vaccination. *J Thromb Haemost* 2021;19:2007–13.
- 6 Greinacher A, Thiele T, Warkentin TE, *et al.* Thrombotic thrombocytopenia after ChAdOx1 nCov-19 vaccination. *N Engl J Med* 2021;384:2092–101.
- 7 Tiede A, Sachs UJ, Czwalinna A, *et al.* Prothrombotic immune thrombocytopenia after COVID-19 vaccination. *Blood* 2021;138:350–3.