

LETTER

Neurological manifestations of the coronavirus (SARS-CoV-2) pandemic 2019–2020

INTRODUCTION

Since December 2019, a cluster of cases with contact history of live animals in Huanan seafood wholesale market of Wuhan city developed an unexplained course of pneumonia. A novel virus was identified and named severe acute respiratory syndrome coronavirus 2 (SARS-CoV-2). Later on, WHO declared that the outbreak constitutes a Public Health Emergency of International Concern and named the disease COVID-19. As of 6 April 2020, more than 1 270 000 human infections with the novel coronavirus have been confirmed in more than 200 countries or regions with nearly 70 000 reported deaths. Studies revealed that angiotensin-converting enzyme 2 (ACE2) is the main host cell receptor of SARS-CoV-2.¹ Since ACE2 is expressed in the neurons and glial cells, COVID-19 may also cause neurological symptoms. Considering the neurological manifestations of COVID-19 have been rarely mentioned in past literature,² familiarising neurologists with the clinical course of the disease is critical in treating and controlling the disease.

INFECTIOUS AGENT AND CLINICAL FEATURES

The coronavirus known as SARS-CoV-2 is a novel beta coronavirus in the form of RNA and has nearly 29 000 nucleotide base pairs that hold the genetic code for viral production. SARS-CoV-2 is transmitted mainly through respiratory tract secretions or by direct contact. Asymptomatic persons are also potential sources of SARS-CoV-2 infection. Based on the current epidemiological investigations, the incubation period ranges from 1 to 14 days.

The clinical manifestations of COVID-19 include fever, fatigue and dry cough. Patients with mild course may only present low-grade fever, mild fatigue and no signs of pneumonia. Dyspnoea and/or hypoxemia occurs in patients with severe course after 1 week. Critical cases were rapidly progressive with complications like acute respiratory distress syndrome, septic shock, refractory metabolic acidosis and coagulation dysfunction developing in days.

NEUROLOGICAL SYMPTOMS

Neurological symptoms have been observed in patients with COVID-19 in China. These symptoms are grouped into several categories, including acute cerebrovascular disease related symptoms, intracranial infection related symptoms, peripheral nervous system symptoms and neuromuscular symptoms. Some patients may also present neuralgia, sensory abnormalities and sphincter disturbances. Neurologists need to be vigilant to the symptoms outlined below. A differential diagnosis should always be considered.

Headache

A recent study in Wuhan showed headache as a symptom occurred in 8% of patients² but another study from Zhejiang found that 34% of patients complained of headache.³ This non-specific symptom may increase the difficulty of diagnosis if headache is the only onset symptom when a patient seeks medical attention. Thus besides following routine protocols, neurologists should inquire about the patients' medical and epidemiological history in more detail under current circumstances, especially for those who had fever and/or contact history with suspected or confirmed cases. For atypical cases, blood tests, respiratory pathogen tests and thoracic CT examinations should be performed.

Acute cerebrovascular disease related symptoms

Among confirmed patients with COVID-19, significant numbers of elderly individuals were severely affected. The high D-dimer levels observed in intensive care unit (ICU) patients predispose to a hypercoagulable state.^{2–4} The elderly patients will, additionally, have the usual risk factors for cerebrovascular disease. Considering ACE2 is an entry receptor for SARS-CoV-2, the lower platelet count¹ in critical cases suggests that patients with hypertension infected by SARS-CoV-2 may experience increased blood pressure and higher risk for cerebrovascular haemorrhage. Thus, clinicians at the front line need to involve neurologists for patient management in case of such vascular and other neurological complications in patients with COVID-19.

Intracranial infection related symptoms

Intracranial infection related symptoms such as headache, epilepsy, disturbance of consciousness have been described in COVID-19.⁴ Past evidence from SARS revealed possible central nervous system

infection by SARS-CoV. Given the fact that SARS-CoV and SARS-CoV-2 share common genetic sequences and use the same ACE2 receptor to gain entry inside the cells, neurologists should consider the possibility of central nervous system infection by SARS-CoV-2 when facing suspected cases. In a patient with COVID-19 and neurological symptoms and signs, imaging and if possible a lumbar puncture with PCR for the SARS-CoV-2 and other viruses should be considered.

The first case of COVID-19 with encephalitis was reported in Beijing, China. This patient presented with convulsions and persistent hiccups. Neurological examination revealed slow pupillary response, bilateral ankle clonus, bilateral positive Babinski sign and meningeal irritation. The patient had a normal CT scan. A lumbar puncture showed an increased opening pressure of 330 mmH₂O, normal biochemical and cytological parameters with a positive PCR for SARS-CoV-2. COVID-19 patients with dysregulated immune system can be co-infected with other pathogens and this may further complicate and deteriorate their condition. Since metagenomics next generation sequencing test on patient's cerebrospinal fluid (CSF) sample is unavailable, whether the encephalitis was caused by the co-infection of other pathogens is still undetermined. Recently, another rare case of COVID-19 with tuberculous meningitis is reported.⁵ This further reminds the neurologists that a comprehensive pathogen examination is required⁵ when COVID-19 patients present encephalitis or meningitis related symptoms.

Peripheral nervous system symptoms

A study in Wuhan showed that among patients with peripheral nervous system symptoms, the most common complaints were hypogeusia and hyposmia.⁴ Other peripheral nervous system symptoms include deficit in visual function and neuralgia.⁴ So far, electromyography report of COVID-19 with peripheral nervous system symptoms is still lacking.


Muscle damage related symptoms

Some patients showed fatigue, muscle soreness and elevated muscle enzyme levels, which may be related to the inflammation and muscle damage caused by the virus.

CONCLUSION

At present, COVID-19 has been declared a global pandemic but our understanding

of the disease is still limited. Given that COVID-19 patients can present with neurological symptoms and signs, neurologists need to be involved, alert and prepared.

Kaiming Liu ¹, Mengxiong Pan,² Zheman Xiao,³ Xiaopei Xu⁴

¹Department of Neurology, The Second Affiliated Hospital of Zhejiang University School of Medicine, Hangzhou, China

²Department of Neurology, First People's Hospital of Huzhou, Huzhou, China

³Department of Neurology, Renmin Hospital of Wuhan University, Wuhan, China

⁴Department of Radiology, The Second Affiliated Hospital of Zhejiang University School of Medicine, Hangzhou, China

Correspondence to Dr Xiaopei Xu, Department of Radiology, The Second Affiliated Hospital of Zhejiang University, School of Medicine, Hangzhou 310009, China; xiaopeix@zju.edu.cn

Contributors KL: proposed and drafted the manuscript for intellectual content. MP: drafted and revised the manuscript. ZX: summarised patient data, proposed the manuscript for intellectual content.

XX: interpreted the data; revised the manuscript for intellectual content.

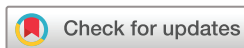Funding This study was funded by the Shandong Provincial Natural Science Foundation of China (Grant No. ZR2013HQ050), Zhejiang Provincial Natural Science Foundation of China (Grant No. LY19H090025, Grant No. LQ15H090003), National Natural Science Foundation of China (Grant No. 81101157).

Competing interests None declared.

Patient consent for publication Not required.

Provenance and peer review Not commissioned; externally peer reviewed.

© Author(s) (or their employer(s)) 2020. No commercial re-use. See rights and permissions. Published by BMJ.



To cite Liu K, Pan M, Xiao Z, *et al.* *J Neurol Neurosurg Psychiatry* Epub ahead of print: [please include Day Month Year]. doi:10.1136/jnnp-2020-323177

Received 7 March 2020

Revised 6 April 2020

Accepted 8 April 2020



► <http://dx.doi.org/10.1136/jnnp-2020-323177>

J Neurol Neurosurg Psychiatry 2020;0:1–2.

doi:10.1136/jnnp-2020-323177

ORCID iD

Kaiming Liu <http://orcid.org/0000-0001-9264-6631>

REFERENCES

- Chan JF-W, Yuan S, Kok K-H, *et al.* A familial cluster of pneumonia associated with the 2019 novel coronavirus indicating person-to-person transmission: a study of a family cluster. *Lancet* 2020;395:514–23.
- Huang C, Wang Y, Li X, *et al.* Clinical features of patients infected with 2019 novel coronavirus in Wuhan, China. *Lancet* 2020;395:497–506.
- Xu X-W, Wu X-X, Jiang X-G, *et al.* Clinical findings in a group of patients infected with the 2019 novel coronavirus (SARS-Cov-2) outside of Wuhan, China: retrospective case series. *BMJ* 2020;368:m606.
- Mao L, Wang M, Chen S, *et al.* Neurological manifestations of hospitalized patients with COVID-19 in Wuhan, China: a retrospective case series study. *SSRN Journal* 2020.
- Wang L, Cai J, Luo H, *et al.* A case of coronavirus disease 2019 with tuberculous meningitis. *Chin J Neurol* 2020;53.